

## Case Report

# Gastrointestinal metastasis of infiltrating lobular carcinoma of the breast: Four case reports and literature review

Belma Doyle, Andrew Palmier, Stephanie Magri,  
Gordon Caruana-Dingli, Michelle Ceci

## Abstract

Breast cancer is the most common cancer in women worldwide. The two main types of invasive breast cancer are invasive ductal and invasive lobular carcinoma. The most common sites of breast cancer metastasis encountered are liver, lung, bone and brain. Metastasis of primary lobular breast carcinoma to gastrointestinal (GI) tract is a well-known yet rare occurrence with reported incidence ranging from 2% to 18%. We report four such cases of invasive lobular breast carcinoma metastasizing to the GI tract, and review the literature.

## Keywords

Invasive lobular carcinoma, Breast Cancer, Gastrointestinal (GI) metastasis, Linitis plastica, E-Cadherin, Estrogen receptor (ER), Progesterone receptor (PR), CK7

## Introduction

Breast cancer is the most common cancer in women worldwide. According to the Global Health Estimates, World Health Organization 2013, breast cancer was responsible for over 508 000 deaths in 2011. Women in Western Europe saw greater incidence of breast cancer, 89.7 per 100,000, when compared to women in Eastern Africa where the incidence of breast cancer was 19.3 per 100,000.<sup>1</sup>

The two main types of invasive breast cancer are invasive ductal carcinoma comprising 80% of invasive breast cancers, and invasive lobular carcinoma accounting for about 10%.<sup>2</sup> Most commonly breast cancer is known to metastasize to the liver, lung, bone and brain. In addition to these common sites, the propensity of invasive lobular carcinoma to metastasize to extra hepatic gastrointestinal (GI) sites, peritoneum, and adnexae has been well reported in the literature.<sup>3-6,11</sup> Despite this, metastasis of primary lobular breast carcinoma to GI tract is a rare occurrence, with reported incidence ranging from 0.7% to 18%. The stomach is the most commonly affected organ and metastasis here most often presents as linitis plastica.<sup>3,4,8,10,12,19</sup> The finding of GI tract metastasis as the first presentation of breast carcinoma is particularly uncommon, but does occur.<sup>3</sup> We report four cases of primary breast carcinoma metastasizing to GI tract, with one of the patients being diagnosed with primary breast cancer and GI metastasis synchronously. Our patients experienced a wide range of gastrointestinal symptoms varying from vague discomfort and loss of appetite to severe abdominal pain, nausea and vomiting.

**Belma Doyle, M.D, F.E.B.S \***  
RS, General Surgery Department  
Mater Dei Hospital  
Msida, Malta  
belma@mcmadd.net

**Andrew Palmier, M.D (Melit.)**  
BST, Ophthalmology  
Mater Dei Hospital  
Msida, Malta

**Stephanie Magri, M.D (Melit.)**  
Medical Doctor  
Mater Dei Hospital  
Msida, Malta

**Gordon Caruana-Dingli, M.D, FRCS (Ed/Glas)**  
Consultant General and Breast Surgery  
Mater Dei Hospital  
Msida, Malta

**Michelle Ceci, MD (Melit.)**  
HST, Histopathology  
Mater Dei Hospital,  
Msida, Malta

\*Corresponding Author

### Case Presentations

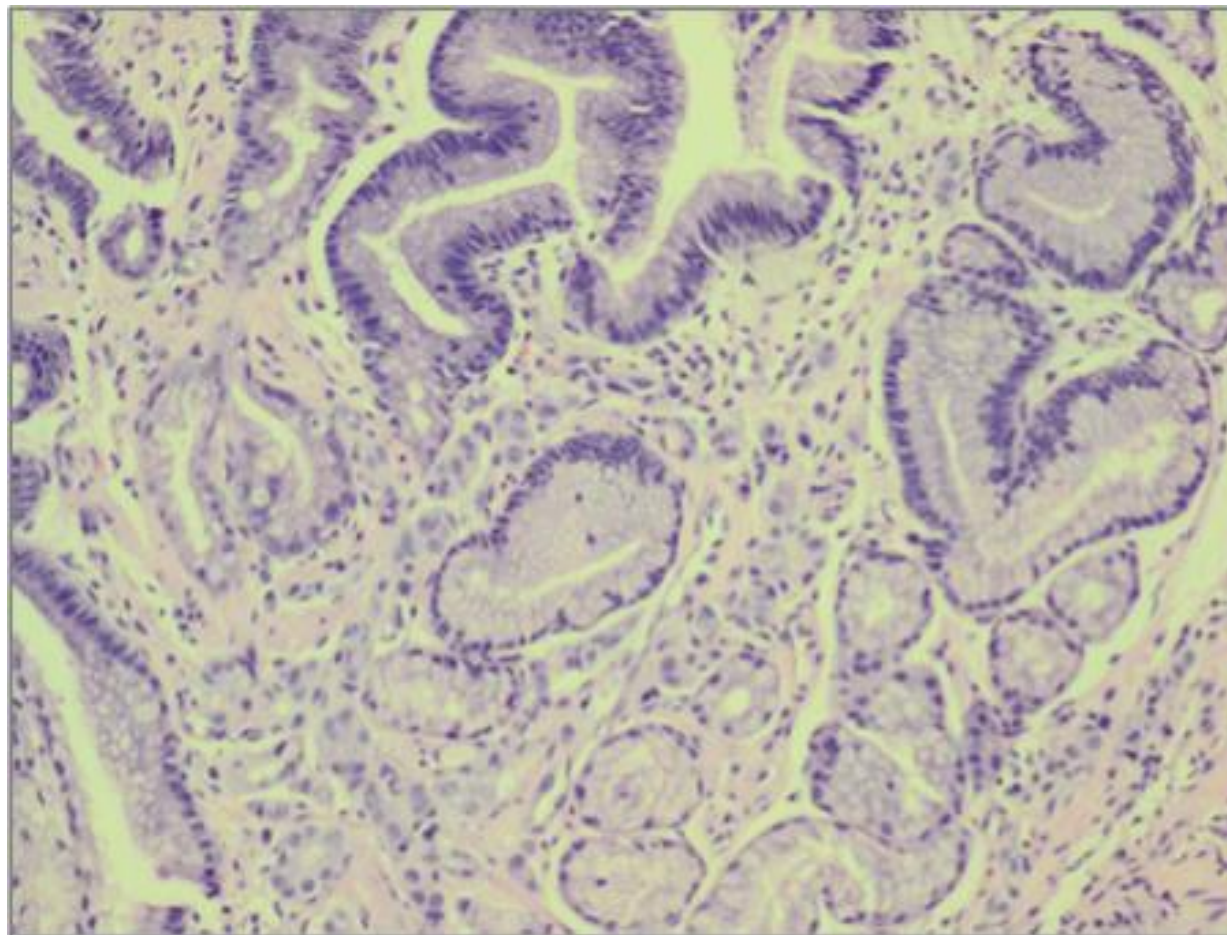
#### Case presentation 1

A 67-year-old female presented to our outpatient clinic in view of severe weight loss and loss of appetite. No other associated symptoms were reported. On physical examination she was found to have a palpable, non-tender epigastric mass, accompanied by left breast deformity with an underlying breast lump. When questioned further, it transpired that the left breast mass had been present for 20 years, during which she never sought medical attention. CT study revealed small ill defined hypodense lesions in the liver due to possible metastasis, thickening of the wall of the stomach a 17 mm round lesion between stomach, splenic vein and spleen, and rectal wall thickening accompanied by pelvic ascites. Also of note was the finding of collapsed of sixth thoracic vertebra and irregular bone texture of thoracic vertebrae 5 and 11 and the second lumbar vertebra.

OGD confirmed the CT results noting a thick, rigid stomach wall suggestive of linitis plastica extending from the oesophagogastric junction (OGJ) to the pylorus. Biopsy of the breast mass revealed invasive lobular carcinoma grade II, estrogen receptor (ER) and progesterone receptor (PR) positive and Her 2 and E-cadherin negative. Endoscopic biopsy demonstrated metastatic mammary lobular carcinoma expressing cytokeratin 7 (CK7) and ER receptors, with cytokeratin 20 (CK20), the homeobox intestinal differentiation factor CDX2, and E-Cadherin negative (Figure 1). The rectal thickening found on the CT scan was suggestive of metastasis to the rectum, however this was not confirmed by biopsy due to patient's unwillingness to undergo the procedure.

The patient was referred to oncology and chemotherapy was initiated.

**Figure. 1:** Stomach biopsy specimen stained with H&E, showing extensive infiltration of the lamina propria by malignant discohesive epithelial cells, consistent with metastatic mammary lobular carcinoma.



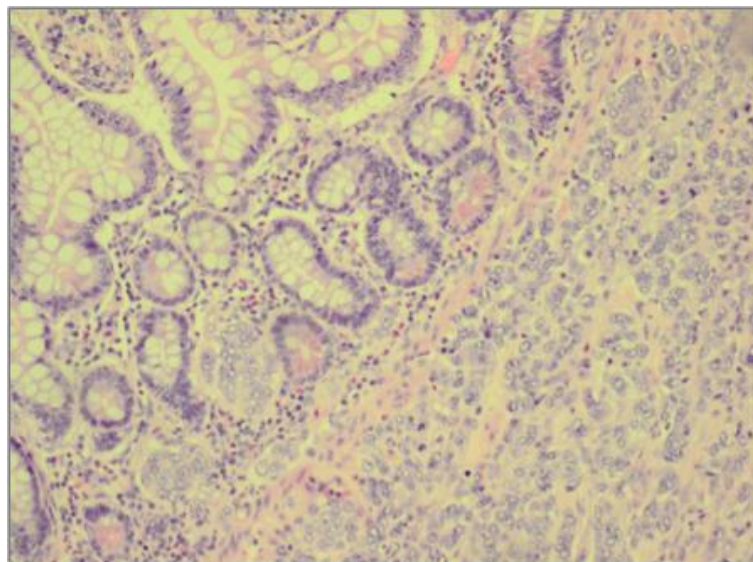
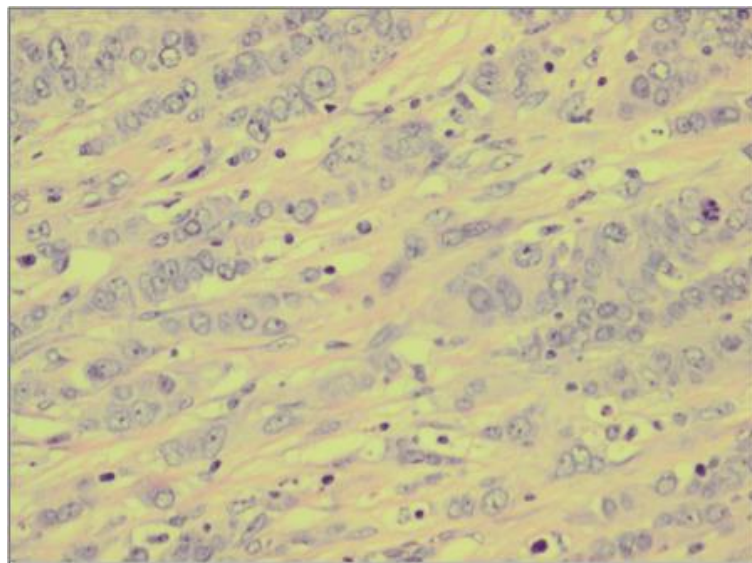
## Case Report

### Case Presentation 2

A 56 year old female presented to the outpatient clinic with a five-day history of constipation, colicky abdominal pain, nausea and vomiting. Nine years prior to this presentation the patient had undergone a wide local excision and axillary clearance for a left breast lump. Postoperative histology showed invasive lobular carcinoma, grade II, ER positive with no metastasis to axillary lymph nodes. She was subsequently treated with radiotherapy to the left breast and five-year course of Tamoxifen. Seven years later patient was diagnosed with regional metastases and treated with radiotherapy to cervical, pectoral and internal mammary regions followed by a course of chemotherapy.

CT scan of abdomen and pelvis showed multiple dilated ileal loops with a transition point in the distal ileum and a moderate amount of ascites. At laparotomy small bowel stricture was identified and resected together with a peritoneal nodule. Histological sections from small intestine confirmed diffuse infiltration by a grade III invasive lobular carcinoma (Figures 2a and 2b), which involved the whole thickness of the intestinal wall with widespread vascular and perineural invasion and lymph nod metastasis. The peritoneal nodules examined revealed the presence of metastatic lobular carcinoma. The tumor was found to be ER, PR, Her2 and E-cadherin negative. The patient underwent chemotherapy treatment.

**Figures 2a and 2b:** Sections from the small intestine stained with H&E, showing diffuse infiltration by grade III invasive lobular carcinoma involving the whole thickness of the intestinal wall.



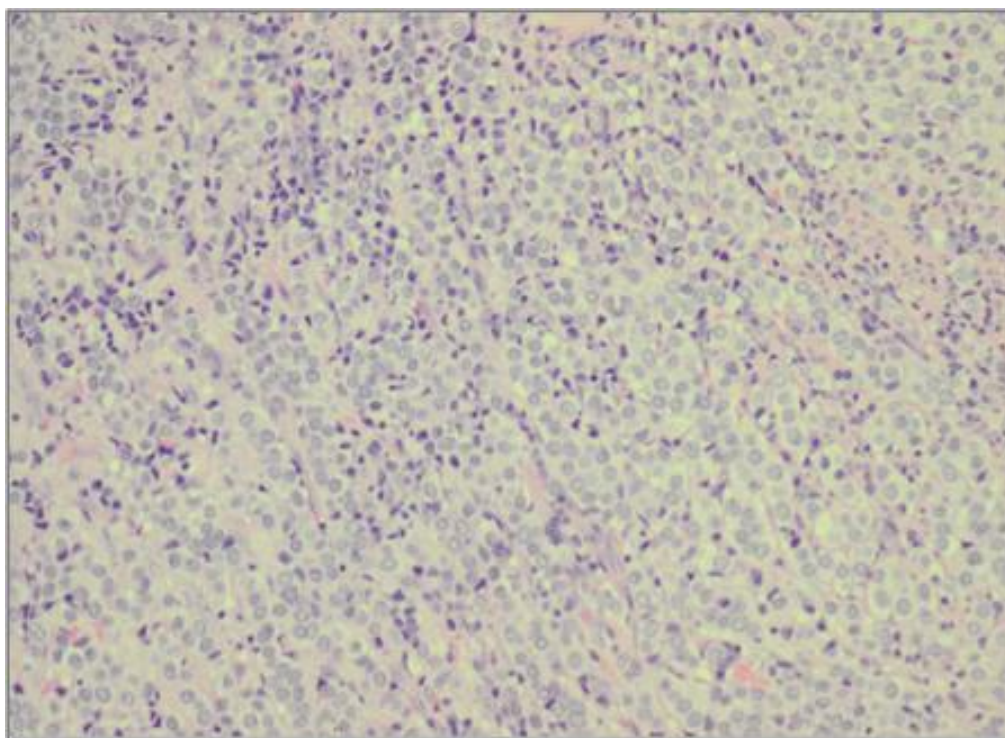
## Case Report

### Case presentation 3

An 88-year-old female presented to the outpatient clinic in view of large (8x5x3.5cm), firm, and mobile mass in the right axilla associated with right nipple retraction. Right axillary excisional biopsy was preformed, which showed ER positive, infiltrating metastatic adenocarcinoma from a primary breast carcinoma. The patient underwent radiotherapy to the right breast and axilla, and hormonal treatment of Tamoxifen was initiated with good response. Follow up radiological studies revealed no spread and no distant metastases. Eleven years later the patient presented to the

Emergency Department with persistent nausea and vomiting. Upper GI follow through showed an obstructing stricture in the distal duodenum and duodeno-jejunal flexure. Exploratory laparotomy showed a tumour obstructing the small bowel at the duodeno-jejunal flexure, para-aortic lymphadenopathy and deposits on anti-mesenteric border of jejunum. Biopsy of the stricture was taken, and gastrojejunostomy fashioned. Histology revealed metastatic lobular breast carcinoma to GI tract (Figure 3).

**Figure 3:** Histology specimen from the duodeno-jejunal flexure stained with H&E, showing metastatic adenocarcinoma from breast primary. Tumour cells can be seen in the bowel mucosa surrounded by inflammatory cells.



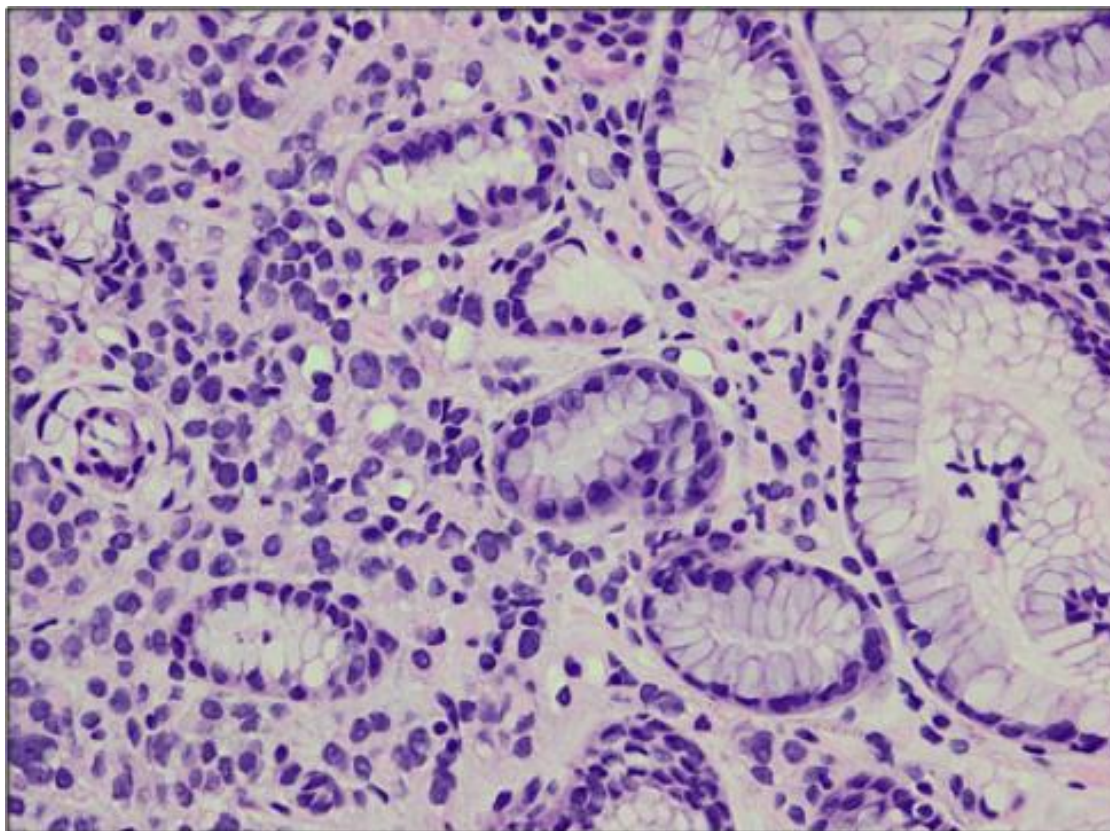
### Case Presentation 4

A 52 year old female with a history of right mastectomy with axillary clearance for invasive lobular cancer metastasizing to 6 out of 29 axillary lymph nodes 6 years prior, presented with epigastric discomfort and 20 kg weight loss in 3 months. In view of her history and raised Ca 125, a CT scan of thorax, abdomen and pelvis were preformed which demonstrated an irregularity at the gastroesophageal junction and edema of the wall of the stomach with free pelvic fluid. Multiple osteolytic bone lesions were also noted in the spine and pelvis.

Oesophagogastroduodenoscopy (OGD) and endoscopic gastric cardia biopsies were carried out. The histology confirmed metastatic lobular breast carcinoma ER, HER2, cytokeratin 7 (CK7) and gross cystic disease fluid protein 15 (GCDNF-15) positive, and PR, cytokeratin 20 (CK20), lymphocyte common antigen CD45, and E-cadherin negative (Figure 4). Cytology of free peritoneal fluid during the staging laparoscopy demonstrated adenocarcinoma. The patient was referred to oncology for further treatment.

## Case Report

**Figure 4:** Gastric cardia biopsies. Neoplastic cells infiltrating lamina propria, arranged in trabecules and single-cell lines as shown. Atypical epithelial cells are ER and HER2 positive.



### Discussion

The expected site of breast cancer metastasis commonly includes lung, liver, bone and brain. However, invasive breast carcinoma of lobular pathology, in addition to metastasizing to the listed sites, also has a propensity to metastasize to unusual areas such as GI tract, peritoneum and adnexa.<sup>6</sup> This difference in metastatic pattern of lobular and ductal carcinoma was demonstrated by Borst et al. who analyzed the rates of metastasis of invasive lobular vs. invasive ductal carcinoma and were able to show that rate of metastasis to the gastrointestinal tract (4.5% vs 0.2%), gynecologic organs (4.5% vs 0.8%), peritoneum-retroperitoneum (3.1% vs 0.6%), adrenal glands (0.6% vs 0%), bone-marrow (21.2% vs 14.4%), and lung-pleura (2.5% vs 10.2%) were significantly different ( $p < 0.05$ ).<sup>21</sup> The time interval from diagnosis of primary breast cancer to metastasis to GI is up to 30 years.<sup>14</sup>

The reported incidence of invasive lobular carcinoma metastasis to GI tract ranges from 0.7-18%.<sup>8,12</sup> The stomach seems to be the most common site of metastasis. During the year 2000, Taal et al. retrospectively evaluated 51 patients with

metastatic gastric carcinoma and found that 83% of patients with gastric involvement had lobular breast cancer as a primary histological subtype.<sup>16</sup> Similar findings were observed by Almubarak *et al.* who completed a single institution retrospective study of 35 patients with metastatic breast carcinoma to the stomach and found that 97% of the gastric metastasis from a breast cancer was derived from invasive lobular carcinoma. In lobular breast carcinoma, gastric metastasis most often presents as linitis plastica, while metastatic ductal breast carcinoma exhibits a nodular pattern.<sup>4,8,10</sup>

What gives metastatic linitis plastica its appearance is a diffuse infiltration of gastric wall by poorly differentiated tumor cells, resulting in reactive fibrosis.<sup>9</sup> As in our case, metastatic linitis plastica is usually diagnosed by endoscopy and endoscopic biopsy, although CT plays an important role in diagnosing metastases beyond the stomach. Endoscopic findings may present in 3 different patterns: localized lesions (18%), diffuse infiltration (57%), and external compression at the cardia or pylorus (25%).<sup>16</sup> When taking a biopsy during endoscopic procedures it is important to take deep

biopsies due to the observation that diffuse infiltration is predominantly seen within the submucosa and muscularis propria.<sup>9</sup>

The differentiation between the primary breast cancer metastasis to GI tract and primary gastric cancer is of utmost importance, as the treatment options will differ greatly. It may be difficult to distinguish between primary and metastatic lesions using only histology. In some cases metastasis of lobular breast carcinoma mimics primary gastric adenocarcinoma by producing signet ring morphology, making it almost indistinguishable from primary gastric linitis plastica. Therefore, immunohistochemistry can be of great help in determining the accurate diagnosis.<sup>18</sup>

Symptoms elicited by metastasis to GI tract are variable ranging from vague abdominal discomfort to acute GI symptoms. Symptoms encountered most often are weight loss, early satiety, nausea, vomiting and abdominal pain, however, incidental finding of metastases in asymptomatic patients is also common.<sup>7,11</sup> Taal *et al.* in review of 51 patients found that most common presentation was anorexia (71%), followed by epigastric pain (53%), and vomiting (41%).<sup>16</sup>

Metastasis to the GI tract from invasive carcinoma of the breast represents evidence of systemic disease and as such it is primarily treated with chemotherapy, hormonal therapy or combination of the two. A partial remission with a clear palliative effect was demonstrated in only 46% of patients receiving systemic therapy with no obvious difference in response rates between hormonal treatment and chemotherapy. Surgical intervention is reserved for complications such as bleeding or obstruction.<sup>15-16,18</sup> The choice of treatment depends on the presenting symptoms, age, general condition, receptor status, and previous systemic treatments.<sup>20</sup> Advanced age at diagnosis and gastric metastases has a negative effect on survival, whereas treatment with systemic chemotherapy or Tamoxifen carries a positive effect on survival.<sup>19</sup> McLemore *et al* reported that surgical intervention did not have a significant effect on survival (28 vs. 26 months).<sup>19</sup> Some survival benefit was seen in a select group of patients with metastasis only to the GI tract that underwent palliative surgical resection. Surgical intervention should be reserved for palliation, or may be a reasonable choice in cases of solitary resectable GI tract metastases. Appropriate systemic treatment for

metastatic breast carcinoma is the preferred treatment.

The reported median survival of patients undergoing systemic treatment for metastatic breast cancer to the stomach and gastrointestinal tract varied between 10 and 28 months.<sup>17,29,22</sup>

### Conclusion

When a patient with a history of breast cancer presents with gastrointestinal symptoms, or an apparent primary gastric cancer is diagnosed, a high index of suspicion for a potential breast cancer metastasis has to be maintained. The differentiation between breast cancer metastasis from primary gastric cancer is of utmost importance, as the treatment options of the two differ greatly. Furthermore, increased awareness of the possibility of breast cancer metastasis should be observed in females without history of breast cancer who are diagnosed with diffuse-type gastric cancer or gastrointestinal carcinoma of unknown origin.

### Reference

1. who.int [internet]. World Health Organization. Breast cancer: prevention and control; c2016 [cited 2016 May 29]. Available from: <http://www.who.int/cancer/detection/breastcancer/en/cancer.org> [internet]. American Cancer Society. Types of breast cancers; c2016 [cited 2016 Apr 5]. Available from: <https://www.cancer.org>
2. Abid A, Moffa C, Monga DK. Breast cancer metastasis to the GI tract may mimic primary gastric cancer. *J Clin Oncol.* 2013;31(7):e106-7.
3. Cormier WJ, Gaffey TA, Welch JM, Welch JS, Edmonson JH. Linitis plastica caused by metastatic lobular carcinoma of the breast. *Mayo Clin Proc.* 1980;55(12):747-53.
4. Carcoforo P, Raiji MT, Langan RC, Lansara S, Portinari M, Maestroni U, et al. Infiltrating Lobular Carcinoma of the Breast Presenting as Gastrointestinal Obstruction: A Mini Review. *J Cancer.* 2012; 3: 328-32.
5. Winston CB, Hadar O, Teitcher JB, Caravelli JF, Sklarin NT, Panicek DM, et al. Metastatic lobular carcinoma of the breast: patterns of spread in the chest, abdomen, and pelvis on CT. *AJR Am J Roentgenol.* 2000;175(3):795-800.
6. Switzer N, Lim A, Du L, Al-Sairafi R, Tonkin K, Shiller D. Case series of 21 patients with extra-hepatic metastatic lobular breast carcinoma to the gastrointestinal tract. *Cancer Treatment Communications.* 2015;3:37-43.
7. Whitty LA, Crawford DL, Woodland JH, Patel JC, Nattier B, Thomas CR Jr. Metastatic breast cancer presenting as linitis plastica of the stomach. *Gastric Cancer.* 2005;8(3):193-7.

9. Kodera Y, Nakanishi H, Ito S, Mochizuki Y, Yamamura Y, Fujiwara M, et al. Detection of disseminated cancer cells in linitis plastica-type gastric carcinoma. *Jpn J Clin Oncol.* 2004;34(9):525–31.
10. Rusticeanu M, Schuster M, Moga SL, Solomayer EF, Bohle RM, Lammert F, et al. Metastatic lobular breast cancer presenting as gastric linitis plastica. *Am J Med.* 2011;124(7)e5-6.
11. Ferri LE, Onerheim R, Emond C. Linitis plastica as the first indication of metastatic lobular carcinoma of the breast: case report and literature review. *Can J Surg.* 1999 Dec;42(6):466-9.
12. Arrangoiz R, Papavasiliou P, Dushkin H, Farma JM. Case report and literature review: metastatic lobular carcinoma of the breast an unusual presentation. *Int J Surg Case Rep.* 2011; 2(8): 301–5.
13. globocan.iarc.fr. International Agency for Research on Cancer (IARC) and World Health Organization (WHO). GLOBOCAN 2012: Estimated cancer incidence, mortality and prevalence worldwide in 2012; c2014 [cited 2016 Apr 6]. Available from: [http://globocan.iarc.fr/Pages/fact\\_sheets\\_cancer.aspx](http://globocan.iarc.fr/Pages/fact_sheets_cancer.aspx)
14. Benfiguig A, Anciaux ML, Eugene CL, Benkémoun G, Etienne JC. Gastric metastasis of breast cancer occurring after a cancer-free interval of 30 years. *Ann Gastroentetol Hepatol.* 1992;28:175–7.
15. Schwarz R, Klimstra D, Turnbull A. Metastatic breast cancer masquerading as gastrointestinal primary. *Am J Gastroenterol.* 1998;93:111–4.
16. Taal BG, Peterse H, Boot H. Clinical presentation, endoscopic features, and treatment of gastric metastases from breast carcinoma. *Cancer.* 2000;89: 2214-21.
17. Almubarak MM, Laé M, Cacheux W, De Cremoux P, Pierga J, Reyat F, et al. Gastric metastasis of breast cancer: A single centre retrospective study. *Dig Liver Dis.* 2011;43(10):823-7.
18. Pectasides D, Psyrris A, Pliarchopoulou K, Floros T, Papaxoinis G, Skondra M, et al. Gastric metastases originating from breast cancer: report of 8 cases and review of the literature. *Anticancer Res.* 2009;29(11):4759-63.
19. McLemore EC, Pockaj BA, Reynolds C, Gray RJ, Hernandez JL, Grant CS, et al. Breast cancer: presentation and intervention in women with gastrointestinal metastasis and carcinomatosis. *Ann Surg Oncol.* 2005;12:886-94.
20. Jones GE, Strauss DC, Forshaw MJ, Deere H, Mahedeva U, Mason RC. Breast cancer metastasis to the stomach may mimic primary gastric cancer: report of two cases and review of literature. *World J Surg Oncol.* 2007;5: 75.
21. Borst MJ, Ingold JA. Metastatic patterns of invasive lobular versus invasive ductal carcinoma of the breast. *Surgery.* 1993 Oct;114(4):637-42
22. O'Connell FP, Wang HH, Odze RD. Utility of immunohistochemistry in distinguishing primary adenocarcinomas from metastatic breast carcinomas in the gastrointestinal tract. *Arch Pathol Lab Med.* 2005;129:338-47.