



8-1999

Identifying Osseous Cut Mark Morphology for Common Serrated Knives

Jenny Rebecca Martin
University of Tennessee, Knoxville

Follow this and additional works at: https://trace.tennessee.edu/utk_gradthes



Part of the [Anthropology Commons](#)

Recommended Citation

Martin, Jenny Rebecca, "Identifying Osseous Cut Mark Morphology for Common Serrated Knives. "
Master's Thesis, University of Tennessee, 1999.
https://trace.tennessee.edu/utk_gradthes/4193

This Thesis is brought to you for free and open access by the Graduate School at TRACE: Tennessee Research and Creative Exchange. It has been accepted for inclusion in Masters Theses by an authorized administrator of TRACE: Tennessee Research and Creative Exchange. For more information, please contact trace@utk.edu.

To the Graduate Council:

I am submitting herewith a thesis written by Jenny Rebecca Martin entitled "Identifying Osseous Cut Mark Morphology for Common Serrated Knives." I have examined the final electronic copy of this thesis for form and content and recommend that it be accepted in partial fulfillment of the requirements for the degree of Master of Arts, with a major in Anthropology.

William M. Bass, Major Professor

We have read this thesis and recommend its acceptance:

Steven A. Symes, Walter E. Klippel, Murray K. Marks

Accepted for the Council:


Carolyn R. Hodges

Vice Provost and Dean of the Graduate School


(Original signatures are on file with official student records.)


To the Graduate Council:


I am submitting herewith a thesis written by Jenny Rebecca Martin entitled "Identifying Osseous Cut Mark Morphology for Common Serrated Knives." I have examined the final copy of this thesis for form and content and recommend that it be accepted in partial fulfillment of the requirements for the degree of Master of Arts, with a major in Anthropology.


William M. Bass, Major Professor

We have read this thesis
and recommend its acceptance:







Accepted for the Council:


Associate Vice Chancellor and
Dean of The Graduate School

**IDENTIFYING OSSEOUS CUT MARK MORPHOLOGY
FOR COMMON SERRATED KNIVES**

25/11
10
37E11

**A Thesis
Presented for the
Master of Arts
Degree
The University of Tennessee, Knoxville**

**Jenny Rebecca Martin
August 1999**

Copyright © Jenny Rebecca Martin, 1999
All rights reserved

This work is dedicated to my parents, who raised me, in their own ways, to love justice, integrity, honor, and all that is good; and to the victims of violent crimes, who show me why these things are important.

ACKNOWLEDGMENTS

There are a number of people to whom I owe an extraordinary debt of gratitude; and since I don't have the room to give them the proper thanks they deserve here, I'll try to keep it simple.

First, my deepest thanks, respect, and admiration go to Dr. William Marvin Bass. When our paths first crossed I never thought such kindness and support would come of it. Thank you, then, not only for chairing my committee when you could have very easily said no, but for helping me believe that I could really do this thing called forensic anthropology. Thank you for treating me like a future colleague, and for the bits and pieces of encouragement and advice you have imparted to me during my time at UT. Your intelligence and skill have made you well-known as an investigator, but your warmth, sincerity, and humor have made you well-liked as a human being.

I first contacted Dr. Murray Marks in late 1996, and I don't think either of us knew quite what we were in for. Thank you, yes, for agreeing to sit on my committee; but thank you, too, for guiding me through what has been a rather rough but not entirely unenlightening two years and change. Thanks for your advice, constructive criticism, and helpful suggestions.

Thanks, too, to Dr. Walter Klippel for becoming an important part of my committee and a most gracious teacher. I truly believe you must have the patience of a saint. Thank you for taking my sometimes bizarre questions and observations with understanding and a sense of humor, and for offering me access to a number of resources that have enhanced my research.

I owe an especial word of thanks to Dr. Steven A. Symes of the Regional Forensic Center at The University of Tennessee, Memphis. Not only has Dr. Symes shown a great

deal of interest in my research, but he agreed to sit on my committee and has enthusiastically offered constructive criticism and guidance through the evolution of this thesis into the form that it now takes. Thank you, Dr. Symes, for your often insightful comments on this and other topics of discussion and for being so willing to set some time aside to devote to this project.

Dr. David Joy and Justin Hwu of The University of Tennessee Engineering Department have been a Godsend to me, as without their extraordinary talents and patience the Scanning Electron portion of this research might not have been possible, particularly in the time frame I was shooting for. Gentlemen, I am grateful to you for sharing your knowledge and skills with me in this work.

Dr. Edward Siden of Felician College generously placed at my disposal the dissecting microscope I used during the magnification level of this analysis and demonstrated an enthusiasm for my own work and the work of anthropologists in general that I greatly appreciate. Thank you for allowing access to the lab and equipment I needed to get the job done, and for your help and words of encouragement.

Very special thanks are due to the individuals who aided me in the performance of the stab wound experiment: René Berube, Arthur Durband, Ginny Ellenburg, and Melissa Hargrove. Not only did Art drive me all over to pick up the truck and shirts and go out to the Experimental Station to pick up the pigs, but he helped in the infliction of the stab wounds. Ginny recorded the events of the morning and my obnoxiously-worded comments with great accuracy and good humor. René's enthusiasm for the project was unbounded and she made a number of the stab wounds under consideration while lending great moral support. And Pooh (Melissa) provided two-thirds of the left-handed stab wounds as well as a tremendous amount of professional and emotional support for which I will be forever grateful. It takes a very special group of people to overcome the

anxiety and mental blocks we all faced in order to carry out a project like this one, and I must say that they transcended the traditional definition of friendship the day the deed was done.

Additionally, thanks are due to several individuals in the UT Anthropology Department whose help has certainly enhanced this work. Dan Weinand lent a good-natured hand in processing the pig skeletons by providing me with the plastic containers and letting me run amok in the Zooarchaeology Processing Lab for a few weeks. Thanks, Dan. Jennifer Love was kind enough to take some time out so we could discuss her research dealing with serrated knives and offer welcome input, and I am grateful to her. Thank you, Jennifer, for your openness and respect. Dr. Lee Meadows Jantz and I discussed my research on several occasions, and it was she who brought up the idea of clothing that led me to throw T-shirts over the pigs — thanks for your encouragement and frank comments, Lee. Dr. Michael Elam was an important part of the very beginnings of this project, while it was still in its early formative stages. I am grateful to you, sir, for helping me with the brainstorming process and giving me some suggestions.

I would like to thank Ann Lacava and Heather Doncaster, thesis/dissertation consultants at The University of Tennessee Graduate School for examining numerous versions of this thesis and for always receiving me with great cheer, support, professionalism, and advice. Thank you for helping me to get this work done, and done well. You are truly a treasure to this University (especially to its graduate students!).

My impending graduation, and the concomitant entry into the so-called Real World, has left me with a grand view of my life as the rich tapestry that it is. Several strands seem to stick out, gleaming beacons of kindness, warmth, and support in gold and

silver against what was on many occasions a dark and stormy background. It is to these Strands I owe much, and I cannot imagine a better place to recognize them.

I believe that my birth as a scientist was heralded by Sister Mary Angelica, guidance counselor at Immaculate Conception High School. Sister Angelica, our discussions during my years at Immaculate and our continued contact afterwards have always been a source of joy and inspiration to me. On stage crew, you trusted me to get the job done when I didn't quite yet trust myself — even when the light board showered us with glittering sparks of danger during that one fateful performance. Since that time, you have persistently demonstrated that faith and support, and I thank you from the bottom of my heart.

Dr. Marla N. Powers ushered me into my nascent anthropological career and helped it to blossom into flowers of unbelievable beauty and strength. Thank you, my “anthropological mother,” for your steadfast trust, your unwavering support, and your limitless kindness. Not to mention for the fry bread and Indian Tacos! Thank you for bringing me out of myself into a world that has, in the words of Franz Kafka, freely offered itself to me to be unmasked. You pinpointed talents in me, and brought them so vigorously to my attention that I had no choice but to learn to use them to the best of my ability. All the while, you slashed down the self-deprecating remarks I insisted on making with an honesty and wit that still makes me stand back and take notice after five years, two field schools, and a multitude of conversations. I only hope that I will become half the scholar you are, and a quarter of the *winyan*.

Dr. Herbert C. Kraft took the ball that Marla set rolling and has run with it since. If she is my “anthropological mother,” then certainly Herb Kraft is my “father.” He took a stumbling toddler, handed her a pen and ink and some arrowheads, and the rest is, quite literally in some respects, history. Thank you, sir, for honoring me with your

unblinking support, constructive criticism, and heartfelt advice, treating me as a future colleague as well as a trusted assistant with an attitude of professional and personal respect unsurpassed by any. Thank you for teaching me by your shining example what it means to be a professor, author, and human being, and for always having warm water for tea when I got to work in the mornings. Your warm cordiality and honest guidance has meant a great deal to me over the years, and I am grateful to call you mentor and friend.

Dr. Philip Kayal has taught me much more than I suspect he thinks during the completion of my Sociology minor at Seton Hall. His lively approach to education and to life has proven to be infectious, and I always walked out of his classroom richer for the experience. Dr. Kayal, thank you for leading me to figure out for myself a great many things academic and otherwise, and for encouraging me to find my own path. You helped me to find my true faith, and for that I will be forever grateful.

Although he was not directly involved in my academic upbringing per se, Dr. Robert Ingoglia at Felician has been one of my staunchest supporters. Our many frank discussions have given me some very strong insights into the world of academia as it was, as it is, and as it could be; and they have bolstered my hope that a few good men and women can still make a difference. Thank you for that hope, for your friendship and support, and for the continuous encouragement and guidance that have meant a great deal to me.

My family and friends have been a great source of support and strength throughout this tedious and more than a little nerve-wracking process. Family or friends, family and friends, family but friends, angels in my life all. I have truly been blessed by their presence in my lives, and the words "Thank You" fall far too short.

Mom, what can I say other than thanks for everything. I'll never forget that first weekend's trek with a tiny car full of junk and a whole lot of emotion, and while I know it was hard for both of us I have to say thank you. Thank you for expecting nothing but the best from me, knowing full well that you'd get it. Thank you for teaching me what it means to be strong in the face of adversity, content in the face of sadness, and light in the face of darkness. Thank you for the support you've given me, financial and otherwise, not only in these past two years but always. Thank you for honoring me by being my Mother, but being a friend to me as well.

Very special thanks are due to my Father, who taught me through example the things that matter. We've come pretty far in a short time, Dad, and I'm proud of you. Thanks for your words of support and encouragement, and for re-acquainting me with someone I thought I lost a long time ago.

Deborah, Marty, Brie, and Will Manning have been my "adopted family" since I was in grade school, and have been such a wonderfully strong source of love and support for me that I think I might be lost without them. Thank you so much for opening your lives and your hearts to the girl who lived across the street; you will always be my family.

I owe a tremendous amount of gratitude to Jason S Coveleski, and words simply aren't enough to elucidate my feelings on the matter. I couldn't have found a better friend, confidante, and partner if I spent the rest of my lives searching for him. I know that the last two years have been hell for both of us, and I want you to know that I am grateful to you for your support and love throughout it all. Your patience, candor, faith, warmth, and good humor — did I mention your patience? — have helped me not only through this project but through the many slings and arrows of graduate school as well. We have waited too long for the day that you hold this finished thesis in your hands to

read, so throw a few Coronas in the fridge, get some shrimp for the fajitas, and find the Penguin, we're having a party.

The Coveleski Family has shown me such openness, respect, and support since we first met, unblinkingly and enthusiastically. I am grateful to you for the weekends, the celebrations, the sharing of joys and sorrows, and the conversations over tea and dessert. The words seem like so little in the face of the tremendous beauty that you have brought into my life, but I'll say them anyway: thank you, thank you, thank you.

I owe so much to Tracey Thomasey, my wonderful "sister" not by birth but by a deep and lasting friendship that has seen ten years of happiness, heartaches, and lots and lots of laughter and tears. We've been through so much together, skipping, stumbling, but never falling because we've always had each other to lean on. I am so thankful to you for being in my life, for laughing with me not at me, for listening to me when I call in the middle of a nervous breakdown, for your sage advice and your words of wisdom. Okay, I'm done, now I get to watch *you* be in grad school for a while.

The Thomasey Family didn't realize they were getting another daughter when their own wound up sitting next to me at Freshman Orientation ten years ago, but, well, here we are. Thank you so much for all the time we've spent together, all the fun and games and trips to the shore; and thank you for teaching a very serious girl what it means to have fun and live a little.

Truly, I have the best friends a girl could ask for. Pooh, Rex, Passley, and Katie Hargrove made me feel so welcome when I first came to Knoxville that I was happy to stay for a while. You have taught me more than you know, and I thank you for it. Pooh, what can I say? When we first set foot on the coals, we felt frightened and alone; but somewhere along the way we joined hands in solidarity and genuine friendship. Thank

you for the extreme moral, emotional, and physical support you have shared with me during our time at UT, and especially during our last semester.

Art Durband has lent me help and support above and beyond the call of friendship, especially during the course of this project. Thank you so much for your listening ear and welcome advice. Thanks too for the countless evenings of hanging out and watching movies, TV, and my computer's Stupid Computer Tricks, not to mention the falafel runs. Moe's rocks! But what are we going to do for dinner on Thursday nights now?

Kalli Lucas, Rachel Katsil, Reneé Berube, and Ginny Ellenberg made lunchtime a particularly bright spot on Tuesdays and Thursdays, and somehow even the toughest days seemed a little bit more bearable when we all got together. Thank you, girls, for the vent sessions and the tears, which more often came from laughter than sorrow. There were days I thought they were going to kick us out of Chili's because we were having too much fun. We've *got* to go Cosmic Bowling again. Preferably on '80s night.

Ginny, Reneé, thanks for making me feel like I wasn't the only sci-fi fan hanging around. Thanks too for extending your hands to help me during the course of this project, and for coming down to visit me when I was all by myself cleaning pig bones in the Annex. Rachel, how wonderful it was to be a Yankee in Knoxville and have a fellow Noo Yawker — even if I *am* technically from Joisey — to hang out with, someone who understands the beauty (?) of the subway and Washington Square Park. Kalli, thank you for helping me to become re-acquainted with the playfulness I thought I had abandoned for good. I forgot how much fun it is to play skeeball. Thank you for your genuine friendship, honesty, and warmth. Thank you all for listening to me with an understanding and patient ear.

To my remaining groups of friends in Tennessee and New Jersey, thanks for listening to me, sharing with me, and teaching me to keep my mind open for what my heart has to say.

PHOTOGRAPHS

The superior talents of Dr. Herbert Kraft have certainly enhanced this work in the face of my photographic ineptitude, something to which countless rolls of ruined film can attest. Thank you, Herb, from the bottom of my heart, for being there in my darkest hour. I worked with Dr. Kraft on two separate days to set up and shoot the bone photos in the Results I and Results II sections of Chapter 3.

Additionally, I thank Jody Whisnant at The University of Tennessee Law School for the photo scans featured in Figures 1.3 and 1.4.

ABSTRACT

Worldwide crime statistics indicate that while the firearm is the instrument of choice used in the commission of homicide, bladed weapons run a very close second. This being the case, the analysis of these implements and the cut marks they create in soft and osseous tissues demands the attention of the medico-legal and law enforcement community, particularly forensic pathologists and anthropologists. To this end, the author and several colleagues inflicted stab wounds with three pairs of common serrated-edged kitchen knives of differing blade structures to the thoracic areas of three euthanized domestic pigs (*Sus scrofa*) and examine the cut marks delivered by these knives to the ribs in order to generate an inventory of traits specific to each type of knife. This inventory consists of a combination of gross morphological and microscopic properties resulting from a three-tiered analysis: a visual examination, a low-power magnification examination, and an examination under scanning electron microscopy. The results indicate that wounds inflicted with the five-inch Farberware knife used can generally be distinguished by a large width between cut walls, little evidence of bone chipping or splintering, some lip formation visible along the cut wound edges, and walls manifesting an uneven, undulating appearance with wide, blocky, V-shaped cut floors; wounds inflicted with the five-inch and eight-inch Ekco "Flint" knives can be characterized by a moderate or marked degree of wound edge separation, some evidence of bone chipping and splintering, some lip formation that may show a cloven appearance, and walls that manifest an uneven, stepped appearance with extremely tapered cut floors; and wounds inflicted with the five-inch and eight-inch Henckels "Eversharp-Pro" knives are differentiated by their moderate degree of wound edge separation, a great deal of bone chipping and splintering, little to no lip formation, and walls that manifest an uneven, clean appearance with but slightly pointed U-shaped cut

floors. Additionally, directionality of cutting stroke may be obtained by careful examination of both chipping/splintering and lip formation features. No differences were found between the five-inch and eight-inch knife of each pair. It is noted that the list of characteristic traits generated works best as a suite for each knife, but that wall appearance and floor structure are most distinct for each type.

PREFACE

I keep next to my computer table a small collection of books I use quite often in my work and studies, something of a reference shelf that saves me the trouble of getting up to go searching for something I need five or six times in the course of one report or paper. After all, my library has developed into a rather sizeable collection of books, journals, and journal articles over the course of my academic career; to go searching for one particular work can be an endeavor akin to looking for that clichéd needle in a haystack. It takes considerable time and effort, and once I find whatever it is I was looking for I also usually find myself wondering why I was looking for it in the first place, and if I wouldn't instead be better off reading something a little less scholarly or even doing something entirely different. The problem is not one of organization, but rather one of volume, and it is coupled with that part of my personality which lacks tolerance for wasting time (actually, some would say that part which lacks patience).

The literature dealing with the identification of tool- and cut marks is much like the elusive article lost in a sea of bound and stapled books and articles in my apartment — present, but somewhat buried in the sheer number of works surrounding it. It takes time to look for it, something that I quickly discovered in researching this project. Unfortunately, when it comes to the investigation of suspicious deaths and homicides time is usually not plentiful. Putting myself in this position, beset on all sides by individuals wanting and needing answers to questions only the forensic anthropologist can provide, I hoped I would find something in my quick reference shelf that would guide me, that would help me work more efficiently. I found little.

Hence, this work is partly a selfish one. I intend to produce something that I know I would find helpful in my chosen profession. It is my sincere hope, however, that others will find it useful.

TABLE OF CONTENTS

CHAPTER 1. Introduction.

The Problem	1
The Investigation	2
The Literature	5

CHAPTER 2. Materials and Methods.

A Brief Introduction	31
A Word on the Knives	32
The Farberware® Knives: A Brief Consideration of Class Characteristics	37
The Ekco™ “Flint” Knives: A Brief Consideration of Class Characteristics	41
The Henckels® “Eversharp-Pro” Knives: A Brief Consideration of Class Characteristics	42
A Look at the Bones	44
An Account of the Procedure	46

CHAPTER 3. Results.

Immediate Results: The Injuries	56
Results I: Visual Inspection	63
Degree of Wound Edge Separation.	65
Chipping/Splintering	82
Lip Formation	89
Wall Appearance	100

Results II: Examination Under Low-Power Magnification	107
Injuries Inflicted with the Farberware® Blades	110
Injuries Inflicted with the Ekco™ “Flint” Blades	115
Injuries Inflicted with the Henckels® “Eversharp-Pro” Blades	121
Results III: Scanning Electron Microscope Examination	126
The Farberware® Injury Collection	126
The Ekco™ Injury Collection	126
The Henckels® Injury Collection	140
CHAPTER 4. Discussion and Conclusions.	
Stab Wound Morphology: A Consideration	144
The Investigation: A Brief Discussion	154
Final Summary	157
REFERENCES	160
VITA	170

LIST OF TABLES

CHAPTER 1. Introduction.

TABLE 1.1. Criteria for distinguishing between homicidal, suicidal, and accidental cutting and stabbing events, as given in “Differential diagnostic features in 700 cutting and stabbing fatalities”	10
---	----

TABLE 1.2. Skeletal characteristics of knife wounds, saw wounds, and axe wounds	30
---	----

CHAPTER 2. Materials and Methods.

TABLE 2.1. Serrated knives employed in this study, presented by brand, blade length, knife type, retail price, serration type (defined by investigator), and single- versus double-sided serrations	33
---	----

TABLE 2.2. Summary of dimensions for serrated knives employed in this study . . .	33
---	----

TABLE 2.3. Domestic pigs (<i>Sus scrofa</i>) employed in this study, presented by weight, knife pair with which injuries have been inflicted, and total number of stab wounds inflicted	46
---	----

CHAPTER 3. Results.

TABLE 3.1. List of injuries occurring on bones, by pig number, rib number and side, knife type, general location, applicable measurements in centimeters (cm), and additional comments	57
--	----

TABLE 3.2. Summarized results of visual inspection on the rib bones from Pig Carcass 1	66
--	----

TABLE 3.3. Summarized results of visual inspection on the rib bones from Pig Carcass 267

TABLE 3.4. Summarized results of visual inspection on the rib bones from Pig Carcass 370

TABLE 3.5. List of rough measurements of minimum and maximum cut widths (min width and max width, respectively) obtained under magnification 73

CHAPTER 4. Discussion and Conclusions.

TABLE 4.1. Summary of stab wound morphology features diagnostic of the Farberware,® Ekco™ “Flint,” and Henckels® “Eversharp-Pro” knives used in this study 158

LIST OF FIGURES

CHAPTER 1. Introduction.

- FIGURE 1.1. Diagram of the ribs and sternum in relation to the visceral organs directly affected by sharp force injury to the thorax4
- FIGURE 1.2. Illustration of Langer's lines present in human dermal tissue13
- FIGURE 1.3. Striae in casts and cartilage 16
- FIGURE 1.4. Class and individual characteristics of a common mass-produced screwdriver as described by Burd and Gilmore 20
- FIGURE 1.5. Cut marks and taphonomic residuals exhibited by fossil bone from Olduvai Gorge 24

CHAPTER 2. Materials and Methods.

- FIGURE 2.1. Diagrams of the general traits held in common by the collection of knives used in this study, illustrated with the 8-inch implements (not to scale) in side view and blade cross-section34
- FIGURE 2.2. Illustration of the serration types for the three knife pairs under study, as defined by the investigator 38
- FIGURE 2.3. Diagrams demonstrating measurements discussed for each knife, illustrated with the Farberware® 8-inch (top and middle left) and Henckels® "Eversharp-Pro" 8-inch (bottom and middle right) blades (not to scale) 39
- FIGURE 2.4. Illustration of the general structure of the ribs of the domestic pig . 45
- FIGURE 2.5. Body map of pig carcass demonstrating the designation of quadrants by the investigator47

FIGURE 2.6.	Visual summary of stab injuries inflicted on Pig 1	50
FIGURE 2.7.	Visual summary of stab injuries inflicted on Pig 2	51
FIGURE 2.8.	Visual summary of stab injuries inflicted on Pig 3	53

CHAPTER 3. Results.

FIGURE 3.1.	Example of a shallow cut wound/incision injury	61
FIGURE 3.2.	Two complex injuries found among the cut wound assemblage, pointed out with arrows	62
FIGURE 3.3.	The tip of the 5-inch Ekco™ “Flint” utility knife that is embedded in the fourth right rib of Pig 2	64
FIGURE 3.4.	Manifestations of a “marked” degree of wound edge separation among the injuries in the Farberware® collection (Pig 1)	75
FIGURE 3.5.	Apparent puncture wound to the sixth right rib of Pig 1	76
FIGURE 3.6.	Manifestations of wound edge separation among the injuries in the Ekco™ collection (Pig 2)	78
FIGURE 3.7.	Medial and lateral aspects of the fourteenth left rib of Pig 2	79
FIGURE 3.8.	Manifestations of wound edge separation among the injuries in the Henckels® collection (Pig 3)	81
FIGURE 3.9.	The second of two defect conglomerates seen in Figure 3.1	83
FIGURE 3.10.	Manifestations of chipping and/or splintering among the injuries in the Farberware® collection (Pig 1), pointed out with white arrows . . .	85
FIGURE 3.11.	Manifestations of chipping and/or splintering among the injuries in the Ekco™ collection (Pig 2)	87

FIGURE 3.12. Manifestations of chipping and/or splintering among the injuries in the Henckels® collection (Fig 3)	90
FIGURE 3.13. Manifestations of lip formation among the injuries in the Farberware® collection (Fig 1)	93
FIGURE 3.14. Manifestations of lip formation among the injuries in the Ekco™ collection (Fig 2)	96
FIGURE 3.15. Manifestations of lip formation among the injuries in the Henckels® collection (Fig 3)	99
FIGURE 3.16. Manifestations of wall appearance among the injuries in the Farberware® collection (Fig 1)	102
FIGURE 3.17. Manifestations of wall appearance among the injuries in the Ekco™ collection (Fig 2)	105
FIGURE 3.18. Manifestations of wall appearance among the injuries in the Henckels® collection (Fig 3)	108
FIGURE 3.19. Bone chipping is apparent in the corner of the medial floor and the vertebral edge of this wound to the fifth right rib of Fig 1	111
FIGURE 3.20. Splintering is visible on the interior of the bony lip, which appears prominent under magnification, along the vertebral edge of this injury to the seventh right rib of Fig 1	112
FIGURE 3.21. Marked lipping is visible on the vertebral edge of this wound in the anterior edge of the sixth right rib of Fig 1	113
FIGURE 3.22. Evident in this lateral view of the deep stab wound on the anterior edge of the fifth right rib is the “uneven/undulating” appearance that seems to characterize the walls of the wounds comprising the Farberware® collection	114

FIGURE 3.23. Chipping in the floor of this injury to the posterior edge of the midshaft region of the twelfth right rib of Pig 2	116
FIGURE 3.24. Chipping is apparent in the medial aspect of the floor of this stab wound in the posterior edge of the thirteenth left rib of Pig 2	117
FIGURE 3.25. This injury to the fourteenth left rib of Pig 2 demonstrates the unique “cleft-lip” appearance that is observed among several of the injuries in the Ekco™ collection	118
FIGURE 3.26. The walls of this injury to the fifteenth left rib of Pig 2 show the “moderately uneven/stepped” appearance characteristic of the Ekco™ wounds	119
FIGURE 3.27. The floor of this stab wound in the fourth right rib of Pig 2 exhibits a pointed, tapered appearance	120
FIGURE 3.28. A marked degree of chipping is evident in the medial aspect of this wound on the posterior edge of the thirteenth left rib of Pig 3	122
FIGURE 3.29. The non-patterned unevenness characteristic of the Henckels® injuries is easily discerned in the walls of this stab wound in the anterior edge of the fifth right rib of Pig 3	123
FIGURE 3.30. Apparent in the vast majority (70%) of the wounds comprising the Henckels® collection is a “clean,” cauterized appearance, even at the microscopic level, such as that seen in the walls of this injury to the eleventh left rib	124
FIGURE 3.31. Lip formation and chipping are visible under magnification where the incision marks of this conglomerate of defects, seen above in Figure 3.1, come together	125

FIGURE 3.32. Scanning electron micrographs of two separate injuries showing chipping and splintering resulting from injury with the Farberware® knives, pointed up with black arrows127

FIGURE 3.33. Scanning electron micrograph of the lateral aspect of the deep stab wound to the fifth right rib of Pig 1 128

FIGURE 3.34. Scanning electron micrograph of two injuries showing bony lip formation in the Farberware® collection129

FIGURE 3.35. Scanning electron micrographs of the walls of two stab wounds to ribs in Pig 1, with wall edges pointed up with black arrows130

FIGURE 3.36. Scanning electron micrographs of two injuries from Pig 2 that demonstrate the characteristic narrowness of the Ekco™ stab wounds. 132

FIGURE 3.37. Scanning electron micrograph of the tip of the broken 5-inch Ekco™ utility knife embedded in the fourth right rib of Pig 2133

FIGURE 3.38. Scanning electron micrographs demonstrating bone splintering, pointed up with black arrows, along the edges of two wounds from Pig 2 134

FIGURE 3.39. Scanning electron micrographs showing lipping along the edges of a wound to the eighth right rib of Pig 2 (view of medial side, sternal end toward top) 135

FIGURE 3.40. Scanning electron micrographs demonstrating the characteristic uneven/stepped appearance seen among the Ekco™ collection of injuries (Pig 2), pointed up with black arrows136

FIGURE 3.41. Scanning electron micrographs illustrating sharp tapering, pointed up with black arrows, of wound floors in rib injuries from Pig 2 138

FIGURE 3.42. Scanning electron micrograph showing roughness along the edge and interior of one stab wound from the injuries in Fig 2 139

FIGURE 3.43. Scanning electron micrograph of two wounds showing the clean, uneven structure — pointed up with black arrows — that characterizes the injuries inflicted with the Henckels® knives (Fig 3)141

FIGURE 3.44. Scanning electron micrograph of the floor of a stab wound to the eleventh left rib of Fig 3142

FIGURE 3.45. Scanning electron micrograph of the stab wound to the thirteenth right rib of Fig 3 at its floor, showing concentration of broken fibers caught in walls of wound. 143

CHAPTER 4. Discussion and Conclusions.

FIGURE 4.1. Illustrations of a false start kerf and bone cross section with break-away spur 145

FIGURE 4.2. Variants within the Class A kerf type, which is comprised of fine toothed bow saws (1-9) and serrated knives (10-11)147

CHAPTER 1

INTRODUCTION

THE PROBLEM

Generally, injuries that occur from the corpus being punctured, slashed, or otherwise sullied by a bladed or pointed weapon are not accidental, although many may be; rather, they are intended to cause injury at the very least (Adelson 1974, Knight 1975). Recent statistics from the U.S. Department of Justice Bureau of Justice Statistics (1998) indicate that knives were the second most-often used implements of homicides in the United States between 1976 and 1997 (see also Spitz 1980). According to the Federal Bureau of Investigation (1998), approximately 18,209 individuals were the victims of "the willful (nonnegligent) killing of one human being by another" in 1998, and 15,289 are documented with

supplemental data . . . consist[ing] of: the age, sex, and race of both victims and offenders; the types of weapons used; the relationships of the victims to the offenders; and the circumstances surrounding the murders [1998:15-16].

Of the homicides furnished with this information, 12.8 percent — 1,963 crimes — were committed with "knives or cutting instruments," mainly by males between the ages of 20 and 24, with the majority taking place during the course of arguments and robberies (Federal Bureau of Investigation 1998). These numbers are slightly lower than those of the preceding year, in which 13.5 percent, or 2,142 homicides were executed using sharp instruments, mainly by males between the ages of 35 and 39 during arguments and robberies (Federal Bureau of Investigation 1997).

The use of bladed weapons during the perpetration of such violent acts as homicide is equally common, if not moreso, in nations other than the United States. Hunt and Cowling (1991:107), for example, indicate that "Stabbing is the most frequent way of

committing homicide in the United Kingdom,” a statement echoed by Knight (1975). A study of the homicide rate in the province of Newfoundland, Canada, demonstrates that 35 percent involved the use of a knife, with 16 of the 45 murders recorded for the years 1985-1993 resulting from sharp force trauma (Avis 1996). In Jamaica, knives also comprise the major tool of injury, as these implements are prolific in the small island nation (Mansingh and Ramphal 1993). Knife stab injuries are seen under a multitude of circumstances throughout the world, including drug-related crimes (Federal Bureau of Investigation 1997), situations of domestic violence (Green 1978; Knight 1975), sexually sadistic killings (Warren et al. 1996), and suicides (Adelson 1974; Hasekura et al. 1985; Kuroda et al. 1997; Spitz 1980; Start et al. 1992). Given the prevalence of bladed weapons and their use in the commission of homicide, it behooves the law enforcement community to develop a greater understanding of these implements and the cut marks they leave in human tissue in order to better facilitate the prosecution of assailants in cases of knife wound violence.

THE INVESTIGATION

As they are so widely employed in the commission of violent acts, the importance of the study of knives and other such instruments cannot be too greatly emphasized. Of course, the type of tool put to use in these crimes can take one of an extraordinarily wide array of (e.g., Symes et al. 1999). Adelson remarks that deaths resulting from stab and cut injuries are

caused by objects whose *primary* function is *not* that of an offensive or defensive weapon. . . . The great majority of cutting *and* stabbing fatalities encountered in civil life are *not* caused by such warlike weapons as bayonets, swords or sabers. Rather they involve such mundane objects as kitchen knives, pocket knives, screw drivers, razor blades, broken bottles, shattered window panes, files, scissors, axes and hatchets [Adelson 1974:319, italics in original].

Perhaps not surprisingly, highly frequent among this array of tools is the ubiquitous kitchen knife. Green (1978) finds that while kitchen knives are the most commonly-wielded tool of murder, they tend to bend and/or break quite easily. As is pointed out by Hunt and Cowling (1991; see also Knight 1975), this type of knife is readily accessible, highly fatal, and effortlessly concealed; in their investigation of stabbing deaths in Great Britain, the authors note that

The commonest weapon was a kitchen knife or carving knife. . . . men deliberately arming themselves will often choose a kitchen knife rather than a sheath knife, presumably because it is easier to pocket, easier to dispose of and more easily available [Hunt and Cowling 1991:111].

For this reason, this investigator has chosen to direct her research to the careful consideration of one of the most common types of knives to fall into the hands of murderers, the serrated kitchen knife, with the intention of making the injuries inflicted in bone by this handy weapon more definitively indicative of its type. The focus of injury inflicted will be the bones of the chest, specifically the ribs — a logical selection given that “Lethal stab wounds are usually located on the anterior chest, epigastrium and subcostal regions . . . from the natural tendency of the assailant to direct his thrust at the heart as his organ of choice” (Adelson 1974:340). Stabbing injuries to the chest have very high potential for fatality, as they may strike not only the heart but also major arteries and veins, the lungs and air passageways, and the diaphragm and thus may result in a large amount of blood loss or the introduction of air into the circulatory pathways (Adelson 1974; Sherman et al. 1977; see Figure 1.1).

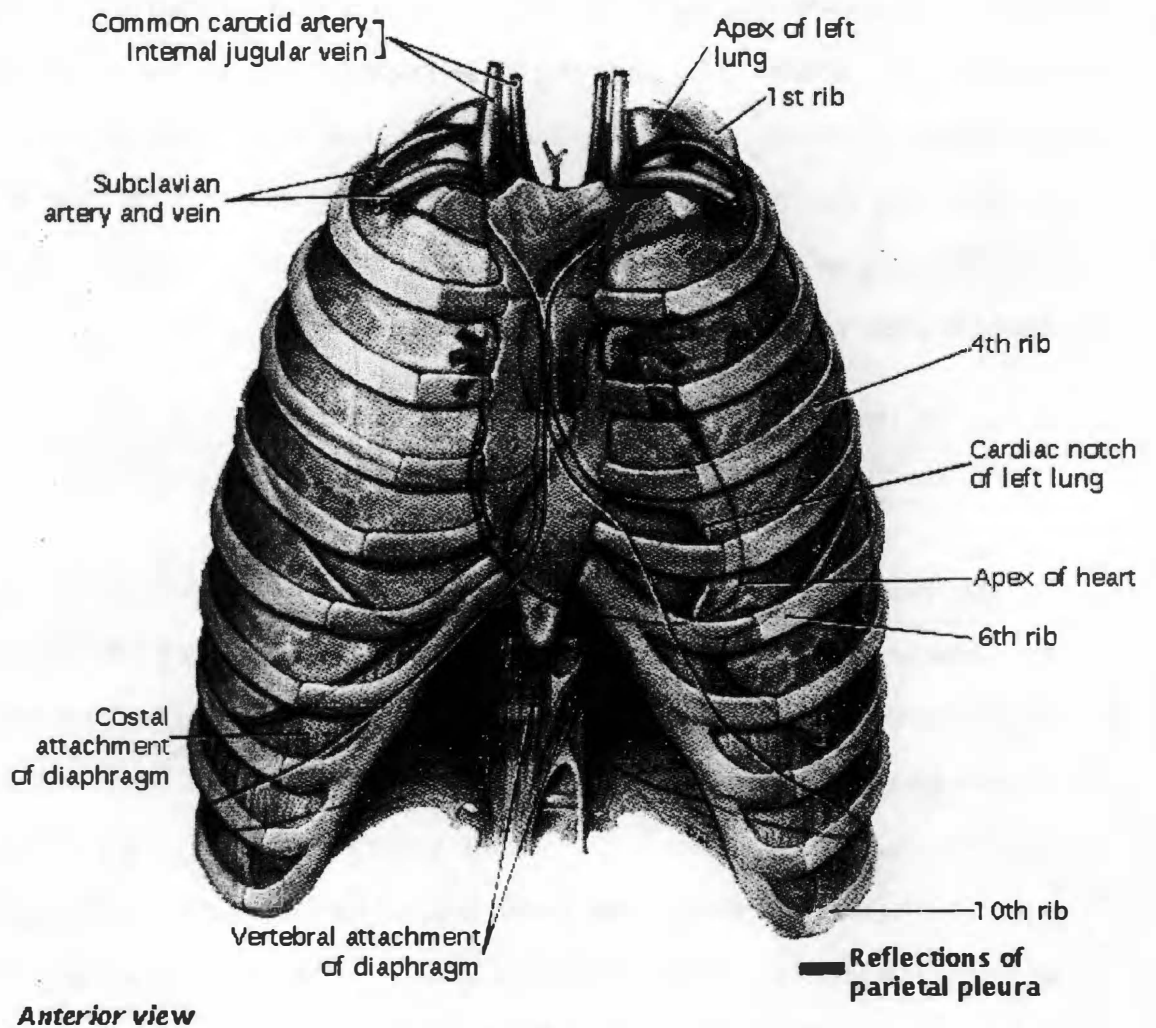


FIGURE 1.1. Diagram of the ribs and sternum in relation to the visceral organs directly affected by sharp force injury to the thorax. Note that the heart and major blood vessels are but partially protected by the bony plates of the manubrium and gladiolus (sternal body). Modified from Moore KL. Clinically oriented anatomy. Third edition. Baltimore (MD): Williams and Wilkins, 1992; 61.

THE LITERATURE

Addressing this study of stab wounds in bone requires a brief literature review of work previously accomplished by physicians, criminalists, and anthropologists. The consideration of the efforts of these researchers highlights the interdisciplinary approach that must be taken in the investigation of homicides and other criminal acts, in general, and fatal stab wounds in particular. Frayer and Bridgens (1985) discuss a case involving apparent stab wounds in a skeleton found in Kansas in 1983. The authors highlight the importance of an interdisciplinary approach to the investigation of suspicious deaths (1985:238):

In this case, presumably fatal, antemortem injuries as well as indications of the dimensions of the instrument of death were determined by detailed examination of carefully cleaned skeletal material. This emphasizes the importance of a close working relationship among investigating officers, pathologists, radiologists, and forensic anthropologists. Careful examination of any bony parts following removal of the decomposed tissues may reveal the appearance of unappreciated injuries that can lead to the delineation of the cause of death and definition of the weapon used in inflicting the wounds.

In his review of advances in forensic medicine in Belgium, Thomas (1964) briefly describes two instances in which the examination of skeletal remains is pivotal to the successful investigation of cases of suspicious deaths. In the first case, a fracture of the frontal bone caused by a hammer blow to the forehead is only observed after the victim is autopsied, buried, exhumed, and autopsied again, the second procedure including the removal of the remaining flesh. The second case is one in which an inspection performed on the defleshed skull of an axe-murder victim yields markings which match the weapon to the crime (see also Thomas and Gallet 1947). Sivaram (1977) describes a case in which a set of skeletal remains is uncovered in a field in India, accompanied by a serrated sickle such as that used in grain harvesting; inspection of marks present on the bones after their cleaning draws a strong connection between the implement and the

wounds. One physician points out that "A stab or incised wound, like any other wound, possesses important characteristics in addition to its dimensions" (Adelson 1974:329). This statement that is true not only of skin, cartilage, and other soft tissue but also of bone, making it an important contributor of evidential knowledge.

Although information regarding stab wounds and cut marks is of great import in medico-legal investigations, material applicable to the examination of such injuries is surprisingly sporadic, and the majority of the literature is directed toward the identification of implements by marks produced in skin and cartilage rather than bone. Spitz (1980) presents a discussion of the characteristics of cut and stab wounds, differentiating between the two and examining at some length the distinctions between homicidal and suicidal injuries. He reviews the ways in which skin interacts with a sharp implement to create a wound, the methods by which stab wounds are investigated, the deadly aspects of stab injuries, and the phenomenon of dismemberment. Adelson (1974) considers the subject of cutting and stabbing wounds in skin and cartilage in depth, presenting an overview of fatal wounds inflicted by bladed and pointed objects with his major focus being epidermal and visceral tissue. He briefly comments on a number of topics pertinent to the investigation of these injuries. These include characteristics of stab, incised, and laceration wounds, the physical and anatomical logistics surrounding the creation and appearance of these wounds in skin and visceral tissue, a breakdown of wounds by anatomical location, the consequences of initial injury that lead to the death of the victim, and the piecing together of events immediately preceding the fatal strike. In perusing his work, the reader finds a number of factors that can be derived from the investigation of sharp force injuries to the skin: the thickness and/or width of a blade, the angle at which the knife penetrated the skin, the number of cutting edges on the blade, the sharpness of these edges, the weight of the

implement, and the force of the blow can all be suggested by the appearance of the lesion (Adelson 1974). However, these characteristics can be easily lost once the process of decomposition begins (Sauer 1984), significantly decreasing their value as the soft tissue loses its integrity; and not all fatal stabbing victims are conveyed to the police or medical examiner immediately following their injury.

Additionally, unlike the sequence of events in many shooting deaths, the victim may not succumb at once to his or her wound(s), but may perform any number of actions or move some distance before so doing; death results not simply from the stab itself but from “(1) the site and (2) the functional consequences of the injury” (Adelson 1974; Spitz et al. 1961). The wound sustained by a stabbing victim can be quite damaging, as Green (1978) states that little can halt the blade save for its reaching the hilt on one end or bone on the other, making the potential for severe or lethal injury high indeed. External blood loss and internal hemorrhage account for the majority of deaths in which stabbing or cutting instruments are used. These injuries lead to the imbalance in circulatory pressure known as hypovolemic shock, in which blood pressure can be lost quickly (Adelson 1974; Marieb 1995). Sherman et al. (1977) detail the consequences of thoracic injury resulting from a variety of forces, including “missile” injuries such as gunshot wounds; blunt trauma injuries, such as those sustained in vehicular accidents; and “penetrating” injuries such as stabbings. In thoracic stab injuries, they note, “The tissue damage inflicted . . . is largely determined by the size of the instrument and the pathway it travels” (Sherman et al. 1977:200). External blood loss, hemorrhage within the pericardial sac or pleura, pneumothorax and hemothorax — the introduction of air and blood respectively into the chest cavity that disallows proper lung function — interference with the integrity of the trachea and bronchi, infectious disease and

abscess, and aneurysm each comprise an avenue by which the victim of a fatal stab wound perishes (Adelson 1974; Marieb 1995; Sherman et al. 1977; Spitz 1980).

The multifarious methods by which stab wounds can kill and the factor of time variation involved in blood loss within and/or outside the body give this type of fatality a non-instantaneous quality. Spitz et al. (1961) describe cases in which the victims survived for different periods of time, carrying out numerous actions while losing blood from sharp force or gunshot wounds that would ultimately result in their demise. These cases are tabulated and compared based upon type of wound, how quickly the wound disabled the individual, and the amount of blood lost. For example, the physicians describe three cases in which the victims were stabbed with kitchen knives (Spitz et al. 1961:297):

Case 59: B9 A 23 year old colored male who was stabbed with a kitchen knife. Following the stabbing, the victim walked and staggered a distance of 358 feet and died at the hospital a few minutes after arrival there. The wound tract penetrated the left ventricle and the aorta to a width of one-fourth inch and caused internal bleeding of nearly 2000 ml.

Case 82: B10 A colored male, aged 25, was stabbed with a kitchen knife causing severance of his left subclavian artery and vein. Following the injury the victim ran four city blocks and collapsed. He died at the hospital one hour later. The total blood loss was estimated at about 3000 ml. . . .

Case 107: B12 A colored male, aged 26, who was stabbed with a kitchen knife. Following the injury the victim staggered a distance of three city blocks and died at a hospital about thirty minutes later. The wound tract penetrated the heart and caused a one inch wide laceration in the right atrium. The total blood loss into the pericardial sac and the left pleural cavity was 1500 ml.

The majority of sharp force victims (51.0 percent) remained active for approximately five minutes after receiving their death blows; one individual, however, lived for close to a day (Spitz et al. 1961). English physicians Hendry and Stalker (1967) describe the case of a young man who is admitted into the hospital after having suffered what he believes to be a stab wound to the face from a metal comb. After spending approximately one and one-half days in the hospital with decreasing health but retaining consciousness for the majority of his stay, the youth dies; and only careful autopsy reveals that he had in

actuality sustained a stab wound to the upper neck through which the weapon perforated the medulla oblongata. There is a direct relationship between the amount of time an individual survives prior to succumbing to his/her injuries and the amount of blood s/he loses, with the increasing length of survival time increasing blood loss (Spitz et al. 1961). Hunt and Cowling (1991:112) note that "the victim goes on fighting despite having received many stab wounds" in some cases. The difficulty this presents in the investigation of stabbing fatalities lies in the fact that while an individual may survive for rather a while before death ensues, there is no method by which to anticipate this length of time (Spitz et al. 1961). These aspects of fatal stabbing injuries may limit the utility of the crime scene in the interpretation of injury as well, as the victim may move within or away from the scene (as demonstrated particularly well by Spitz et al. 1961) or alter it in some other fashion so as to render it poorly reflective of the actions that occurred there.

As pointed out earlier in this chapter, fatalities resulting from stab wounds rarely arise by chance. An important distinction medical examiners and other forensic scientists must render, but which will be only briefly touched upon here, is the situation surrounding such an injury, as whether a given case is a homicide or a suicide. Adelson (1974:359) counsels, "A sound approach to this phase of the investigation is to consider every cutting and stabbing fatality as homicidal unless there is irrefutable proof to the contrary," and presents a table of characteristics (Table 1.1) that establishes definitive criteria for each situation. Hesitation marks are generally seen to indicate suicide, whereas defense wounds are taken to indicate homicide (Adelson 1974; Hasekura et al. 1985; Spitz 1980). Additionally, Spitz notes that "A stab wound generally suggests homicidal assault by virtue of its appearance and depth" (1980:160). In a study dealing with suicidal refugee victims of Post-Traumatic Stress Disorder (PTSD) living in Sweden,

TABLE 1.1. Criteria for distinguishing between homicidal, suicidal, and accidental cutting and stabbing events, as given in "Differential diagnostic features in 700 cutting and stabbing fatalities." Modified from Adelson L. Homicide by cutting and stabbing. In: Adelson L, editor. The pathology of homicide. Springfield (IL): Charles C. Thomas, 1974; 359.

MANNER OF DEATH	HOMICIDE	SUICIDE	ACCIDENT
INCIDENCE	80%	18%	02%
WOUND GROUPING	Irregular	Arranged or systematic	Vulnerable site
TARGET AREA	Chest mainly, neck or groin	Victim's choice Neck, wrists, precordium	Vulnerable site
NUMBER OF WOUNDS	Usually multiple (may be single)	Frequently multiple	Usually single
HESITATION MARKS	Absent	Usually present	Absent
DEFENSE WOUNDS	Present if victim had opportunity	Absent	Absent
CLOTHING	May be involved	Part usually exposed	May be involved
NON-CUTTING INJURIES	Signs of struggle	Absent	May be associated with accident
WEAPON	May or may not be at scene	Usually at scene	Usually at scene
METHOD	Usually stabbing, but often associated with cutting	Cutting of neck and wrists Stabbing at precordium	Usually stabbing

Ferrada-Noli et al. (1998) indicate a high correlation of suicide by cut or stab injury for those individuals subject to the infliction or witness of torture by sharp force trauma. Hasekura et al. (1985:1269) note that "Stabbing oneself with a pointed knife . . . reveals a definite resolution to kill oneself," and although it comprises a small percentage of suicides in Japan, it is "a national tradition." The authors illustrate the case of a ten-year-old boy who, despondent over his mother's recent death and his father's disciplinary actions, stabbed himself in the throat with a small knife. Although this case is unusual in its youth (Hasekura et al. 1985), between the years 1976-1995, the self-stabbing manner of suicide was involved in approximately 3.4 percent of Japanese cases, with the chest being second only to the neck in terms of anatomical region in which the fatal wound was inflicted (Kuroda et al. 1997). According to Spitz, self-stab injuries are infrequent in the United States as well, and are definitive:

When present, they are usually multiple and superficial . . . Suicidal stabbings are frequently accompanied by cuts in other locations, particularly on the wrists and the throat, less commonly in the bend of the elbows and ankles.

The appearance of suicidal cuts is usually characteristic: they are multiple parallel cuts of variable depth whose edges commonly reveal several sharp angles as if resulting from *sawing* of the skin with repeated tentative incisions at the same location. Frequently numerous superficial parallel cuts resembling scratches are noted, indicating repeated trials before the buildup of sufficient courage for the final deep gash that severs major blood vessels or exposes the trachea or larynx [Spitz 1980:173; italics in original].

Adelson notes multiple wounds as part of the suite of identifying traits of homicide situations. However, Hunt and Cowling (1991) indicate that multiple wounds may result for a number of reasons, including a desire on the part of the assailant to ensure the death of the victim, particularly in cases where s/he does not immediately expire. Murray and Green (1987) find that, among 143 cases of fatal stabbings, slightly more than one-half (77 cases) involved multiple wounds. While the evidence toward one scenario or another may appear to be overwhelming, it is important to keep in mind that

“. . . it is never right for a medical witness to comment, even obliquely, upon the possible state of mind of a person inflicting injuries” (Hunt and Cowling 1991:111).

It is not only proper but required for that witness to comment upon the weapon used by a person to inflict those injuries, and a number of authors have written on the identification of these weapons. Rabinowitsch (1959) presents a basic overview of the morphology of cut marks in skin and their relation to the weapon allegedly used in their infliction, synthesizing interpretations offered by several researchers in terms of blade form and the positioning of dermal reticular fibers and how these influence the shape of the wound (see Marieb 1995). From his observations, Rabinowitsch has concluded that extremely open wounds are produced when a stab is administered transversely to separations among these fibers, commonly called Langer’s lines (Figure 1.2), while relatively closed wounds are produced when a stab is inflicted along these separations (Rabinowitsch 1959; see Adelson 1974, Spitz 1980 for further discussion of Langer’s lines). Where Adelson (1974) considers these lines integral to the identification of the implement used in creating an injury, however, Rabinowitsch (1959:160) states that “Most authors . . . advise care in drawing conclusions about the shape of instruments from the shape of the wounds,” even as they are in consensus about some aspects. Spitz discusses the method by which stab wounds are reconstructed in skin to gain a better understanding of its original structure, and thus a clue as to what type of weapon might have caused it, as well as the determining of the wound’s directionality (Spitz 1980). In his brief discussion of stab wounds, the physician indicates that the shape of the injury might aid the investigator in determining what type of weapon caused it, as certain implements such as forks and screwdrivers ordinarily leave characteristic marks (Spitz 1980). He also notes the utility of bone in an investigation:

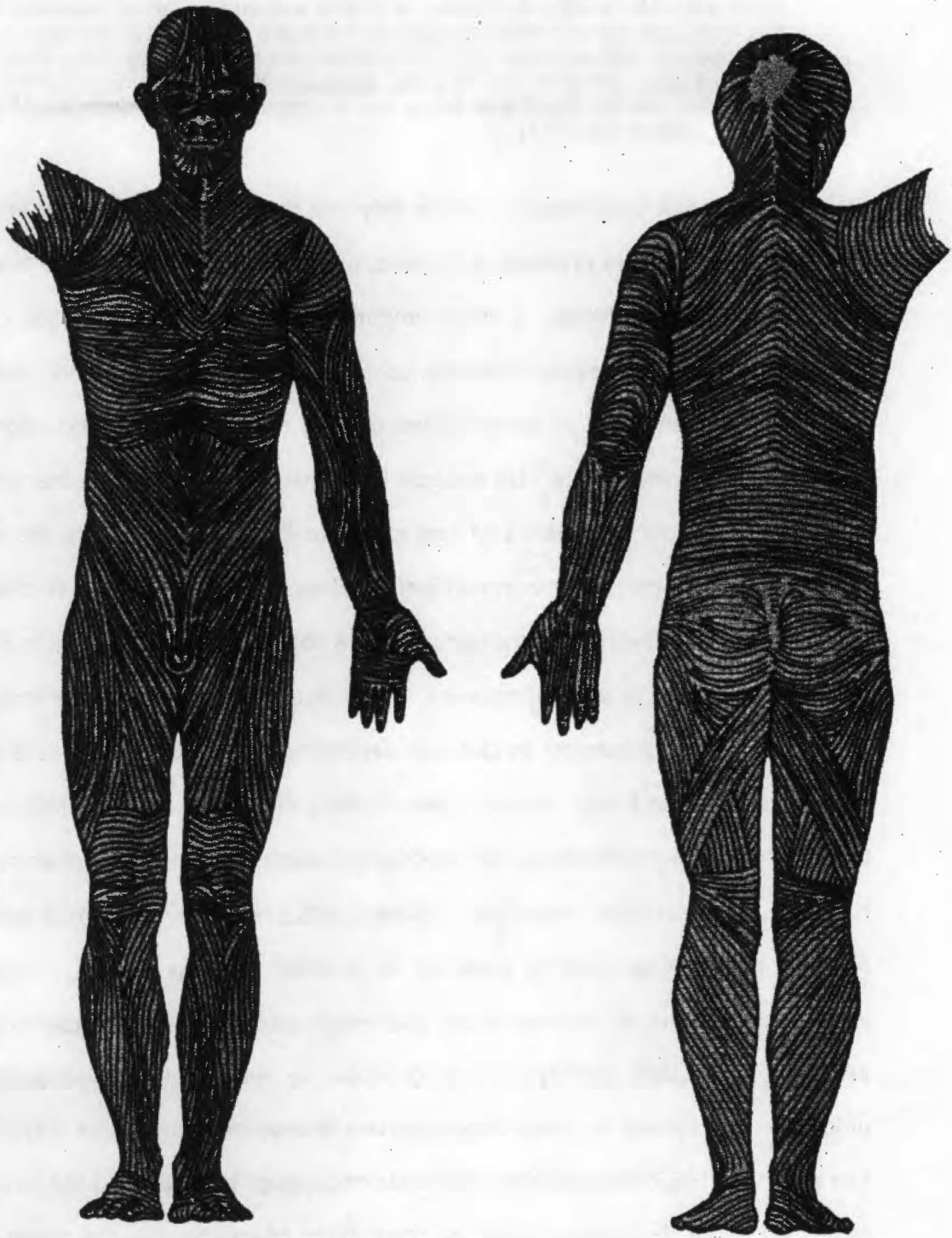


FIGURE 1.2. Illustration of Langer's lines present in human dermal tissue. Modified from: Spitz WU. Sharp force injury. In: Spitz WU, Fisher RS, editors. *Medicolegal investigation of death*. Springfield (IL): Charles C. Thomas, 1980; 191.

Due to its rigidity, bone maintains the dimensions and shape of a stab wound far better than skin or other soft tissue. In fact, it is often possible to determine the type of weapon used to inflict an injury by examining the wound in the bone . . .

A homicidal stab wound is rarely inflicted without some cutting taking place at the same time. The knife may be pulled upward or downward during insertion or withdrawal, thereby causing an injury that is longer than the widest part of the blade . . . [Spitz 1980:184].

Clearly, then, epidermal tissue is not the only one that is important to the investigation of stab wounds. Before proceeding to bone, however, it would be wise to touch on the role of cartilage. Cartilage, a tissue important in the formative stages of skeletal development and mature joint structure, contains neither nerve tissue nor blood vessels but maintains a structure of both soft and ossified tissue (Marieb 1995). Bonte (1975) considers the appearance of stab wounds in cartilage as governed by the form of tool used as well as the appearance of saw marks in bone as affected by the movement involved, and presents the concept of individual weapon identification via characteristic marks left by flaws present on the surface of the objects, emphasizing the importance of tool mark analysis in law enforcement. This study also demonstrates that serrated knives leave distinct patterns in cartilage depending upon the displacement caused by the structure of the blade. Imperfections in the knife blade due to manufacturing and use wear increase the likelihood of identifying a particular knife by further specializing the cut mark in cartilage, according to Bonte (1975:318): "one can almost always count on finding individual marking patterns" as a result of these factors. Similarly, the idiosyncratic nature of saw teeth aids the investigator in assessing the likelihood of assigning responsible identity to a particular saw by making the cut marks left in bone unique, as considered in cases of postmortem dismemberment (Bonte 1975:322-323). Rao and Hart (1983) illustrate the usefulness of cartilage in preserving the structure of a suspected homicide implement via the comparison of striations in the costal cartilages of the victim and striations created by the knife in question in a cellulose acetate

butyrate medium and cast with a dental impression material (Figure 1.3) (Rao and Hart 1983). In their discussion, Rao and Hart state that “Cartilage . . . may record much finer detail than bone because of its firm and softer texture. It facilitates identification comparison of tools with less prominent individualities [such as major imperfections]” (1983:798). However, anthropologists have made great progress in the identification of individual implements from cut marks in bone, particularly with the advent of scanning electron microscopy. Symes et al. (1999) detail the unique characteristics of cartilage that render it an important, though largely neglected resource, stressing the need to examine it quickly and thoroughly at autopsy. The authors encourage forensic investigators to turn their attentions toward both cartilage and bone rather than rely mainly on skin in their efforts to identify the type of implement. Bone and cartilage may hold information that skin cannot, such as blade features retained in the impressionable cartilage and “chicken tracks” resulting from the movements of individual teeth seen in the path of serrated knife stabs on bone.

It is the “record-keeping” aspect of bone that makes it so useful in criminal investigations. Most often, the aspect of criminalistics that deals with tool marks considers only those left at a crime scene, such as in a damaged lock (see Burd and Greene 1948; Flynn 1957; May 1930) or sawn tree branch (see Burd and Greene 1948; May 1930); it is infrequent that bone is even mentioned in the course of these early studies. Criminalistics studies dealing with tool mark and firearms identification have much insight to offer the anthropological investigation of knife marks in calcified tissue. Tool mark investigation began in the early twentieth century with the work of May (1930), who described several cases where rudimentary microscopic identification of weapons was used in the solving of heinous crimes. May states that




FIGURE 1.3. Striae in casts and cartilage. a, Striae created by suspected weapon in cellulose acetate butyrate and cast with dental impression material (1 inch = 25.4mm); b, comparison microscopic analysis of striae observed in blade casts and those apparent on costal cartilage of victim. Modified from Rao VJ, Hart R. Tool mark determination in cartilage of stabbing victim. *Journal of Forensic Sciences* 1983;28:798, 799.

Exhaustive research over [an eighteen-year] period has developed the fact that it is possible, under favorable circumstances, to identify the particular instrument, knife or tool, making a cut in metal, wood or other stable substance in over 90% of the cases [1930:246-247].

This includes those implements that were twisted or otherwise moved during their criminal use. Insights such as these led a number of workers in the field of criminalistics to focus on a scientific approach to the differentiation of particular tools and weapons according to characteristic marks. Thomas (1967) presents a brief history of the technique of matching characteristic striations to certain tools, beginning with the work of R. Kockel in the early nineteen-hundreds. Thomas points out that a great deal of literature concerning the topic of the forensic identification of guns was hidden for many years, and encourages other scientists to contribute to the field with the hope that ultimately "a complete inventory" of the literature might coalesce (Thomas 1967:5). Burd and Kirk (1942:679), citing "a lack of careful study of the factors which influence the character of the marks left by a tool, and which must be considered in the identification of such marks," delineate the differences apparent among compression, friction, and cut marks and set forth a list of such factors which are integral to the formation of specific friction marks, including the vertical and horizontal angles at which the implement is held during its use, divergences in these angles as use continues, differences in pressure during the use of the tool, individual variations in the implement itself, and the medium in which the mark is inflicted. The authors proceed to describe the distinctive effects of the angles on the identifying characteristics of the mark and how these might hinder identification in some instances. A point upon which great emphasis is placed is the fact that the endeavor is not particularly easy, and that the establishment of the absolute identity of a particular tool is not necessarily the goal so much as the degree of likelihood that an implement suspected of being used in a particular act is in actuality the object responsible:

It is . . . commonplace for a defense attorney to attempt to establish that all mass production tools which are apparently identical will therefore leave identical marks, although exactly the reverse has been established many times . . . no two tools will ever be expected to leave identical marks, nor in fact will the same tool ordinarily leave two absolutely identical marks. However, for a considerable period of time, the marks left by a single tool will be so similar as to leave no doubt of their common origin unless some major change is wrought in the edges leaving the marks [Burd and Kirk 1942:684].

Burd and Greene (1948) established a method by which tool marks uncovered during a criminal investigation are analyzed for identity, briefly discussing the differences among impression, friction, and combination friction-impression marks and the conclusions that can be drawn from following the procedure they outline. They used twelve separate cases to illustrate the ways in which their method has been used and the results that were obtained from it in the courtroom setting. Their eleven-step process is easy to replicate and applicable to the scrutiny of tool marks in bone, although it is not assignable to a medium. There are, of course, problems inherent in the application of this method to bone that are not attached to other materials such as wood or metal. The principal issue is that the test material necessary to create the comparative marks called for in Step 8 (Burd and Greene 1948) is in rather low supply, as a rule. The use of anything less than bone in the creation of a test mark, however, detracts from the specificity of the process; the marks will never be fully adequate to compare to bone if they are made in, for example, a synthetic medium that does not interact with the tool in the same manner.¹

Flynn (1957) conducted a study in tool mark identification and discovered that each of one hundred chisels created different and individual markings in test media. He applied the results to a case involving a broken door lock and a "lock puller tool"

¹ It is the purpose of this study that test marks must come as closely as possible to mimicking the state in which the actual marks were inflicted if they are to be of use in a criminal investigation.

suspected of being used to damage it, stating that the scientific discipline concerned with the identification of marks left by tools is an outgrowth of criminalistic study dealing with the firearms identification. This field relies upon the characteristic traits of bullets such as those described by Biasotti (1959). Like knives and tools, bullets possess specialized characteristics that enable identification of the weapon from which they were fired. The most marked trait results from patterns of striations imparted to them by the unique internal structure and any extraneous objects intruding into or part of the gun's barrel (Biasotti 1959). Although such criteria can be enormously helpful in the determination of the identity of a weapon used in a crime, Biasotti reasserts Burd and Kirk's disavowal of an absolute establishment of identity for a particular object in discussing his work with the statistical analysis of these characteristics for two samples fired from separate collections of Smith and Wesson handguns, insisting that his results "should dispel the erroneous conception of the 'perfect match' which is actually only a theoretical possibility and a practical impossibility" (1959:44). From his work, however, the criminalist has discovered that although there are only a few properties that can be considered discriminative, these may be all that are needed to draw an accurate conclusion as to a bullet's identity (Biasotti 1964). In a consideration of the evidentiary role of firearms and tool mark analysis, he points out that while a number of authors have written on these applications of criminal science, very little has actually been done in producing set standards for its use in this capacity, heightening the importance of existing studies and the development of better guidelines toward this end (Biasotti 1964). This lack has not gone unnoticed by others in the field (see Osterburg 1966, Thomas 1967).

Integral to the study of tool marks in any medium is the work of Burd and Gilmore (1968). This work set the stage for a number of identification studies based upon two

sets of characteristics basic to any implement: class characteristics such as make, and individual characteristics such as the variations in striae discussed in firearms identification (Burd and Gilmore 1968; see also Houck 1998)(Figure 1.4). The role of modern mass-production methods is explored in terms of these properties, as the introduction of machinery to the manufacture of tools such as screwdrivers, knives, and the like has had considerable impact on both class and individual characters. The authors counsel the exercise of caution in examining marks for class and individual features, because while the analysis of tool marks has proven itself to be of high importance in criminal justice endeavors, the only way in which it will remain so is in the hands of skilled practitioners who play close attention to these separate groups of traits and the differences between the two (Burd and Gilmore 1968). Andahl's (1978) study of saw marks involves the application of tool mark analysis in investigating defects in both bone and non-biological materials such as wood and metal. After briefly recounting the history of saw mark investigation and surveying their basic characteristics, Andahl

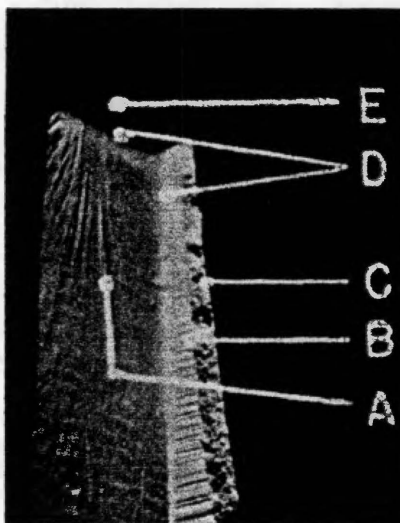


FIGURE 1.4. Class and individual characteristics of a common mass-produced screwdriver as described by Burd and Gilmore (Burd DQ and Gilmore AE. Individual and class characteristics of tools. *Journal of Forensic Sciences* 1968;13:391). Class characteristics include: a, die marks; b, edge cuts. Individual characteristics include: c, broken edge; d, wear marks; e, folded metal.

outlines a general procedure to be used by medical examiners in order to gain greater knowledge of the object used to inflict the wounds and illustrates the use of his method in three short case studies. The three-step plan described by Andahl includes an initial inspection of the tool mark in question for trace elements, striations, and cut direction to determine the general class of the saw used (e.g., wood saw, hacksaw, or coping saw); the creation and examination of test marks with such a blade in order to verify an investigator's determination; and, if possible, scrutiny of the weapon used in the crime.

The forensic anthropologist has the experience of archaeological and other anthropological research to draw upon as well as that of pathologists and criminalists. A significant amount of archaeological research has dealt with the study of cut marks on fossils in two separate pursuits: the differentiation between possible cut marks created by hominids and the remnants of taphonomic events, and the identification of the tools that may have inflicted identified cut marks. By analyzing cut marks on bone, anthropologists determine something of the individuals who created those marks centuries or possibly even millennia in the past (Behrensmeyer et al. 1986; Bunn 1981, 1986; Bunn and Kroll 1986; Potts and Shipman 1981; Walker and Long 1977; White 1986). Bunn (1981, 1986), for example, has interpreted cut marks found on a number of animal bones, marks that he describes as possible defleshing and/or butchering marks bearing some of the traits outlined by Walker and Long (see below) that are characteristic of cut marks inflicted with stone tools (1981, 1986). From this Bunn (1981:576) concludes that

The presence of cut marks and percussion marks on significant numbers of bones documents the involvement of early hominids nearly 2 Myr ago in cutting up animal carcasses and breaking open bones, presumably to obtain meat and marrow. In addition to indicating one use of stone artefacts, this direct evidence of early hominid diet allows us to dismiss models of human evolution which do not incorporate meat-eating as a significant component of early hominid behaviour.

Bunn and Kroll (1986) examined several hypotheses that have been formulated to explain these cut marks, as well as the general structures and formation processes of the artifact assemblages at Olduvai Gorge in Tanzania and Koobi Fora in Kenya. These authors noticed the patterning and positioning of the cuts and suggest that a number of actions were performed on the fossil bones, including "carcass skinning, joint disarticulation, and defleshing" (Bunn and Kroll 1986). Walker and Long (1977) present the methods and results of an experiment considering the creation of butchering marks with chert flake tools and steel knives on bovine metapodials in order to determine what traits characterized the cut marks that would link the marks to their implements of origin. The authors discovered significant differences in depth associated not only with the type of instrument used in the creation of cut marks but also with the capacity in which it was used (e.g., cutting or chopping actions), with steel knives typically creating "V-shaped grooves with straight sides that meet in a distinct apex at the bottom" bearing "parallel grooves," the configurations of which depend upon the angle at which the implement entered the bone cortex (Walker and Long 1977:608-609; see also Potts and Shipman 1981:577). This research may be applied in archaeological settings to better narrow the range of possible tools used at a site as well as the types of activities in which the implements were likely used; but they note the constraints created by the alteration in morphological appearance due to variation in pressures at which an instrument is used (Walker and Long 1977:615-616).² Most authors have concentrated mainly on the traits that are visible at the gross visual and low-power microscopic levels such as those described above. Several scientists, however, have expanded this research by employing scanning electron microscopy (SEM).

² This aspect of cut and tool mark analysis has been encountered previously (Burd and Kirk 1942).

Scanning electron microscopy has become a powerful descriptive and analytical tool.³ Potts and Shipman (1981) first illustrate the use of the SEM in the separation of cut marks inflicted on calcified tissue with lithic tools from marks caused by taphonomic processes such as carnivore activity and marks accidentally inflicted by excavators. In order to address this issue, the authors created a control group with various types of cut marks and taphonomic damage to compare with fossil bone from Olduvai Gorge under SEM study. They concluded that the association of the tools and bones found during archaeological investigations at Olduvai Gorge was the result of early hominids' activities (1981)(Figure 1.5). It is the contention of these scientists that "No process has yet been discovered which produces marks that mimic slicing, chopping, or scraping marks on a microscopic level" (Potts and Shipman 1981:577), suggesting the importance held by SEM technology in investigating cut marks in both archaeological and, more importantly for the study at hand, forensic settings. Shipman and Rose employ SEM in the analysis of a number of cut marks found on fossil animal bones from the Acheulian sites of Torralba and Ambrona in Spain to deduce whether the marks were produced by human butchering activity or carnivore feeding, further demonstrating that while cut marks and other taphonomic residuals including "vascular grooves, rootmarks, carnivore tooth scratches, damage caused by trampling or sedimentary abrasion" (Shipman and Rose 1983:466) appear identical to the eye, they are in fact quite different at the microscopic level. The work of Behrensmeyer et al. (1986), however, refutes this claim. According to these authors, the evidence obtained through the use of SEM, one cannot differentiate between cut marks inflicted by hominid activity and those originating in

³ For a complete discussion of SEM in the study of bone structure, see Boyde 1972.

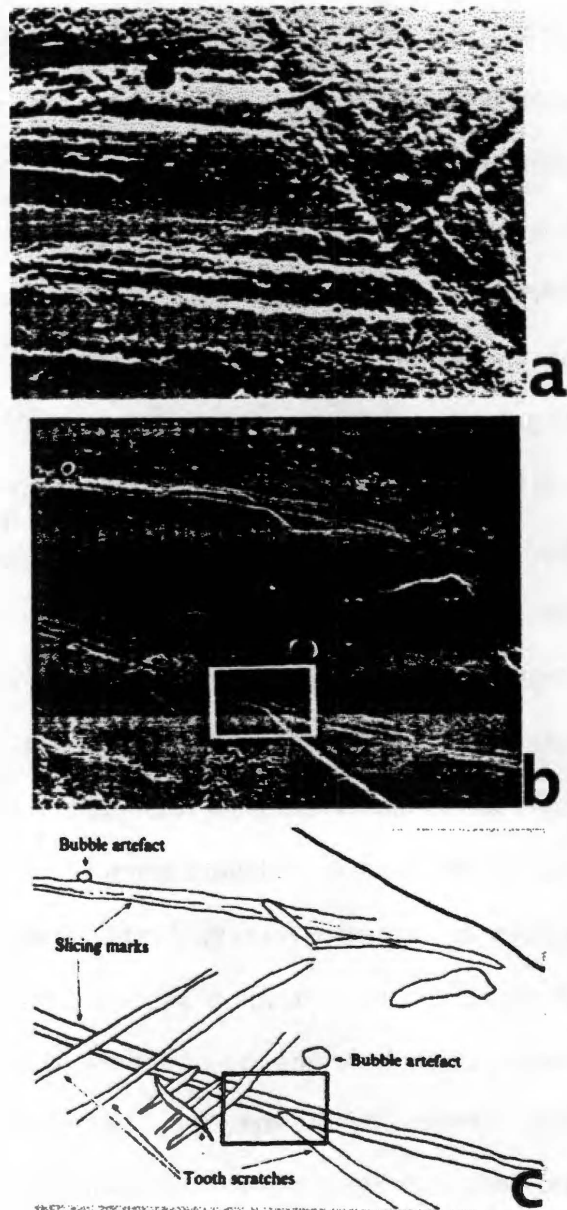


FIGURE 1.5. Cut marks and taphonomic residuals exhibited by fossil bone from Olduvai Gorge. a, slice and scrape marks; b, slice marks running from top left to bottom right, overlapped by later tooth marks (both marks coincide in rectangle); c, tracing of b indicates major aspects. Magnification ranges between x20 - x50. Modified from Potts R, Shipman P. Cutmarks made by stone tools on bones from Olduvai Gorge, Tanzania. *Nature* 1981; 291:580.

other taphonomic processes, preventing them from establishing characteristic features strictly for cutmarks (1986). The authors support this claim by presenting an experiment in which they inflicted trampling damage and lithic slice marks on fresh equine and bovine bones. They replicated the marks and compared them under SEM, discovering that they appeared to demonstrate similarities in morphology both before and after washing, and that the trampling damage can obliterate one of the main characteristics of lithic tool markings, the striae, which further clouds the issue of the origin of marks found on bone. The authors encourage the inclusion of contextual and mark arrangement evidence in considering microscopic analysis of cut marks to yield a better determination of the possible implement or process that created them (Behrensmeyer et al. 1986). Similarly, Blumenschine and Selvaggio (1991) advocate the consideration of the anatomical patterning of marks as an aid in discerning between percussion marks and damage from carnivore activity.

Blumenschine et al. (1996; see also Blumenschine 1995) have eschewed the SEM, citing

its often prohibitive time and financial costs, the consequent limitations these costs impose on assemblage-wide analyses of surface marks, and an over-reliance during diagnoses on the micro-morphology of individual marks at the expense of the mark's context [Blumenschine et al. 1996:494].

According to this research (Blumenschine et al. 1996), extremely reliable identifications of the origin of a given mark — whether it be a taphonomic residual or intentionally inflicted by a human — can be obtained using nothing more than a low-power microscope and/or magnifying lens. They present a blind-study experiment in which several types of marks including knife cut marks, tool marks, and carnivore gnawing were inflicted on long bones and examined at both the macroscopic level and under low-power (16-power) hand lens or microscopic level by both experienced and relatively

inexperienced observers, with nearly 100 percent accuracy obtained in most cases. While they concede that simple macroscopic examination is fallible, the authors insist that careful scrutiny of the bone in question, particularly with a low-power stereo light microscope, is quite sufficient to differentiate among taphonomic marks and those imposed by human modification (1996).

Regardless of the debates raging around SEM, the proponents of techniques integrating this technology into the examination of anthropological evidence have remained undaunted. White discusses the utility of SEM in his examination of cut marks on a cranium found at the Bodo site in Ethiopia, finding that "it is . . . evident that intentional postmortem defleshing of some kind occurred" (1986:508) involving the use of a stone tool. Bromage (1984) presents an experiment in which parietal and occipital bones of young macaques are subjected to abrasion from a variety of agents, including sodium bicarbonate and tribasic calcium phosphate particles, water, several different weights, silicone and epoxy compounds used for casting, and acetic acid. After this abuse, the bones are examined with SEM in order to document the effects of such outside sources on bone surfaces, particularly in regard to bone growth and remodeling studies in the archaeological context. Further demonstrating the use possibilities for SEM technology, Bromage and Boyde (1984) offer the prospect of determining the handedness of the individual who inflicts a particular cut mark through SEM analysis — in this instance, a factor of early hominid activity important in aiding the understanding of the development of brain structure (see also Shipman and Rose 1983a, b). Building on the work of Shipman and Rose (1983a, b) and their own dental research, Bromage and Boyde (1984) discuss an experiment in which they examined under SEM cut marks inflicted with obsidian flakes and bone tools on juvenile and adult cow bones to

determine whether features indicative of directionality are manifested. The authors note several such features:

Bone smears lifted in the opposite direction of the cut were frequently observed We also noted faulting of short segments of bone adjacent to slicing marks in bone specimens with a demonstrable collagen fiber bundle orientation. The faults are oblique to the general fiber orientation, with their ends closest to the center of the slicing mark displaced forward in respect to directionality In certain other bone specimens, chipping away of bone traversing obliquely from the cutmark margin forward of the directionality was a prominent indicator [Bromage and Boyde 1984:361]

Interestingly, the authors also note that "Directionality . . . can be reliably interpreted when the fiber orientation of the segments can be observed to change from the parent fiber array" (Bromage and Boyde 1984:364). This is not the first time the significance of tissue fibers has been demonstrated in the consideration of cut mark analysis. In interpreting these traits, it is important to bear in mind that both the method by which a bone specimen is prepared for SEM analysis and the presence of non-calcified tissue around the bone when the cut mark is inflicted have influence over their final form (Bromage and Boyde 1984). Microscopy promises to be useful in further pursuits aside from the concerns of cut mark morphology. Recently, Love (1998) applied environmental scanning electron microscopy coupled with energy-dispersive x-ray technology to the examination of cut marks inflicted on the bones of domestic pigs with three types of knives with differing blade structures (non-serrated, semi-serrated, and fully serrated) to determine whether elemental compounds characteristic of the knife used in the creation of the marks remain in calcified tissue. Ideally, this would augment the solely morphological identification methods currently being used in the field. Given the nascent state of advancement seen in the microscopic technology, however, it appears that the author's potentially useful goals have yet to be fulfilled.

According to Houck, while the use of SEM in paleoanthropological and forensic taphonomic analysis has proven itself "pivotal," its full potential has not been realized,

particularly in the criminal setting (1998). Echoing Behrensmeyer, he exhorts the following of all avenues of information-gathering in the interpretation of a skeletal injury, including exploitation of SEM technology (Houck 1998). In an effort to expand the understanding of knife-inflicted cut marks on skeletal material, Houck describes an experiment in which cut marks are imposed upon macerated bovine tibiae, deemed by the author as comparable to human bone for this work with three different types of knives in order to determine characteristic traits for individual identification, first by class characteristics and then by individual ones, and develops a procedural guide for the examination of cut marks (Houck 1998). Houck also highlights the analysis of mark directionality via SEM as being important in criminal investigation:

With gross visual examination and anatomical orientation of a cutmark, microscopic determination of cutmark directionality could be of assistance in victim/assailant positioning at the time of the assault. Also, directionality can narrow the examiner's range of test marks for comparison by eliminating from comparison impossible or difficult stab wound trajectories [1998:419].

Houck is not alone in being concerned with the legal importance of the anthropological examination of cut marks. Sauer (1984) presents a detailed discussion of a blunt force/stabbing homicide that illustrates the utility of anthropological analysis in criminal investigation. The paths through which the author determined likely manner of death are clearly explained, and several pitfalls of the analysis of skeletal trauma are pointed out, including the resemblance bone growth and remodeling processes might bear to traumatic lesions. Several suggestions for the examination of possible signs of trauma are also offered, including radiographing of the skeletal material under scrutiny and careful inspection of bone remodeling, healed lesions, and taphonomic residuals.

Unique to forensic concerns in the pursuit of identifying weapons from cut marks in the criminal justice setting is the phenomenon of dismemberment, which ordinarily involves the use of saws. The criminalists Bonte (1975) and Andahl (1978) both discuss

the identification of suspect saws, particularly in crimes involving dismemberment, each dispelling the notion “that saw marks destroy themselves since the marks of the preceding saw teeth would be covered by those of the following” (Bonte 1975:318). The anthropological community has since begun to explore this issue (e.g., Stewart 1979). The work of Symes (1992) constitutes one of the first comprehensive considerations of saw mark morphology in terms of the class characteristics of forty different types of saws (including a serrated steak knife) and the correspondingly differentiated marks they inflict on bone. The serrated knife is included in the saw sample because the blades of serrated knives bear small teeth, though they do not exhibit “set” (Symes 1992:57).⁴ Symes’ research, which this study follows, is designed help determine the identity of a weapon used in a particular criminal action. This was achieved through qualifying trait characteristics of specific tools, using new, unworn, and commonly-used saws in an effort to resolve the previously unmet “need for an improved understanding of the tool creating the characteristics, the principles of tool action in a cut, and the value and potential of residual characteristics remaining after a cut” (Symes 1992:6). Symes et al. (1998) present an overview of saw characteristics including tooth set and size, tooth set patterns, and tooth shape, detailing how each of these affect the cut mark they inflict in bone, illustrating their conclusions with the narrative of a Canadian dismemberment case. The authors are quick to point out that, rather than conceal class characteristics, the to-and-fro movements of a saw in use brings a number of distinctive traits into being in the resulting mark (Symes et al. 1998; see Symes 1992). Additionally, they emphasize the importance saw mark identification holds for anthropologists in medico-legal work:

⁴ Set, defined by Symes (1992:39-40) as “the altering of teeth to reduce binding [that] is an integral and age tested part of saw design,” improves saw efficiency but is not a necessary element.

Contrary to criminalistic hypotheses, forensic contributions of saw marks in bone analyses need be neither limited nor rare. The combined knowledge of osteology and a basic understanding of toolmarks in bone allow anthropological contributions beyond those traditional human bone topics of 'age, ancestry, sex, and stature' [Symes et al. 1998:407-408].

In her consideration of criminal dismemberment, Reichs (1998) describes in detail a procedure for the removal and interpretation of knife or saw wounds in cases where the postmortem dismemberment of the victim is apparent. The author briefly describes several characteristics of injuries to examine in such crimes, including wound size and shape and the presence of striations (see Table 1.2). She also considers additional aspects of dismemberment such as cut distribution, the positions of multiple cuts, and the position of the individuals involved, illustrating various manifestations of dismemberment with the descriptions of six case studies.

TABLE 1.2. Skeletal characteristics of knife wounds, saw wounds, and axe wounds. Modified from Reichs KJ. Postmortem dismemberment: recovery, analysis and interpretation. In: Reichs KJ, editor. Forensic osteology: advances in the identification of human remains. Springfield (IL): Charles C. Thomas, 1998:359.

KNIFE MARKS	SAW MARKS	AXE MARKS
Narrow (\leq blade dimension)	Wide ($>$ blade dimension)	Very wide
V-shape in cross-section	Square in cross-section	V-shape in cross-section
Smooth (or microscopic striations)	Visible striations	Smooth (or microscopic striations)
Striations perpendicular to kerf floor	Striations parallel to kerf floor	Striations perpendicular to kerf floor
Minimal wastage	Moderate wastage	Significant wastage/ fracture/"chattering"

CHAPTER 2

MATERIALS AND METHODS

A BRIEF INTRODUCTION

This study will examine the stab wounds inflicted on the calcified tissue of ribs by six new serrated kitchen knives.⁵ The wounds will be created by stabbing the chests of three euthanized pigs obtained from the University of Tennessee College of Veterinary Medicine. The procedure regulates variables including clothing, in an effort to remain true to the nature of the crime in question, and handedness, the wounds being inflicted by one right-handed and one left-handed "assailant." The necessity of controlling for handedness is seen in the writings of several scientists. Adelson (1974) discusses the assessment of the positions of the players, the handedness of the perpetrator, the force with which the weapon was wielded and resistance it met, the condition of the blade's edge, and the angle as being of highest importance in investigating stabbing and cutting fatalities. Knight (1975) indicates the legal significance represented in such facets of these injuries, particularly estimates of force, stating that this factor is dependent mainly upon the degree of sharpness of the cutting blade, especially the tip, as well as the condition of the skin (see also Green 1978; Spitz 1980). Once the wounds have been inflicted, the affected bones will be processed as necessary to be examined at both the macroscopic and microscopic levels. The cut marks observed are initially inspected at the gross level, providing a basic list of characteristics to proceed to a scrutiny of the marks at a low-power magnification level with typical instruments

⁵ While several colleagues have indicated the likelihood that a murder might be committed with the closest implement at hand rather than a newly-purchased one, a baseline must be drawn to determine those characteristics that are unique to a type of knife, or class characteristics (see, e.g., Burd and Gilmore 1968).

available in most forensic/biological laboratories. The low-power magnification analysis continues to an inspection of the marks using scanning electron microscopy. At each level of this three-tiered investigation, stab wounds are described and photographed, generating an inventory of the characteristics of cut marks inflicted by each knife to efficiently guide forensic anthropologists and pathologists toward a specification of knife class responsible for the perpetration of a particular crime to narrow a weapon search, or if a weapon has been recovered during the course of a homicide investigation, to state with a high degree of certainty its likelihood of being used or not used in a particular crime.

A WORD ON THE KNIVES

The six serrated knives employed in this study and presented in Table 2.1 by brand name, blade length, knife type, retail price, serration pattern, and whether the serrations appear on one or both sides of the cutting edge. Their dimensions are summarized in Table 2.2. Each of these knives possesses similar general traits that are universal features shared by all kitchen knives, as defined by Strung (1976:24-25). They include the following:

The guard, hilt, or bolster is the dividing line between blade and handle . . .

The blade is one piece of steel, but it too has subdivisions. The back or spine of a blade is the unsharpened edge or top of the blade . . .

The primary bevel or blade bevel is that portion of the original steel stock that has been ground down to taper to the cutting edge.

The edge bevel is the true cutting edge; it is the microscopic portion of the leading edge that has been ground and polished until it forms a sharp, clean V.

The point of a knife lies at the tip of the blade. It may take any number of shapes, depending on the function of the tool.

These shared features are depicted in Figure 2.1.

The six knives are divided by manufacturer into three pairs: Farberware,[®] Ekco[™] "Flint," and J. A. Henckels International "Eversharp-Pro."[®] Each pair includes tools of two

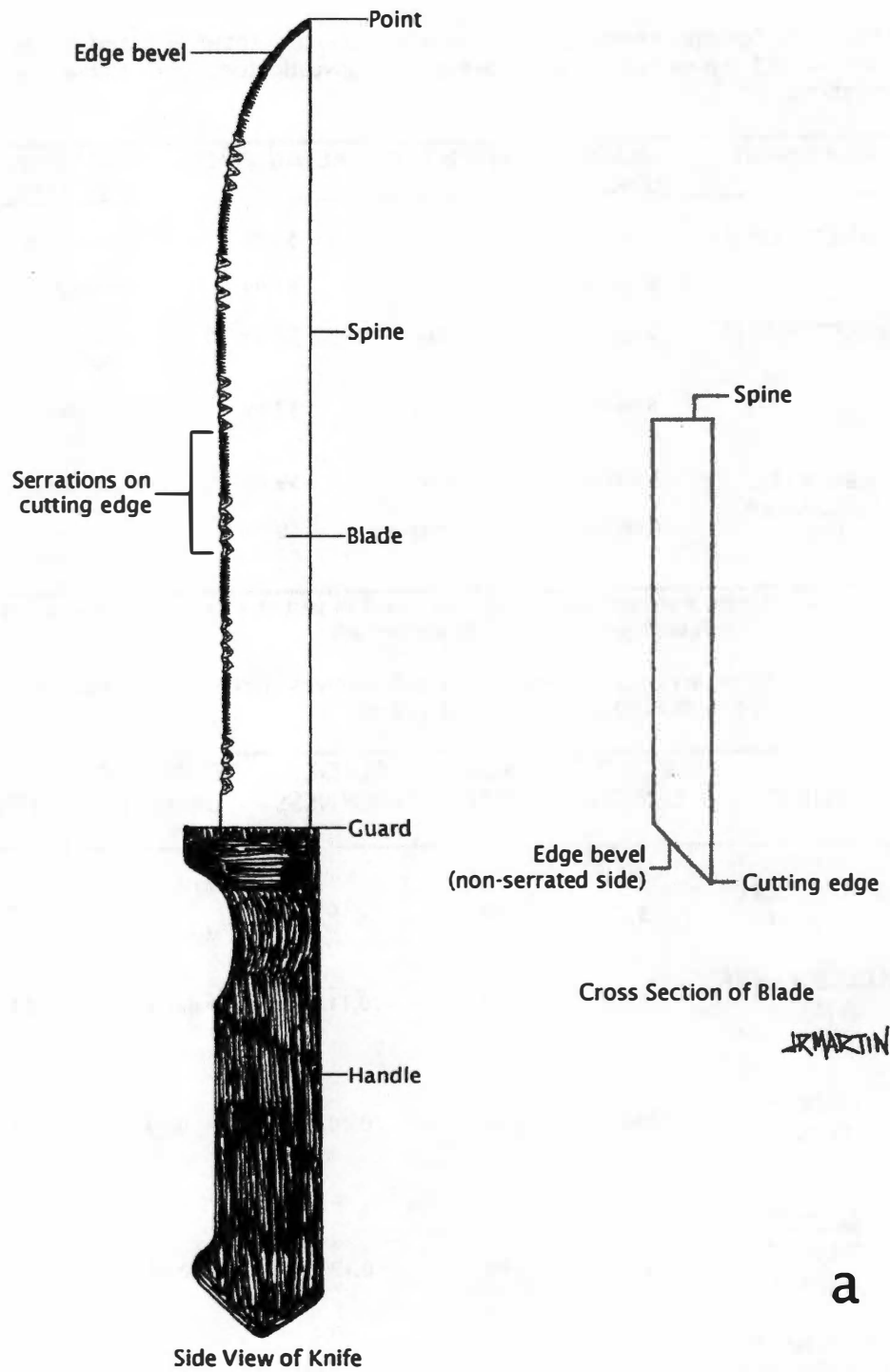
TABLE 2.1. Serrated knives employed in this study, presented by brand, blade length, knife type, retail price,* serration pattern (defined by investigator), and single- versus double-sided serrations.

BRAND NAME	BLADE LENGTH	KNIFE TYPE	RETAIL PRICE	SERRATION PATTERN	SERRATION SIDE
FARBERWARE®	5 inches	Utility	\$9.99	Alternating	Single (left)
	8 inches	Slicer	\$9.99	Alternating	Single (left)
EKCO™ "FLINT"	5 inches	Utility	\$2.39	Constant scalloped	Double
	8 inches	Slicing	\$3.49	Constant scalloped	Double
HENCKELS EVERSHARP PRO®	5 inches	Utility	\$9.99	Constant wide	Single (left)
	8 inches	Carving	\$9.99	Constant narrow	Single (left)

* It is noted that the two Farberware® were purchased as part of a five-pack of knives also including a 3-inch paring knife, a 5-inch boning knife, and an 8-inch chef knife.

TABLE 2.2. Summary of dimensions for serrated knives employed in this study. All measurements except teeth per inch (TPI) are in centimeters (cm).

KNIFE	BLADE LENGTH	BLADE WIDTH	BLADE THICKNESS	SERRATION LENGTH	BEVEL	TEETH PER INCH (TPI)
FARBERWARE® 5-INCH	13.72	1.96	0.10	Major: 0.31	0.26	Major: 7
				Minor: 0.25		Minor: 24
FARBERWARE® 8-INCH	20.25	2.33	0.11	Major: 0.37	0.23	Major: 5
				Minor: 0.28		Minor: 19
EKCO™ "FLINT" 5-INCH	13.0	2.44	0.10	0.23	0.22	7
EKCO™ "FLINT" 8-INCH	20.65	3.06	0.12	0.35	0.18	3
HENCKELS "EVERSHARP-PRO"® 5-INCH	12.95	2.87	0.14	0.15	0.98	8
HENCKELS "EVERSHARP-PRO"® 8-INCH	18.92	3.12	0.19	0.20	1.28	32



a

FIGURE 2.1. Diagrams of the general traits held in common by the collection of knives used in this study, illustrated with the 8-inch implements (not to scale) in side view and blade cross-section. a, general characteristics on the Farberware® 8-inch knife; b, general characteristics on the Ekco™ 8-inch knife; c, general characteristics on the Henckels® 8-inch knife.

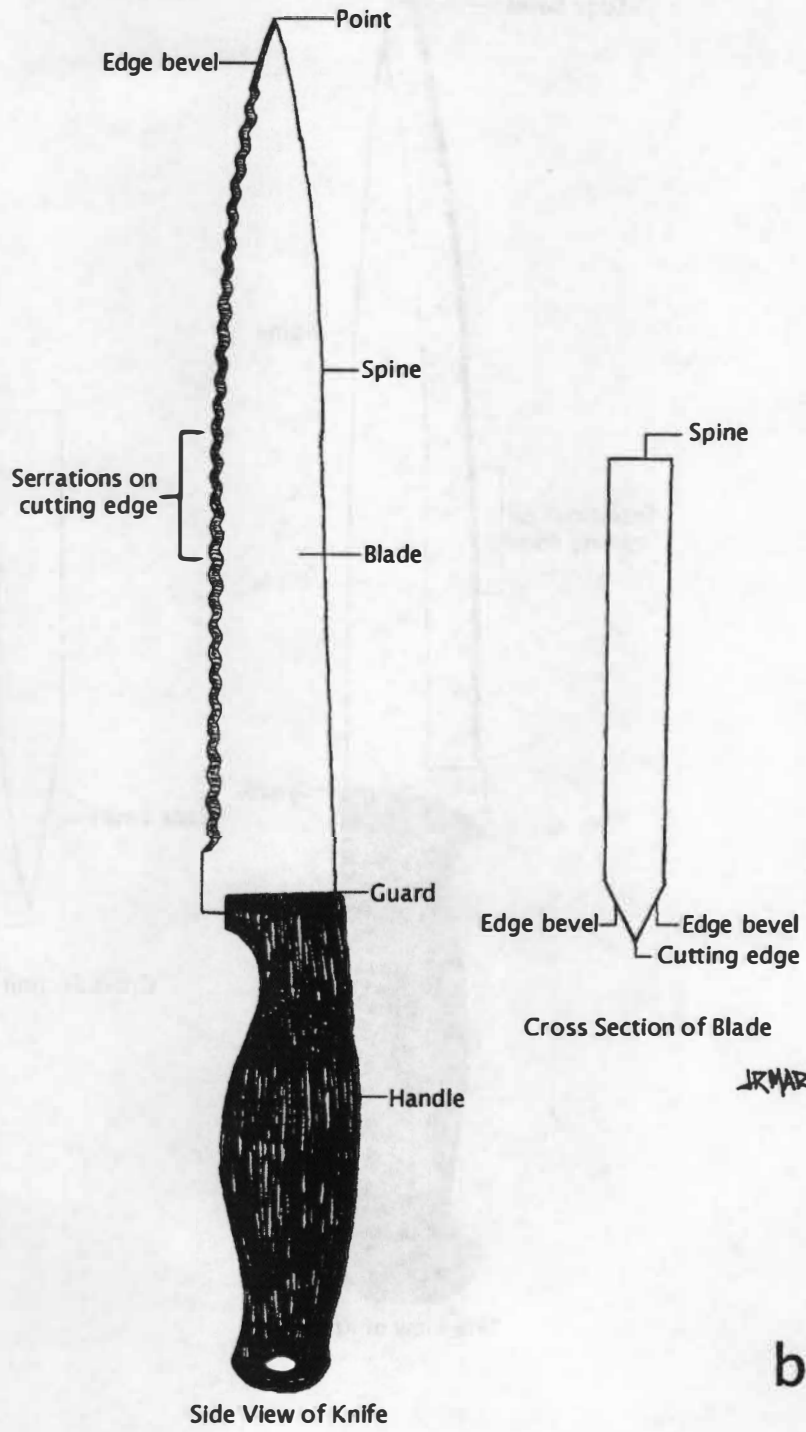


Figure 2.1 (continued).

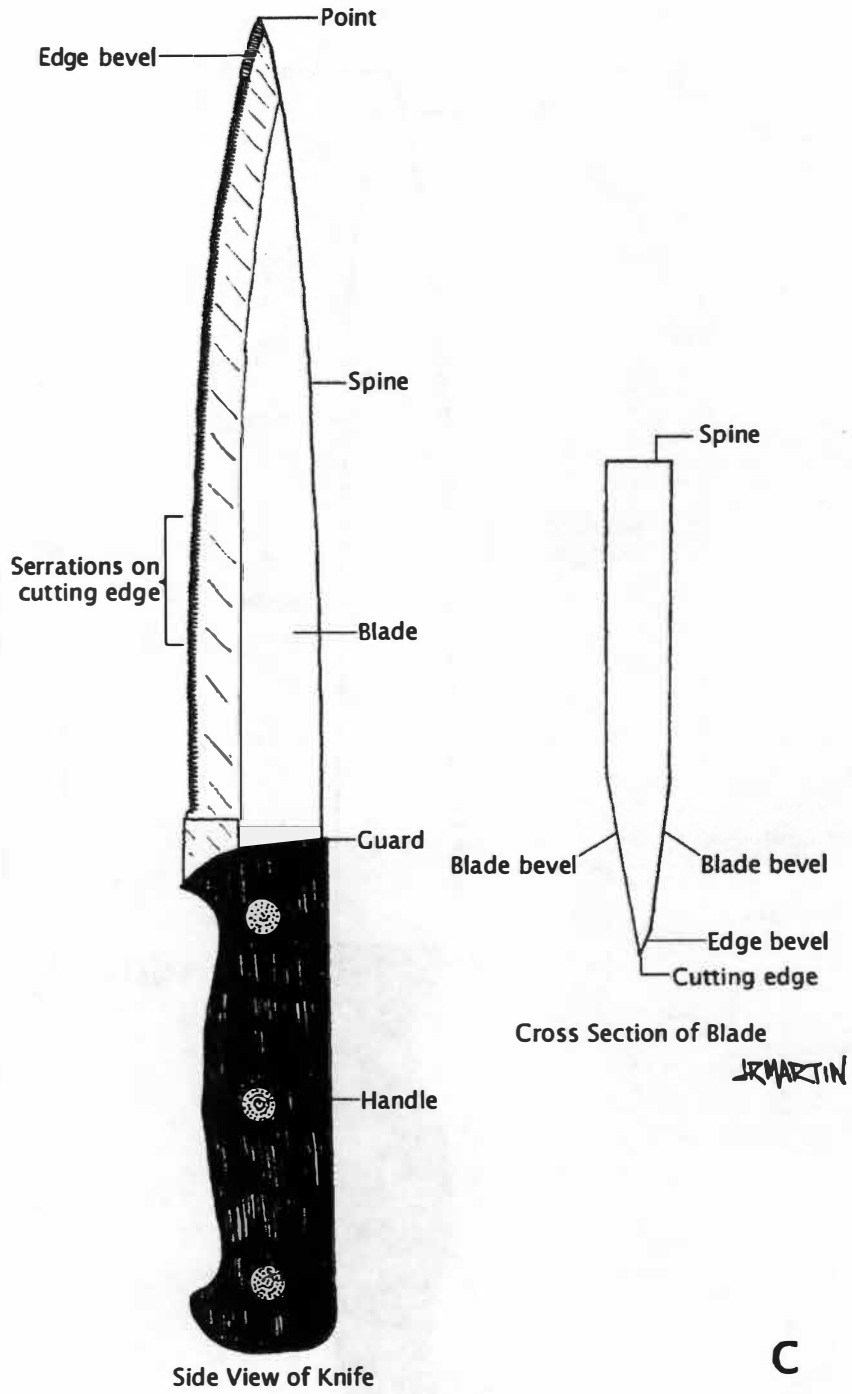


Figure 2.1 (continued).

lengths, 5 inches, which are considered “utility knives” by all three manufacturers; and 8 inches, considered to be “slicing” or “carving” knives by the manufacturers. The retail price for all knives is less than or equal to \$9.99, and one pair of instruments, the Farberware® 5-inch utility knife and 8-inch slicer knife, comprise two-fifths of a cutlery set (\$9.99 for 5 knives) found in both of the stores in which the investigator made knife purchases. Serration pattern, defined by the investigator, considers the structure of the edge of the blade and the pattern in which the serrations appear: “alternating” serration refers to an alternating pattern of wide triangular scallops and straight lines of narrow serrations along the blade edge (Figure 2.2a); “constant scalloped” serration refers to a continuous line of wide rounded serrations along the blade edge (Figure 2.2b); “constant wide” serration refers to a continuous line of wide, semicircular serrations along the blade edge (Figure 2.2c); and “constant narrow” serration refers to a continuous line of narrow serrations along the blade edge (Figure 2.2d). The alternating, constant wide, and constant narrow serrations appear on only the left side of the blades, while the constant scalloped serrations appear on either the left side or the left and right sides the blades, depending upon the knife. The investigator procured these implements in two local stores that are part of highly prolific national chains and were chosen for their accessibility to the majority of the general populace, judged by price and manufacturer-intended usages. Diagrams illustrating the measurements referred to in the following sections are presented in Figure 2.3.

The Farberware® Knives: A Brief Consideration of Class Characteristics

The 5-piece Farberware® cutlery set from which the first pair of knives was obtained consists of a 3-inch paring knife, 5-inch boning knife, 5-inch utility knife, 8-inch slicer knife, and 8-inch cutlery knife, each bearing unique blade structures and serration

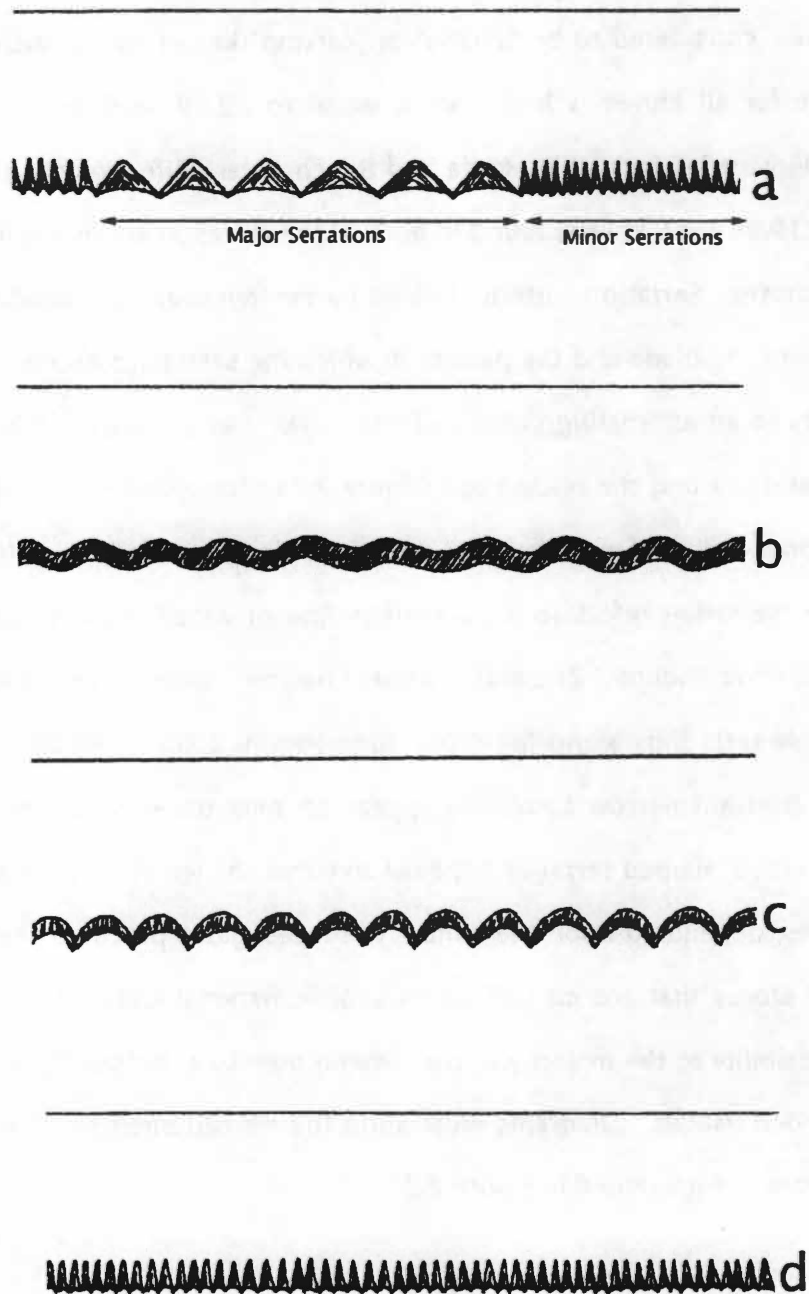


FIGURE 2.2. Illustration of the serration patterns for the three knife pairs under study, as defined by the investigator. a, "alternating" serration pattern as seen in the Farberware® knife blades, with major and minor serrations; b, "constant scalloped" serration pattern as seen in the Ekco™ "Flint" knife blades; c, "constant wide" serration pattern as seen in the Henckels "Eversharp-Pro"® 5-inch blade; d, "constant narrow" serration pattern as seen in the Henckels "Eversharp-Pro"® 8-inch knife blade. Diagrams not to scale.

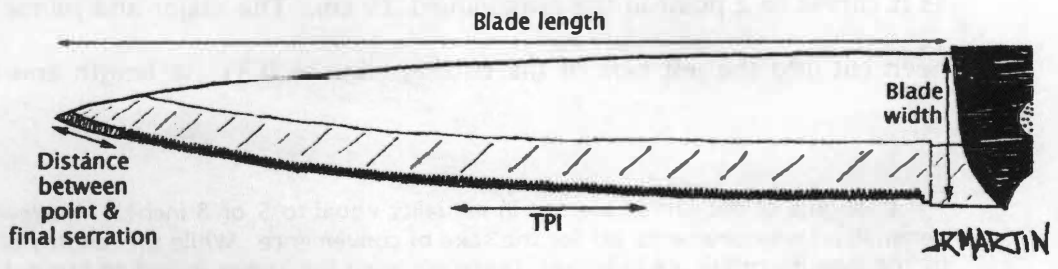
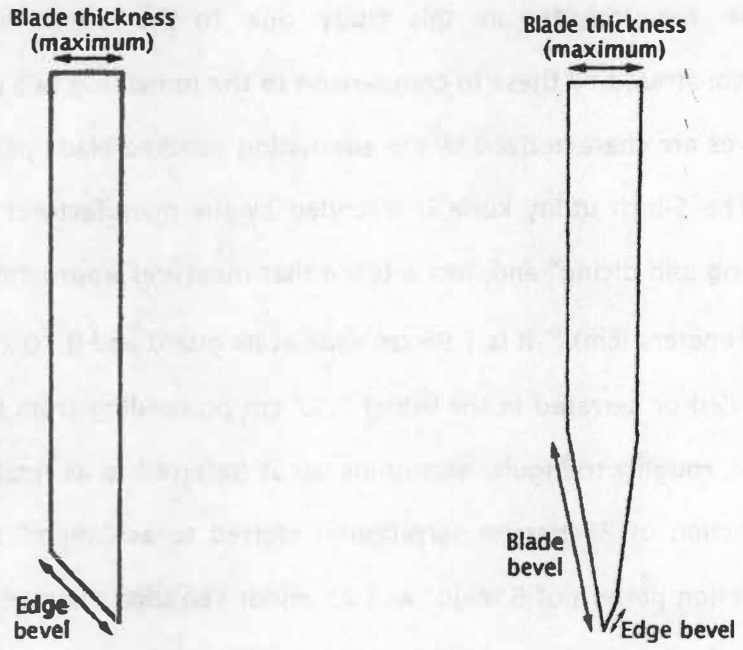
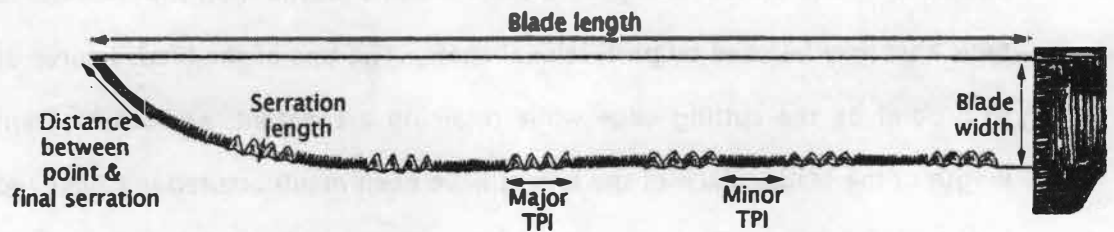


FIGURE 2.3. Diagrams demonstrating measurements discussed for each knife, illustrated with the Farberware® 8-inch (top and middle left) and Henckels® "Eversharp-Pro" 8-inch (bottom and middle right) blades (not to scale).

patterns. These knives have simple black molded plastic “non-slip” handles and are of a type that may be used by professional chefs. The tips of the blades curve up gradually to a point on the cutting edge while retaining a constant, non-tapering spine for the length of the blade. Each of the knives have been manufactured in China and packaged in the United States. The blades are not imprinted with any logos, but the left sides of the handles bear the Farberware® name in raised print. Only the utility knife and slicer knife are included in this study due to the similarities in form and function demonstrated by these in comparison to the remaining two pairs of knives used. These knives are characterized by the alternating serrated blade pattern (see Figure 2.2a).

The 5-inch utility knife is intended by the manufacturer “For all purpose trimming, slicing and dicing” and, has a blade that measures approximately 5.41 inches, or 13.72 centimeters (cm).⁶ It is 1.96 cm wide at its guard and 0.10 cm thick. The blade is not beveled or serrated in the initial 1.52 cm proceeding from the guard, at which point 6 wide, roughly triangular serrations occur (referred to as “major” serrations), followed by a section of 25 narrow serrations (referred to as “minor” serrations). An alternating serration pattern of 6 major and 25 minor serrations is repeated twice more — yielding a total of 3 major serration segments of 7 teeth per inch (TPI) and 3 minor serration segments of 24 TPI — after which the blade becomes uniformly beveled along the edge as it curves to a point in the remaining 1.29 cm. The major and minor serrations have been cut into the left side of the cutting edge to 0.31 cm length and 0.25 cm length

⁶ The lengths of the knives are not in actuality equal to 5 or 8 inches. However, the use of the generalized measurements are for the sake of convenience. While the lengths of the knives given by the manufacturers are in inches, those made on the knives including but not limited to length made by the author have been made using centimeters, and it is these measurements that will be used in the course of this text. Lengths will be given in centimeters and inches in order to demonstrate the discrepancy between the actual lengths of the blades and those given by the manufacturers.

respectively, with the right side blade bevel extending 0.26 cm into the body of the blade.

The 8-inch slicer knife, intended by the manufacturer "For carving and slicing meats and poultry," has a blade that measures 20.25 cm, or approximately 8.18 inches. It is 2.33 cm in width at the guard, and 0.11 cm thick. The first 0.96 cm from the guard is featureless. At this point, 3 major serrations measuring 0.37 cm in length occur, followed by a series of 20 minor serrations measuring 0.28 cm in length. Alternating sections of 4 major serrations and 20 minor serrations are repeated five times along the length of the blade; at the end of the sixth grouping of major and minor serrations, the tip of the blade is curved with a uniform edge bevel. Similar to the 5-inch knife, the major serration segments equal 5 TPI, while the minor serration segments equal 19 TPI. The right side of the cutting edge is beveled to 0.23 cm.

The Ekco™ "Flint" Knives: A Brief Consideration of Class Characteristics

The pair of Ekco™ "Flint" knives is comprised of a utility knife with a 5-inch blade and a slicing knife with an 8-inch blade. Both blades are attached to black molded plastic "comfort grip" handles. On both the knives, the cutting edge and spine taper gradually to a point, giving the blade an extended narrow pyramidal shape. The knives have been manufactured and packaged in China. These "satin-finish" blades bear two imprints: an "Ekco Flint" logo on the left side approximately 1.00 cm from the base, and a "Made in China" statement on the right side approximately 0.61 cm from the base. Unique among this study assemblage, the Ekco™ knife blades are serrated on both the left and right sides of the cutting edge, allowing the knives to "[cut] cleanly without tearing," according to the manufacturer. These knives are characterized by a constant scalloped serrated blade pattern (see Figure 2.2b).

The 5-inch utility knife is considered by the manufacturer to be “perfect for cutting, slicing or dicing.” The length of the blade not including the extra metal below the baseline of the plastic handle measures 13.0 cm, approximately 5.12 inches from guard to tip. The blade measures 2.44 cm wide at the guard and 0.10 cm thick; from this point, it is featureless for the initial 0.77 cm of its length. A continuing line of scalloped serrations is then initiated and continues for the majority of the blade’s length, ending 1.18 cm from the point. An edge bevel is present from the final serration to the blade point, extending 0.22 cm into the body of the blade. As noted, these serrations are cut into both sides of the blade’s edge, measuring 0.23 cm long. Measurements of these serrations yield 7 TPI.

The 8-inch utility knife is alleged by the manufacturer to be “perfect for slicing ham, turkey, roasts.” Its blade measures 20.65 cm, approximately 8.14 inches long from guard to tip, and is 0.12 cm thick. Like its 5-inch companion, the metal of the blade extends slightly into and from the plastic of its handle. At the guard, the blade measures 3.06 cm wide, after which the featureless blade extends for 0.85 cm. From this point, a line of scalloped serrations begins and continues to 1.72 cm from the point of the blade. Between the final serration and the point, an edge bevel exists that extends 0.18 cm into the body of the blade. The serrations are cut into both sides of the blade to a length of 0.35 cm. Measurements of these serrations yield 3 TPI.

The Henckels® “Eversharp-Pro” Knives: A Brief Consideration of Class Characteristics

The pair of “Eversharp-Pro” knives manufactured by J. A. Henckels International is composed of one 5-inch utility knife and one 8-inch carving knife. These knives are of greater heft than the previous two pairs in the study assemblage and appear to be of

more solid construction. The metal of the blades extends the length of the handle as well, riveted into the black molded plastic handles with three stainless-steel rivets for each implement. The blade and spine each taper gradually to the tip, giving the knives an extended triangular shape. Both knives are made in Japan. The blades each bear two imprints: the Henckels "Eversharp-Pro" logo on the left side (1.55 cm on the 5-inch and 2.47 cm on the 8-inch) from the guard of the blade, and a "Japan" imprint indicating its nation of manufacture on the right side (0.15 cm on the 5-inch and 0.080 cm on the 8-inch) from the guard of the blade. Unique to these knives is the differentiation in metal finishing at the edge of the blade, the "satin finish," and the remainder of the blade, the "mirror polish." The knives also differ in the construction of the serrated edges, with the utility knife composed of wide semicircular serrations and the carving knife composed of narrow straight-line serrations; in each knife, serrations exist only on the left side of the cutting edge. These knives are characterized by the constant wide (5-inch) and constant narrow (8-inch) serrated blade pattern (see Figure 2.2c).

The 5-inch utility knife, intended by the manufacturer to be used "For many cutting jobs, peeling, slicing, chopping, carving," in actuality measures 12.95 cm, or 5.10 inches from guard to point, with a width of 2.87 cm at the guard and thickness of 0.14 cm. For its initial 0.70 cm, the blade is featureless; after this point a continuous line of wide semicircular serrations measuring 0.15 cm in length begins, cut into the left side of the blade. This line of serrations ends 0.75 cm from the point of the blade, and measurement of these serrations yields 8 TPI. The "satin finish," which extends just above the margin of the primary bevel, is 0.98 cm wide on both the left and right sides of the blade.

The 8-inch carving knife, intended to be used "For carving roasts and fowl, [and] cutting large vegetables and fruit," measures 18.92 cm, or 7.45 inches in length, is 3.12

cm wide at the guard, and is 0.19 cm thick. The blade is featureless for 0.67 cm from the guard, at which point a continuous line of narrow serrations begins and continues to 1.25 cm from the tip. These narrow serrations measure 0.20 cm long, cut into the left side of the edge. The edge of the primary bevel is defined by an area of "satin finish" measuring 1.28 cm long on both sides of the blade. Measurement of the long row of narrow serrations yields 32 TPI.

A LOOK AT THE BONES

The ribs, which comprise the majority of the calcified tissue in the anterior thoracic area (see Figure 1.1), have been chosen for study due to the fact that they protect the vital visceral organs, the heart and lungs, in addition to the auxiliary blood and air paths associated with them. The data set for sharp force rib defects has been produced from the rib bones of three domestic pigs (*Sus scrofa*, Table 2.3) obtained through The University of Tennessee, Knoxville Agricultural Experimental Station. Such animals are valued in medical research for the high degree of similarity displayed between their biological tissue and that of human beings. Sisson (1921:165-166) describes the ribs of the domestic pig as follows:

The ribs number fourteen or fifteen pairs, of which seven are sternal and seven or eight asternal usually. They are in general strongly curved in the improved breeds, so that there is a fairly distinct angle, except toward the end of the series. The backward slope of the posterior ribs is slight. The first rib is prismatic, has a large sternal end, and a very short cartilage. The width is greatest in the third to the sixth, and the length in the sixth and seventh usually. The tubercle fuses with the head on the last five or six.

Thus the rib of a pig (Figure 2.4), while not identical to a human rib, bears the same general structure and approaches the approximate size of a small-bodied adult human, making its comparability quite useful in forensic anthropological studies.

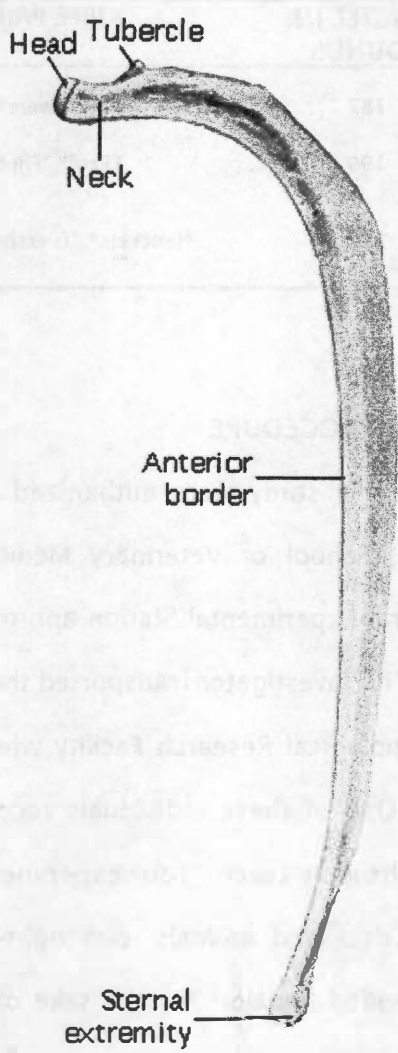


FIGURE 2.4. Illustration of the general structure of the ribs of the domestic pig, anterior edge. From Sisson S. *The anatomy of the domestic animals*. Philadelphia (PA): W. B. Saunders, 1921:166.

TABLE 2.3. Domestic pigs (*Sus scrofa*) employed in this study, presented by weight, knife pair with which injuries have been inflicted, and total number of stab wounds inflicted.

PIG NUMBER	WEIGHT IN POUNDS	KNIFE PAIR	NUMBER OF WOUNDS
1	187	Farberware®	40
2	199	Ekco™ "Flint"	57
3	212	Henckels® "Eversharp-Pro"	57

AN ACCOUNT OF THE PROCEDURE

The animals used in this study were euthanized by a member of the University of Tennessee, Knoxville, School of Veterinary Medicine Clinic and acquired from the University's Agricultural Experimental Station approximately one hour prior to infliction of the first wounds. The investigator transported the deceased animals to the University of Tennessee Anthropological Research Facility where she and four colleagues carried out the procedure. One of these individuals recorded the events in written format, though no photographs were taken. Four experimenters participated in the infliction of stab wounds to the deceased animals: two right-handed females, one right-handed male, and one left-handed female. For the sake of convenience, the porcine cadavers were numbered 1 through 3 and assigned to a particular pair of knives. All stab wounds were administered with the tip of the knife pointing downward and the blade facing the experimenter. Before stabbing commenced, the experimenters used a T-shirt to cover the side to be injured on each carcass (e.g., right side, with the animal lying on its left) in an attempt to re-create a situation most likely to be found in a stab wound fatality (Figure 2.5). The five-inch knives were used to inflict wounds to the upper halves of the thoracic sections, while the eight-inch knives were used to injure the lower halves of the

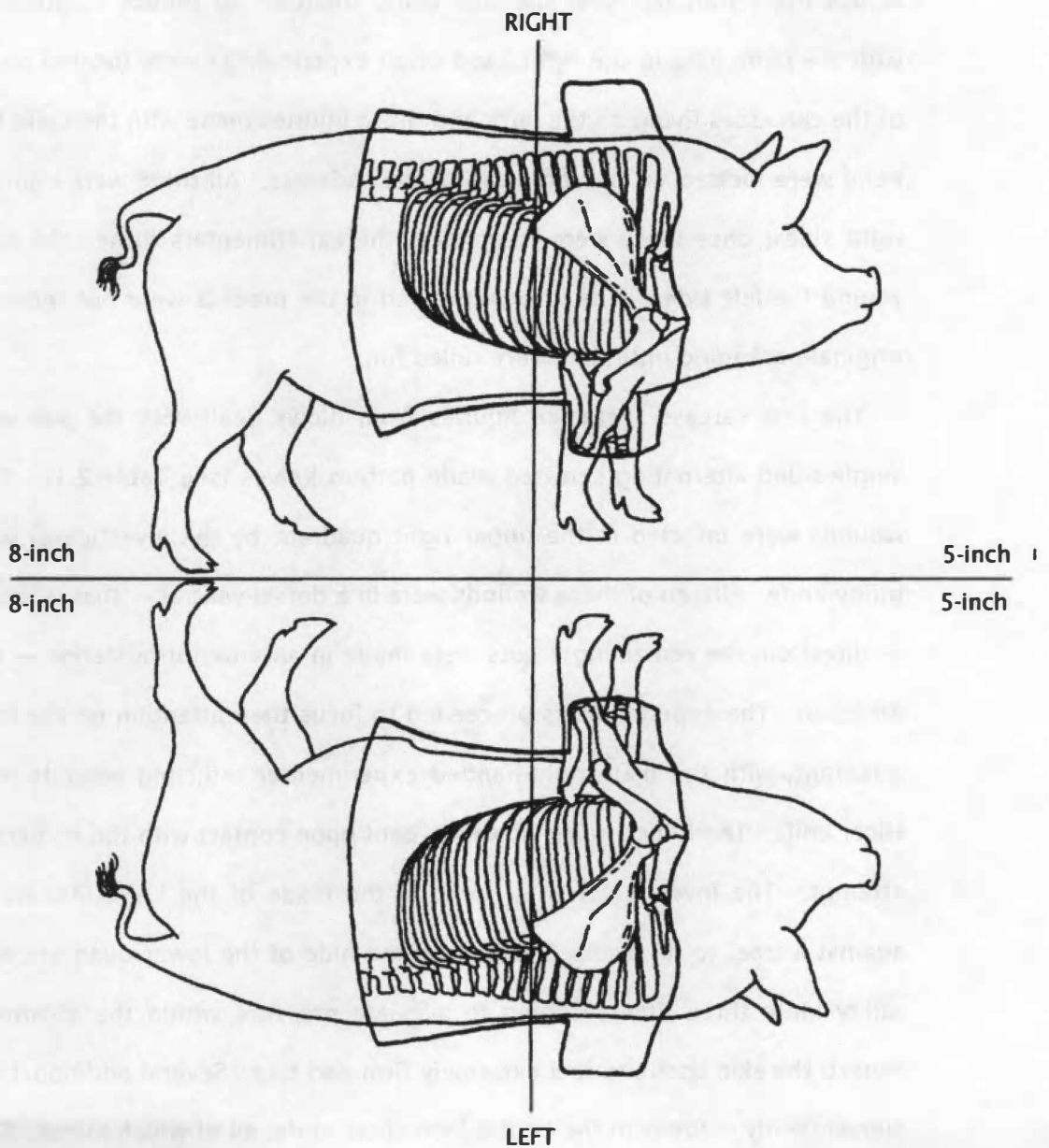


FIGURE 2.5. Body map of pig carcass demonstrating the designation of quadrants by the investigator. The skeletal tissues injured during the course of the experiment are shown within the T-shirt outline.

thoracic sections. The delineation of these two halves was established by a line drawn across the T-shirt lain over the side being treated. To reduce confusion, blows dealt with the knife held in the right hand of an experimenter were located on the right side of the carcasses (lying on the left), and those injuries made with the knife held in the left hand were located on the left sides of the cadavers. All three were injured first on the right sides; once these were completed, the experimenters turned the animals over to wound the left sides. The knives involved in the process were not removed from their original packaging until they were called for.

The first carcass sustained injuries from blows dealt with the pair of Farberware® single-sided alternating serrated blade pattern knives (see Table 2.1). The initial stab wounds were inflicted in the upper right quadrant by the investigator with the 5-inch utility knife. Fifteen of these wounds were in a dorsal-ventral — that is, back to stomach — direction; the remaining 7 cuts were made in an anterior-posterior — nose to tail — direction. The experimenters proceeded to focus their attention on the lower right-side quadrant, with the male right-handed experimenter inflicting wounds with the 8-inch slicer knife. The 8-inch knife, however, bent upon contact with the epidermis in the first attempt. The investigator tried to bend the blade of the knife into its original form against a tree, to no avail. She pierced the hide of the lower quadrant with the 5-inch utility knife three times, hoping to alleviate pressure within the abdominal area that caused the skin tissue to feel extremely firm and taut. Several additional attempts were subsequently made with the bent 8-inch slicer knife, all of which failed. The male right-handed experimenter then inflicted 10 stab wounds in the lower right-hand quadrant originally intended for the 8-inch blade. Given the poor performance of the 8-inch slicing knife, only the upper quadrant of the left side was injured with the 5-inch utility knife by the female left-handed experimenter. This experimenter vigorously inflicted 5

stab wounds with an anterior-posterior orientation. On the fifth stab, this knife bent severely, rendering it unusable in further attempts. The injuries dealt to Pig 1 are summarized in Figure 2.6.

The second carcass received injuries resulting from the use of the Ekco™ “Flint” double-sided constant scalloped serrated blade pattern 5-inch utility and 8-inch slicing knives (see Table 2.1). As with the first carcass, the experimenters inflicted the stab wounds beginning with the upper quadrant of the right side. The male right-handed investigator inflicted four stab wounds with the 5-inch utility knife in an anterior-posterior direction. On the fourth attempt, the tip of the knife broke from the body of the blade and remained embedded in the carcass, likely in bone tissue. On the following stab, the blade shattered entirely, breaking into four pieces and rendering it useless for further attempts. The investigator then proceeded to inflict 14 stab wounds to the lower quadrant of the right side in an anterior-posterior direction with the 8-inch slicing knife, followed by 8 cuts in a dorsal-ventral direction. After placing the cadaver on its right side, the male experimenter inflicted 10 stab wounds in a dorsal-ventral direction and 10 wounds in an anterior-posterior direction in both quadrants of the left side of the animal with his left hand. The left-handed female experimenter, using great force, inflicted an additional 5 stab wounds in an anterior-posterior direction and 5 stab wounds in a dorsal-ventral direction. The injuries dealt to Pig 2 are summarized in Figure 2.7.

The third carcass sustained injuries from the use of the Henckels “Eversharp-Pro”® single-sided constant wide and constant narrow 5-inch utility and 8-inch carving knives (see Table 2.1). Beginning with the upper quadrant of the right side, a right-handed female experimenter inflicted 5 stab wounds in a dorsal-ventral direction. On the fifth stab, the tip of the knife curled to the right but did not break, causing the two

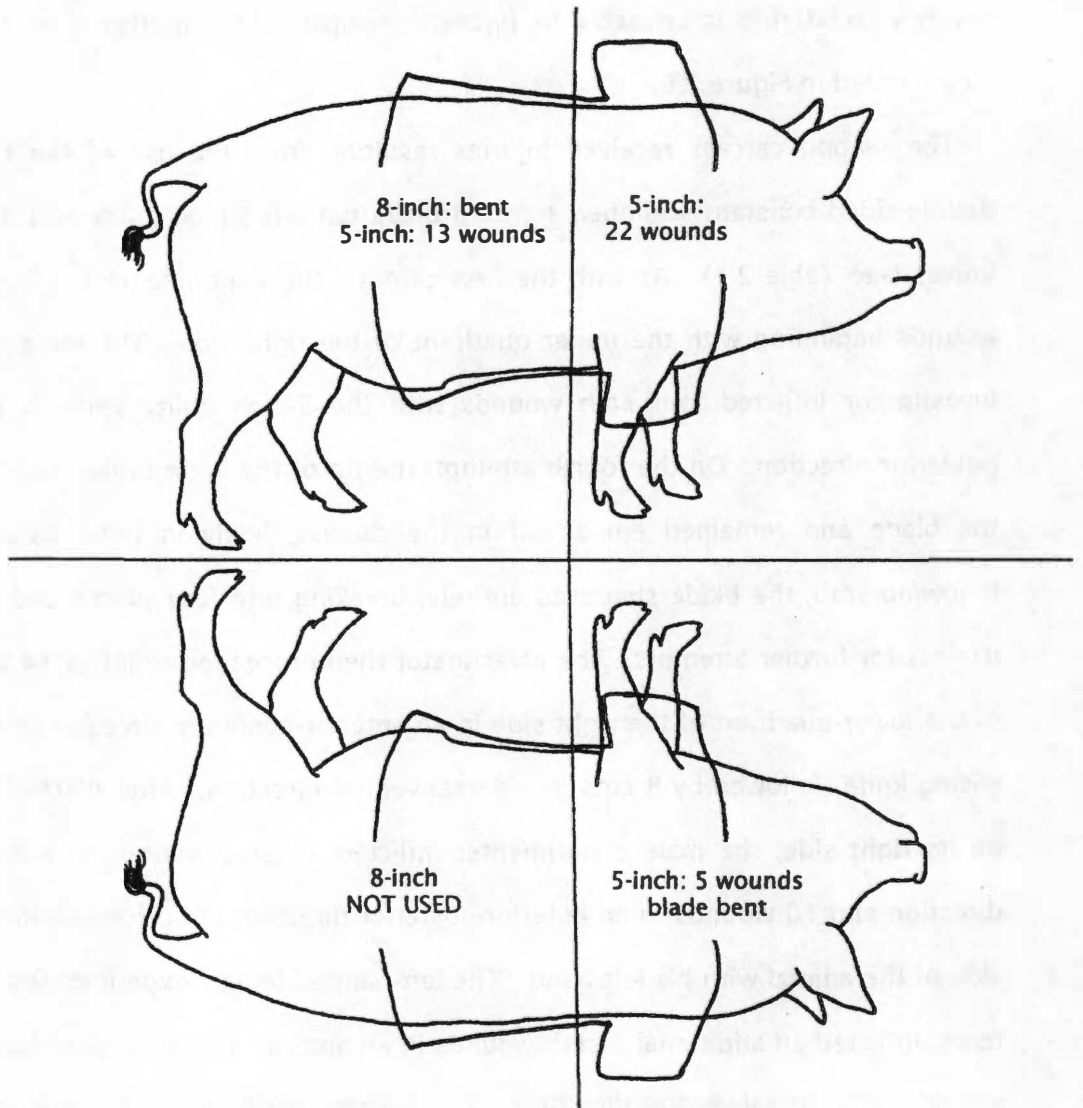


FIGURE 2.6. Visual summary of stab injuries inflicted on Pig 1. A total of 40 wounds were perpetrated by the experimenters on this individual.

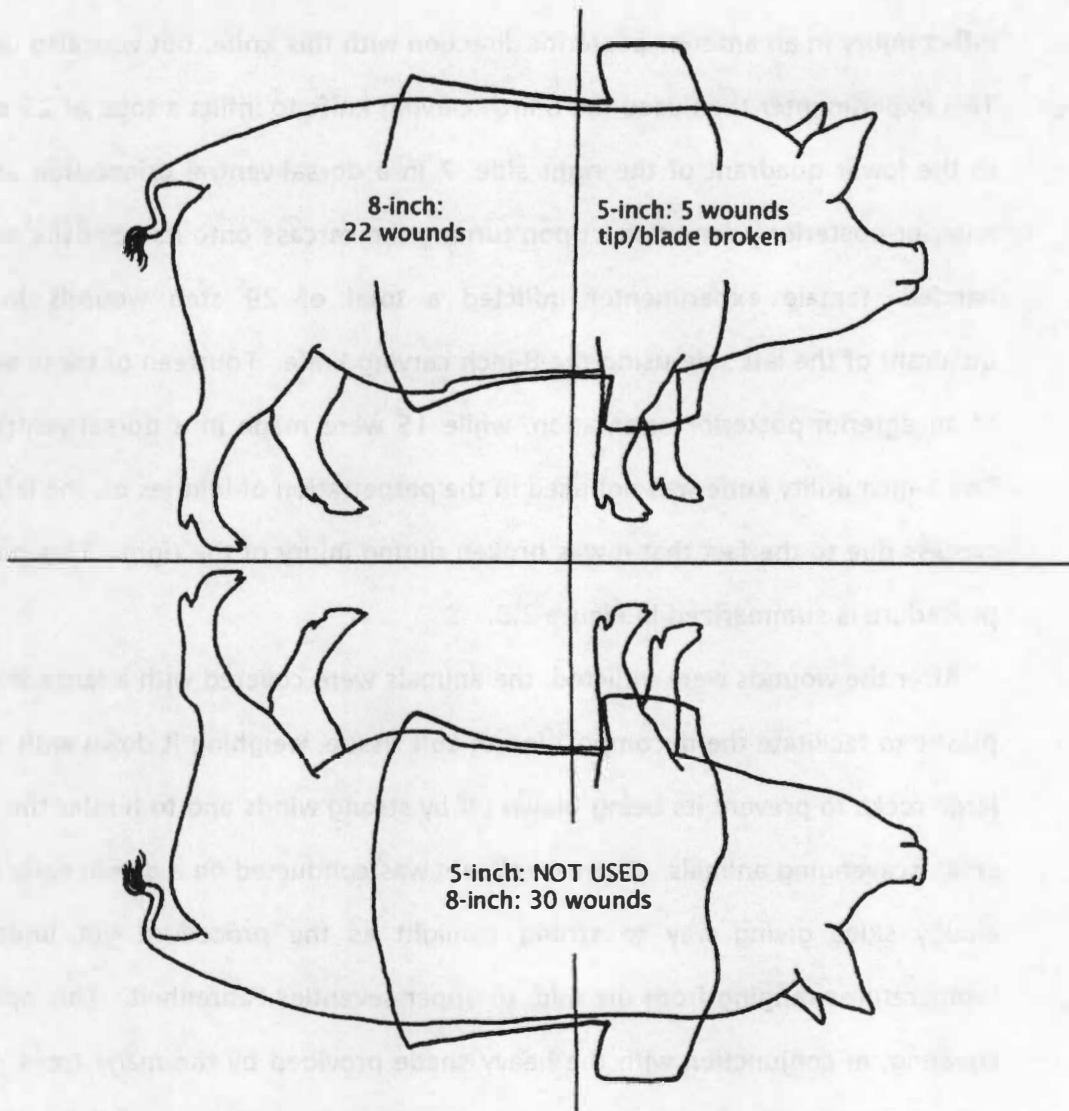


FIGURE 2.7. Visual summary of stab injuries inflicted on Pig 2. A total of 57 wounds were perpetrated by the experimenters on this individual.

subsequent attempts to be unsuccessful. The right-handed male experimenter tried to inflict injury in an anterior-posterior direction with this knife, but was also unsuccessful. This experimenter then used the 8-inch carving knife to inflict a total of 23 stab wounds to the lower quadrant of the right side, 7 in a dorsal-ventral orientation and 16 in an anterior-posterior orientation. Upon turning the carcass onto its opposite side, the left-handed female experimenter inflicted a total of 29 stab wounds in the lower quadrant of the left side using the 8-inch carving knife. Fourteen of these wounds were of an anterior-posterior orientation, while 15 were made in a dorsal-ventral direction. The 5-inch utility knife was not used in the perpetration of injuries on the left side of the carcass due to the fact that it was broken during injury of the right. This portion of the procedure is summarized in Figure 2.8.

After the wounds were inflicted, the animals were covered with a large sheet of black plastic to facilitate the decomposition of soft tissue, weighing it down with a number of large rocks to prevent its being blown off by strong winds and to hinder the activities of small scavenging animals. The experiment was conducted on a day in early spring, with cloudy skies giving way to strong sunlight as the procedure got under way and temperatures ranging from the mid- to upper seventies Fahrenheit. This opaque plastic covering, in conjunction with the heavy shade provided by the many trees surrounding the experiment site and the warm, rainy days intervening between the date on which the experiment was performed and the dates on which the remains were collected, allowed for the near-complete skeletonization of the porcine cadavers (see Bass 1997; Mann et al. 1990). On the 21st day following the experiment, the investigator returned to the scene to begin collecting the skeletal remains of each pig for maceration and analysis by rinsing the remains with water from a garden hose and using a scalpel and metacarpal saw to remove excess soft tissue still clinging to the bones. While some bones retained

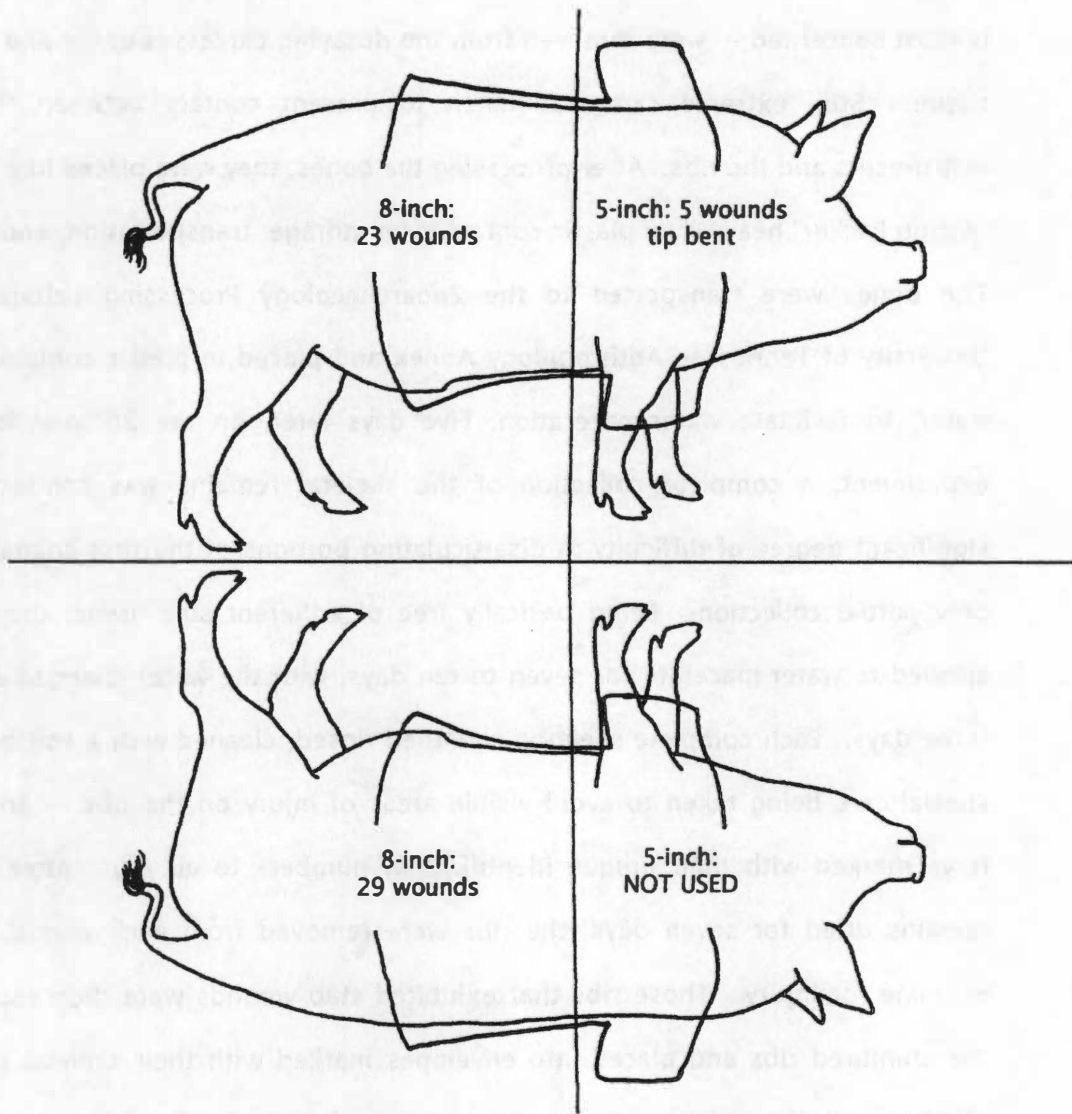


FIGURE 2.8. Visual summary of stab injuries inflicted on Pig 3. A total of 57 wounds were perpetrated by the experimenters on this individual.

a significant amount of adherent soft tissue, the ribs — the bones with which this work is most concerned — were removed from the decaying carcasses easily and with no soft tissue. Still, extreme care was taken to prevent contact between these bladed instruments and the ribs. After processing the bones, they were placed in a Rubbermaid “Action Packer” heavy-duty plastic container for storage, transportation, and maceration. The bones were transported to the Zooarchaeology Processing Laboratory in the University of Tennessee Anthropology Annex and placed in plastic containers with hot water, to facilitate water-maceration. Five days later, on the 26th day following the experiment, a complete collection of the skeletal remains was conducted since a significant degree of difficulty in disarticulating portions of the first animal resulted in only partial collection. Being basically free of adherent soft tissue, the bones were allowed to water-macerate for seven to ten days, with the water changed every two to three days. Each complete skeleton was then rinsed, cleaned with a soft brush — with special care being taken to avoid visible areas of injury on the ribs — and placed on trays marked with their unique identification numbers to air dry. After the skeletal remains dried for seven days, the ribs were removed from each animal to carefully examine for injury. Those ribs that exhibited stab wounds were then separated from the uninjured ribs and placed into envelopes marked with their skeletal identification number and the location, type, and number of wounds. To facilitate examination, isolated section(s) of each rib demonstrating injury were recovered by using a Stryker autopsy saw. Using a permanent marker to indicate sternal (S) from vertebral (V) ends on the bone section, each was labeled to retain injury orientation on the bone. All photographs taken during the visual analysis were taken with a Nikon FM2 55mm camera using a Micro-NIKKOR macro lens. The low-power magnification level of the inspection procedure was performed using a standard-issue biological laboratory

dissecting microscope (Meiji EMZ, Meiji Techno Co. Ltd., Tokyo, Japan) and a Tiffen #4 close-up lens for the Nikon 55mm camera. The SEM portion of the procedure was performed with the extraordinary aid of Dr. David Joy and Justin Hwu at the University of Tennessee Science and Engineering Department and the use of the Hitachi S-3000N Scanning Electron Microscope. All observations were made and photo images taken under the VP-SEM Low Vacuum Mode.

CHAPTER 3

RESULTS

IMMEDIATE RESULTS: THE INJURIES

A total of 45 bone defects in ribs has resulted from the 154 stab wound injuries inflicted on the three carcasses by the experimenters. These injuries are summarized in Table 3.1, which presents the initial verbal description of the location of the stab wounds as well as the dimensions of the wounds, the sizes of the knives used to inflict them, and additional comments offered by way of description. The majority of these are simple knife stab wounds, appearing as an incision into (mainly) the anterior or posterior edges (21 and 22 stab wounds, respectively) of the bones at varying angles. Most of the defects occur toward the sternal ends of the bones (30 stab wounds), while the remainder (10 wounds) occur toward the vertebral end; only a few (5 wounds) appear to be in the midshaft region. Several bones demonstrate very shallow stab wounds instead of or in addition to full stab wounds, giving the impression of slight incisions on the outer bone cortex (Figure 3.1).

Some of the observed injuries are, rather than being simple incision marks, somewhat unique in their presentations. Two of these the investigator considers complex injuries, with the infliction of the stab resulting in significant bone damage. The first of these complex wounds (Figure 3.2a) exhibits a large area of exposed trabecular bone, with the outer cortex forming flaps of bone over the region of internal exposure. While the cortical bone surrounding this injury is highly damaged, no auxiliary fractures are apparent. The second complex wound, however, shows two lengthy auxiliary fractures in addition to two small areas of exposed trabecular bone

TABLE 3.1. List of injuries occurring on bones, by pig number, rib number and side, knife type, general location, applicable measurements in centimeters (cm), and additional comments. Pig identification number is followed by letter to facilitate injury correlation with remaining tables.

PIG	RIB/ SIDE	KNIFE TYPE	LOCATION	DISTANCE FROM STERNAL END (cm)	LATERAL DEPTH (cm)	MEDIAL DEPTH (cm)	COMMENTS
1a	5 th right	Farber- ware® 5- inch	Anterior edge toward sternal end	4.30	0.65	0.20	—
1b	6 th right	Farber- ware® 5- inch	Anterior edge near vertebral end	11.10	0.31	N/A*	—
1c	6 th right	Farber- ware® 5- inch	Anterior edge near sternal end	5.10	0.20	0.15	—
1d	6 th right	Farber- ware® 5- inch	Posterior edge near sternal end	1.91	0.48	N/A	Resembles a puncture wound
1e	7 th right	Farber- ware® 5- inch	Anterior edge just sternal to midshaft	7.48	0.90	N/A	—
1f	9 th right	Farber- ware® 5- inch	Anterior edge toward sternal end	7.00	0.09	0.20	—
1g	9 th right	Farber- ware® 5- inch	Anterior edge toward sternal end	5.80	0.11	0.18	—
1h	9 th left	Farber- ware® 5- inch	Posterior edge toward vertebral end	14.51	0.10	0.59	—
1i	9 th left	Farber- ware® 5- inch	Posterior edge toward vertebral end	13.10	0.28	0.58	—
2a	4 th right	Ekco™ "Flint" 5-inch	Midshaft	7.40	N/A	N/A	Tip of broken knife embedded in rib shaft†

* This indicates that a specific defect does not extend onto a given surface or edge.

† This is the tip from the Ekco™ "Flint" knife that shattered during the portion of the procedure focusing on the second pig carcass. This defect measures 0.60 cm in width on the lateral side and is 0.91 cm from the anterior edge. It has barely broken through the outer cortex on the medial side. This is a unique illustration of the breakage discussed by Green (1978:162; see also Chapter 1, page 3 above for further comment).

TABLE 3.1 (continued).

PIG	RIB/ SIDE	KNIFE TYPE	LOCATION	DISTANCE FROM STERNAL END (cm)	LATERAL DEPTH (cm)	MEDIAL DEPTH (cm)	COMMENTS
2b	4 th right	Ekco™ "Flint" 5-inch	Sternal end	N/A	1.41	1.50	Cut into face of sternal articulation [†]
2c	5 th right	Ekco™ "Flint" 5-inch	Posterior edge near vertebral end	14.20	0.33	1.11	—
2d	5 th right	Ekco™ "Flint" 5-inch	Posterior edge toward sternal end	5.80	0.51	0.88	—
2e	5 th right	Ekco™ "Flint" 5-inch	Posterior edge toward sternal end	2.70	0.20	0.64	—
2f	6 th right	Ekco™ "Flint" 5-inch	Posterior edge at midshaft	8.53	0.09	0.70	—
2g	7 th right	Ekco™ "Flint" 5-inch	Posterior edge toward vertebral end	11.40	N/A	0.94	—
2h	8 th right	Ekco™ "Flint" 8-inch	Anterior edge near sternal end	3.40	0.89	0.95	—
2i	10 th right	Ekco™ "Flint" 8-inch	Posterior edge near sternal end	2.78	0.16	0.30	—
2j	11 th right	Ekco™ "Flint" 8-inch	Posterior edge toward sternal end	5.70	0.40	0.27	—
2k	12 th right	Ekco™ "Flint" 8-inch	Anterior edge near sternal end	1.51	0.42	0.19	—
2l	12 th right	Ekco™ "Flint" 8-inch	Posterior edge at midshaft	8.48	0.30	0.30	—
2m	12 th left	Ekco™ "Flint" 8-inch	Anterior edge toward vertebral end	10.23	0.55	N/A	2 associated shallow cut marks [§]

[†] This lengthy cut mark enters the face of the sternal articulation itself at an angle toward the anterior edge of the rib. It measures 1.43 cm in width across the sternal articulation.

TABLE 3.1 (continued).

PIG	RIB/ SIDE	KNIFE TYPE	LOCATION	DISTANCE FROM STERNAL END (cm)	LATERAL DEPTH (cm)	MEDIAL DEPTH (cm)	COMMENTS
2n	13 th right	Ekco™ "Flint" 8-inch	Posterior edge near sternal end	2.71	0.40	0.24	—
2o	13 th right	Ekco™ "Flint" 8-inch	Posterior edge near sternal end	0.51	0.31	0.25	—
2p	13 th left	Ekco™ "Flint" 8-inch	Posterior edge toward sternal end	3.78	0.40	0.10	—
2q	14 th left	Ekco™ "Flint" 8-inch	Anterior edge toward sternal end	8.99	N/A	N/A	Lies across anterior edge only ^{**}
2r	14 th left	Ekco™ "Flint" 8-inch	Posterior edge toward vertebral end	8.00	2.86	2.78	Complex injury
2s	14 th left	Ekco™ "Flint" 8-inch	Posterior edge toward sternal end	4.25	0.44	0.19	—
2t	15 th left	Ekco™ "Flint" 8-inch	Anterior edge toward sternal end	3.59	0.42	0.32	—
2u	15 th left	Ekco™ "Flint" 8-inch	Posterior edge toward sternal end	1.21	0.62	0.64	—
3a	3 rd right	Hen- ckels® 5-inch	Anterior edge on neck	12.90	0.62	N/A	—
3b	5 th right	Hen- ckels® 5-inch	Anterior edge toward vertebral end	11.09	0.59	0.26	—
3c	10 th left	Hen- ckels® 8-inch	Anterior edge toward sternal end	5.38	N/A	0.50	Extends an- teromedially
3d	10 th left	Hen- ckels® 8-inch	Anterior edge toward sternal end	N/A	N/A	N/A	Shallow cut mark ^{††}

^s Two incision marks are associated with this defect, both on the vertebral side of the injury across the anterior edge; they measure 0.40 and 0.38 cm.

^{**} This cut mark lies only across the wider portion of the anterior edge and measures 0.35 cm in length.

TABLE 3.1 (continued).

PIG	RIB/ SIDE	KNIFE TYPE	LOCATION	DISTANCE FROM STERNAL END (cm)	LATERAL DEPTH (cm)	MEDIAL DEPTH (cm)	COMMENTS
3e	10 th left	Hen- ckels ^o 8-inch	Anterior edge toward sternal end	N/A	N/A	N/A	Shallow cut mark
3f	11 th left	Hen- ckels ^o 8-inch	Posterior edge toward sternal end	3.98	0.51	0.21	—
3g	11 th left	Hen- ckels ^o 8-inch	Posterior edge toward sternal end	3.10	0.55	0.11	—
3h	12 th left	Hen- ckels ^o 8-inch	Posterior edge toward sternal end	3.10	0.29	N/A	—
3i	13 th right	Hen- ckels ^o 8-inch	Anterior edge toward vertebral end	9.71	0.75	0.48	—
3j	13 th left	Hen- ckels ^o 8-inch	Anterior edge toward sternal end	5.19	N/A	0.10	—
3k	13 th left	Hen- ckels ^o 8-inch	Posterior edge near sternal end	1.67	0.58	0.10	—
3l	14 th right	Hen- ckels ^o 8-inch	Posterior edge at midshaft	7.70	0.90 ^{††}	0.31 ^{§§}	Complex injury
3m	14 th left	Hen- ckels ^o 8-inch	Anterior edge toward sternal end	2.50	N/A	N/A	Resembles a “nick” mark ^{***}

^{††} This mark and its two companions below are shallow cut marks occurring just vertebral to the cut mark in the anterior edge, extending across the bone anteromedially. They measure 0.47, 0.38, and 0.30 cm in length.

^{**} This cut mark gives rise to an additional fracture running toward the sternal end and measuring 0.91 cm in length.

^{§§} This cut mark gives rise to an additional fracture running toward the sternal end and measuring 1.38 cm in length.

^{***} This injury resembles a “nick” mark on the lateral side toward the anterior edge measuring 0.50 cm in length.

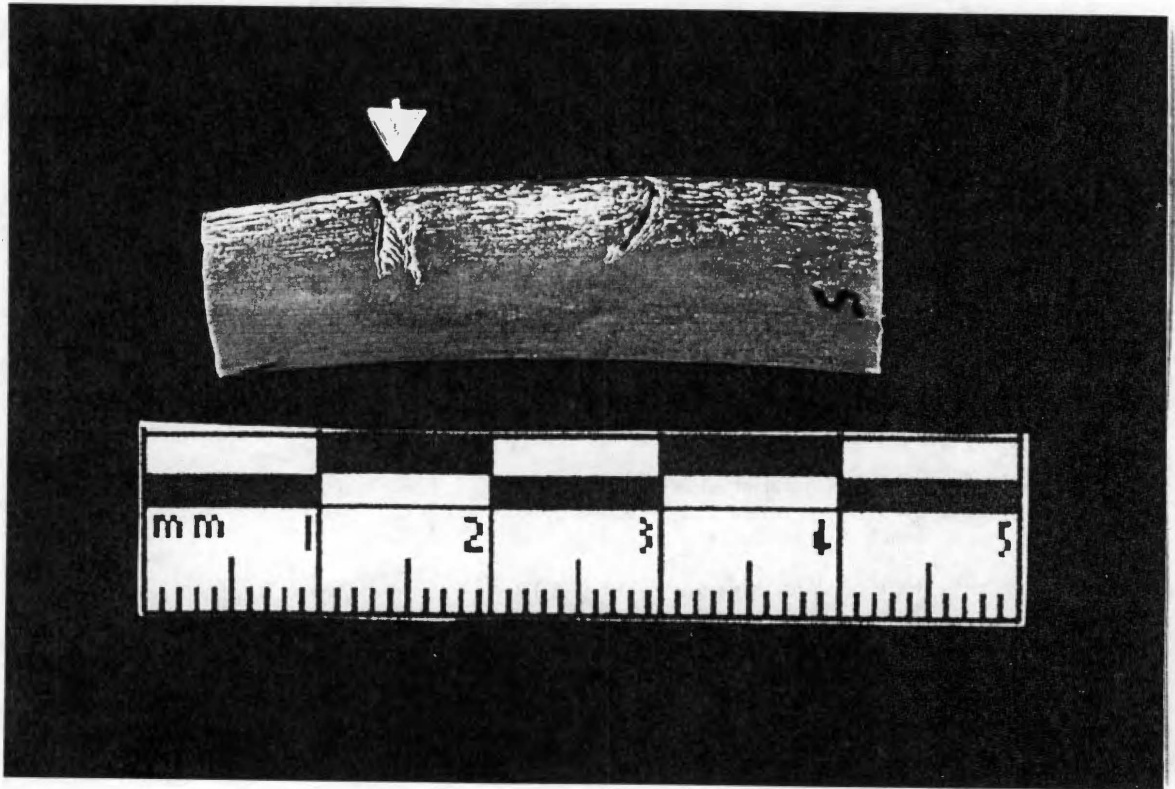
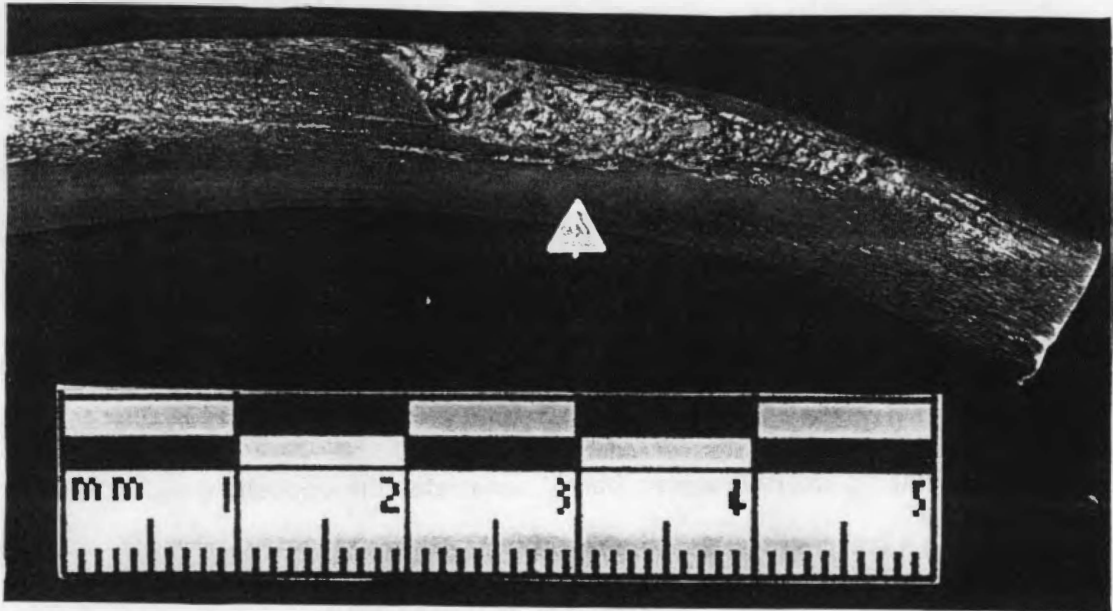
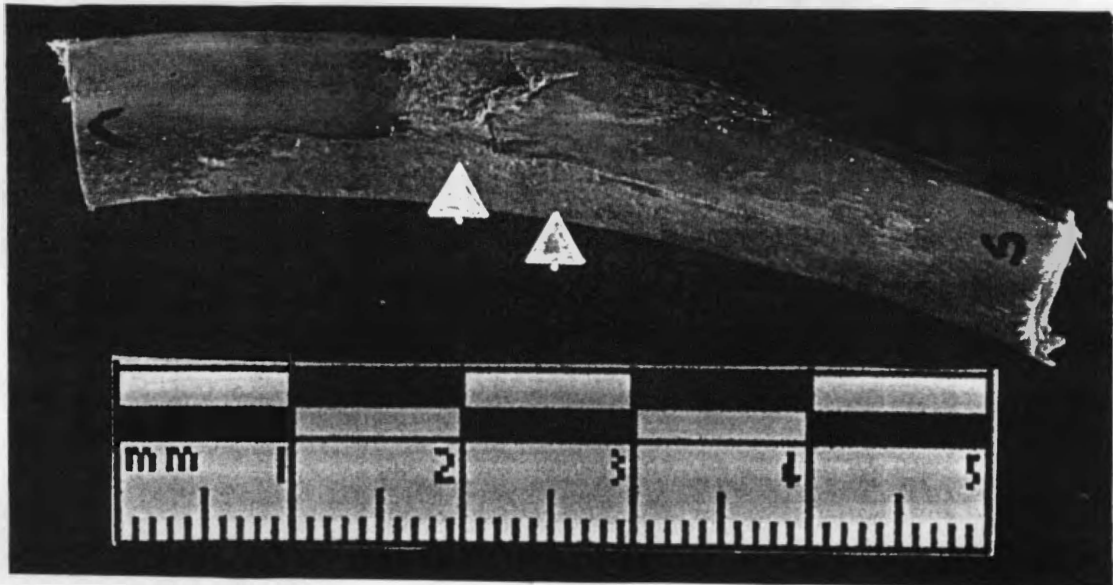


FIGURE 3.1. Example of a shallow stab wound/incision injury. This feature on the anteromedial surface of the tenth left rib of Pig 3, pointed out with arrow, is a small collection of defects consisting of one shallow stab wound, a second extremely shallow stab wound slightly sternal and parallel to the first, and a series of incisions sandwiched between, forming an N shape across the anteromedial surface. Note the pattern reminiscent of a beach being buffeted by breaking waves that is manifested in the incision marks.



a



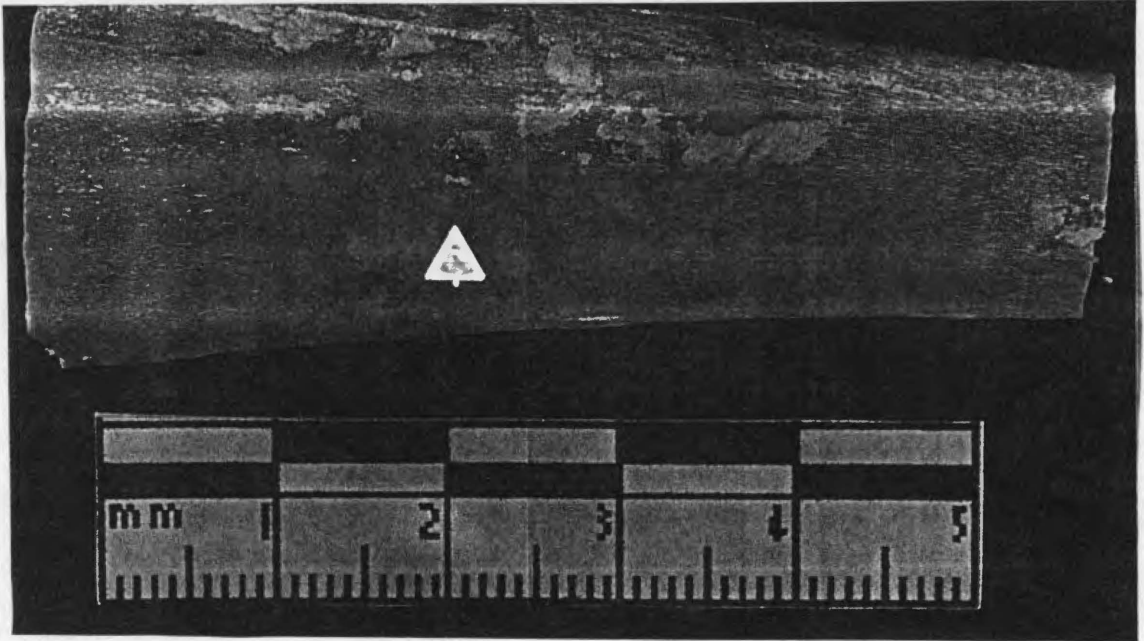
b

FIGURE 3.2. Two complex injuries found among the stab wound assemblage, pointed out with arrows. a, this injury to the fourteenth left rib of Pig 2 extends across the posterior edge of the rib, showing a large segment of exposed trabecular bone; b, this injury to the fourteenth right rib of Pig 3 exhibits not only an area of exposed trabecular bone but also auxiliary fracturing.


(Figure 3.2b). This stab wound extends from the posterior edge of the affected rib deeply into the shaft, generating the regions of bone exposure and two small bony flaps. The cortical bone also shows a small degree of splintering around the edge of the stab wound. Unique among the assemblage is the injury resulting from the shattering of the 5-inch Ekco™ “Flint” blade (Figure 3.3). The tip of this blade, which broke into four pieces during execution of the procedure, remains embedded in the shaft of one rib and transfixes the bone at a slightly obtuse angle. As the blade enters the lateral surface of the bone at an angle, the cortical bone of the entry site has curved around the metal, forming a margin of bone around the broken edge. This edge is completely visible; the tip itself, however, barely penetrates the opposite (medial) side of the bone, creating a cracking convex defect at the exit site.

RESULTS I: VISUAL INSPECTION

The visual level of examination will serve as the foundation from which the succeeding microscopic examinations will advance, and as such its results are outlined extensively. The differences among the knives at this level are quite subtle but can be found relatively easily by a careful observer with a keen eye. As one might expect, outside simple measurements such as length of wound and its distance from a particular point on the bone, little quantitative observations can be made at the visual level; this renders the “eyeballing” process somewhat subjective. A significant degree of interobserver error is clearly expected on this level. It is hoped that as the levels proceed, the amount of predicted interobserver error will decrease. Mainly, the immediately visible characteristics that can be established are the degree of wound edge separation, or width of the stab wound; the amount and locations of bone chipping and splintering accompanying the wound; the amount and locations of lip formation on the edges of



a



b

FIGURE 3.3. The tip of the 5-inch Ekco™ "Flint" utility knife that is embedded in the fourth right rib of Pig 2. a, view from the medial side; b, view from the lateral side. Note that the tip itself barely breaks the cortical surface of the bone; tip pointed out with arrow.

the wound; and the appearance of the wounds' walls. Tables 3.2, 3.3, and 3.4 present each set of knives (Farberware,[®] Ekco,[™] and Henckels,[®] respectively) by rib, type of knife, type of injury, and the wound edge separation, chipping/splintering, lip formation, and wall appearance traits are seen. "Type of injury" refers to whether the injury presents itself as a deep stab wound, a shallow stab wound, a complex stab wound (showing significant damage and/or additional wounds in association), or a nick mark. Typically, stab wounds classified as "deep" extend to a length of approximately 1.00 centimeters on at least one side of the wound (i.e., medial or lateral), with the shortest length at 0.55 cm and longest at 1.50 cm. On the other hand, those marks classified as "nicks" have little measurable depth, being very slight incursions into the outer bone cortex. "Shallow" stab wounds, which are the average throughout the study's assemblage, all demonstrate depths below 1.00 cm (and, for the most part, below 0.500 cm). Each of these properties are herein described qualitatively on the basis of the manner in which the wounds present themselves, and are illustrated with photographs that seem to best exemplify the feature.

Degree of Wound Edge Separation

Degree of wound edge separation refers to the quality of having a potentially quantifiable amount of space interceding between the edges of a stab wound as viewed from the top of the stab wound and is created by the thickness of the knife blade used in a stab wound's infliction. The injuries comprising this assemblage demonstrate varying degrees of wound edge separation, and this characteristic has shown itself to be somewhat diagnostic of knife type at the visual level. In the visual inspection, the wounds exhibit wound edge separation according to the following scale:

Slight: edges of wound appear to be extremely close together and may touch in regions of the injury (i.e., injury is suture-like in appearance)

TABLE 3.2. Summarized results of visual inspection on the rib bones from Pig Carcass 1.

PIG	RIB/ SIDE	KNIFE TYPE	INJURY TYPE	WOUND EDGE SEPARATION	CHIPPING/ SPLINTERING	LIP FORMATION	WALL APPEARANCE
1a	5 th right	5-inch Farber- ware®	Deep cut	Marked	Slight degree of chipping in floor on vertebral edge on medial side	Slight lipping; more marked on vertebral edge	Uneven/ undulating
1b	6 th right	5-inch Farber- ware®	Shallow cut	Marked	Moderate chipping on sternal edge at anteromedial end, and in floor on sternal; edge on anterolateral surface	Marked degree; more marked on vertebral edge	Slightly uneven/ undulating
1c	6 th right	5-inch Farber- ware®	Shallow cut	Marked	Not observed	Slight degree visible on vertebral edge	Straight
1d	6 th right	5-inch Farber- ware®	Shallow cut; looks like puncture	Closed; opens slightly on lateral side	Not observed	Moderate degree visible on sternal edge	Uneven/ undulating
1e	7 th right	5-inch Farber ware®	Shallow cut	Marked	Slight degree of chipping on vertebral edge	Moderate degree on vertebral edge	Slightly uneven/ undulating
1f	9 th right	5-inch Farber- ware®	Shallow cut	Marked	Not observed	Slight degree; more marked on vertebral edge	Straight
1g	9 th right	5-inch Farber- ware®	Shallow cut	Marked	Not observed	Slight degree	Slightly uneven/ undulating
1h	9 th left	5-inch Farber- ware®	Nick	Marked	Not observed	Slight degree visible on posteromedial surface	Slightly uneven/ undulating
1i	9 th left	5-inch Farber- ware®	Nick	Marked	Not observed	Slight degree	N/A*

* The bony flap constituting part of this injury was broken during examination, preventing proper assessment of this trait.

TABLE 3.3. Summarized results of visual inspection on the rib bones from Pig Carcass 2.

PIG	RIB/ SIDE	KNIFE TYPE	INJURY TYPE	WOUND EDGE SEPARATION	CHIPPING/ SPLINTERING	LIP FORMATION	WALL APPEARANCE
2a	4 th right	5-inch Ekco™ "Flint"	Broken knife tip	N/A*	Not observed	Moderate degree on anterior edge of injury	N/A
2b	4 th right	5-inch Ekco™ "Flint"	Deep cut	Marked	Not observed	Not observed	Moderately uneven/ stepped
2c	5 th right	5-inch Ekco™ "Flint"	Deep cut	Moderate	Not observed	Moderate degree apparent on vertebral edge	Moderately uneven/ stepped
2d	5 th right	5-inch Ekco™ "Flint"	Deep cut	Moderate	Not observed	Moderate degree visible on medial surface	Slightly uneven/ stepped
2e	5 th right	5-inch Ekco™ "Flint"	Shallow cut	Moderate	Not observed	Not observed	Slightly uneven/ stepped
2f	6 th right	5-inch Ekco™ "Flint"	Deep cut	Moderate	Slight degree of chipping on lateral floor; moderate degree of splintering on vertebral edge lip	Marked along vertebral edge	Markedly uneven/ stepped
2g	7 th right	5-inch Ekco™ "Flint"	Shallow cut	Moderate	Not observed	Slight degree on vertebral side	Slightly uneven/ stepped
2h	8 th right	8-inch Ekco™ "Flint"	Deep cut	Moderate	Marked degree of chipping on vertebral side in lateral surface	Small degree on medial side of vertebral edge	Moderately uneven/ stepped
2i	10 th right	8-inch Ekco™ "Flint"	Shallow cut	Marked	Not observed	Slight degree on vertebral edge	Slightly uneven/ stepped
2j	11 th right	8-inch Ekco™ "Flint"	Shallow cut	Marked	Not observed	Moderate degree on vertebral side	Moderately uneven/ stepped

* As the tip of the shattered knife blade is completely embedded in the bone, openness and wall appearance cannot be accurately gauged.

TABLE 3.3 (continued).

PIG	RIB/ SIDE	KNIFE TYPE	INJURY TYPE	WOUND EDGE SEPARATION	CHIPPING/ SPLINTERING	LIP FORMATION	WALL APPEARANCE
2k	12 th right	8-inch Ekco™ "Flint"	Shallow cut	Moderate	Moderate degree of chipping on lateral corner of floor	Not observed	Moderately uneven/ stepped
2l	12 th right	8-inch Ekco™ "Flint"	Shallow cut	Marked	Slight degree of chipping in medial floor	Slight degree visible on vertebral edge	Moderately uneven/ stepped
2m	12 th left	8-inch Ekco™ "Flint"	Shallow cut [†]	Marked	Not observed	Not observed	Moderately uneven/ stepped
2n	13 th right	8-inch Ekco™ "Flint"	Shallow cut	Marked	Slight degree of chipping on sternal edge along posterior	Moderate amount on medial side of sternal edge	Slightly uneven/stepped
2o	13 th right	8-inch Ekco™ "Flint"	Shallow cut	Moderate	Not observed	Slight degree on vertebral edge	Slightly uneven/stepped
2p	13 th left	8-inch Ekco™ "Flint"	Shallow cut	Moderate	Moderate degree of chipping on medial floor; some splintering across posterior surface	Not observed	Slightly uneven/stepped
2q	14 th left	8-inch Ekco™ "Flint"	Nick	Moderate	Not observed	Slight degree visible on posterior edge	N/A [‡]
2r	14 th left	8-inch Ekco™ "Flint"	Complex injury [§]	N/A	Not observed, except for splintering of bone into large flap	Not observed	N/A

[†] This cut is flanked by two small, shallow scratches on its vertebral side.

[‡] This wound is too shallow to properly assess this trait at the visual level.

[§] This wound extends across the length of the posterior edge of the rib, with two large flaps of bone overlying an exposed area of trabecular bone. The structure of the wound suggests that the knife most likely entered the rib at a slight angle quite near the posterior edge with great force, causing the bone to splinter into the two flaps and shearing a large portion of cortical bone away.

TABLE 3.3 (continued).

PIG	RIB/ SIDE	KNIFE TYPE	INJURY TYPE	WOUND EDGE SEPARATION	CHIPPING/ SPLINTERING	LIP FORMATION	WALL APPEARANCE
2s	14 th left	8-inch Ekco™ "Flint"	Shallow cut	Lateral surface moderately separated; medial surface markedly separated	Slight amount of chipping visible on medial floor	Not observed	Moderately uneven/ stepped
2t	15 th left	8-inch Ekco™ "Flint"	Shallow cut	Marked	Slight amount of chipping visible on lateral floor	Not observed	Moderately uneven/ stepped
2u	15 th left	8-inch Ekco™ "Flint"	Shallow cut	Marked	Moderate degree of chipping visible the extent of injury	Not observed	Moderately uneven/ stepped

TABLE 3.4. Summarized results of visual inspection on the rib bones from Pig Carcass 3.

PIG	RIB/ SIDE	KNIFE TYPE	INJURY TYPE	WOUND EDGE SEPARATION	CHIPPING/ SPLINTERING	LIP FORMATION	WALL APPEARANCE
3a	3 rd right	Henckels® 5-inch	Shallow cut	Slight	Not observed	Slight degree	Moderately uneven and clean
3b	5 th right	Henckels® 5-inch	Shallow cut	Slight	Marked degree of chipping on floor of wound on medial side, vertebral edge	Slight degree on vertebral edge	Moderately uneven and clean
3c	10 th left	Henckels® 8-inch	Extremely shallow cut/scratch **	Moderate	Moderate degree of chipping on sternal edge	Not observed	Moderately uneven and clean
3d	10 th left	Henckels® 8-inch	Shallow cut††	Moderate	Not observed	Moderate degree on vertebral edge	Moderately uneven and clean
3e	11 th left	Henckels® 8-inch	Shallow cut	Moderate	Moderate degree of chipping present on vertebral edge	Marked degree on both edges	Uneven
3f	11 th left	Henckels® 8-inch	Shallow cut	Moderate	Moderate degree of chipping present on medial floor	Marked degree on vertebral edge (medial side) and sternal edge (lateral side)	Uneven
3g	12 th left	Henckels® 8-inch	Nick	Moderate	Not observed	Slight degree on sternal edge	Slightly uneven and clean
3h	13 th right	Henckels® 8-inch	Deep, lengthy cut	Moderate	Slight degree of chipping in floor on lateral side	Not observed	Slightly uneven and clean
3i	13 th left	Henckels® 8-inch	Shallow cut	Marked	Moderate degree of chipping in medial floor	Not observed	Moderately uneven and clean
3j	13 th left	Henckels® 8-inch	Shallow cut	Moderate	Slight degree of chipping on medial floor	Not observed	Slightly uneven and clean

** This is actually a small collection of defects, manifesting itself in an extremely shallow cut across the anteromedial surface of the bone, another extremely shallow cut across the anteromedial surface slightly sternal and parallel to the first cut, and a series of what appear to be tooth scratch marks sandwiched between, forming an N shape across the anteromedial surface. The second cut shows some chipping on its sternal edge, creating a slightly ragged appearance, but no lip formation.

†† This shallow cut is flanked by 3 shallow incisions in the cortical bone on its sternal side.

TABLE 3.4 (continued).

PIG	RIB/ SIDE	KNIFE TYPE	INJURY TYPE	WOUND EDGE SEPARATION	CHIPPING/ SPLINTERING	LIP FORMATION	WALL APPEARANC
3k	14 th right	Henckels [®] 8-inch	Complex cut ^{**}	N/A	Moderate degree of chipping along sternal edge	Slight degree apparent on both edges	Slightly uneven and clean
3l	14 th left	Henckels [®] 8-inch	Nick	Moderate	Slight degree toward vertebral end	Not observed	Moderately uneven and clean
3m	15 th right	Henckels [®] 8-inch	Shallow cut	Moderate	Slight degree of chipping	Slight degree	Uneven

^{**} Two auxiliary fractures extend toward the sternal end from each side of the floor of the wound, likely a testament to the amount of force used in the infliction of the injury and fragility of the bone. One bony flap has also splintered away from the cut, hanging precariously by slight pieces from the medial surface of the vertebral side of the wound. A small region of exposed trabecular bone has also been cut into the bone at the injury site along the posterior surface.

Moderate: small amount of space apparent between edges of wound

Marked: significant amount of space apparent between edges of wound

If accurately measured, this feature can be used to determine the thickness of the blade used to inflict the injury (Symes 1992), and can reduce the subjectivity attendant to visual evaluation. Measuring this trait, however, can prove difficult in the face of the sometimes extensive chipping, splintering, and lip formation that occurs with serrated knife stab injuries. Measurements of minimum and maximum distances between the stab wound edges (see Symes 1992) were obtained at the low-power magnification level for several specimens (Table 3.5).

The injuries incurred by the Farberware® knife pair demonstrate a significant amount of wound edge separation. All of the 9 wounds obtained from Pig Carcass 1 exhibit a “marked” degree of separation (Figure 3.4). These wounds vary in their depth from 1 deep stab to 2 simple nick marks, with the majority being uniformly shallow stab wounds. All are relatively uniform in their presentations, in that they appear to the observer as simple wounds of varying depth, with one exception. This injury exhibits a mixture of “marked” separation and complete closure, expressing an appearance that seems to indicate puncture of the cortical bone with the blade tip (Figure 3.5). In this case, the tip likely penetrated the outer cortex of the bone, creating the “ballooning out” of the defect visible as it tends away from the posterior edge. A portion of the remainder of the blade likely came into contact with the cortex but did not penetrate it.

The stab wound injuries inflicted with the Ekco™ knife pair exhibit some variability in the amount of wound edge separation visible, exhibiting “moderate” and “marked” degrees of separation. Of the 21 wounds comprising this collection, 10 are classified as showing “moderate” separation and 8 as expressing “marked” separation. Those injuries described as wounds with “moderate” separation, such as the one illustrated in Figure

TABLE 3.5. List of rough measurements of minimum and maximum cut widths (min width and max width, respectively) obtained under magnification. Measurements are in millimeters (mm) and were obtained with the use of a pair of Vernier calipers.

PIG	RIB/ SIDE	LOCATION	KNIFE TYPE	MIN WIDTH (mm)	MAX WIDTH (mm)	DIFFERENCE (MAX-MIN)	GROUP AVERAGE (\bar{x})
1a	5 th right	Anterior edge toward sternal end	Farberware® 5-inch	0.3	0.8	0.5	0.3
1e	7 th right	Anterior edge just sternal to midshaft	Farberware® 5-inch	0.4	0.5	0.1	0.3
1f	9 th right	Anterior edge toward sternal end	Farberware® 5-inch	0.3	0.7	0.4	0.3
1g	9 th right	Anterior edge toward sternal end	Farberware® 5-inch	0.5	0.6	0.1	0.3
2c	5 th right	Posterior edge near vertebral end	Ekco™ "Flint" 5-inch	0.2	0.5	0.3	0.3
2f	7 th right	Posterior edge toward vertebral end	Ekco™ "Flint" 5-inch	0.4	0.5	0.1	0.3
2h	10 th right	Posterior edge near sternal end	Ekco™ "Flint" 8-inch	0.2	0.5	0.3	0.3
2l	12 th left	Anterior edge toward vertebral end [†]	Ekco™ "Flint" 8-inch	0.6	1.0 [‡]	0.4	0.3
2o	13 th left	Posterior edge toward sternal end	Ekco™ "Flint" 8-inch	0.3	0.7	0.4	0.3

* These were calculated separately for each injury group (Fig 1, Fig 2, Fig 3); nevertheless, each group obtained the same answer. Uncorrected averages are: Fig 1, 0.275mm (1.1 + 4); Fig 2, 0.3mm (1.5 + 5); Fig 3, 0.275mm (1.1 + 4).

† This cut wound is accompanied by two narrow, shallow scratch marks parallel to each other and the vertebral edge of the wound. The scratches measure approximately 0.3mm; distance between scratches, 0.5mm.

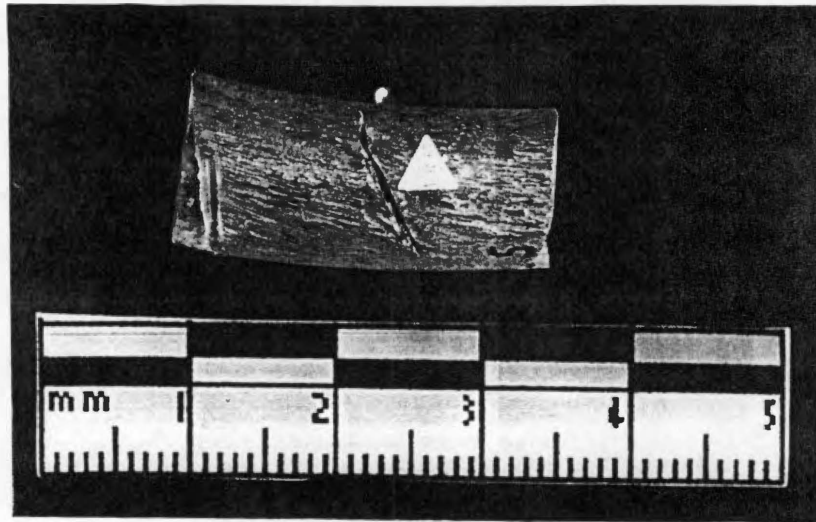
‡ This rough measurement must be taken with caution, however, as it appears under microscopic examination to possibly include 2 small cut marks, or 1 mark with significant tooth or blade jump within the cut.

TABLE A.5. List of rough measurements, continued.

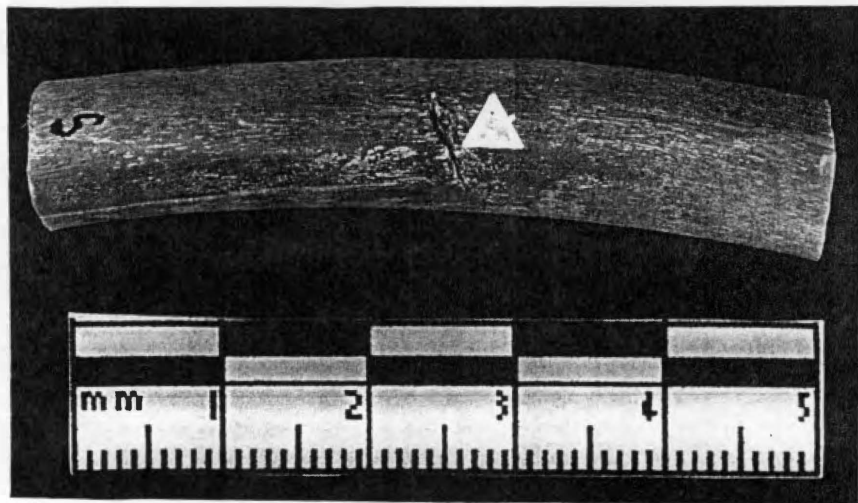
PIG	RIB	LOCATION	KNIFE TYPE	MIN WIDTH (mm)	MAX WIDTH (mm)	DIFFERENCE (MAX-MIN)	GROUP AVERAGE (\bar{x}) [§]
3b	5 th right	Anterior edge toward vertebral end	Henckels® 5-inch	0.2	0.8	0.6	0.3
3d	10 th left	Anterior edge toward sternal end**	Henckels® 8-inch	0.3	0.5	0.2	0.3
3f	11 th left	Posterior edge toward sternal end	Henckels® 8-inch	0.7	0.9	0.2	0.3
3i	13 th right	Anterior edge toward vertebral end	Henckels® 8-inch	0.4	0.5	0.1	0.3

[§] These were calculated separately for each injury group (Pig 1, Pig 2, Pig 3); nevertheless, each group obtained the same answer. Uncorrected averages are: Pig 1, 0.275mm (1.1 + 4); Pig 2, 0.3mm (1.5 + 5); Pig 3, 0.275mm (1.1 + 4).

** In this case, the actual shallow cut mark is measured. The smaller second cut (or largest tooth scratch) is approximately 0.3mm in width; the smaller scratches are approximately 0.1mm in width; and the space between the scratch marks is approximately 0.2mm.



a



b

FIGURE 3.4. Manifestations of a "marked" degree of wound edge separation among the injuries in the Farberware® collection (Fig 1). a, injury to the sixth right rib; b, injury to the seventh right rib. Injuries pointed out with arrows.

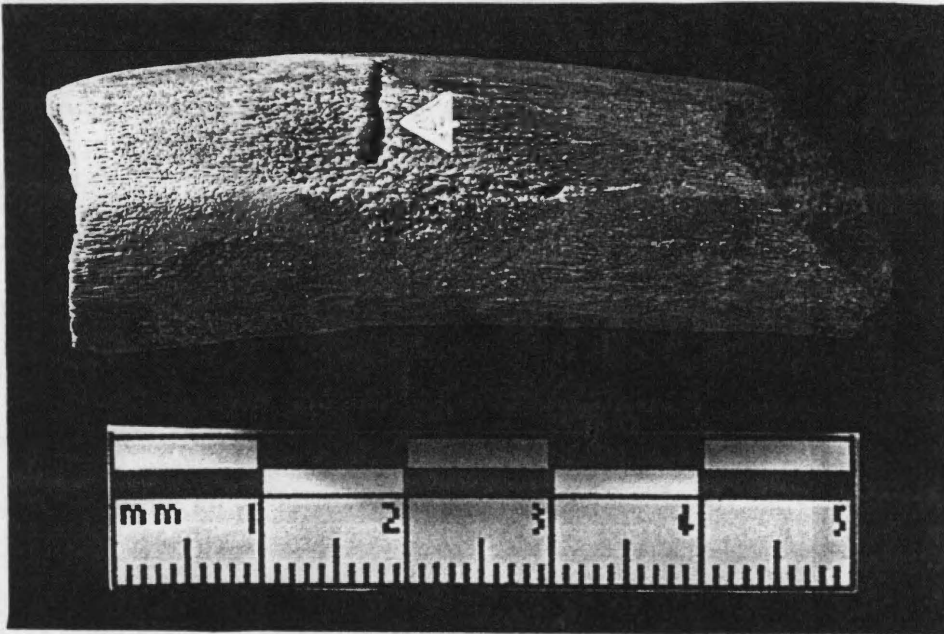
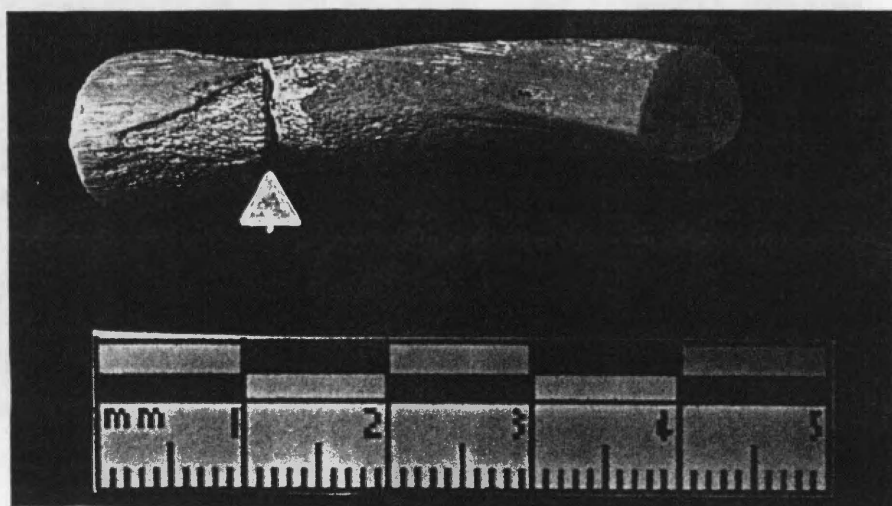
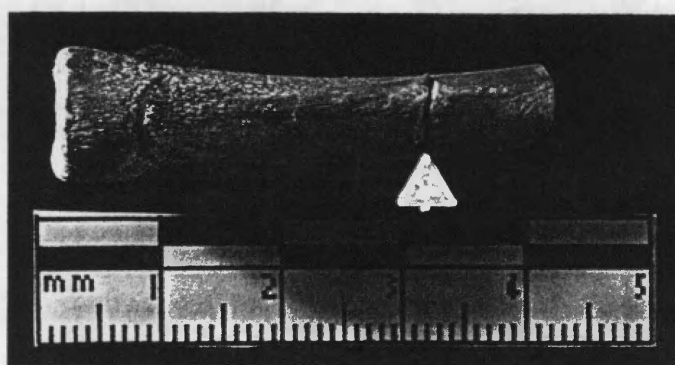


FIGURE 3.5. Apparent puncture wound to the sixth right rib of Pig 1. Note the "ballooning out" aspect of the injury as it tends away from the posterior edge.

3.6a, are, for the most part, shallow stabs or nicks, with only 4 of these injuries showing any extensive depth. Those wounds showing a "marked" degree of separation (Figure 3.6b) are overwhelmingly shallow, with only 1 of the 8 wounds showing depth. While the majority of the assemblage is shallow wounds (13 of 21, as compared to 1 nick, 5 deep stabs, and 3 injuries to which no depth is assigned), a lack of apparent correlation between the two features of depth and wound edge separation is evident in this set. Three of the injuries could not be classified for varying reasons. The first of these is the broken knife tip mentioned above (Figure 3.3). This defect is situated in an angled dorsal-ventral (vertebral-sternal) direction, with the broken blade transfixing the bone. The widest portion, the broken edge of the blade, is visible on the lateral surface of the bone, while the tip of the blade just penetrates the outer cortex on the medial surface. The second non-classified injury is also described above, as the first of two complex stab injuries discovered among the rib assemblage (Figure 3.2a). This defect extends across the posterior edge, with two large flaps of bone overlying an extensive area of exposed trabecular bone. The structure of the wound suggests to the observer that the knife most likely entered the rib at a slight angle quite near the posterior edge with great force, causing the bone to splinter into the two flaps and shearing a large portion of cortical bone away. This makes the depth of the wound rather difficult to measure or even estimate. The third defect that the investigator has not classified according to wound edge separation expresses a mixture of closure and separation (Figure 3.7). While showing itself to be closed along the lateral surface, the edges of this injury demonstrate separation on the posterior edge and medial surface, entering the posterior edge of the bone perpendicularly and opening a large segment of the interior of the wound for examination. Visual observations of this interior show that




a

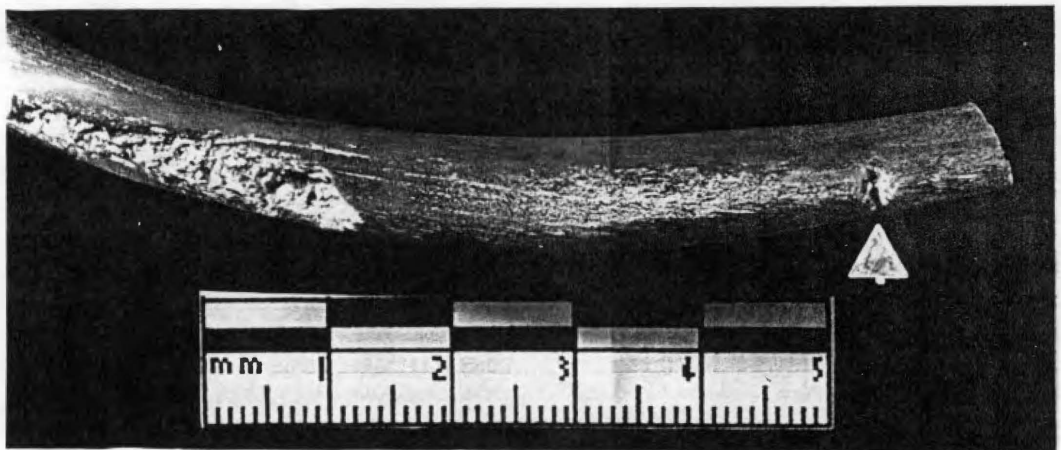


b

FIGURE 3.6. Manifestations of wound edge separation among the injuries in the Ekco™ collection (Fig 2). a, this shallow injury at the sternal end of the twelfth right rib illustrates the "moderate" degree of separation observed in many of these injuries, pointed up with arrow; b, a "marked" degree of separation is seen in this injury to the thirteenth right rib, pointed up with arrow.



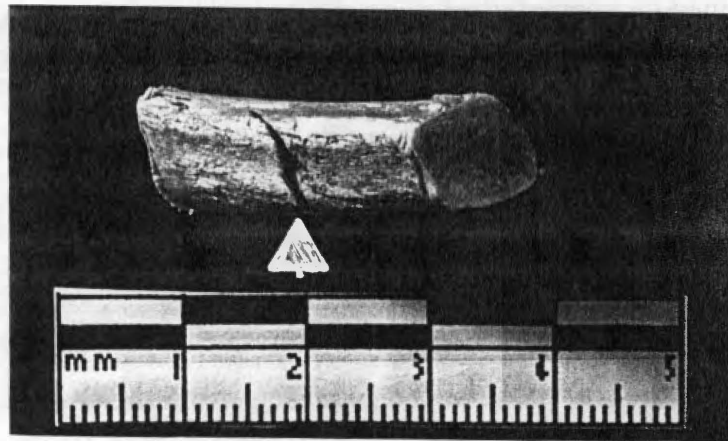
a




b

FIGURE 3.7. Medial and lateral aspects of the fourteenth left rib of Fig 2. While showing itself to be quite narrow along the lateral surface, this injury is open on the posterior edge and medial surface. a, lateral surface; b, posteromedial aspect.

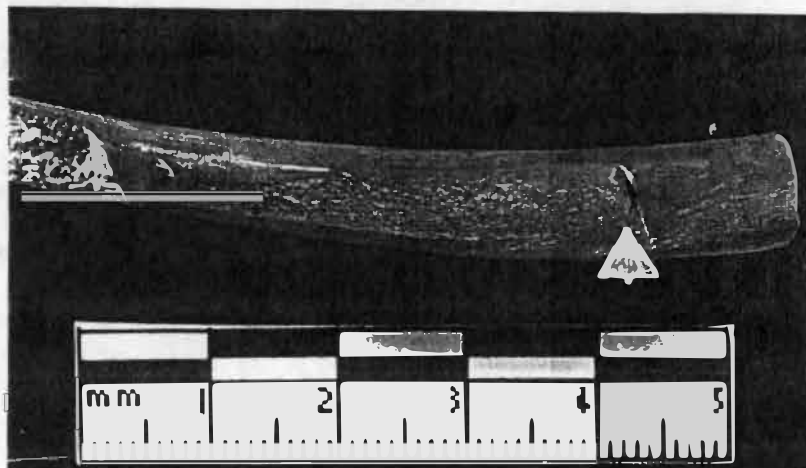
the injury may be composed of two stab wounds rather than simply one, or that the blade jumped during infliction, accounting for its partial expression of separation. In marked contrast to those of the Ekco™ “Flint” set, the injuries inflicted by the use of the Henckels® “Eversharp-Pro” set of knives are quite consistent in their demonstration of wound edge separation. The 13 wounds that comprise this collection do show a range from “slight” to “marked” separation; however, the distribution is heavily skewed in favor of wounds showing a “moderate” degree of separation. Two injuries, both shallow wounds, are classified as showing “slight” separation (Figure 3.8a); 9 injuries — 2 of which are nicks, 6 shallow (1 extremely so), and 1 deep wound — are considered to be “narrow” wounds (Figure 3.8b). Only 1 shallow wound is considered to show a “marked” degree of separation (Figure 3.8c). The overwhelming majority of this collection of injuries are shallow types of injuries — 2 are nick marks, 9 are shallow stab marks (one is extremely shallow), 1 is a deep wound, and 1 is a complex injury — disallowing any immediate observation of a correlation between depth and wound edge separation. Several defects in this group of cut wounds warrant detailed consideration. Two of the injuries showing “moderate” separation are in fact small conglomerates of defects. One of these is mentioned above (see Figure 3.1) as having small incision marks instead of or in addition to stab wounds. The first, seen in Figure 3.1, consists of an extremely shallow stab wound across the anteromedial surface of the bone, another extremely shallow wound across the anteromedial surface slightly sternal and parallel to the first, and a series of incision marks sandwiched between, forming an N shape across the anteromedial surface. These incision marks form a pattern that reminded the investigator of a beach being buffeted by breaking waves, and immediately brings to mind the “constant narrow” serrated blade pattern characteristic of the 8-inch Henckels “Eversharp-Pro”® carving knife. The second conglomerate is similar to the first, with the



a



b



c

FIGURE 3.8. Manifestations of wound edge separation among the injuries in the Henckels® collection (Fig 3). a, this injury to the fifth right rib demonstrates a "slight" degree of separation; b, "moderate" separation is exhibited by the majority of the injuries from Fig 3 is clearly visible in this wound on the anterior end of the thirteenth right rib; c, this injury to the thirteenth left rib, pointed up with white arrow, is the singular injury showing "marked" separation. Injuries pointed up with arrows.

wound entering the anteromedial surface of the rib at a sharply acute angle (floor facing vertebral end) and flanked by 3 light incision marks in the cortical bone on its sternal side (Figure 3.9). The one non-classified injury is the second complex defect discussed above and seen in Figure 3.2b. This wound enters the posterior edge at an acute angle with the floor toward the sternal end of the rib. The two auxiliary fractures extend toward the sternal end from each side of the floor, and one bony flap has splintered away from the cut, hanging precariously by slight pieces of bone from the medial surface of the vertebral side of the wound. The small region of exposed trabecular bone has been cut into the rib at the injury site along the posterior surface.

Chipping/Splintering

Chipping/splintering is defined by the minute damage caused to the cortical bone by the action of the blade stabbing into its outer surface and slicing through. In the stab wound assemblage at hand, the amount of chipping and, in some cases, splintering that is visible is estimated by degrees according to the following scale:

Slight degree: chipping/splintering evident with scrutiny

Moderate degree: chipping/splintering readily seen but only in a small area

Marked degree: chipping/splintering easily seen and extensive

These generally ubiquitous features can be useful in the determination of the directionality of the wound in terms of how the blade entered the bone surface, or the cutting stroke, particularly coupled with the presence of bone shaving; during stabbing, the blade of the knife is pushed into the bone, although great difficulty still lies in the determination of cutting action on the “push stroke” versus the exit (Symes 1992:131-134, 214). The difficulties inherent in the deduction of likely directionality from exit chipping do not necessarily indicate that all is lost, as other features can be employed in

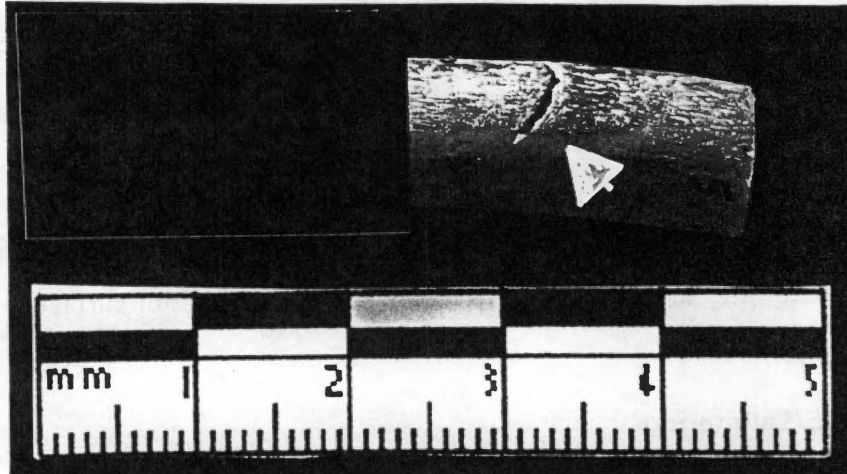
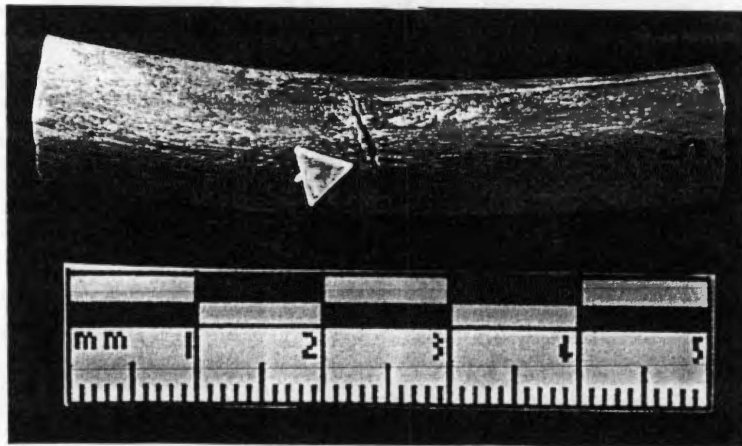


FIGURE 3.9. The second of two defect conglomerates seen in Figure 3.1. This incision enters the anteromedial surface of the tenth left rib at a sharply acute angle, with the floor facing the vertebral end of the rib. Several incision marks are visible at the sternal boundary of the wound, and are pointed up with white arrow.


this endeavor; we shall return to this point below. Among his diminutive collection of serrated knives, Symes (1992:178) observed that “minimal chipping” appeared along the kerf borders; and although the exit chipping he describes was not visible some chipping occurred at the entry point of the kerf where the side of the cutting blade that was not beveled came into contact with the bone.

Generally, the stab wounds generated with the use of the Farberware® knife show little chipping or splintering, even in the entry or exit regions of the defects. Only 3 of the 9 wounds obtained from the use of this pair show any chipping, ranging from “slight” to “moderate.” The presence of any chipping is somewhat surprising, however, as the blade is beveled on both sides, even though the teeth are only built into its left side. This may indicate, rather than being the result of the non-beveled side of a blade coming into contact and pushing through the outer bone cortex (see Symes 1992), chipping (even exit chipping) may result from the non-serrated side of the blade coming into contact with the cortical bone — a very subtle but important distinction.⁷ The first wound exhibits the “slight” degree of chipping described above (Figure 3.10a). This shallow wound demonstrates the extent of this chipping is along its vertebral edge. The second injury, which also shows a “slight” degree of chipping, is depicted in Figure 3.10b. This cut wound, which is open and deep, enters the anterior edge of the rib at an approximate 90° angle and presents itself mainly on the lateral surface of the bone. It is on the small portion of the injury visible on the medial surface, however, that a “slight” degree of chipping is visible at the root of the wound on the vertebral edge. The third injury displays a “moderate” degree of chipping (Figure 3.10c). This shallow, open


⁷ This pattern will continue as the visual analysis progresses with the remaining two knife pairs, for in fact none of the knives used in this study has a non-beveled side to their cutting edges.



a



b



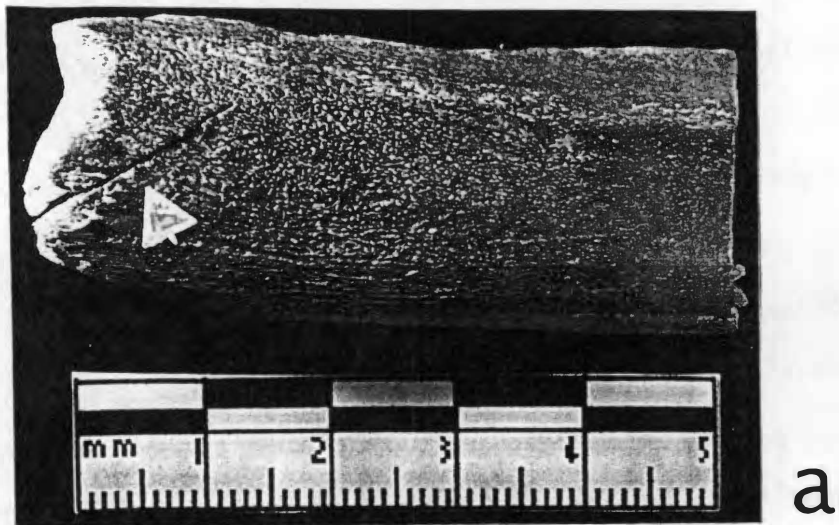
c

FIGURE 3.10. Manifestations of chipping and/or splintering among the injuries in the Farberware® collection (Fig 1), pointed out with white arrows. a, a "slight" degree of chipping is visible in this stab wound to the anterior edge of the seventh right rib midshaft region; b, this injury to the fifth right rib demonstrates a "slight" degree of chipping; c, a "moderate" degree of chipping is visible in this wound on the sixth right rib.

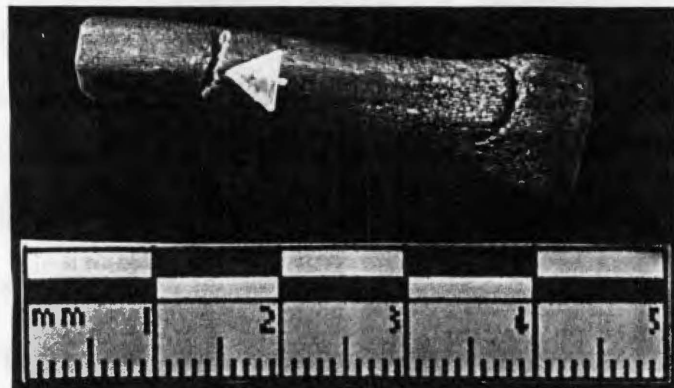
wound, which enters the anterior edge at an acute angle, expresses this chipping on the sternal edge of the injury at both the anteromedial and anterolateral sides of the floor.

The injuries inflicted with the Ekco™ “Flint” pair of knives exhibit similar variation seen in these injuries when the wound edge separation feature was considered, ranging from no visible chipping or splintering to a “marked” degree. Just over half of the 21 wounds that compose this subclass (12 injuries) show no chipping or splintering at the visual level, while 5 show a “slight” degree, 3 show a “moderate” degree, and 1 shows a “marked” degree. The deep incision into the face of a sternal articulation photographed in Figure 3.11a is an excellent example of the complete lack of chipping or splintering observed in most of these injuries. In contrast, the markedly separated, shallow wound in Figure 3.11b demonstrates the “slight” degree of chipping seen in several of the Ekco™ specimens. One of the wounds classified as exhibiting a “moderate” degree of chipping also shows some splintering (Figures 3.11c, d). The shallow wound enters the bone approximately perpendicularly to the posterior surface, presenting chipping in the section of the wound floor visible on the medial side. Splintering is visible as well, on the portion of the injury extending across the surface of the posterior edge. A “marked” degree of chipping is visible on the vertebral side in the lateral surface of the rib photographed in Figure 3.11e.

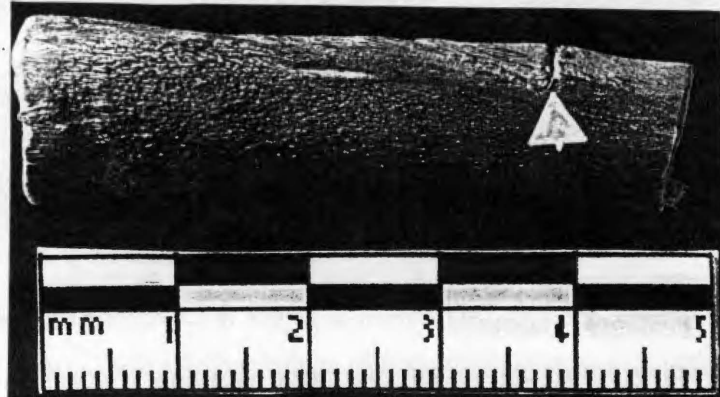
The collection of wounds resulting from the use of the Henckels® “Eversharp-Pro” pair of knives also ranges rather widely in its exhibition of chipping and splintering. Of the 13 injuries that make up this collection, 3 show neither; the majority of the wounds, however, do display some degree of this bone damage. Most manifestations of this feature are of “slight” (4 injuries) and “moderate” (5 injuries) degrees of chipping/splintering; only 1 example of a “marked” degree are present among the



a

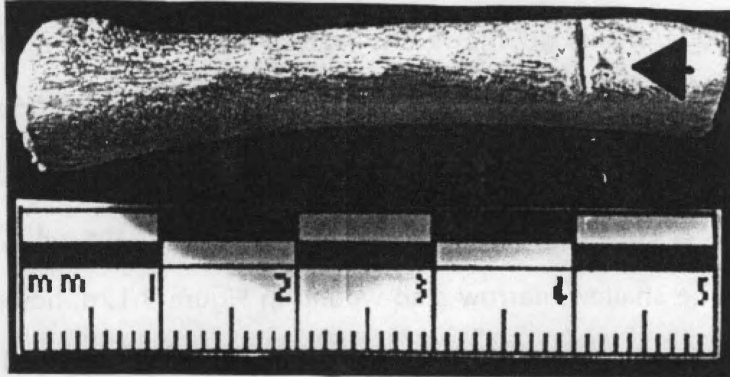


b



c

FIGURE 3.11. Manifestations of chipping and/or splintering among the injuries in the Ekco™ collection (Fig 2). a, this deep incision into the face of the sternal articulation on fourth right rib expresses no chipping or splintering; b, the fairly open, shallow stab wound in the posterior edge of the thirteenth right rib shows a "slight" degree of chipping; c, the medial floor of this stab to the posterior edge of the thirteenth left rib shows "moderate" chipping; d, the posterior surface of the same injury demonstrates some splintering along its length; e, a "marked" degree of chipping is seen in this injury to the eighth right rib. Features are pointed up with arrows.



d



e

FIGURE 3.11 (continued).

group. A small, shallow stab wound that appears on the anterior surface of the neck of one rib serves as an excellent example of the lack of chipping or splintering that is so seldom seen in wounds of this group (Figure 3.12a). The more common “slight” degree of chipping and splintering can be observed in Figure 3.12b. The deep, lengthy cut into the anterior edge of this rib shows this feature on the portion of the wound visible on the lateral side of the bone. A “moderate” degree of chipping (Figure 3.12c) is evident along the edges of some wounds; in this case, it is visible on the sternal edge of this complex of shallow stab wounds and incisions, giving the defect a slightly ragged appearance. The shallow, narrow stab wound in Figure 3.12d, however, stands in stark contrast, exhibiting a “marked” degree of chipping on its vertebral edge in the medial portion of the wound’s floor.

Lip Formation

Lip formation refers to the creation of a small ledge or “lip” of bone along the edges of a wound during the action of cutting, visible on most of the injuries within the assemblage to some degree. Closely related to chipping and splintering, lipping occurs “where bone is compressed as the blade is wedged into the material forming a lip on the outer surface of bone,” and is caused by contact between the beveled side of the cutting edge of the knife and the bone cortex (Symes 1992:180). The same 3-point scale that was established for the description of chipping and splintering is used in describing the more frequent feature of lipping, where it is visible:

Slight: lipping evident with scrutiny, barely ascertained by touch

Moderate: lipping readily seen but only in a small area, easily ascertained by touch

Marked: lipping easily seen and extensive, easily ascertained by touch


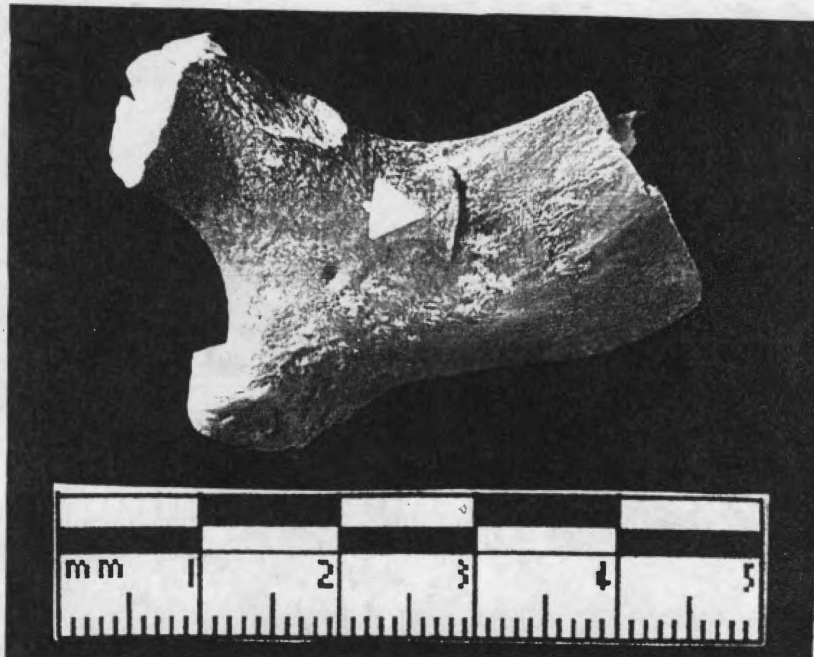
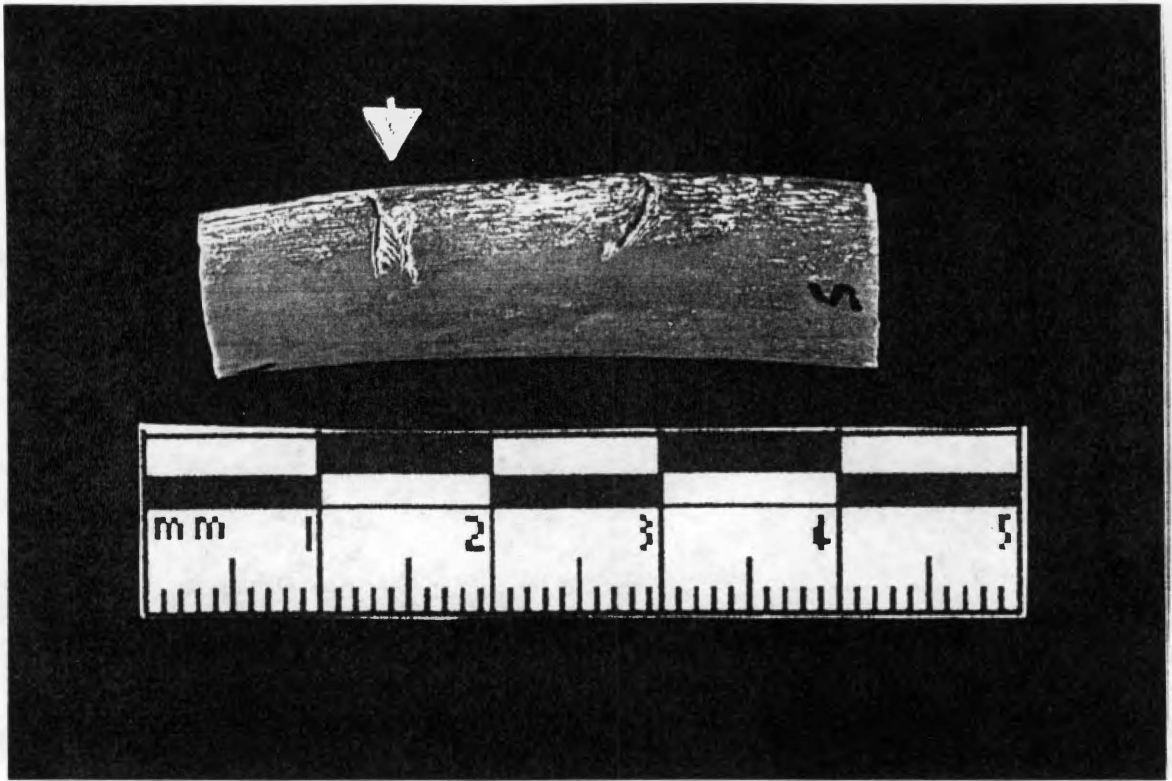



FIGURE 3.12. Manifestations of chipping and/or splintering among the injuries in the Henckels® collection (Fig 3). a, a complete lack of chipping/splintering is evident in this shallow wound to the neck of the third right rib; b, the more common "slight" degree of chipping and splintering is observed in this deep, lengthy wound into the anterior edge of the thirteenth right rib; c, this complex of defects, also seen in Figure 3.1, evinces a "moderate" degree of chipping along the edges; d, a "marked" degree of chipping is seen in this wound to the anterior edge of the fifth right rib. Features pointed up with arrow.



C




d

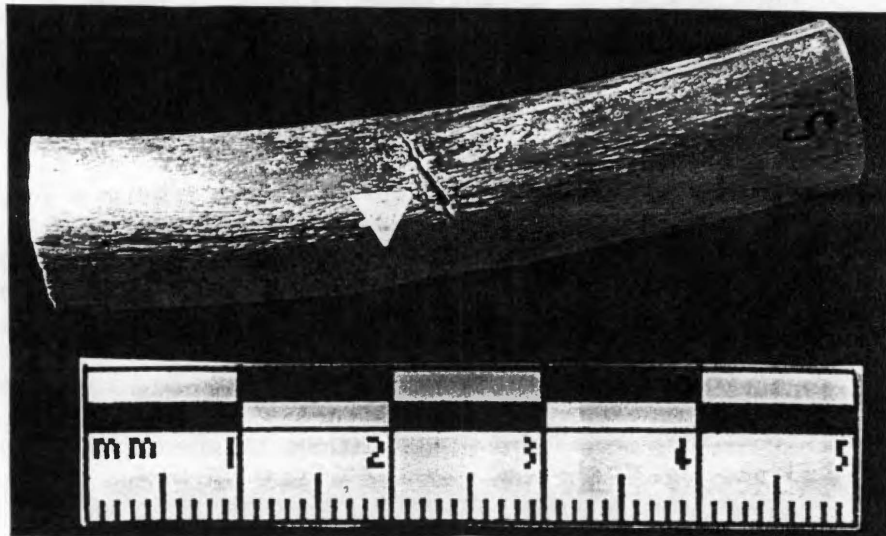
FIGURE 3.12 (continued).

Like chipping/splintering, the presence of lipping can be difficult to ascertain and requires careful consideration. As it is present mainly at the entry point of the knife into bone (Symes 1992), lipping, if observed, may also aid an investigator in the determination of a cutting stroke's directionality.

Lipping in the collection of injuries caused by the use of the Farberware® knife is somewhat variable, but falls most heavily in the "slight" category and is generally more greatly marked on the vertebral edges of the stab wounds. Of the 9 injuries inflicted with the Farberware® knives, 6 are considered "slight," 2 demonstrate a "moderate" degree of lipping, and 1 shows a "marked" degree. Those wounds with amounts of lipping defined as slight (Figure 3.13a) are also quite shallow and markedly separated: 3 of these are markedly separated, shallow stab wounds that express no degree of chipping or splintering; 2 are markedly separated nick marks that show no chipping or splintering; and 1 is a deep, markedly separated wound showing a "slight" degree of chipping in one aspect of the wound floor. Those injuries showing a "moderate" degree of lip formation are shallow injuries demonstrating differing appearances: the first is the "puncture" defect discussed above (see Figure 3.5), which exhibits a "moderate" degree of lipping on its sternal edge; the second, an open, shallow wound displaying only a "slight" degree of chipping, along with the "moderate" degree of lipping, on the vertebral edge (Figure 3.13c). That defect classified as exhibiting a "marked" degree of lipping (Figure 3.13d) does so on both of the wound's edges, but the trait is more prominent on the vertebral edge; this shallow, "markedly" separated stab wound also shows a "moderate" degree of chipping on both the sternal edge and the anterolateral aspect of the wound floor.




a



b

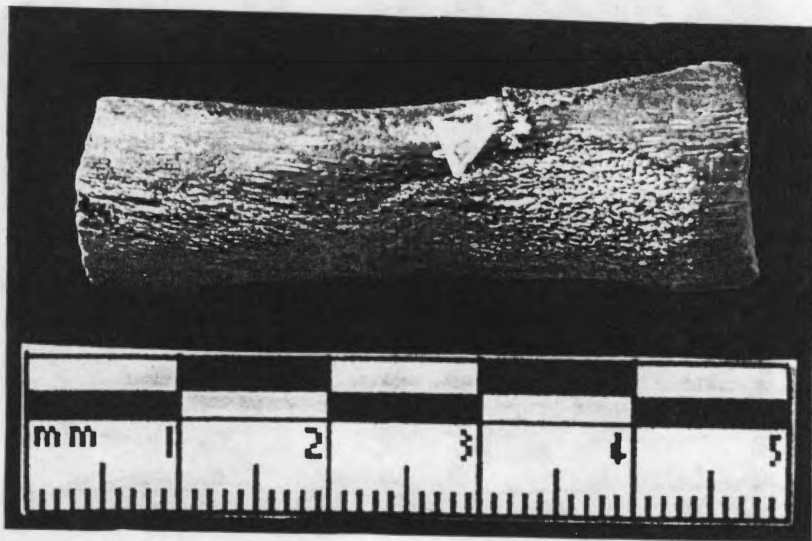
FIGURE 3.13. Manifestations of lip formation among the injuries in the Farberware® collection (Fig 1). a, a "slight" degree of lipping is visible on this deep wound to the right fifth rib; b, this injury to the seventh right rib shows a "moderate" degree of lip formation; c, both edges of this stab wound to the sixth right rib show "marked" lip formation, although this trait is more prominent on the vertebral edge. Features are pointed up with arrows.



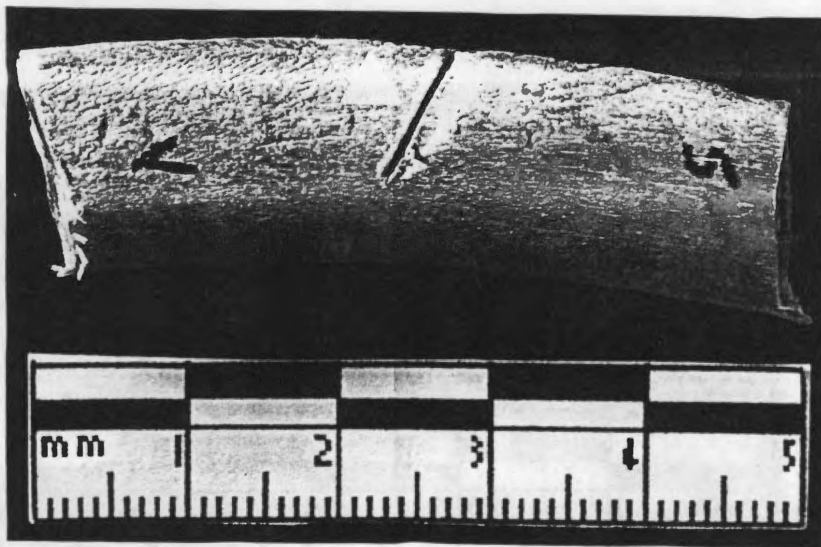
C

FIGURE 3.13 (continued).

While all of the injuries comprising the collection obtained through the application of the Farberware® blades during the execution of the procedure show some degree of lip formation, several of those inflicted with the Ekco™ “Flint” blades display none, and the majority exhibit a “slight” to “moderate” degree. Of the 21 wounds that comprise the Ekco™ group, 9 show no evidence of lip formation, 5 express a “slight” degree, 6 display a “moderate” degree, and only 1 exhibits a “marked” degree. Those showing no lip formation (Figure 3.14a) are mainly narrow wounds expressing varying degrees of wound edge separation. The complex injury described above (see Figure 3.2a) displays no lipping along any of its edges. The wounds that demonstrate a “slight” degree of lip formation (Figure 3.14b) are shallow, mostly narrow wounds: one is a shallow, markedly separated injury showing a “slight” degree of chipping in the medial aspect of its floor; the second is a shallow, narrow wound exhibiting no apparent chipping; and the third is a narrow nick mark expressing no chipping; the fourth is a narrow wound showing no chipping or splintering; and the fifth is an open wound showing no chipping or splintering. Of those wounds expressing a “moderate” degree of lipping (Figure 3.14c), three are deep, narrow stab wounds — two of which show no apparent chipping or splintering and one of which shows a “marked” degree of chipping — and two are shallow marks, one open and one fairly open with only one displaying a “slight” degree of chipping. The deeper stab wounds were inflicted with the 5-inch utility knife, while the more shallow wounds were inflicted with the 8-inch slicing knife. One of the injuries expressing a “moderate” degree of lipping is the embedded tip of the 5-inch utility knife (see Figure 3.3). This defect shows its lipping on its anterior edge. The unique wound that demonstrates a “marked” degree of lipping along its vertebral edge (Figure 3.14d) is a deep, moderately separated wound that was administered with the 5-inch utility knife




a




b

FIGURE 3.14. Manifestations of lip formation among the injuries in the Ekco™ collection (Fig 2). a, a significant number of wounds in this collection demonstrate no lipping, as seen in this narrow wound on the twelfth right rib; b, this injury to the seventh right rib shows "slight" lipping; c, a "moderate" degree of lip formation is evident in this deep wound to the posterior edge of the fifth right rib; d, this wound in the sixth right rib is unique in showing a "marked" degree of lipping along its vertebral edge. Features pointed out with arrows.



C




d


FIGURE 3.14 (continued).

and that shows a “slight” degree of chipping on its lateral floor and small degree in the lipped area.


The wounds inflicted by the use of the Henckels® “Eversharp-Pro” pair of knives demonstrate a range of variation similar to that visible in the Ekco™ group of wounds. Of the 13 injuries comprising the Henckels® collection, lip formation was not observed in 5, observed to a “slight” degree in 5, a “moderate” degree in 1, and a “marked” degree in 2. The wounds that show no lipping (Figure 3.15a) are quite different in their appearance: the first is the series of shallow stab wounds/incision marks described above (see Figure 3.1); the second, a deep, lengthy, narrow stab wound; the third, a markedly separated, shallow wound; the fourth, a shallow, narrow wound; and the fifth, a narrow nick mark. All of these show chipping to some degree and were inflicted with the 8-inch carving knife. The injuries displaying lipping to only a “slight” degree, such as that photographed in Figure 3.15b, are mainly shallow wounds that are very narrow, showing either no chipping or splintering to a “marked” degree. The 3 shallow stab wounds are narrow, show differing degrees of chipping, and were inflicted using the 5-inch utility knife; the singular narrow nick mark shows no chipping and was administered with the 8-inch carving knife. The remaining wound, the second of two complex defects discussed briefly above (see Figure 3.2b), is quite different in its manifestation of the feature. In this injury, lipping is apparent on both edges of the stab wound, while chipping is only visible on the sternal edge along the medial surface. The wound displaying a “moderate” degree of lip formation is a shallow wound flanked by 3 incision marks on its sternal side (see Figure 3.9); no chipping is immediately visible, although lipping is clearly seen along the vertebral edge of the wound. The injuries that show a “marked” degree of lipping (Figure 3.15c), both inflicted with the 8-inch carving knife, are shallow narrow/moderately separated stab wounds manifesting



a



b



c

FIGURE 3.15. Manifestations of lip formation among the injuries in the Henckels® collection (Fig 3). a, no lipping is visible in this injury to the thirteenth left rib; b, this shallow, narrow stab wound to the fifth right rib demonstrates a "slight" degree of lipping on its vertebral edge; c, this shallow wound to the eleventh left rib shows "marked" degrees of lipping on both the vertebral and sternal edges. Features pointed up with arrows.

a small degree of chipping. The first demonstrates lip formation along both edges of the stab wound, while the second shows its lipping on the vertebral edge on the medial surface and sternal edge on the lateral surface.

Wall Appearance

Wall appearance refers to the structure of the wall edges of the stab injuries as affected by the cutting action of the blade, with each knife pair showing a basically uneven pattern in wall structure that differs markedly according to pair. Characteristic structural patterns emerge that are specific to each pair. These patterns can be placed into three general categories: undulating, stepped, and clean. The “undulating” appearance manifests itself as a gentle waviness along the length of the wall, with blunt rounded peaks and valleys. Typically, only a minimal (<5) number of peaks/valleys are visible. On the other hand, the “stepped” appearance expresses itself in a ragged, stair-stepped appearance along the length of the wound’s wall, giving the injury a rather messy appearance. A wound that demonstrates a “clean” appearance may be uneven, but its edges show no raggedness whatsoever; the defects’ walls assume an uneven, cauterized look. The assemblage of injuries exhibits these varied traits in differing degrees, defined by the investigator in the following scale:

Slightly [uneven/undulating/stepped/clean]: trait is visible but not completely expressed

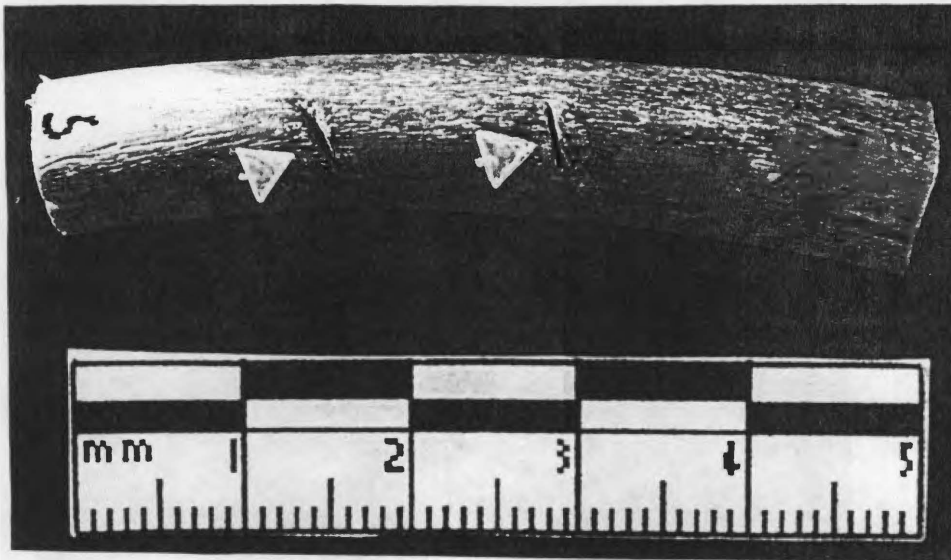
Moderately [Uneven/undulating/stepped/clean]: trait is completely expressed

Markedly [uneven/undulating/stepped/clean]: trait is exaggeratedly expressed


Overall, the walls of the collection of injuries administered through the use of the Farberware® knife are characterized by an uneven, undulating appearance. Of the 9 wounds incurred with the Farberware® blade, 2 appear to be straight, showing no

unevenness; 4 are classified as “slightly uneven/undulating,” as they show some degree of undulation but the trait is not fully demonstrated; and 2 express a “marked” degree of undulation. Those injuries that show no unevenness (Figure 3.16a) are open, shallow cuts inflicted with the 5-inch utility knife that manifest no chipping and only minor amounts of lip formation. Two of the injuries displaying “slightly uneven/undulating” walls (Figure 3.16b) are relatively featureless in all other categories: one is a markedly separated, shallow stab mark showing no chipping or splintering and only a “slight” degree of lipping; the other, a markedly separated nick mark with no accompanying chipping or splintering and a “slight” degree of lipping. The remaining two wounds expressing slightly uneven/undulating walls are shallow stab injuries, both of which show “marked” degrees of wound edge separation, that were incurred with the 5-inch utility knife and demonstrate widely varying degrees of chipping and lip formation. Careful examination of the walls of the puncture-like wound described above (Figure 3.5), particularly in the open portion of the defect, reveals a manifestation of a “markedly uneven/undulating” appearance. The complete expression of this feature is more clear in a deep, markedly separated stab wound that shows “slight” amounts of chipping and lipping (Figure 3.16c). One injury has not been classified according to wall appearance due to breakage of the bony flap generated from the entrance of the wound at a markedly acute angle was during examination. Coupled with the fact that the additional confines of this wound are somewhat ill-defined, this markedly separated nick mark demonstrating no chipping or splintering and only a “slight” degree of lip formation is not well suited for proper assessment of the wall appearance feature.

The 21 wounds obtained from Pig Carcass 2, that which sustained injuries from the Ekco™ knife pair, seem to be generally characterized by unevenness if not a jagged, stepped appearance that is widely divergent in its manifestations. None of the defects




a



b

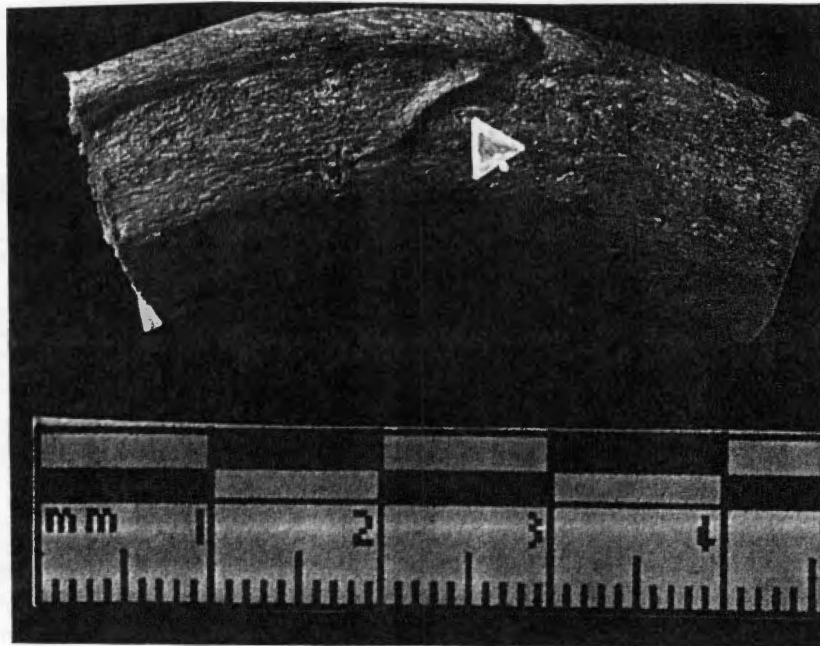
FIGURE 3.16. Manifestations of wall appearance among the injuries in the Farberware® collection (Fig 1). a, no unevenness is visible in these shallow stab wounds in the anterior edge of the ninth right rib; b, the walls of this wound on the ninth left rib demonstrate a "slightly uneven/undulating" appearance; c, this deep, markedly separated stab wound to the fifth right rib shows a "markedly uneven/undulating" appearance.




C

FIGURE 3.16 (continued).

examined from this collection shows a straight wall appearance. Seven are called “slightly uneven/stepped,” as they display a mildly stair-stepped appearance; 10 are considered “uneven/stepped,” as they fully express unevenness and a stair-stepped, toothed appearance; and 1 is classified as “markedly uneven/stepped,” as this trait is rather exaggerated in its manifestation. The injuries demonstrating a “slightly uneven/stepped” appearance (Figure 3.17a) are mainly, shallow stab wounds displaying varying degrees of wound edge separation, moderate chipping and splintering, and some lip formation. They were incurred with both the 5- inch utility and 8-inch slicing knives. Those stab wounds showing a “moderately uneven/stepped” wall appearance (Figure 3.17b) are mainly shallow injuries — only 3 are deep stabs — and show varying expressions of depth, wound edge separation, chipping/splintering, and lip formation. These were also inflicted with both the 5-inch and 8-inch knives. The singular “markedly uneven/stepped” injury (Figure 3.17c), generated with the 5-inch utility knife. This deep, slightly open wound enters the posterior edge of the rib at a slightly acute angle and is remarkable in the prominent lipping visible along the vertebral edge as the wound extends onto the medial surface, as well as the moderate degree of chipping on the edge of the floor visible on the posterior edge of the bone and splintering along portions of the vertebral lip, all of which combine with the stair-stepped appearance of the walls to give this injury a highly ragged appearance. Three defects in this group of injuries, one of which is the broken knife tip of the 5-inch utility knife (see Figure 3.3a), were not included in the classification for wall appearance. A moderately separated nick mark inflicted with the 8-inch slicing knife is too shallow to properly assess this trait at the visual level. In addition, the complex injury among the Ekco™ subclass (see Figure 3.2) lends itself quite poorly to the determination of wall appearance.

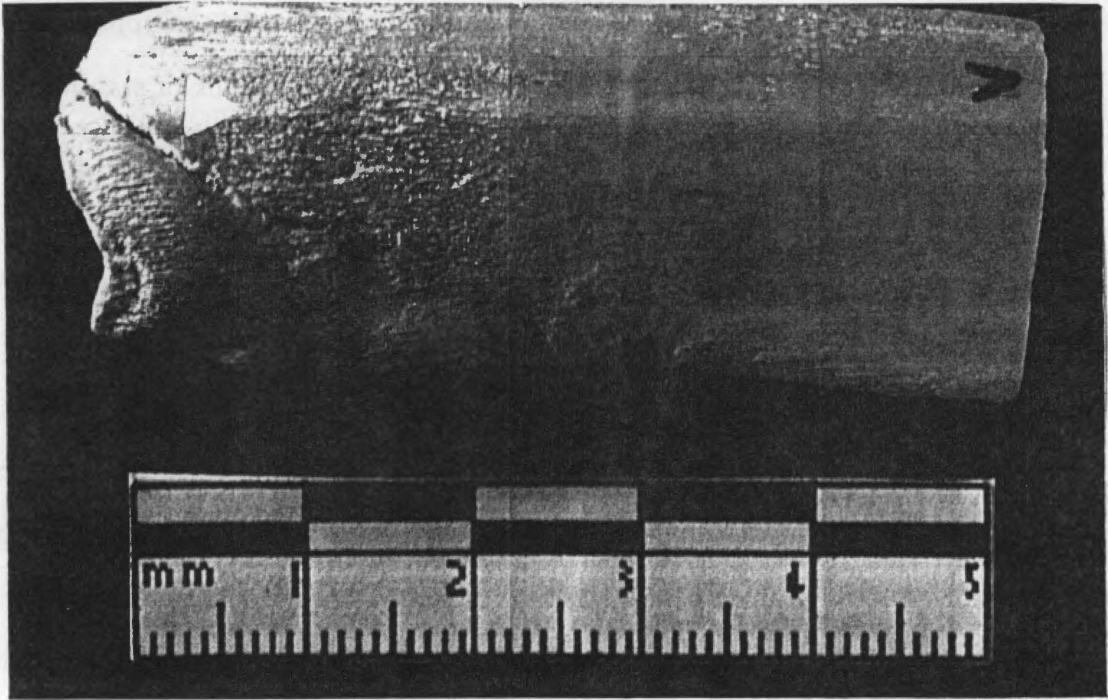


a



b

FIGURE 3.17. Manifestations of wall appearance among the injuries in the Ekco™ collection (Fig 2). a, the "slightly uneven/stepped" aspect of several stab injuries is depicted in this shallow wound on the posterior edge of the fifth right rib; b, this injury in the twelfth right rib shows a "moderately uneven/stepped" wall appearance; c, the incision into the sternal articulation of the fourth right rib demonstrates a "markedly uneven/stepped" appearance. Features pointed up with arrows.




C

FIGURE 3.17 (continued).


The collection of injuries resulting from the application of the Henckels® “Eversharp-Pro” knives exhibits something of a different trait than those considered for the previous two knife sets. Overall, the walls of these wounds are characterized by a clean, “cauterized” appearance; while the wounds do show some chipping, it is not highly evident along the edges of the walls, which, though not straight in appearance, seem to be remarkably free of the rough edges seen in the other groups of stab marks. Of the 13 Henckels® wounds, 3 do not demonstrate the clean appearance observed in the remaining 10 injuries, and are simply uneven (Figure 3.18a). Four are called “slightly uneven and clean,” as the structures of these walls deviate from a straight path visibly to a very small degree, and 6 are classified as “moderately uneven and clean.” The “slightly uneven and clean” wounds (Figure 3.18b) exhibit an array of manifestations, from a deep, lengthy, moderately separated wound with a slight degree of chipping but no lipping to a moderately separated nick mark with a slight degree of lipping but no chipping or splintering. All of these were generated with the 8-inch carving knife. The wounds comprising the “moderately uneven and clean” (Figure 3.18c) group are uniformly rather shallow, inflicted with both the 5-inch and 8-inch knives and showing varying degrees of wound edge separation, chipping, splintering, and lip formation. Two of these are the collective incision defects described above (see Figures 3.1 and 3.9).

RESULTS II: EXAMINATION UNDER LOW-POWER MAGNIFICATION

Since the low-power magnification and microscopic portions of the procedure build on the foundations laid during the visual procedure, describing in great detail the traits uncovered therein, consideration of their results is presented more in the form of a discussion rather than the outline type of structure used for the visual results.




a



b

FIGURE 3.18. Manifestations of wall appearance among the injuries in the Henckels® collection (Fig 3). a, this uneven injury to the posterior edge of the eleventh left rib does not display the cauterized appearance in its walls that most of the Henckels® wounds show; b, a "slightly uneven and clean" aspect is assumed in the walls of this shallow, slightly open stab wound mark on the eleventh left rib; c, this nick injury on the anterolateral surface of the fourteenth left rib demonstrates a "moderately uneven and clean" wall appearance. Features pointed out with arrows.



C

FIGURE 3.18 (continued).

Injuries Inflicted with the Farberware® Blades

While chipping and splintering are not often observed among these wounds at the visual level, the magnified eye perceives these features with far greater frequency and accuracy; in all but 3 of the 9 wounds examined, chipping, splintering, or both are apparent. Chipping, where it is present, is visible mainly in the medial and lateral aspects of the wound floor. In Figure 3.19, for example, bone chipping is seen on the floor corner of the vertebral side of the wound, giving the almost rectangular floor an angled appearance. A tentative connection is also drawn from the appearance of bone splintering, a phenomenon seldom directly observed at the visual level, and lip formation along wound edges. These two features seem to occur together in 4 of 5 wounds displaying significant lipping, with the splintering presenting itself on the edge of the bony lip or on the surface of the lip facing the interior of the injury (Figure 3.20). Lip formation also shows itself to be more prominent at this level of examination than it appeared to be at the visual level, with all wounds demonstrating the feature to some degree. In fact, 6 of the 9 wounds are described during the low-power magnification examination as having “marked” lipping, particularly along the vertebral edges of the stab wounds (Figure 3.21). Also significant in the magnified analysis of the injuries is the continued observation of the wounds’ walls as “undulating,” even if these traits are only slightly pronounced (Figure 3.22); this strengthens the utility of wall appearance as a diagnostic trait, as at the visual level it can be argued that the structure of the wall is easily obscured by the difficulty of the human eye to discern such fine detail, particularly in the face of such features as chipping, splintering, and lipping. No additional evidence of incision marks, save for the two occurrences observed at the visual level, is seen.

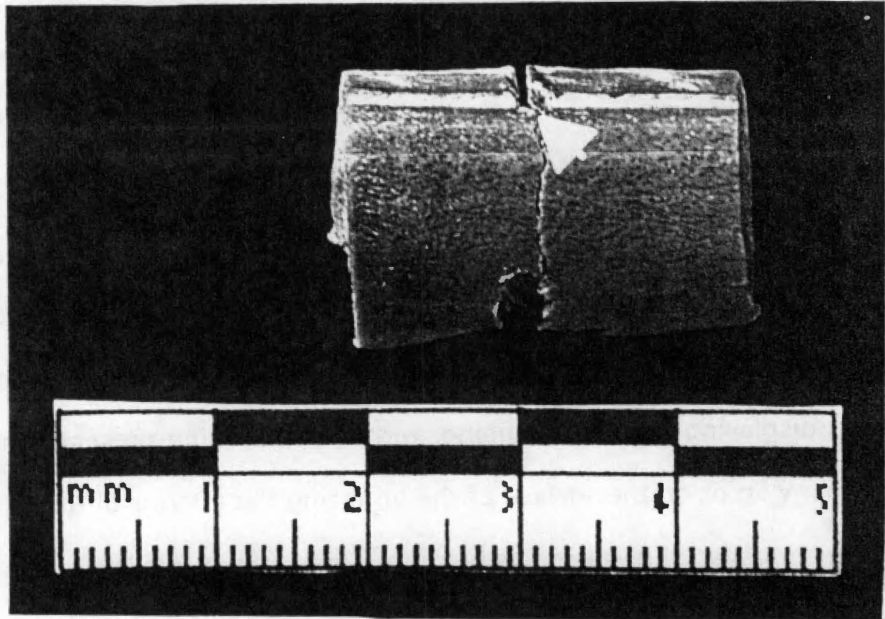


FIGURE 3.19. Bone chipping is apparent in the corner of the medial floor and the vertebral edge of this wound to the fifth right rib of Fig 1.

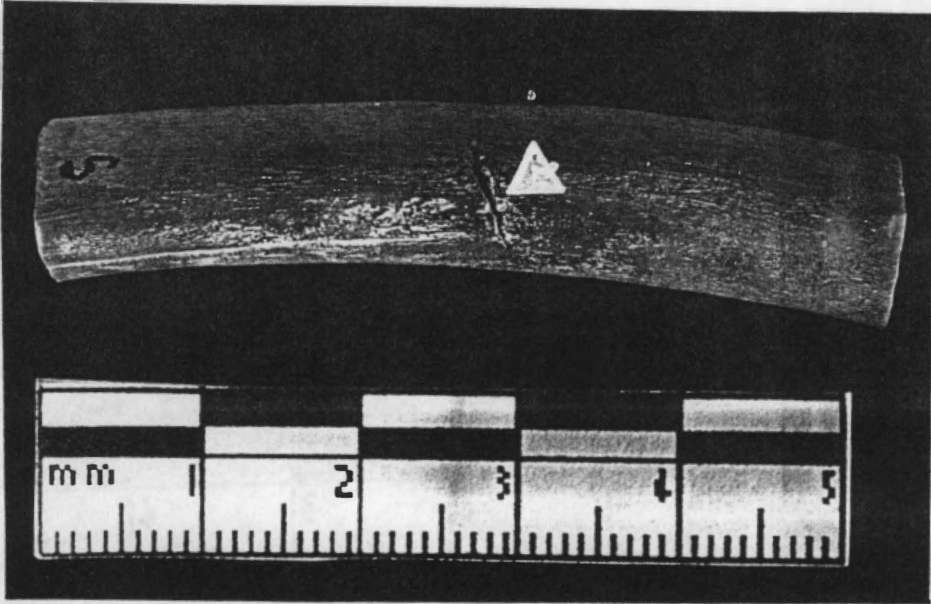


FIGURE 3.20. Splintering is visible on the interior of the bony lip, which appears prominent under magnification, along the vertebral edge of this injury to the seventh right rib of Fig 1.

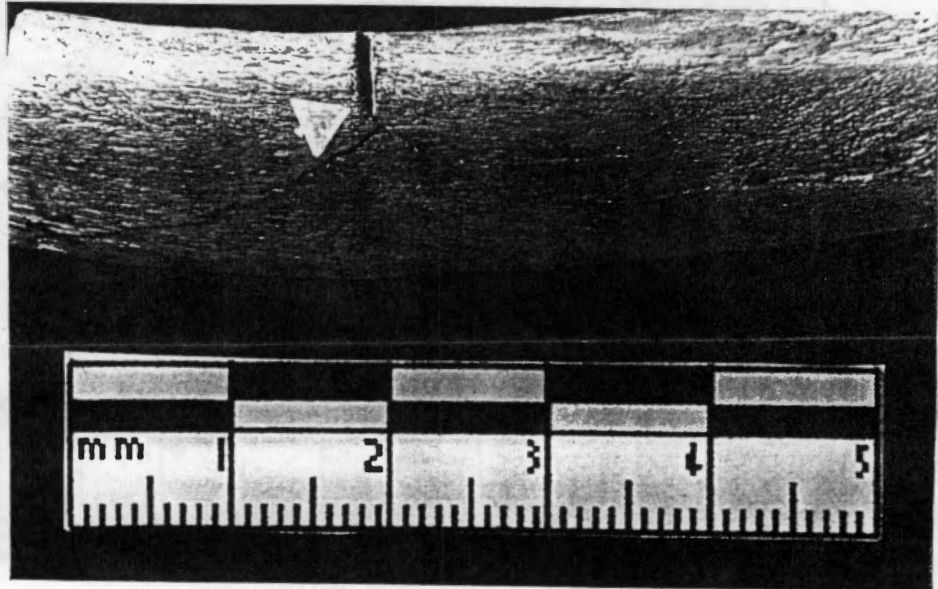


FIGURE 3.21. Marked lipping is visible on the vertebral edge of this wound in the anterior edge of the sixth right rib of Pig 1.




FIGURE 3.22. Evident in this lateral view of the deep stab wound on the anterior edge of the fifth right rib is the "uneven/undulating" appearance that seems to characterize the walls of the wounds comprising the Farberware® injury collection.

Injuries Inflicted with the Ekco™ “Flint” Blades

Upholding the observations made during the visual inspection, magnified examination of this collection of wounds reveals very little in the way of chipping and splintering. When it does appear, however, chipping is seen, mainly in the interior of the wound floors (Figure 3.23), or in the medial or lateral aspects of the injury floors, potentially giving an indication of directionality (Figure 3.24). Lip formation, while generally observed to a slight/moderate degree during the visual examination, is again relatively more marked in the magnified examination, and presents itself in several specimens in a unique fashion, giving rise to a heretofore unrecognized trait. In a number of the injuries wherein lipping is present to any significant degree (4 of 13 wounds), the surface of the lip edge facing the interior of the stab wound contains another cut, giving the appearance of a “cleft lip” (Figure 3.25). This feature may be caused by jump of the knife within the confines of the wound, but it is seen mainly in the injuries resulting from the Ekco™ knife pair. The appearance of the cut walls shows itself to be diagnostic at the level of low-power magnification, with the uneven/stepped appearance expressed at the visual level continuing to be observed at the microscopic level (Figure 3.26). Additionally; the floors of several stab wounds assume a more tapered, pointed aspect (Figure 3.27) — in contrast to the somewhat more blocky profile of the Farberware® knife injuries. This tapered image is augmented by the overall narrowness expressed by the cut itself, with the moderately separated, tapered wound of the Ekco™ knife appearing almost streamlined in contrast to the open, blocky wound of the Farberware® knife. Little evidence of incision marks is evident among this collection of injuries, either at the visual or magnified levels of analysis.

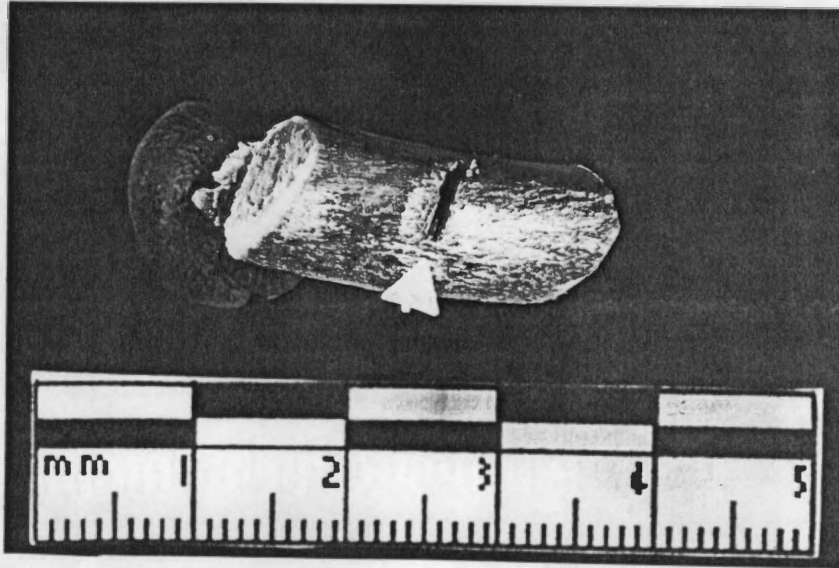


FIGURE 3.23. Chipping in the floor of this injury to the posterior edge of the midshaft region of the twelfth right rib of Fig 2.

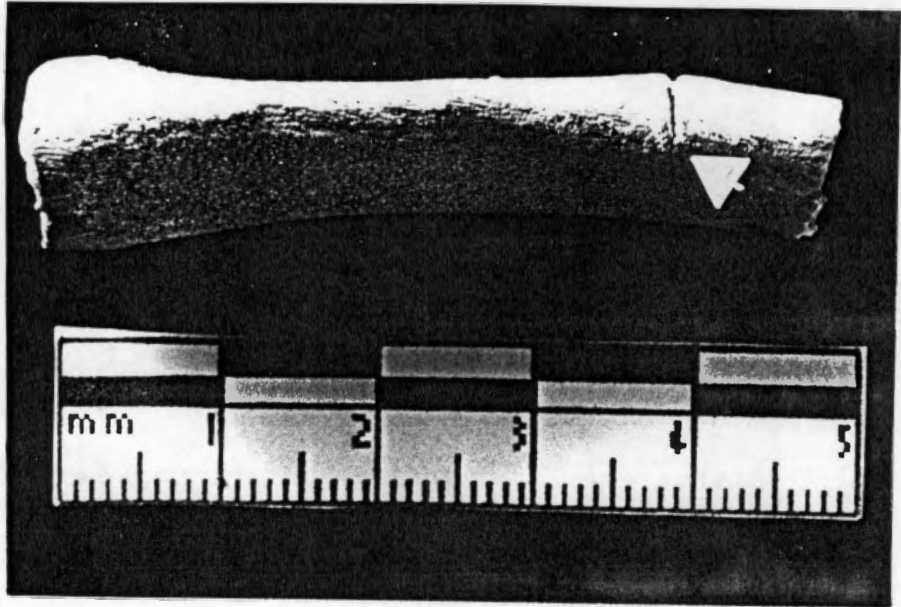


FIGURE 3.24. Chipping is apparent in the medial aspect of the floor of this stab wound in the posterior edge of the thirteenth left rib of Pig 2.

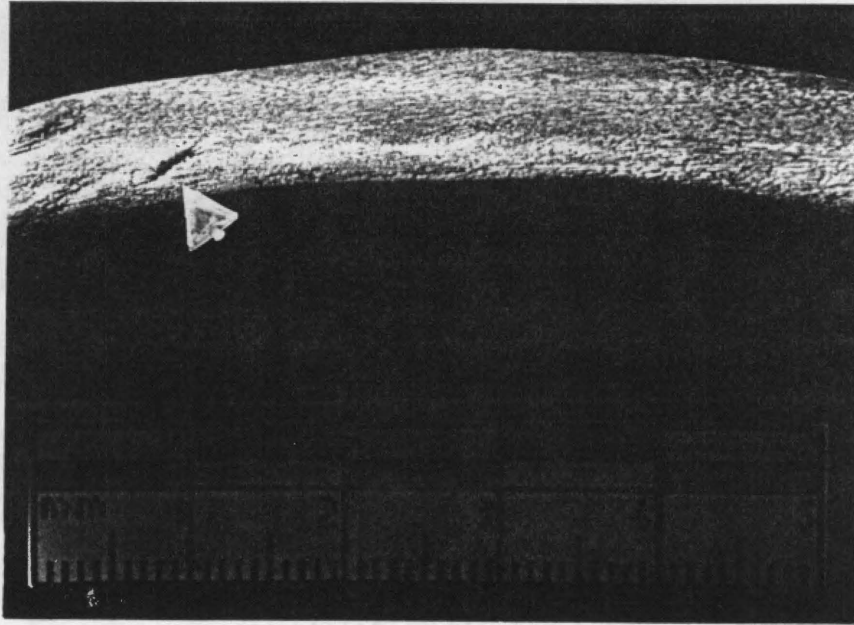


FIGURE 3.25. This injury to the fourteenth left rib of Pig 2 demonstrates the unique "cleft-lip" appearance that is observed among several of the injuries in the Ekco™ collection.

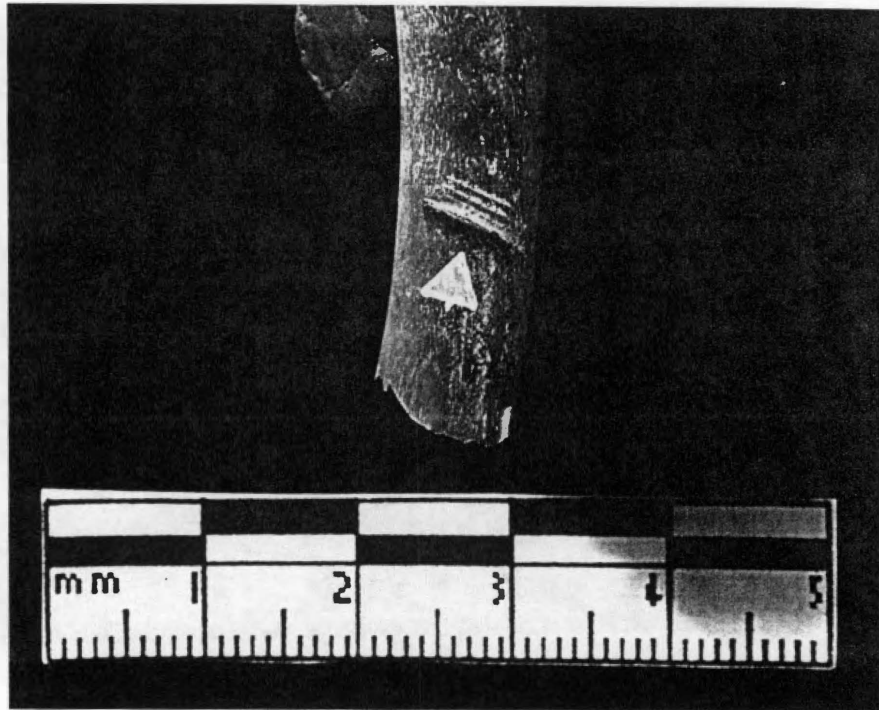


FIGURE 3.26. The walls of this injury to the fifteenth left rib of Pig 2 show the "moderately uneven/stepped" appearance characteristic of the Ekco™ wounds.

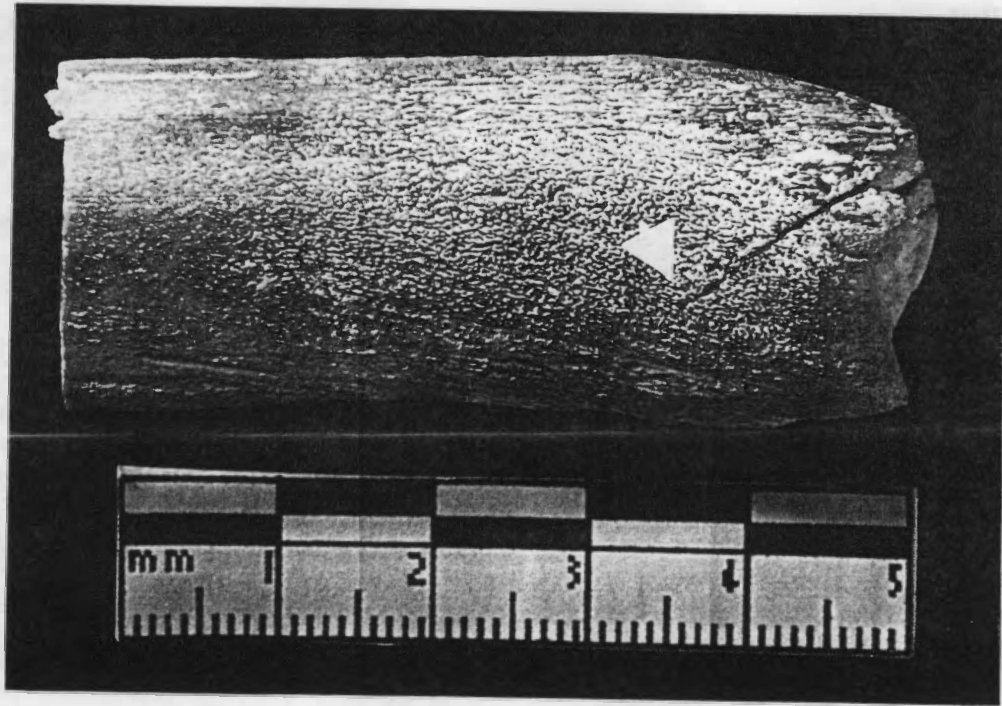


FIGURE 3.27. The floor of this stab wound in the fourth right rib of Pig 2 exhibits a pointed, tapered appearance.

Injuries Inflicted with the Henckels® “Eversharp-Pro” Blades

Among the wounds generated by the Henckels® blades, the amount of chipping and splintering apparent through magnified examination is only slightly more marked than that observed in the visual inspection, occurring mainly in the wound floors (Figure 3.28). No doubt this contributes to, at least in part, the extremely clean appearance of the wounds as a whole and the walls in particular. None of the walls assume a straight, entirely linear appearance; all are uneven in some respect. While this nonlinear quality is easily classified as “undulating” or “stepped” in the remaining knife pairs, in these knife injuries the unevenness is not patterned (Figure 3.29). However, the “cauterized” aspect of the walls remarked upon during the visual inspection is brought into greater focus at the magnified level, particularly as the role of chipping and splintering is diminished. It is this trait more than any other that sets the Henckels® knives apart from the remaining implements. Whereas in the groups of stab wounds inflicted with the Farberware® and Ekco™ knife pairs a significant, if minimal at the visual level, amount of chipping and splintering is visible along the edges and floors at the magnified level, these features appear lacking in the Henckels® collection, alleviating the effects of the movement of the knife that usually result in a rough appearance (Figure 3.30). Like their immediate predecessors, these stab wounds have a pointed, tapered aspect to their floors; but the streamlining effect of this characteristic on these relatively narrow wounds is undermined by the basic unevenness of the walls. This collection is also characterized by the significant amount of tooth incisions observed at the microscopic as well as the visual level. Those tooth incision marks that are visible at the visual level are more easily examined at the microscopic level, and reveal a surprising amount of lip formation along their edges and chipping where the incision mark conglomerates come together (Figure 3.31).

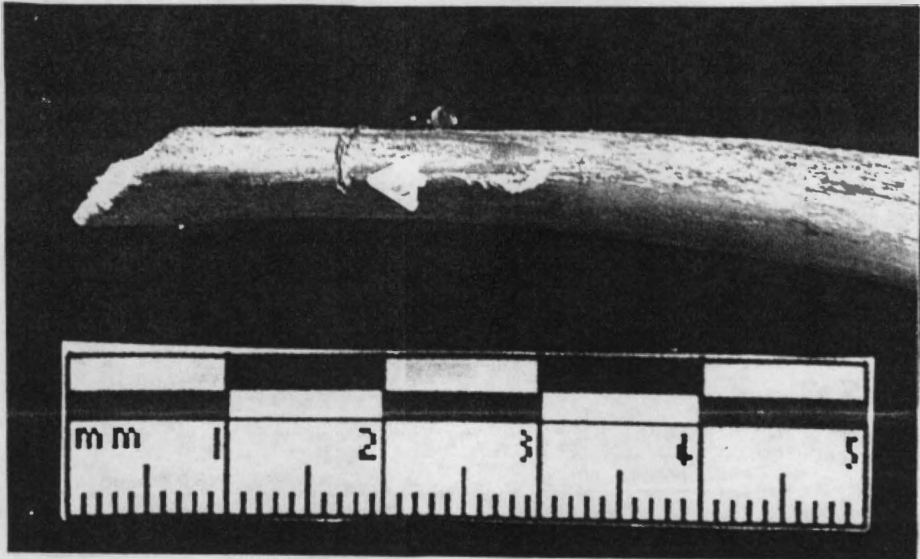


FIGURE 3.28. A marked degree of chipping is evident in the medial aspect of this wound on the posterior edge of the thirteenth left rib of Pig 3. Only a "slight" degree of chipping was visible here at the visual level.

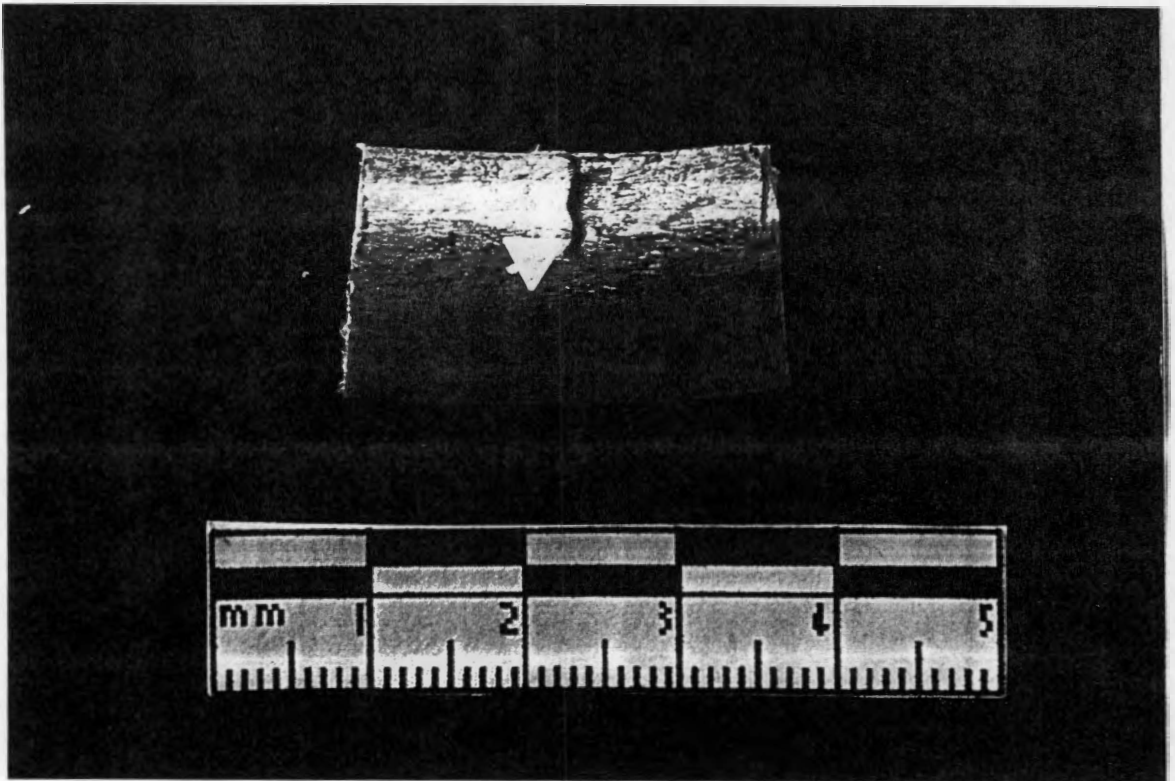


FIGURE 3.29. The non-patterned unevenness characteristic of the Henckels® injuries is easily discerned in the walls of this stab wound in the anterior edge of the fifth right rib of Fig 3.




FIGURE 3.30. Apparent in the vast majority (70%) of the wounds comprising the Henckels® collection is a "clean," cauterized appearance, even at the microscopic level, such as that seen in the walls of this injury to the eleventh left rib.

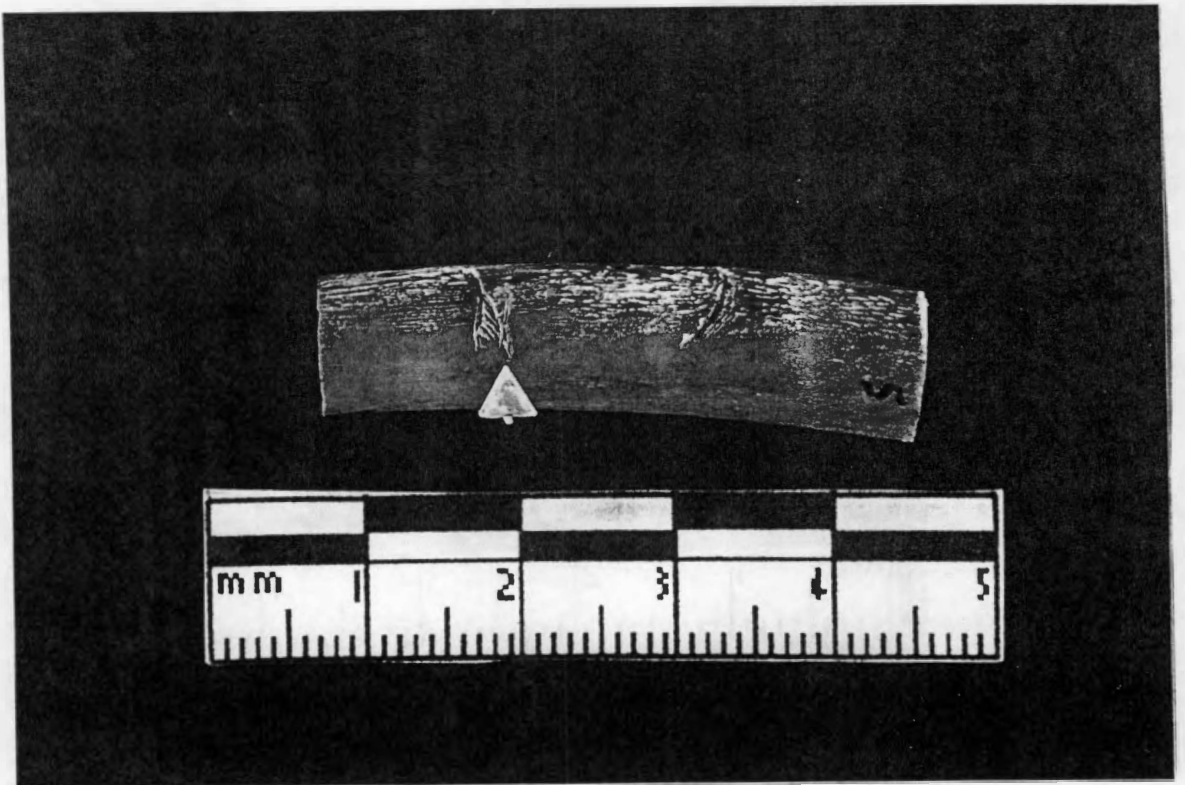


FIGURE 3.31. Lip formation and chipping are visible under magnification where the incision marks of this conglomerate of defects, seen above in Figure 3.1, come together.

RESULTS III: SCANNING ELECTRON MICROSCOPIC EXAMINATION

The Farberware® Injury Collection

Under scanning electron microscopy, the coalescence of apparent Farberware®-injury features such as chipping, splintering, and lip formation into an uneven, slightly “messy” wound becomes more clear as these are brought up in fine detail. Small amounts of chipping and splintering are visible along the edges of the stab wounds, as shown in the injuries photographed in Figure 3.32. While not observed at the visual or low-power magnification levels, chipping is also demonstrated around the lateral aspect of the wound floor (Figure 3.33). Under scanning electron magnification, we see that the wound continues to appear relatively open, with the floor showing the wide, somewhat rectangular appearance observed at lower magnification; this is characteristic of the Farberware® injuries. Bony lip formation along the edges of the wounds is not as evident as in the lower levels of analysis, but is still visible to some extent (Figure 3.34). Under this high-power magnification, it is easy to see the “pushing upward” of cortical bone that occurred as the knife blade came into contact with the bone and progressed inward, resulting in lip formation; this is particularly apparent along the vertebral edges of the injuries. More evident, however, is the uneven, undulating structure of the walls seen first at the visual level, which is demonstrated by most specimens under scanning electron magnification. For example, as the stab wound in Figure 3.34a progresses into the bone one can discern waves within the structure of the walls; this feature is demonstrated in several specimens among the Farberware collection to varying degrees under SEM (Figure 3.35).

The Ekco™ Injury Collection

The variety of trait manifestations we have seen in the collection of injuries resulting from the use of the Ekco™ knives continues under SEM analysis. As in the lower levels




FIGURE 3.32. Scanning electron micrographs of two separate injuries showing chipping and splintering resulting from injury with the Farberware® knives, pointed up with black arrows (Fig 1). a, the lateral aspect of this deep stab wound to the fifth right rib demonstrates some surface chipping along the vertebral edge of the wound (anterior edge toward top; magnification = x80); b, chipping and splintering seen along the bony flap comprising the vertebral edge of this stab wound to the posterior edge of the ninth left rib (facing posteromedial surface, sternal end toward top; magnification = x70).

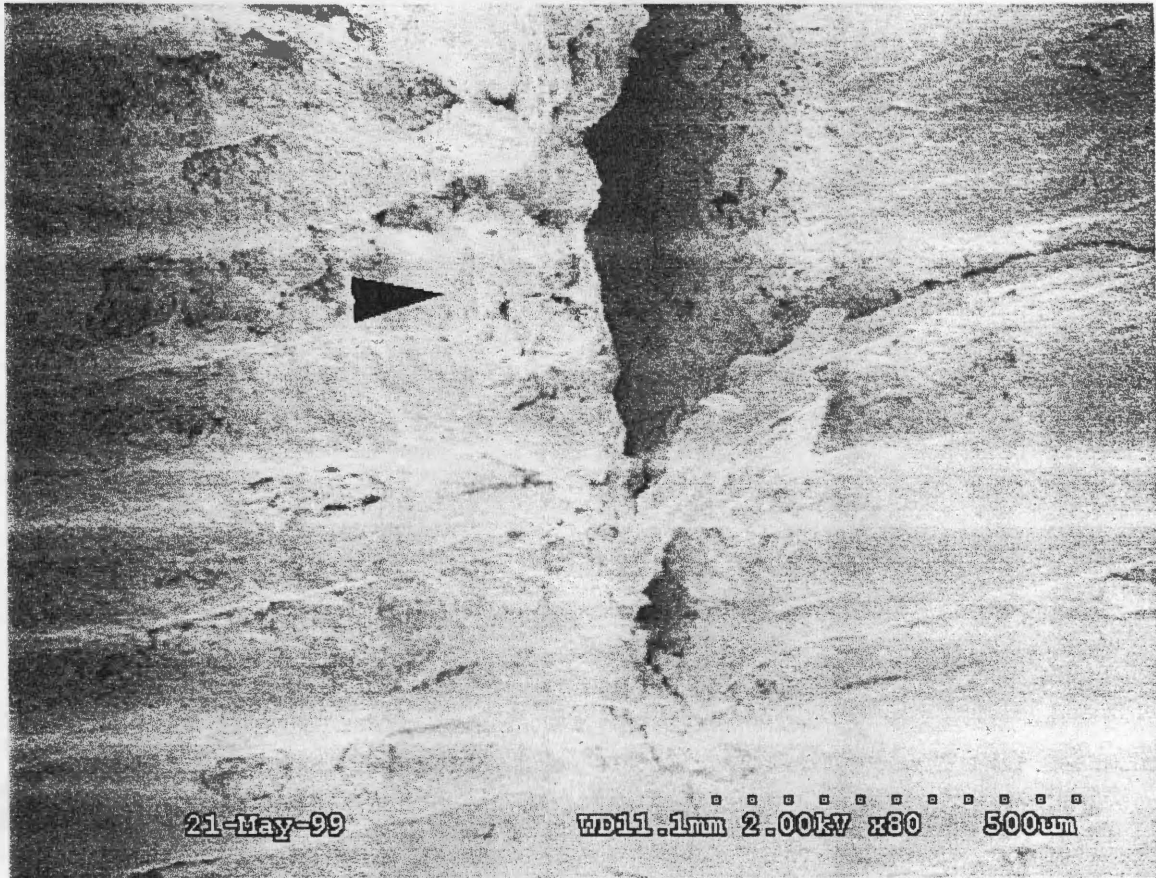


FIGURE 3.33. Scanning electron micrograph of the lateral aspect of the deep stab wound to the fifth right rib of Pig 1. This demonstrates a wide open, somewhat "blocky" rectangular appearance as well as chipping and splintering around the floor area (pointed up with black arrow). Anterior edge of rib is toward top; magnification = x80.

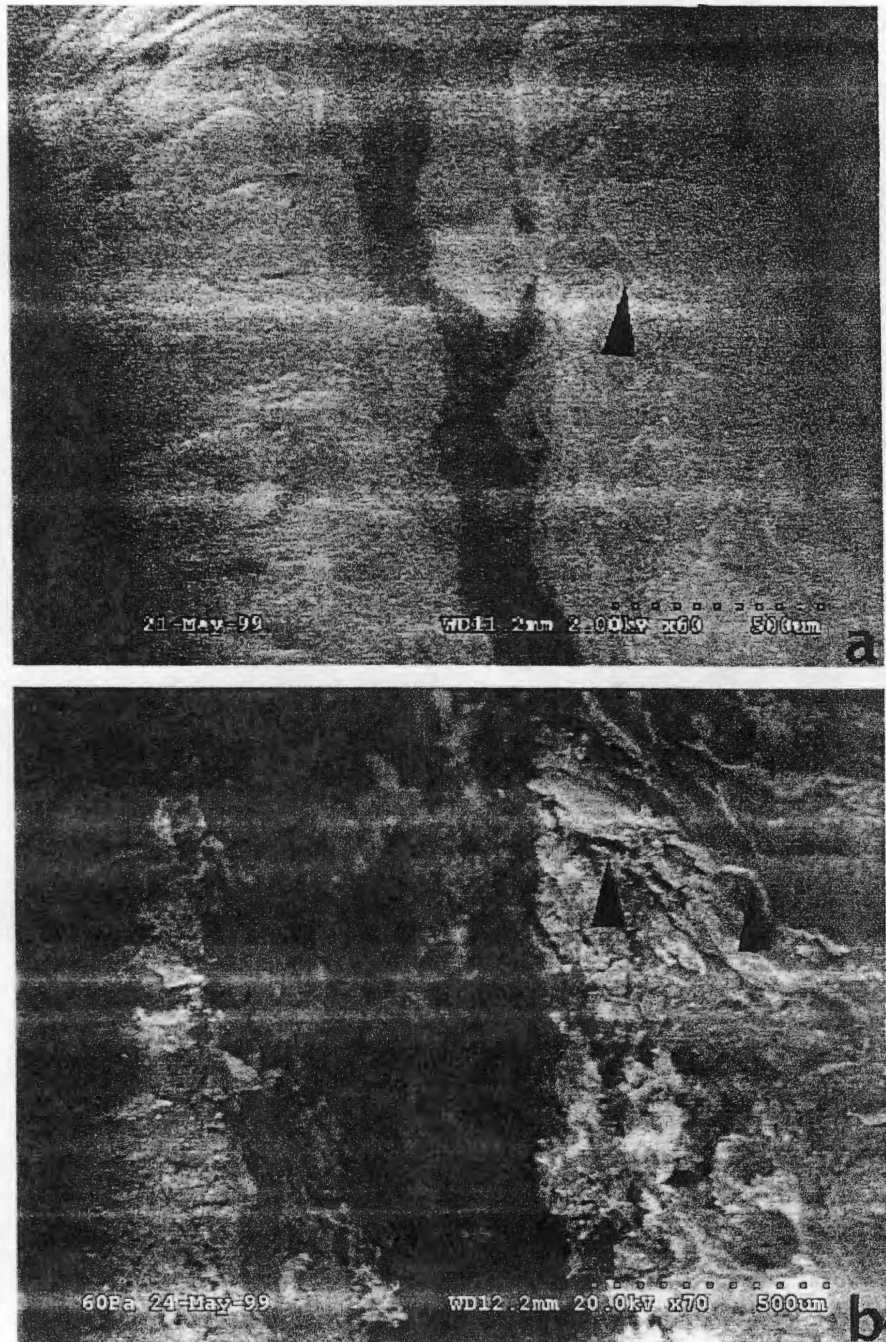


FIGURE 3.34. Scanning electron micrograph of two injuries showing bony lip formation in the Farberware® collection. a, view of the entry point of the stab wound into the anterior edge of the fifth right rib shows the “pushing up” of cortical bone to form a bony lip at the vertebral edge, as well as the beginnings of uneven, undulating wall structures (anterior edge toward top; magnification = x60); b, the splintering and “pushing upward” of cortical bone, pointed up by black arrows, is visible along the vertebral edge of this injury to the ninth left rib, a feature that not readily visible under low-power magnification (lateral edge toward top; magnification = x70).

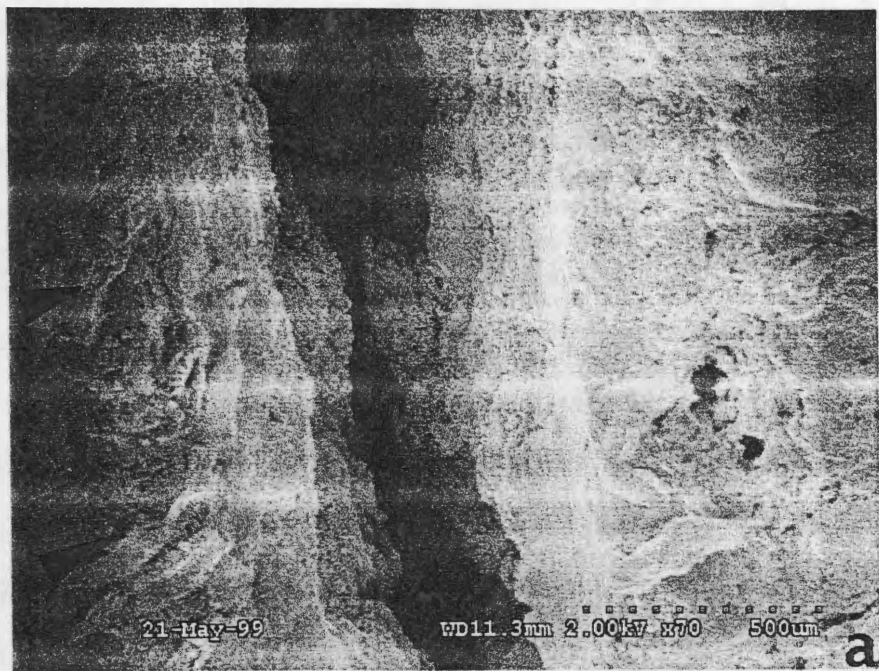


FIGURE 3.35. Scanning electron micrographs of the walls of two stab wounds to ribs in Fig 1, with wall edges pointed up with black arrows. a, further along the stab injury demonstrated in 3.38a, showing the progression of the undulating, uneven wall structure visible (anterior edge toward top; magnification = x70); b, the vertebral edge of the wall of the ninth left rib demonstrates a slightly uneven, undulating appearance (facing posteromedial surface, sternal end toward top; magnification = x200).

of analysis, these injuries appear for the most part as moderately separated, mainly shallow stab wounds that express a tapered appearance (Figure 3.36), a feature we will return to below. Instances of splintering and chipping are rare among the specimens in this high level of magnification, appearing in less than ¼ of the injuries, but where they do appear they are marked. The presence of the broken 5-inch utility knife tip (see Figure 3.3), embedded as it is in the bone, appears to engender a significant amount of bone splintering in the bone surrounding the exposed broken portion of the blade on the lateral side of the rib (Figure 3.37). Other wounds demonstrate severe splintering along their edges (Figure 3.38). One injury expresses splintering in conjunction with lipping, another relatively uncommon trait at the SEM level; both, however, are relatively slight (Figure 3.39a). As in the Farberware® collection of wounds, the “pushing upward” of cortical bone that creates the effect of lip formation is readily visible (Figure 3.39). The “cleft lip” appearance seen in a number of Ekco™ injuries at the low-power magnification level is not observed at this higher level of magnification. On the other hand, the uneven, stair-stepped wall appearance that presents itself at the visual and low-power magnification levels is quite visible, showing itself in many of the specimens (Figure 3.40). This stepped, uneven appearance, combined with the narrowness described above and the sharp tapering of the wound floor (see Figures 3.40, 3.41), generally gives these injuries a rather streamlined but messy appearance, particularly in wounds that also display splintering. The structure of the stab wound floors, where not obscured by other features, demonstrates a sharp, constricted V shape with little curving along the corners of the floor and the vertebral and sternal edges. Overall, the wounds express a very rough appearance, on the interior as well as the exterior (Figure 3.42).

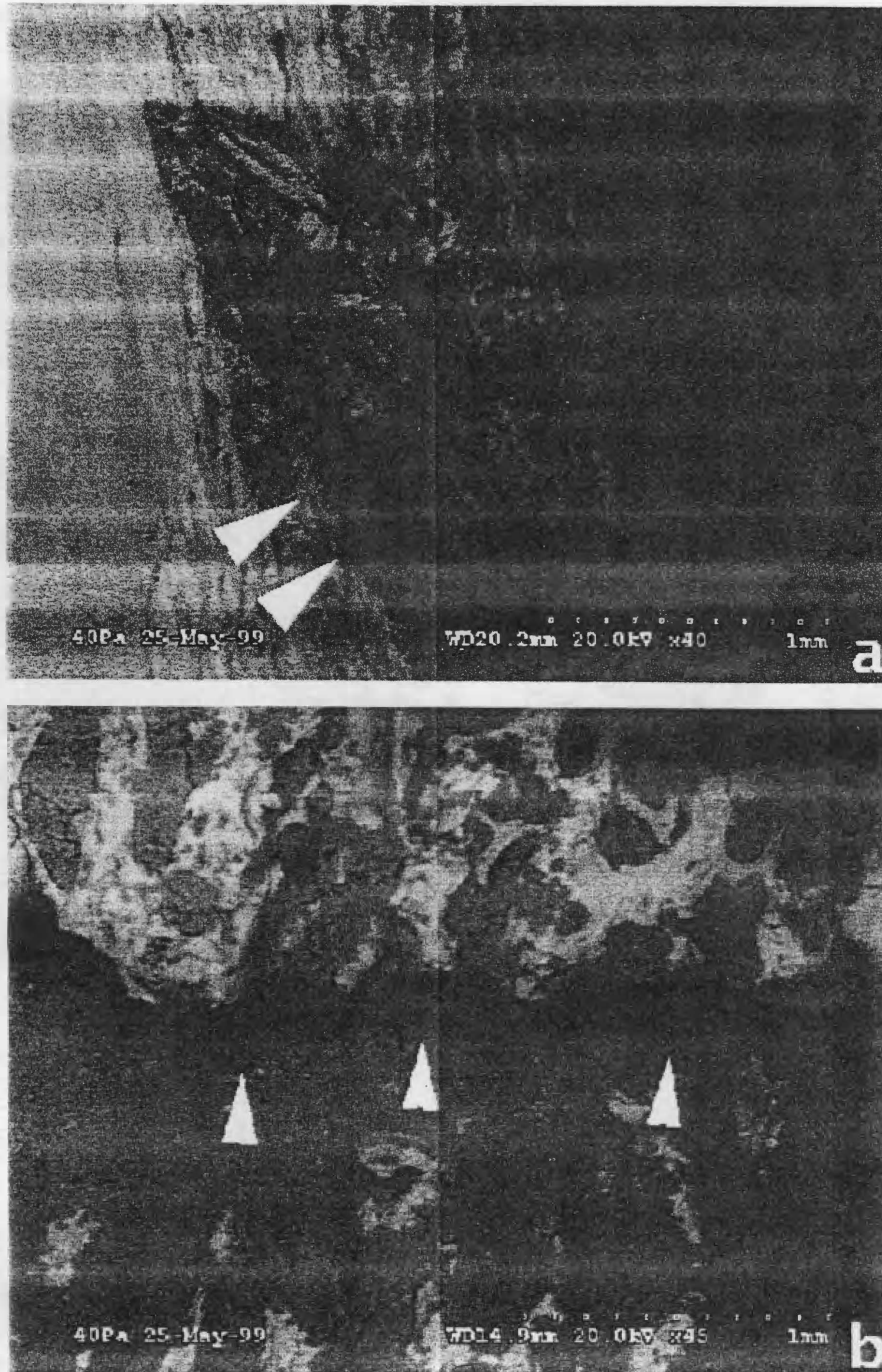


FIGURE 3.36. Scanning electron micrographs of two injuries from Fig 2 that demonstrate the characteristic narrowness of the Ekco™ stab wounds. a, this injury to the posterior edge of the twelfth right rib shows a nearly closed appearance (view of medial side, vertebral end toward top; magnification = x 40); b, this injury to the anterior edge of the twelfth right rib is quite narrow in its manifestation (view of anterior surface, sternal end toward top; magnification = x45).

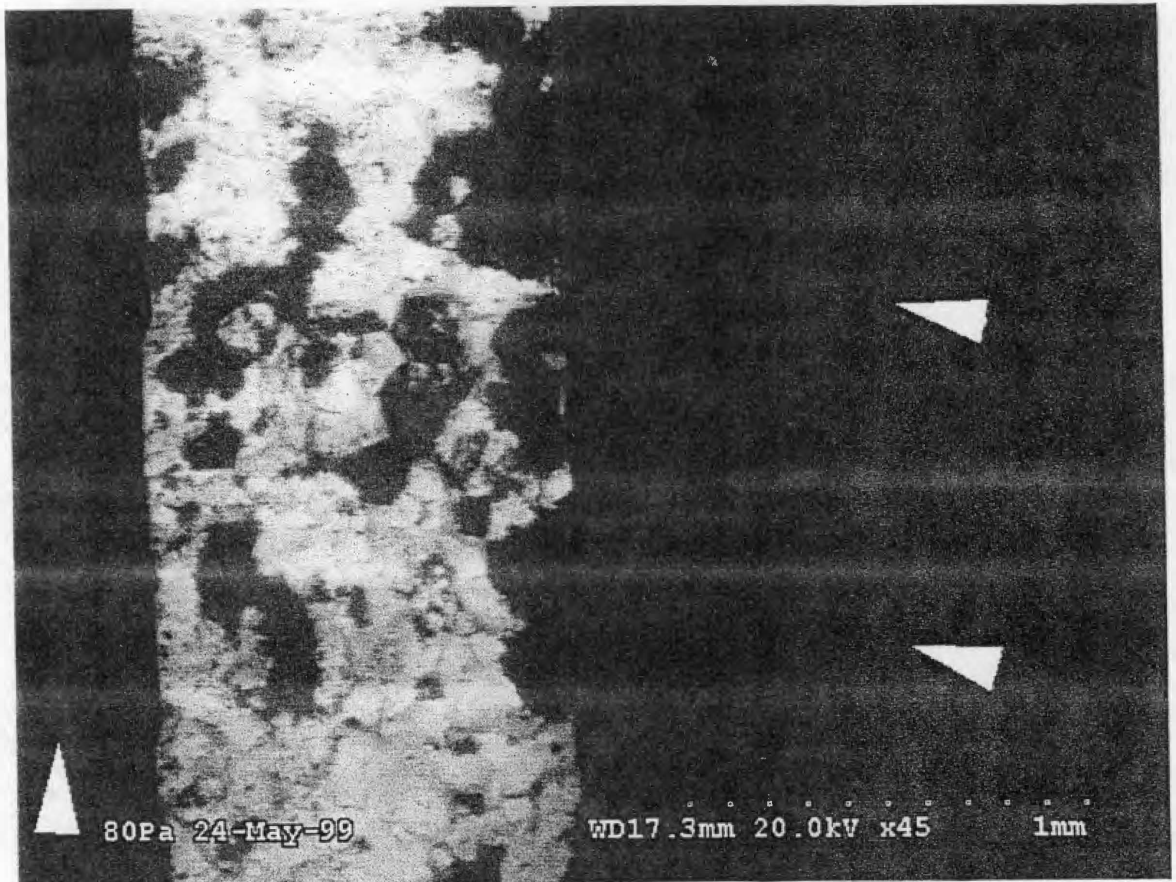


FIGURE 3.37. Scanning electron micrograph of the tip of the broken 5-inch Ekco™ utility knife embedded in the fourth right rib of Pig 2. White arrows point up the high degree of bone splintering around the broken portion of the knife blade on the lateral surface of the bone, while the metal of the blade shows up as a mottled, rough black and white object. Posterolateral edge of the rib is toward the top; magnification = x45.

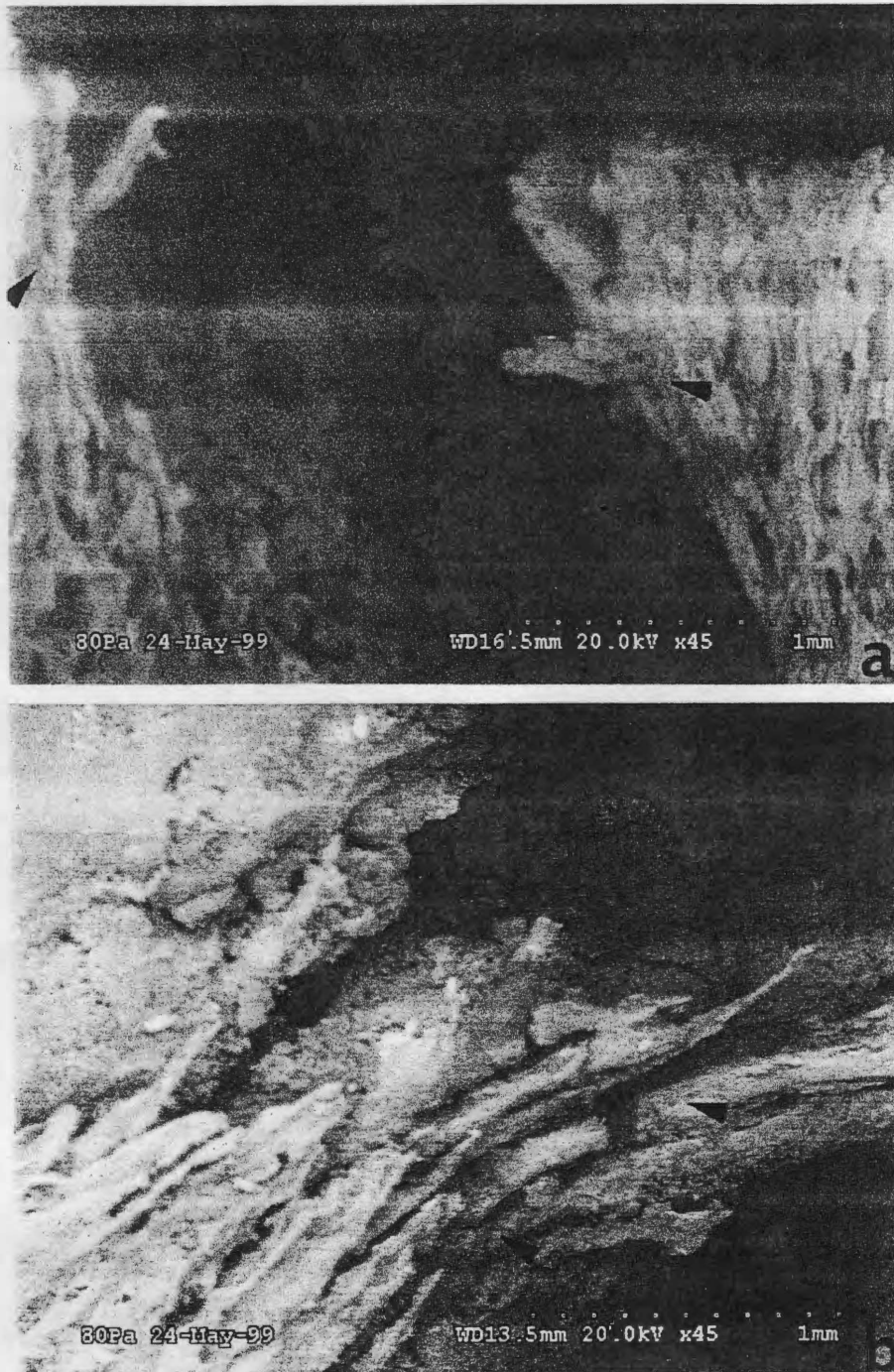


FIGURE 3.38. Scanning electron micrographs demonstrating bone splintering, pointed up with black arrows, along the edges of two wounds from Fig 2. a, point of entry for a deep stab into the sternal articulation of the fourth right rib (view of medial side, sternal articulation at top); b, vertebral edge of a stab wound on the posterior edge of the fifth right rib (view of lateral side, anterior edge toward top; magnification = x45).




FIGURE 3.39. Scanning electron micrographs showing lipping along the edges of a wound to the eighth right rib of Pig 2 (view of medial side, sternal end toward top). a, this image of the entry point of the stab into the rib displays a slight amount of bone splintering in conjunction with lip formation, both pointed up with black arrows (magnification = x50); b, as the wound progresses into the rib, chipping is no longer visible but lipping is still apparent, pointed up with black arrows (magnification = x70).




FIGURE 3.40. Scanning electron micrographs demonstrating the characteristic uneven/stepped appearance seen among the Ekco™ collection of injuries (Fig 2), pointed up with black arrows. a, the floor and walls of this stab to the sternal face of the fourth right rib show a narrow, stepped appearance (view of medial side, sternal face toward top; magnification = x70); b, the edges of this wound to the anterior surface of the eleventh right rib demonstrate an uneven, stepped appearance (view of anterior surface, sternal end toward top; magnification = x70); c, in this lateral view of an injury to the posterior edge of the fourteenth left rib, the beginnings of unevenness are visible (anterior edge toward top; magnification = x45); d, the edges of the bony flap that constitutes the sternal edge of this stab wound to the posterior edge of the fifteenth left rib show an uneven, stepped appearance (view of posterior surface, or the exterior, of the bone flap; magnification = x60).

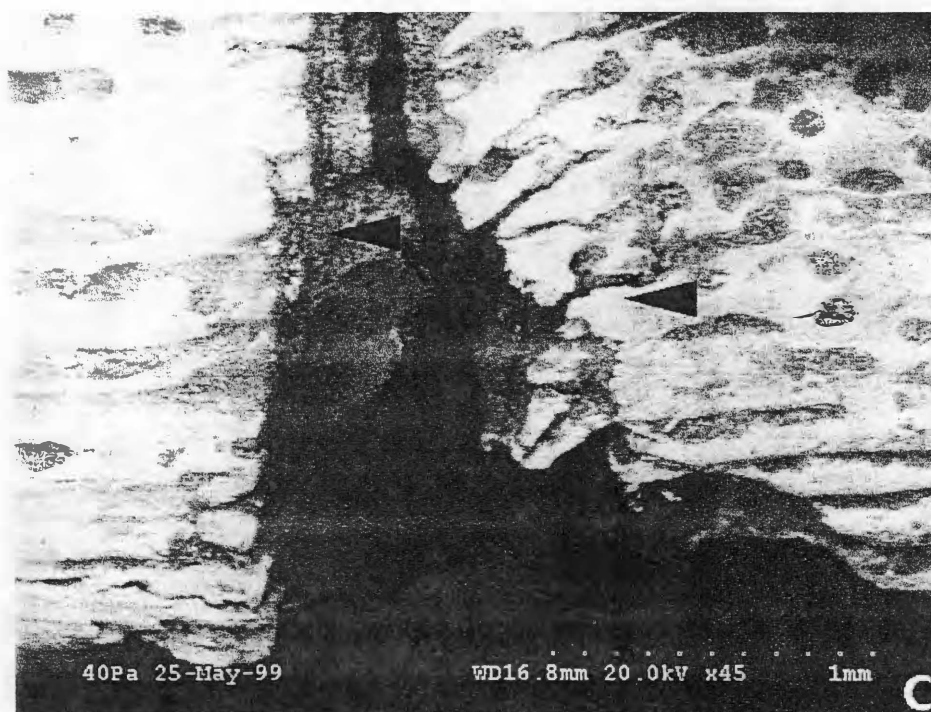

FIGURE 3.40 (continued).

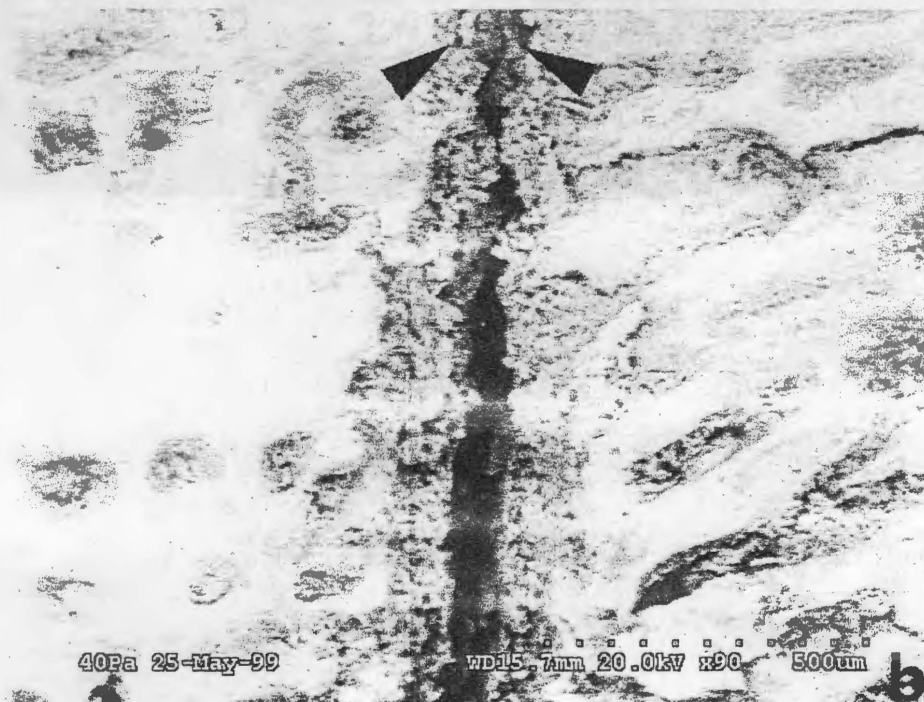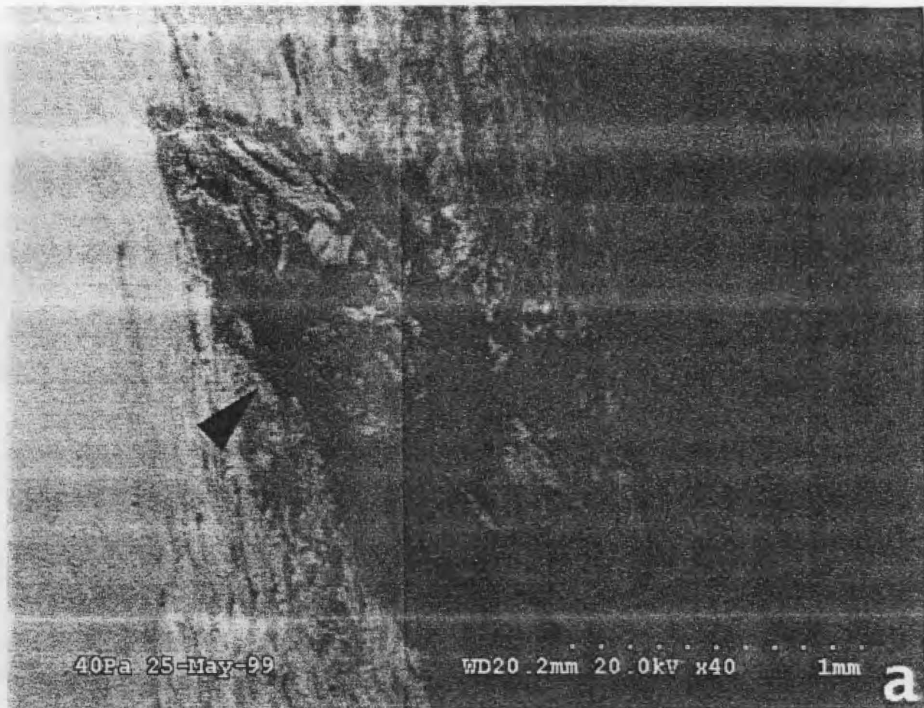


FIGURE 3.41. Scanning electron micrographs illustrating sharp tapering, pointed up with black arrows, of wound floors in rib injuries from Fig 2. a, medial view of a stab wound to the posterior edge at the midshaft region of the twelfth right rib (vertebral end is toward top; magnification = x40); b, this injury to the posterior edge of the fourteenth left rib shows significant constriction at its floor (view of lateral side, anterior edge toward top; magnification = x90).




FIGURE 3.42. Scanning electron micrograph showing roughness along the interior of one stab wound from the injuries in Fig 2. Medial view, including interior, of stab wound to the posterior edge of the thirteenth right rib demonstrates a similar appearance (vertebral end toward top; magnification = x50).

The Henckels® Injury Collection

Absolute lack of chipping and splintering along the edges and within the interiors of the collection of stab wounds is immediately apparent under SEM examination, and only the slightest amount of lipping is visible, making the extremely “clean” appearance of the Henckels® wounds seen at the previous levels of analysis even more striking at this high level of magnification. As in the low-power magnification examination, though the edges of the injuries’ walls appear to be uneven, the walls themselves continue to reflect this clean, almost “cauterized” appearance visible at the lower magnification levels (Figure 3.43). At the scanning electron level, the relatively narrow walls taper into a slightly pointed, wide, and shallow U — as opposed to the sharply-pointed V shape demonstrated by the Ekco injuries in Figure 3.41 — leaving the injury with less of a constricted, streamlined appearance as its immediate predecessors (Figure 3.44). Significant among the Henckels® stab wounds under scanning electron magnification, although certainly not a unique identifying characteristic, is the appearance of broken fibers caught within the walls of the wounds (Figure 3.45). This trait is visible to a small extent in the Ekco collection and to a wider degree in the Henckels collection at the low-power magnification level, but it is only manifest in the latter under SEM.

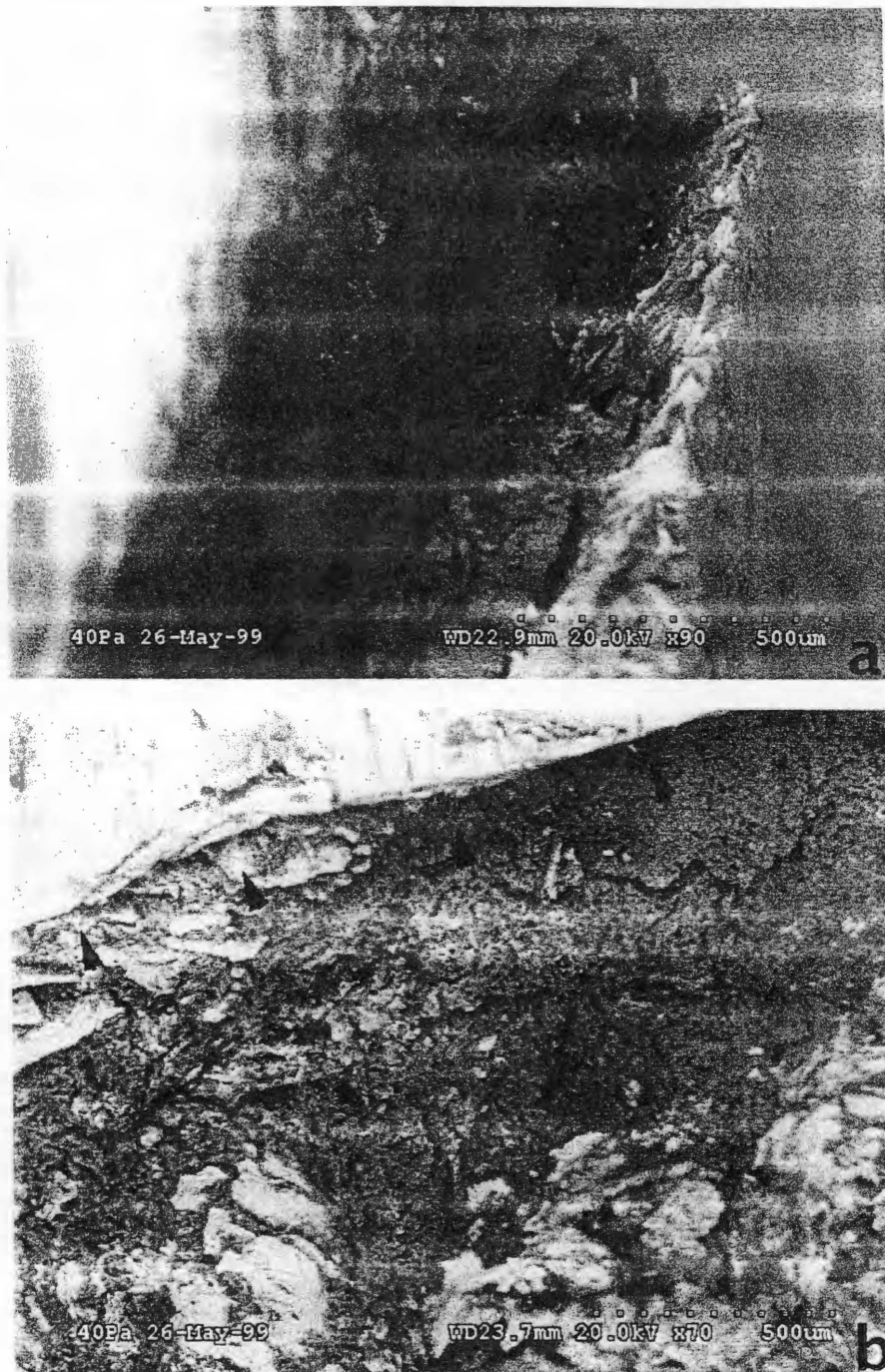


FIGURE 3.43. Scanning electron micrograph of two wounds showing the clean, uneven structure — pointed up with black arrows — that characterizes the injuries inflicted with the Henckels® knives (Fig 3). a, this injury to the anterior surface of the thirteenth right rib shows extreme cleanliness along its edge (view of lateral side, anterior surface at top right corner; magnification = x90); b, this injury to the posterior surface of the thirteenth left rib shows a clean, uneven aspect (view of posterior surface, sternal end toward top; magnification = x70).

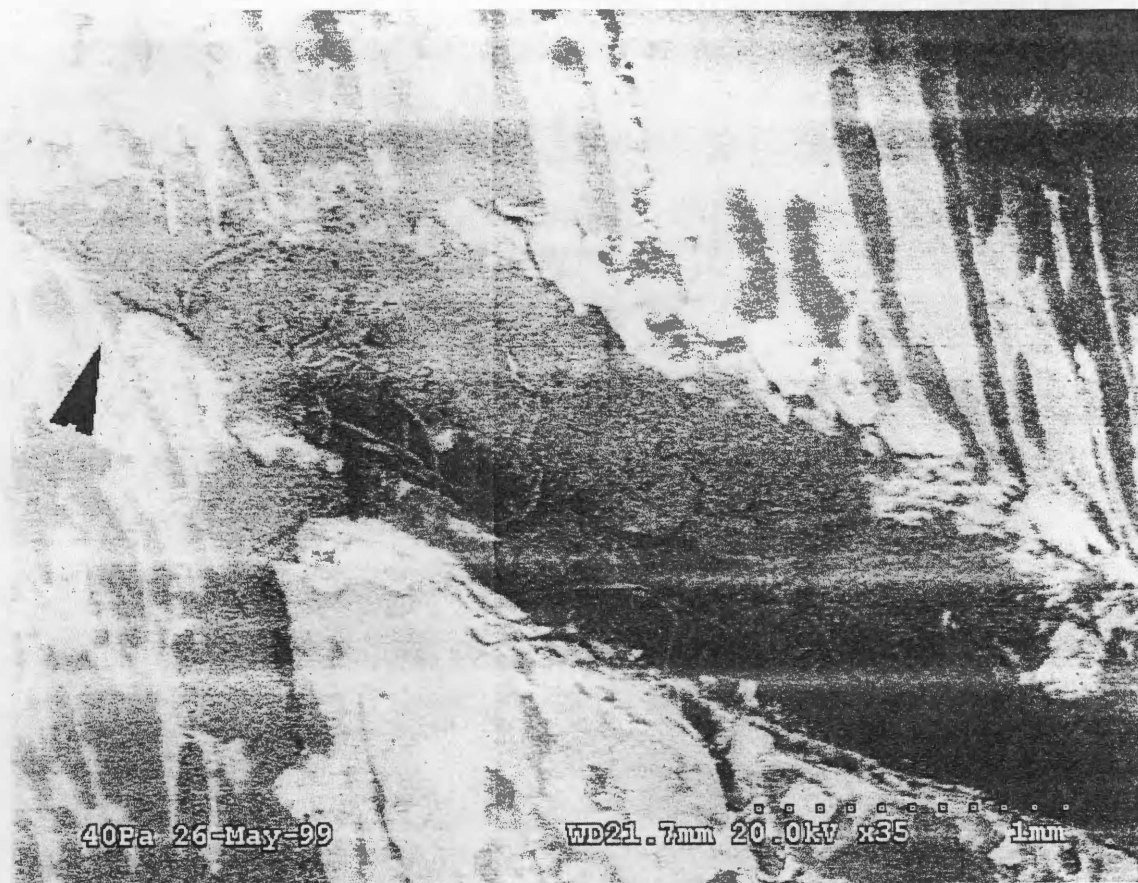

FIGURE 3.44. Scanning electron micrograph of the floor of a stab wound to the eleventh left rib of Pig 3. This demonstrates the slightly pointed, wide, shallow U shape found among the Henckels® injuries (view of lateral side, vertebral edge toward top; magnification = x35). Note also the very slight amount of lipping, "clean," uneven edges, and small fibers present within the wound, concentrated toward the floor area.

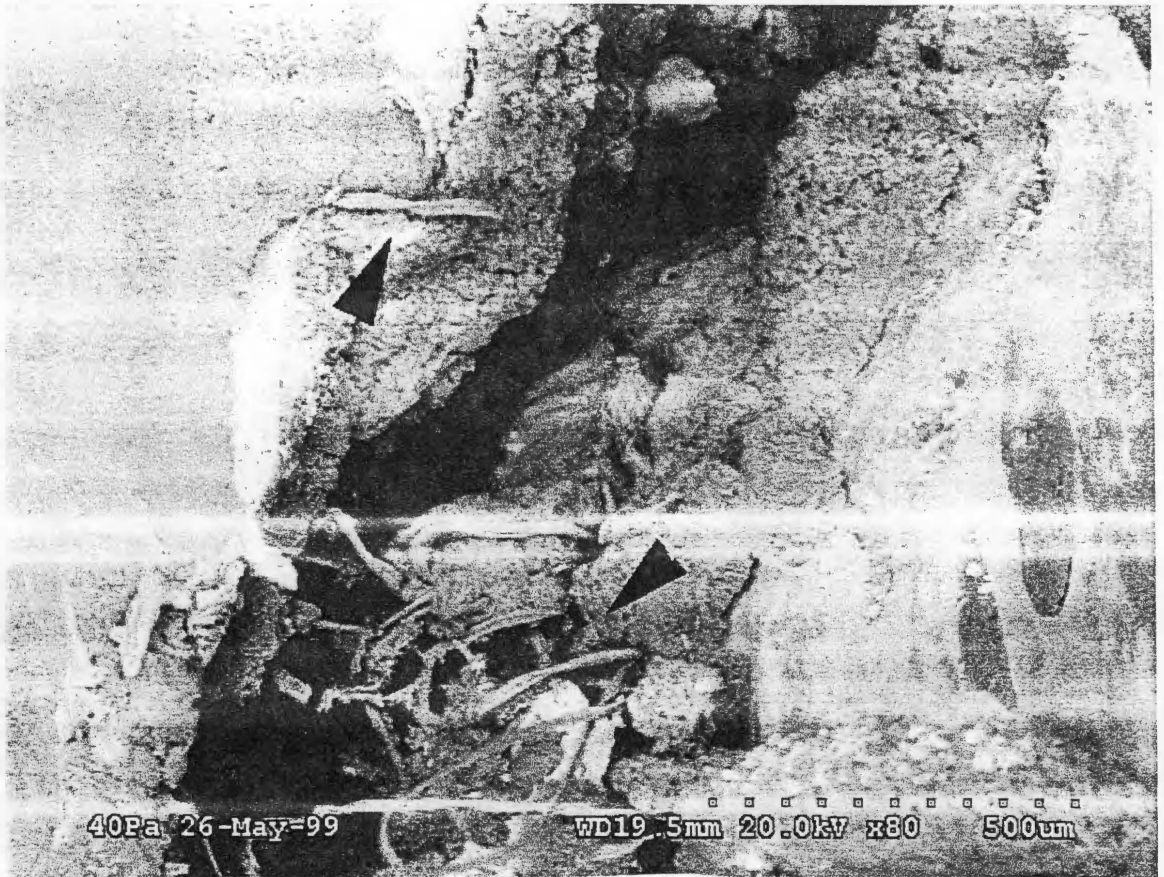


FIGURE 3.45. Scanning electron micrograph of the stab wound to the thirteenth right rib of Pig 3 at its floor, showing concentration of broken fibers caught in walls of wound. View of lateral side, vertebral edge toward top; magnification = x80.

CHAPTER 4

DISCUSSION AND CONCLUSIONS

STAB WOUND MORPHOLOGY: A CONSIDERATION

As we have seen, while research abounds when dealing with knife injuries in soft tissue — particularly skin — very little has been accomplished regarding the specifics of these injuries in bone. Still, the work that has been done to date proves itself informative to this research. The injuries that comprise this study assemblage correspond most closely with “false start” kerfs inflicted as an individual attempts to saw through bone or other material (Figure 4.1; see also Reichs 1998; Symes et al. 1998),⁸ and

The value of false starts in sawed bone analysis is immediate. While false starts do not always exist, the presence of a kerf is analogous to a completely sectioned bone reconstructed. The false start kerf diagramed . . . is composed of two initial corners, two walls, two floor corners, and a floor. While these features may not instantly appear to reflect saw blade design, it is important to recognize that they are indicative of the total cutting action of the saw [Symes 1992:53].

This type of wound can be particularly telling in the case of serrated knives, which “cut grooves that mimic dimensions of a blade’s cutting edge” (Symes 1992:53), increasing the wealth of information a forensic investigator may obtain from an intact knife wound injury. This is due to the fact that the teeth of a serrated knife have no set, a feature of most saw blades that strives to keep the saw blade from binding to the cutting medium by differing the positions of the teeth (Reichs 1998; Symes 1992; Symes et al. 1998). The serrated knife appears to be most closely related in form to fine toothed bow saws like hacksaws, and the class and individual characteristics of these implements are directly related to the morphology of the injuries they create; their manifestations in

⁸ Symes (1992) distinguishes between two separate types of wounds: the false start kerf and the break away spur/bone cross-section.

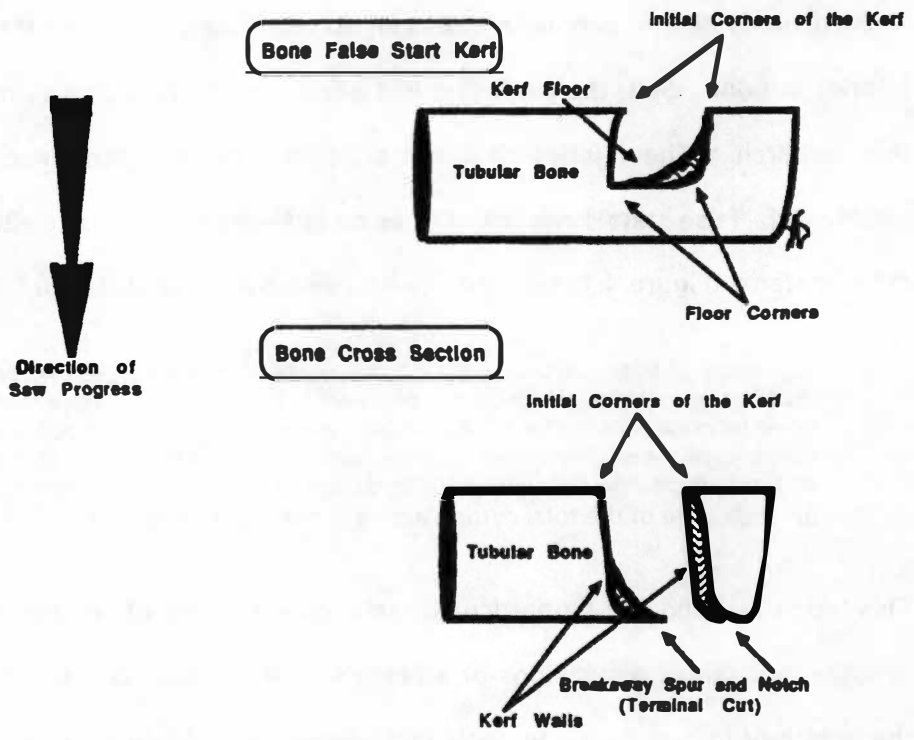


FIGURE 4.1. Illustrations of a false start kerf and bone cross section with breakaway spur. From Symes SA. Morphology of saw marks in human bone: identification of class characteristics. [Ph.D. dissertation.] Knoxville (TN): The University of Tennessee, 1992; 36.

bone coalesce to become a signature for two variations of Symes' "Class A" kerf illustrated in Figure 4.2 (Symes 1992:55-63). These characteristic stab wounds possess a number of distinctive traits, including one corner of the wound floor being straight while its opposite is rounded (Figure 4.2), and blade tapering that further affects the structure of the injury (Symes 1992). The wounds inflicted with serrated knives are generally narrow, and tend to take on a V shape (Reichs 1998; Symes 1992; see also Table 1.2). These implements also tend to generate little in the way of bone chipping or "wastage" (Reichs 1998:358-359). Additionally, serrated knives are apt to give rise to a significant amount of tooth scratch, or striations produced as the toothed blade leaves the stab, that may yield valuable information regarding the extent of space between teeth (Symes 1992; see also Bonte 1975). In her research dealing with cases of criminal dismemberment, where serrated knives may be employed as saws, Reichs (1998:354) points out that the resulting wounds normally present "one wall smooth and polished, the other striated." Sawing with serrated knives may also give rise to striae on the bone surface; these striae, when present, generally manifest themselves in a direction parallel to that of the floor of the stab wound (Reichs 1998). The fact that teeth of serrated blades are bereft of set increases a wound's diagnostic power, particularly if it is a cross-section (as opposed to a false start) type of injury (Symes 1992:63). This affects blade drift, which is a significant gauge of how much space lies between each tooth and is seen in injuries caused by large-toothed serrated knives with single-side serrations as well as in alternating set saws (Symes 1992; Symes et al. 1999).

Reichs (1998:359) points out that with knives bearing serrations on only one side of the cutting blade, "a cut may be produced with no uniform patterning," making generalizations about blade morphology somewhat difficult. Nevertheless, a number of conclusions as to the general morphological characteristics of the stab wounds under

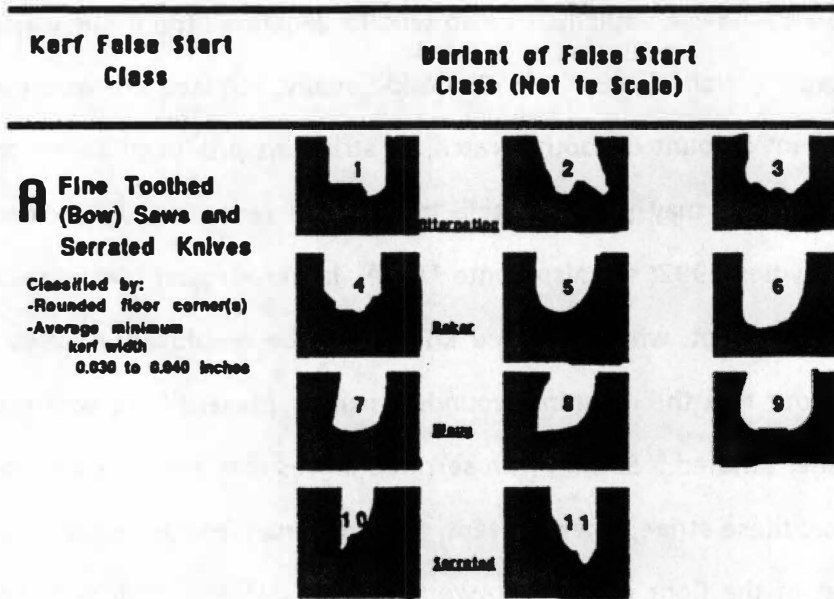


FIGURE 4.2. Variants within the Class A kerf type, which is comprised of fine toothed bow saws (variants 1-9) and serrated knives (variants 10-11). From Symes SA. Morphology of saw marks in human bone: identification of class characteristics. [Ph.D. dissertation.] Knoxville (TN): The University of Tennessee, 1992; 56.

consideration can be drawn. As we shall see below, clear differences are manifest among each of the three knife pairs within the characteristic categories established during the analysis. However, little to no difference was perceived between the two knives in each pair. Green (1978) points out that although kitchen knives are widely employed in the commission of homicides, they tend to bend and break easily, a trait that was demonstrated by a number of implements during the course of the experiment. This may have contributed to the lack of difference observed, as it altered the ratio of 5-inch to 8-inch knives used severely. On the other hand, given the fact that the blade structures of the knives in question are very similar in each pair, it is more likely that blade length (and, correspondingly, blade width) have little impact on the morphology of the injuries they inflict in bone tissue. The Farberware® “knife pair” is actually comprised of only one knife, the 5-inch utility knife, in the final analysis, as the 8-inch slicer knife broke before it inflicted any significant wounds.

Slightly more chipping/splintering and lip formation are apparent with the 8-inch Ekco knife. Additionally, the two injuries inflicted with the 5-inch Henckels® knife to Pig 3 are identical to each other in every way but in their manifestations of chipping/splintering. The presence of distinctive traits is generally supported at the magnified levels, with microscopic analysis serving more of an illustrative or corroborating purpose than identifying further differentiation in these features. Among the injuries inflicted with the Ekco™ knives, more chipping and lipping are uncovered under low-power magnification, and four wounds were observed to show less of a stepped appearance: 5 are observed to have more chipping and 3 are seen to manifest less; 4 injuries are observed to display more lip formation and 3 are seen to demonstrate less; and 4 wounds are observed to express less of a stair-stepped wall appearance while 1 is seen to show more. In the collection of injuries administered with

the Henckels® knives, slightly less chipping, lipping and unevenness are seen: 3 wounds are observed to have less chipping/splintering while 1 is seen to express more; 5 wounds are observed to show less lip formation while 2 are seen to display more; and 2 walls appear to be straight rather than uneven under magnification. Especially prominent among the collections of injuries inflicted with the Farberware®, Ekco™ and Henckels® knives are differences in degree of wound edge separation, most marked between the Farberware® knife, which produces mainly open or fairly open stab wounds, and the Henckels® knives, which inflict primarily narrow wounds; and wall appearance, which seems to be distinct for each type of knife. Stab wounds inflicted with the Farberware® knife, which has a thickness of 0.11 cm, generally demonstrate a “marked” degree of wound edge separation, while those administered with the Henckels® knives, which have thicknesses of 0.14 cm (5-inch) and 0.19 cm (8-inch), show a “moderate” degree of separation. When measured, the widths of these wounds are less than the thicknesses of the blades that were used to generate them. This is not surprising given the fact that the wounds were inflicted on fresh bone, which constricts after injury and thus shrinks the width (Reichs 1998), reducing the possibility of positive correlation between blade thickness and the degree to which the edges of the wounds are separated. Wounds inflicted with the Farberware® knife present uneven and sometimes undulating walls, those inflicted with the Ekco™ knives present uneven and stair-stepped walls, and those inflicted with the Henckels® knives present uneven and remarkably clean walls. Also apparent is slight variation in lip formation among the three sets of knives: the Farberware® injuries express very slight to slight amounts of lipping; the Ekco™ injuries, generally small amounts; and the Henckels® injuries, very slight lipping, if any. Chipping and splintering, for their part, seem diagnostic as well — over half of the injuries administered by the Farberware® knife show no chipping/splintering, while

approximately half of the wounds created with the Ekco™ knives show some chipping/splintering and less than half the wounds inflicted with the Henckels® knives show no chipping/splintering.

Generally, the vast majority of wounds constituting the study assemblage demonstrate the morphology described above, that of the V-shaped, narrow structure with one rounded floor corner. Narrowness and an approximately V-shaped tapered floor are observable at the visual level; under magnification, however, the interior structure of the cut becomes more evident, as the magnified eye allows for closer examination of the walls and floor. The wounds created with the Farberware® knife show structures that manifest significant wound edge separation, hardly tapering but coming to an open end in the form of a blocky, wide, V-shaped floor that in some cases is indeed rounded along one corner. Figure 3.33, for example, demonstrates this wide, blocky appearance that is straight along one edge and rounded along its opposite. These stand in marked contrast to the almost uniformly markedly separated stab wounds inflicted with the Henckels® knives. The injuries inflicted with the Henckels® knives are narrow wounds that end in more of a slightly pointed, shallow U shape (see Figure 3.44). These wounds and those resulting from the use of the Farberware® knife assume appearances resembling the serrated knife variants of the "Class A" kerf defined by Symes (see Figure 4.2; Symes 1992:55-57). The Ekco™ injuries, however, with distinctive narrow, tapered manifestations, do not. These injuries taper quite sharply to a fine, constricted point with little evidence of actual wound floor corners, giving the wound an appearance akin to an efficient, streamlined incision (see Figures 3.27, 3.41). The fact that the wounds administered with the Ekco™ knives express such an aspect is not surprising given the morphology of the blades, which are serrated on both sides of the blade rather than only one side. The identical serrations on both the left and right

sides seem to allow for no difference between the structures of the stab wounds' walls, although some difference was demonstrated among the injuries (see Table 3.3).

Bone chipping, splintering, and lip formation are quite plentiful throughout the injury assemblage and are relatively distinctive. These traits take on greater significance when the determination of directionality comes under consideration (see below). The presence of the amount of chipping seen, however, is somewhat surprising, since the blades of the knives in question are tapered along both sides; those knives that are serrated on only one side express serrations on the left side of the cutting edge while the right remains tapered. This implies that, rather than resulting from contact between the "non-tapered" side of the cutting edge (see Symes 1992:178-180) and the bone surface, chipping arises from contact between the bone surface and that beveled side of the blade that bears no serrations — with the present knives, the right side. Among the injury assemblage, chipping and splintering are concentrated mainly in the wound floors, while lip formation is generally more prominent on the vertebral edges of the wounds. The stab wounds inflicted with the Farberware® knife express very little in the way of chipping and splintering; where these are visible, however, they are seen in two places: the medial aspect of the wound floor and in areas of lipping. Lip formation is present in nearly all of the Farberware® stab wound specimens, and it is overwhelmingly observed on the vertebral edges of the stab wounds. In all levels of analysis, splintering is particularly apparent along these lipped edges (Figure 3.20). The Ekco™ collection of injuries demonstrate a significant amount of chipping and splintering, and lipping is ubiquitous, albeit in small amounts. Where they are seen, chipping and splintering are visible in both the medial and lateral aspects of the wound floors, and splintering, again, is quite visible in areas of lipping. Lip formation takes place in very slight and slight degrees in several locations around the wounds, but mainly along the vertebral edges.

The lipping in this particular collection of injuries presents in several specimens a unique structure wherein the lip itself appears to be cloven in two on the interior surface of the edge (Figure 3.25). In the Henckels® collection of wounds, chipping and splintering are seen in slight to small amounts in most of the specimens, while lip formation is not as easily found, at least at magnified levels. Chipping and splintering are generally found in the medial aspect of the wound floors, while some is also visible in the lateral aspect and along wound edges. Some chipping, as well as some lip formation, is visible in the regions where the few visible incision marks in this collection are seen to come together (Figure 3.31). Lip formation is generally not a striking feature of the Henckels® wounds, but where it is observed it is mainly on the vertebral edges of the wounds.

Surprisingly, few incision marks are found throughout the entirety of the stab wound assemblage, even under low-power and scanning electron magnification. These small auxiliary defects tend to occur when the knife blade leaves the stab wound and its teeth drag momentarily across the cortical bone, creating tiny superficial injuries; but their diagnostic power is low (Bonte 1975; Symes 1992). Thus, they are only touched upon in this consideration. Among the injuries administered with the Farberware® knife, only two showed any evidence of incision marks. Where this feature occurred, it did so in such a way as to appear to extend from the wound floor; in one injury, it appeared on the lateral surface, while on another this feature appeared on the medial surface. Three of the wounds comprising the Ekco™ collection show evidence of incision, with one instance being visible only under magnification. There is no apparent pattern as to location in these defects: one occurrence consisting of two small incisions flanks the vertebral edge of a wound; another manifestation, a set of three incision marks, is located near the sternal end of a wound; and the third lone incision extends from the

wound floor of its parent injury on the medial surface. The Henckels® collection of injuries shows slightly more frequent incision (four occurrences). The conglomerates of defects discussed in Chapter 3 (Figures 3.1, 3.9, 3.12, 3.31) show significant expressions of this feature, while the remaining instances of incision are similarly noticeable. Only one of these occurs on a lateral surface; generally, these defects present themselves on medial surfaces.

It is in the discussion of wound directionality that chipping, splintering, and lip formation come into play. These features are found to some extent in many of the specimens constituting the injury assemblage, and can aid in determining the direction of the cutting stroke by distinguishing between “push stroke,” when the implement enters the bone, and “pull stroke,” as it leaves the wound (Symes 1992:131-134, 214).

We see that

As the saw enters the side of the bone, the blade many times shaves the bone entrance to give it an almost polished and scalloped appearance. . . . Seldom is there chipping as the tooth enters the bone, and if present, it is difficult to observe.

Exit chipping is variable in saw cuts, but is present with few exceptions. . . .

Examination of bone on each end of the striae will reveal entrance shaving versus exit chipping and indicates direction of cutting stroke. Difficulties arise in the interpretation of these features. It is not possible to separate saw user preference versus the design of the saw. Since most saws do have a tooth designed to cut in a certain direction, pronounced chipping generally does indicate the direction of teeth exiting on the cutting stroke [Symes 1992:132-133].

Regardless of these troublesome aspects of the estimation of cutting stroke direction, the application of the characteristic features to the problem can prove to be enlightening. While no entrance chipping was apparent in any of the wounds in the assemblage, it appears that some exit chipping is indeed found — though not universally. Chipping, where it occurs in the injuries, is visible mainly in the medial aspect of cut floors, which is consistent with the manner in which the wounds were

inflicted during the stabbing experiment: generally, experimenters stood on the ventral, anterior, or posterior sides of the slain animals, who lay on their left or right sides according to the stage of the procedure, administering stabs to the side that was facing them. This resulted in stab wounds to the anterior or posterior edges of the ribs that entered the bones on the lateral surface. Thus, if entrance shaving had occurred, it would most likely have done so on the external (lateral) rib surfaces; and internal (medial) chipping is expected. In many cases, this chipping occurs in conjunction with and on the same edge as lip formation, which appears to result from the non-serrated side of the cutting edge coming into contact with the bone surface as the blade is pushed through. Thus, it may be possible to use this trait to re-construct how a blade entered a rib, particularly when used in conjunction with exit chipping.⁹ While the investigator differentiated between right-handed and left-handed “assailants” in an attempt to correlate stab wound directionality with handedness, it is apparent that little basis exists for a direct connection between handedness and wound directionality. This is due to the fact that wound directionality indicates only the way in which a blade entered its target bone (e.g., into the lateral surface of a bone from an anterior position), which is independent of handedness.

THE INVESTIGATION: A BRIEF DISCUSSION

The use of human cadavers would have been preferable from a strictly scientific point of view, as the situation would have far better approximated reality and yielded more applicable results regarding stab wounds in human ribs. Bromage and Boyde

⁹ For example, consider that a number of the wounds express lipping on the vertebral edge of the cut, along with chipping in the medial aspect of the cut floor. This is consistent with an experimenter standing on the posterior side of the animal and stabbing from above.

(1984:361, see 366) note that, "Bone tissue type is one variable related to the response of bone to a cutting tool," indicating that not all bone tissue is created equal. However, such research is unethical. Also, the somewhat random infliction of stab wounds on the "victims" complicated the investigation in that every aspect of the injuries administered by the "assailants" cannot be known for certain. We can say, for example, that it is likely that an experimenter was standing on the ventral portion of the animal when s/he made a stab wound, making it likely that wound attributes such as chipping and lip formation indicate cut direction, but we cannot be assured. Likewise, it is, for the most part, not possible to have pinpoint knowledge of which of the experimenters delivered a certain wound, or the force with which s/he inflicted it. The goal of this project from its inception was to conduct a practical investigation into the morphological characteristics of stab wounds inflicted in osseous tissue by three types of serrated knives, as affected by the knives' varying class characteristics. However, the morphological characteristics considered have shown themselves to be rather similar in the final analysis, as they have been generated from the use of knives with like class characteristics. The inclusion of additional knives of different construction would have alleviated this and yielded more varying results, likely leading to better results in terms of unique identifying traits.

In applying the research of her forbears to this analysis, what little of it there is, one of the implicit objectives quickly became the determination of whether or how much of the relatively clean, laboratory-setting experimental research that has graced the field so far would be appropriate in the course of everyday investigation; and as a rule it has proven to be relatively easily applied. The procedures employed herein were designed to mimic as closely as possible the methods by which such wounds would be inflicted in reality and subsequently examined, from the choice of the weapons wielded by the involved "assailants," to the covering of the "victims" with clothing and the involvement

of simple tools of investigation such as the low-power dissecting microscope. According to Blumenschine et al. (1996), this level of detail is sufficient to uncover unique identifying traits for cut marks, and preferred to SEM technology because of its relatively lesser costs in time and money. In their work, in which they seek to prove this point, the authors follow a similar progression in analysis as that used in this study: visual examination followed by low-power magnification with hand lens or stereo microscope (1996). In this study, the examination under low-power magnification conducted following the visual inspection builds upon the results of this inspection, bringing to bear this basic technology to examine in increasing detail and complexity the stab wounds under study. Many of the characteristics identified during the course of the visual inspection are clarified with the low-power magnification examination. Some characteristics that do not seem terribly diagnostic appear to take on greater importance when the dissecting microscope and/or magnifying lens is applied to the analytical procedure. While depth and wound edge separation do not change when moving from one stage to another - these are relative qualitative terms - the remaining traits are explored in greater detail and their apparent diagnostic utility is either confirmed or denied by their persistence or failure at the level of low-power magnification. Nevertheless, employment of the SEM in this study has been enlightening as to its utility in forensic investigation. As described, SEM technology is proving itself to be an ascending star in the world of anthropological cut mark analysis, although it has not been applied in the realm of forensic research and investigation (see Houck 1998). Financial constraints, limited access, time, and inadequate technical training generally disallow a forensic anthropological investigator from making effective use of this important new resource at this point in time, to the point that Blumenschine et al. (1996:504) consider "the expense, time, and volume restriction of the SEM unnecessary"

in light of low-power magnification techniques. These limiting factors may be more powerful deterrents to implementing SEM technology for a forensic investigator working without benefit of easy access to a medical center or university where a scanning electron microscope resides. Nevertheless, its utility can be great if employed in conjunction with other research methods, even though its application is limited for the forensic anthropologist at this point due to the factors described above. The results of the procedures followed during this study are meticulously documented in the hope that they will inform future research, especially when viewed in light of the statistics surrounding homicides both in the United States and abroad.

FINAL SUMMARY

Crime statistics from around the world indicate that, while firearms have become the deadly weapon of choice for many, bladed weapons still run an alarmingly close second. Kitchen knives are easily obtained and can be lethal, and as such the analysis of the wounds they inflict, particularly at the osteological level, demand the attention of the forensic community. The main objective of this investigation is to generate a list of traits that characterize three pairs of common serrated kitchen knives through a three-tiered analysis that examined stab wounds administered with these knives to three euthanized domestic pigs at the gross morphological, low-power magnification, and scanning electron microscopy levels. By doing so, the investigator hopes to better enable herself and other forensic investigators to more easily determine the identity of a particular homicide weapon, or to more accurately inform the investigations of law enforcement officers as to the type of weapon they might be searching for in a particular case. This goal is met in the list of diagnostic features for the Farberware,[®] Ekco[™] “Flint” and Henckels[®] “Eversharp-Pro” knife sets presented in Table 4.1.

TABLE 4.1. Summary of stab wound morphology features diagnostic of the Farberware,[®] Ekco[™] "Flint," and Henckels[®] "Eversharp-Pro" knives used in this study.

FEATURE	FARBERWARE	EKCO "FLINT"	HENCKELS "EVERSHARP-PRO"
DEGREE OF WOUND EDGE SEPARATION	Marked	Moderate/Marked	Moderate
CHIPPING/SPLINTERING	Little (slight to moderate) evident	Some (slight to moderate) evident	Much (moderate to marked) evident
LIP FORMATION	Some (slight) evident	Some (slight to moderate) evident; this may show divided or "cleft-lip" appearance	Little (slight to moderate) to none evident
WALL/FLOOR APPEARANCE	Uneven, undulating appearance with wide, rectangular V-shaped floor	Uneven, stepped appearance with extremely tapered floor	Uneven, clean appearance with slightly pointed U-shaped floor

The Farberware[®] knives have slender, thin blades, straight spines, and edges that curve to the point that demonstrate an edge bevel along the length of the right side and bear serrations in an alternating major/minor blade pattern along the non-beveled left side. The stab wounds inflicted with these knives are injuries that express a marked degree of wound edge separation, little (slight to moderate, if any) chipping or splintering, some (mainly slight) lip formation, and an uneven, undulating wall appearance with wide, blocky and rectangular V-shaped wound floors. The Ekco[™] knives have blades that are slightly wider but of equal thickness with spines and edges that both taper to the point, giving the implement an extended pyramidal shape, and show a constant scalloped serration pattern on both sides of the blade. The stab wounds inflicted with these knives show some variation in wound edge separation (moderate to marked), slight to moderate degrees of chipping/splintering and lip formation, some evidence of a "cleft-lip" appearance in those injuries that do express lip formation, and uneven, stair-stepped walls with extremely tapered wound floors. The

Henckels® “Eversharp-Pro” knives have wide, thick blades that appear to be less prone to bending and breaking than the previous knife sets, spines and edges that both taper to a point in an extended triangular shape, a uniform edge bevel on the right side and a constant wide serrated blade pattern (5-inch) or constant narrow serrated blade pattern (8-inch) on the left. The stab wounds inflicted with these knives demonstrate a moderate degree of wound edge separation, moderate to marked degrees of chipping and splintering, little (slight to moderate) to no lip formation, and an uneven, clean wall appearance with slightly pointed U-shaped wound floors. In considering these traits, it is important to bear in mind that one feature alone does not a positive identification make; these seem to work best when used as a suite. Greater weight, however, may be given to wall appearance and floor structure, as they seem to be especially distinctive for each type of implement. Additionally, we have seen that a determination of cut directionality may be obtained through the careful application of some of these characteristics, although this does not appear to indicate the handedness of the individual who inflicted the stab wound.

...by ... for ...

... of ...

... in ...

100-100

... the ...

REFERENCES

... London ...

... study of ...

... the ...

... and ...

... of ...

REFERENCES

- Adelson L. Homicide by cutting and stabbing. In: Adelson L, editor. The pathology of homicide. Springfield (IL): Charles C Thomas, 1974. p 319-377.
- Andahl RO. The examination of saw marks. *Journal of Forensic Sciences* 1978;18:31-46.
- Avis SP. Homicide in Newfoundland: A nine-year review. *Journal of Forensic Sciences* 1996;41:101-105.
- Bass WM. Outdoor decomposition rates in Tennessee. In: Haglund WD, Sorg MH, editors. *Forensic taphonomy: the postmortem fate of human remains*. Boca Raton (FL): CRC Press, 1997; 181-186.
- Behrensmeyer AK, Gordon KD, Yanagi GT. Trampling as a cause of bone surface damage and pseudocutmarks. *Nature* 1986;319:768-771.
- Biasotti AA. A statistical study of the individual characteristics of fired bullets. *Journal of Forensic Sciences* 1959;4:34-50.
- Biasotti AA. The principles of evidence evaluation as applied to firearms and toolmark identification. *Journal of Forensic Sciences* 1964;9:428-433.
- Blumenschine RJ. Percussion marks, tooth marks, and experimental determinations of the timing of hominid and carnivore access to long bones at FLK *Zinjanthropus*, Olduvai Gorge, Tanzania. *Journal of Human Evolution* 1995;29:21-51.

Blumenschine RJ, Marean CW, Capaldo SD. Blind tests of inter-analyst correspondence and accuracy in the identification of cut marks, percussion marks, and carnivore tooth marks on bone surfaces. *Journal of Archaeological Science* 1996;23:493-507.

Blumenschine RJ, Selvaggio MM. On the marks of marrow bone processing by hammerstones and hyenas: their anatomical patterning and archaeological implications. In: Clark JD, editor. *Cultural beginnings: approaches to understanding early hominid life-ways in the African savanna*. Bonn: Dr Rudolf Habelt GmbH, 1991; 17-32.

Bonte W. Tool marks in bones and cartilage. *Journal of Forensic Sciences* 1975;20:315-325.

Boyde A. Scanning electron microscope studies of bone. In: Bourne GH, editor. *The biochemistry and physiology of bone*. Volume I. Second edition. New York (NY): Academic Press, 1972; 259-310.

Bromage TG. Interpretation of scanning electron microscopic images of abraded forming bone surfaces. *American Journal of Physical Anthropology* 1984;64:161-178.

Bromage TG, Boyde A. Microscopic criteria for the determination of directionality of cutmarks on bone. *American Journal of Physical Anthropology* 1984;65:359-366.

Bunn HT. Archaeological evidence for meat-eating by Plio-Pleistocene hominids from Koobi Fora and Olduvai Gorge. *Nature* 1981;291:574-577.

Bunn HT. Patterns of skeletal representation and hominid subsistence activities at Olduvai Gorge, Tanzania, and Koobi Fora, Kenya. *Journal of Human Evolution* 1986;15:673-690.

Bunn HT, Kroll EM. Systematic butchery by Plio/Pleistocene hominids at Olduvai Gorge, Tanzania. *Current Anthropology* 1986;27:431-452.

Burd DQ, Gilmore AE. Individual and class characteristics of tools. *Journal of Forensic Sciences* 1968;13:390-396.

Burd DQ, Greene RS. Tool mark comparisons in criminal investigations. *American Journal of Police Science* 1948;39:379-391.

Burd DQ, Kirk PL. Tool marks: factors involved in their comparison and use as evidence. *Journal of Criminal Law and Criminology* 1942;32:679-686.

Federal Bureau of Investigation. *Uniform Crime Reports for the United States* 1996. Washington DC: USGPO, 1997.

Federal Bureau of Investigation. *Uniform Crime Reports for the United States* 1997. Washington DC: USGPO, 1998.

Ferrada-Noli M, Asberg M, Ormstad K. Suicidal behavior after severe trauma. Part 2: the association between methods of torture and of suicidal ideation in posttraumatic stress disorder. *Journal of Traumatic Stress* 1998;11:113-124.

Flynn EM. Toolmark identification. *Journal of Forensic Sciences* 1957;2:95-106.

Frayner DW, Bridgens JG. Stab wounds and personal identity determined from skeletal remains: A case from Kansas. *Journal of Forensic Sciences* 1985;30:232-238.

Green MA. Stab wound dynamics — a recording technique for use in medico-legal investigations. *Journal of Forensic Sciences Soc* 1978;18:161-163.

Hasekura H, Fukushima H, Yonemura I, Ota M. A rare suicidal case of a ten-year-old child stabbing himself in the throat. *Journal of Forensic Sciences* 1985;30:1269-1271.

Hendry WT, Stalker AL. Stab wound of the medulla by handle of metal comb. *Medicine, Science, and the Law* 1967;7:213-5.

Houck MM. Skeletal trauma and the individualization of knife marks in bones. In: Reichs KJ, editor. *Forensic osteology: advances in the identification of human remains*. Springfield (IL): Charles C Thomas, 1998;410-424.

Hunt AC, Cowling RJ. Murder by stabbing. *Forensic Science International* 1991;52:107-12.

Knight B. The dynamics of stab wounds. Forensic Science 1975;6:249-255.

Kuroda N, Saito K, Takada A, Watanabe H, Tomita A, Murai T, Yanagida J. Suicide by self-stabbing in the city of Tokyo — a review of accumulated data from 1976 to 1995. Nippon Hoigaku Zasshi (Japanese Journal of Legal Medicine) 1997;51:301-306.

Love JC. Cut mark classification with energy dispersive x-ray analysis. [Unpublished Master's Thesis, University of Tennessee.]. Knoxville (TN), 1998.

Mann RW, Bass WM, Meadows L. Time since death and decomposition of the human body: variables and observations in case and experimental field studies. Journal of Forensic Sciences 1990;35:103-111.

Mansingh A, Ramphal M. The nature of interpersonal violence in Jamaica and its strain on the national health system. West Indian Medical Journal 1993;42:53-56.

Marieb EN. Human anatomy and physiology. Third edition. Redwood City (CA): Benjamin/Cummings, 1995.

May LS. The identification of knives, tools and instruments a positive science. American Journal of Police Science 1930;1:246-259.

Moore KL. Clinically oriented anatomy. Third edition. Baltimore (MD): Williams and Wilkins, 1992.

Murray LA, Green MA. Hilts and knives: a survey of ten years of fatal stabbings. *Medicine, Science, and the Law* 1987;27:182-184.

Osterburg JW. The Warren Commission: report and hearings. A commentary on issues of importance in the study of investigation and criminalistics. *Journal of Forensic Sciences* 1966;11:261-271.

Potts R, Shipman P. Cutmarks made by stone tools on bones from Olduvai Gorge, Tanzania. *Nature* 1981;291:577-580.

Rabinowitsch A. Medico-legal conclusions on the form of the knife used, based on the shape of stab wounds produced. *Journal of Forensic Medicine* 1959;6:160-165.

Rao VJ, Hart R. Tool mark determination in cartilage of stabbing victim. *Journal of Forensic Sciences* 1983;28:794-799.

Reichs KJ. Postmortem dismemberment: recovery, analysis and interpretation. In: Reichs KJ, editor. *Forensic osteology: advances in the identification of human remains*. Springfield (IL): Charles C Thomas, 1998. p 353-388.

Sauer NJ. Manner of death: skeletal evidence of blunt and sharp instrument wounds. In: Rathbun TA, Buikstra JE, editors. *Human identification: case studies in forensic anthropology*. Springfield (IL): Charles C Thomas, 1984;176-184.

Sherman MM, McCormick JR, Berger RL. The thorax. In: Tedeschi CG, Eckert WG, Tedeschi LG, editors. Forensic medicine: a study in trauma and environmental hazards. Volume I: mechanical trauma. Philadelphia (PA): WB Saunders, 1977; 199-210.

Shipman P, Rose J. Evidence of butchery and hominid activities at Torralba and Ambrona; an evaluation using microscopic techniques. Journal of Archaeological Science 1983a;10:465-474.

Shipman P, Rose J. Early hominid hunting, butchering, and carcass-processing behaviors: approaches to the fossil record. Journal of Anthropological Archaeology 1983b;2:57-98.

Sisson S. The anatomy of the domestic animals. Philadelphia (PA): W. B. Saunders, 1921.

Sivaram S. Unusual instrument marks on bones. Forensic Science 1977;9:109-110.

Spitz WU. Sharp force injury. In: Spitz WU, Fisher RS, editors. Medicolegal investigation of death. Springfield (IL): Charles C Thomas, 1980;159-201.

Spitz WU, Petty CS, Fisher RS. Physical activity until collapse following fatal injury by firearms and sharp, pointed weapons. Journal of Forensic Sciences 1961;6:290-300.

Start RD, Milroy CM, Green MA. Suicide by self-stabbing. *Forensic Science International* 1992;56:89-94.

Stewart TD. *Essentials of forensic anthropology*. Springfield (IL): Charles C Thomas, 1979.

Strung NM. *An encyclopedia of knives*. Philadelphia (PA): J. B. Lippincott, 1976.

Symes SA. *Morphology of saw marks in human bone: identification of class characteristics*. [Dissertation]. Knoxville (TN): The University of Tennessee, 1992.

Symes SA, Berryman HE, Smith OC. Saw marks in bone: introduction and examination of residual kerf contour. In: Reichs KJ, editor. *Forensic osteology: advances in the identification of human remains*. Springfield (IL): Charles C Thomas, 1998;389-409.

Symes SA, Smith OC, Gardner CD, Francisco JT, Horton GA. Anthropological and pathological analyses of sharp trauma in autopsy. [Paper G40]. 51st Annual Meeting of the American Academy of Forensic Sciences. Orlando (FL), February 15-20, 1999.

Thomas F. Milestones in forensic medicine: the Belgian contribution. *Medicine, Science, and the Law* 1964;4:155-170.

Thomas F. Comments on the discovery of striations matching and on early contributions to forensic firearms identification. *Journal of Forensic Sciences* 1967;12:1-7.

Thomas F, Gallet G. Homicide by blows dealt to the head by means of an axe. Identification of the weapon. *International Criminal Police Review* 1947;1:13-20.

U.S. Department of Justice Bureau of Justice Statistics, 1998, 11 December, Bureau of Justice Statistics Homicide Trends in the U.S.: Weapons Used <<http://www.ojp.usdoj.gov/bjs/homicide/weapons.htm>> (Accessed 01/29/99).

Walker PL, Long JC. An experimental study of the morphological characteristics of tool marks. *American Antiquity* 1977;42:605-616.

Warren JI, Hazelwood RR, Dietz PE. The sexually sadistic serial killer. *Journal of Forensic Sciences* 1996;41:970-974.

White TD. Cut marks on the Bodo cranium: a case of prehistoric defleshing. *American Journal of Physical Anthropology* 1986;69:503-509.

VITA

Born in Teaneck, New Jersey in November of 1975, Jenny Rebecca Martin proceeded to grow into an inquisitive and intellectually daring young woman who graduated as co-salutatorian from Immaculate Conception High School in June 1993. She enrolled in Seton Hall University the following fall, where she served as a tutor and proofreader for fellow students, teaching and research assistant to Drs. Marla Powers and Herbert Kraft, and Anthropology Club President for the 1995-1996 academic year. During this time, the enthusiastic student maintained 4.00/4.00 averages in both her Anthropology major and Sociology minor and was named to the Dean's List for the Fall 1993 semester and the academic years 1994-95 and 1995-96. While attending Seton Hall, she extended her knowledge by participating in two sessions of the Lakota Field School administered jointly by Drs. Marla and William Powers (Seton Hall and Rutgers Universities), producing from the research conducted while living and working on the Pine Ridge Reservation in South Dakota two unpublished ethnographies dealing with the Lakota culture. Martin graduated magna cum laude in December of 1996, recipient of the Anthropology Honors Citation (ex aequo). Until her education at The University of Tennessee in August 1997 began, she continued her work for Dr. Kraft at the Seton Hall University Museum, performing extensive original research on the historic Westward Migration of the Lenape People for Kraft's upcoming *The Lenape/Delaware Indian Heritage*. Becoming a member of Lambda Alpha in 1998, Martin completed her first-year studies in the Department of Anthropology and moved into active pursuance of her Master's Degree in Physical/Forensic Anthropology, taking on casework for the Forensic Anthropology Center under the auspices of Dr. William M. Bass and undertaking her thesis research in the Fall 1998 semester; in the summer intervening between the Spring

and Fall semesters, Martin remained active in an internship in the Pathology Department of Hackensack University Medical Center in Hackensack, New Jersey. Looking forward to the next phase of her career, she completed her Spring 1999 semester Graduate Assistantship in Forensic Anthropology and her cut mark research in July of 1999, planning to put to good use the skills she learned as a forensic anthropologist in the law enforcement community.