

## Facial antibioma formation: A case report.

Haydar Mahdey,<sup>1</sup> Danish Muzaffar,<sup>1</sup>  
 Muhammad Sohail Zafar<sup>2,3</sup> & Muhammad Safwan Malik.<sup>4</sup>

**Affiliations:** <sup>1</sup>Faculty of Dentistry, SEGi University, Malaysia. <sup>2</sup>Department of Restorative Dentistry, College of Dentistry, Taibah University, Al Madinah Al Munawwarah, Saudi Arabia. <sup>3</sup>Department of Dental Materials, Islamic International Dental College, Riphah International University, Islamabad, Pakistan. <sup>4</sup>Faculty of Dentistry, Karachi Medical and Dental college, Karachi, Pakistan.

**Corresponding author:** Muhammad S. Zafar. Department of Restorative Dental Sciences, College of Dentistry, Taibah University, P.O. Box 2898, Al Madinah Al Munawwarah, Saudi Arabia. Phone:(966) 507544691. E-mail: MZAFAR@taibahu.edu.sa

**Receipt:** 03/31/2018 **Revised:** 05/10/2018  
**Acceptance:** 06/26/2018 **Online:** 07/30/2018

**Conflict of interests:** The authors declare no conflicts of interest.

**Funding:** None.

**Authors' contributions:** Study conception, design, ethical aspect and surgical procedure: Haydar Mahdey, Danish Muzaffar, Analysis and manuscript analysis, Danish Muzaffar, Muhammad Safwan Malik, critical review, revisions and correspondence, Muhammad Sohail Zafar.

**Acknowledgements:** None.

**Cite as:** Mahdey H, Muzaffar D, Zafar MS & Malik MS. Facial antibioma formation: A case report. J Oral Res 2018; 7(6):250-253. doi:10.17126/joralres.2018.055

**Abstract:** Odontogenic infections are associated with a variety of microorganisms. Antibiotics are commonly used for the management of various dental infections and have a proven role in decreasing morbidity and mortality caused by infectious diseases. The frequent and over usage of antibiotics has been associated with a number of consequences such as the selection of drug resistant strains, and the formation of antibiomas. Antibiomas are characterized by the formation of a localized pathology surrounded by thick fibrous tissues in response to long term antibiotics use. An established antibioma is characterized by a tough fibrous swelling accompanied by painful or painless swelling, intermittent fever and constitutional symptoms. In this article, we are reporting the case of a facial antibioma formed due to prolonged use of antibiotics prescribed for a residual periapical infection following endodontic treatment. In addition, the association of using antibiotics in this context is discussed.

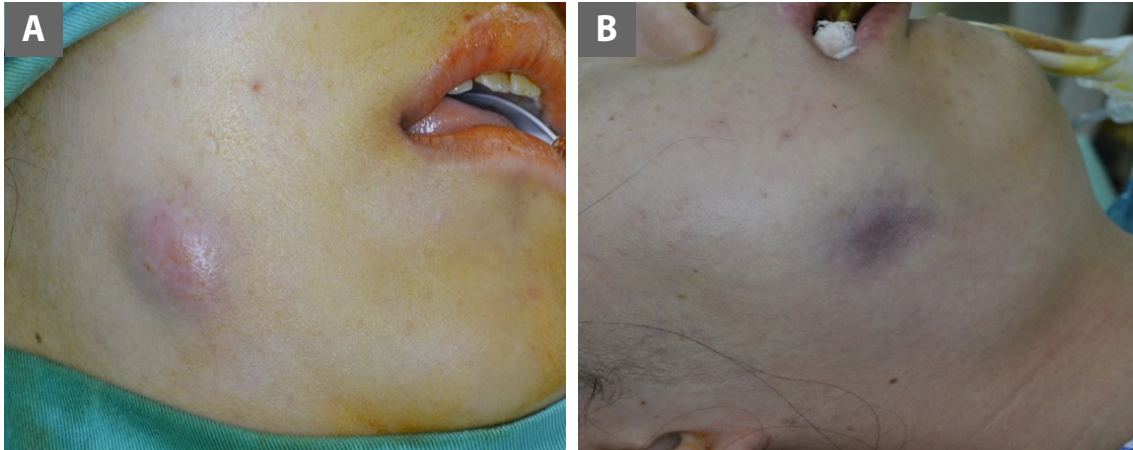
**Keywords:** *Antibioma; antibiotics; mandibular abscess.*

### INTRODUCTION.

Antibiotics are drugs used to restrict the growth of microorganisms. Antibiotics are commonly used for various dental infections and have a proven role in decreasing morbidity and mortality caused by infectious diseases.<sup>1</sup> Since most orofacial infections are mainly odontogenic in origin<sup>2</sup> the prescription of antibiotics has become an integral part of dental practice. In addition, odontogenic infections are associated with a variety of microorganisms and dentists do not routinely investigate which bacterial species is responsible for the infection, and hence prescribe broad spectrum antibiotics.<sup>3</sup> The frequent and over use of antibiotics has been associated with various issues such as the selection of resistant strains and the development of drug resistance in general.<sup>3,4</sup> Factors such as drug interactions with analgesics<sup>3</sup> or a tendency for self-medication<sup>5,6</sup> may also be contributing factors.

The management of odontogenic infections of pulpal origin including pulpitis and apical periodontitis, warrants operative interventions fillings, root canal therapy or extraction, as antibiotics are unlikely to resolve such infections.<sup>7</sup> Unfortunately, dentists commonly prescribe antibiotics for these conditions.<sup>8,9,4</sup> The prescription of antibiotics in dental clinical has increased from 6.7% to 11.3% in recent years.<sup>10</sup> Antibiotics prescription may lead to undesired effects ranging from systemic (gastrointestinal disturbances, selection of antibiotic

**Figure 1.** Clinical images showing the extraoral location of the antibioma.



**A.** Preoperative as patient presented. **B.** Postoperative view following removal of tooth No.46 and associated antibioma.

resistance and fatal anaphylactic shock)<sup>4</sup> or local effects such as antibioma formation. The antibioma results from injudicious (prolonged or repeated) use of antibiotics to treat infections. For instance, using antibiotics without establishing proper abscess drainage leads to the formation of localized collection of sterile material surrounded by thick fibrous tissues. An established antibioma is characterized by a tough fibrous swelling accompanied by pain and intermittent fever and constitutional symptoms.<sup>11</sup> We are reporting a case of a facial antibioma formed due to prolonged use of antibiotics to treat a residual periapical infection following endodontic treatment. In addition, we discuss the association of using antibiotics for a prolonged time in this context.

### CASE REPORT.

A 26 year old female patient attended the SEGi Oral Health Centre with the chief complaint of a swelling in the right lower posterior region of the mandible present for two weeks. The patient was in general good health and reported no systemic illness. Intraoral examination revealed a swelling on the oral mucosa and a temporary restoration on the occlusal surface of a mandibular first molar (tooth 46). Extraoral examination revealed well-marked swelling (2x2cm) at the lower border of the mandible near the tooth 46 area (Figure 1).

The dental history revealed that tooth 46 was under for root canal treatment that had not been yet completed by the dentist. The patient reported a history of repeatedly

and prolonged use of antibiotics including amoxicillin and metronidazole. Etoricoxib was used in conjunction with the antibiotics as a analgesic. The preoperative intra-oral periapical radiographs showed periapical lesion of tooth 46. The patient abandoned root canal treatment following the development of the swelling.

Considering the patient history and clinical presentation, various treatment options, their possible outcomes and related complications were explained to the patient. The agreed treatment plan comprised the surgical removal of tooth 46 and associated antibioma under local anesthesia followed by restoration of the lost tooth (Figure 1). This case study was approved by the institutional ethical research board at SEGi University, Malaysia. Signed informed consent was obtained for the patient both for the treatment and for using the her data for the purpose of a research publication.

### DISCUSSION.

This article reported a case of facial antibioma formed due to prolonged use of antibiotics. The patient was treated under local anesthesia by surgical removal of associated tooth and antibioma (a chronic abscess formed due to incomplete drainage of an infection and become sterile by antibiotics). Initially, in order to eradicate the infection, the patient was treated for root canal treatment. However, insufficient cleaning and shaping of the root canal lead to poor drainage and accumulation of biological material in the affected tooth.

The prolonged use of antibiotics to treat the residual

infection and lack of proper postoperative follow-up led to the formation of the anti-bioma. Clinically, it was characterized by being painless, smooth, non-tender, and hard on palpation of the swelling. This clearly illustrated the importance of mechanical instrumentation (cleaning and shaping) and chemical disinfection of canals during root canal treatment. In addition, the root canal morphology varies among individuals<sup>12,13</sup> and this must be considered in order to avoid missing any canals.

Inappropriate use of antibiotics involves unwanted systemic effects such as gastric, hematological, dermatological or neurological disorders. The most significant side effect is the appearance and selection of resistance to anti-microbial drugs. In order to ensure maximum efficacy and to minimize side effects (such as delaying the development of drug resistances), the rational and guidelines for using any antibiotic in dental clinics should be considered.<sup>14</sup> Although antibiotics have cured many diseases while benefiting a huge number of individuals, a sharp rise in the number of drug resistant strains of bacteria have occurred in parallel due mostly to their inappropriate use.

For instance, the overuse of antibiotics has resulted in the selection of bacterial mutations that make those microorganisms no longer susceptible to these drugs. There are strains of *Staphylococcus aureus* resistant to a variety of antibiotics including vancomycin. The rate at which bacteria become resistant to drugs is quite alarming and has led to an increase in the morbidity and mortality of infectious diseases.<sup>15</sup>

No uniform guidelines are available for indicating which antibiotics to use in such conditions in spite of high incidence of anti-bioma formation. It is reported by Bascones *et al.*,<sup>16</sup> that as an adjunct to root canal therapy, the clinician should also encompass usage of antibiotics in cases of acute odontogenic infection of pulp origin. The authors are not convinced that using antibiotics in cases of chronic odontogenic conditions including chronic gingivitis, periodontitis or periodontal abscesses is warranted. In case of acute odontogenic infections of mixed nature, the drugs of choice are beta-lactam derivatives provided there are no allergies or intolerances. Nevertheless, the ambiguity about the specificity of a particular drug from the beta-lactam family still prevails.

Natural and semi synthetic penicillin (amoxicillin) is considered to be the first drug of choice by some clinicians<sup>17</sup> while others favor the usage of combination drugs (for example amoxicillin-clavulanate), because of the increasing number of bacterial strains resistant to beta lactams, as well as due to the pharmacological advantages of using a broad spectrum drug and its tolerance.<sup>18</sup> Alternatively, clindamycin has also been proposed as an alternative based on its properties such as quick absorption, lower rates of bacterial resistance, and higher concentrations delivered to the tissues.<sup>19</sup> In a dental setting the prescription of antibiotics is mostly associated with a concurrent nonsteroidal anti-inflammatory drugs (NSAIDs) prescription. Antibiotics may have a range of possible interactions with other drug categories; for example, NSAID-mediated reduction of antibiotic bioavailability and its effects is well documented.<sup>20,21</sup> Although certain drug interactions (*e.g.* cephalosporins and ibuprofen, or tetracycline with naproxen or diclofenac) result in agonistic effects thus leading to enhanced bioavailability.<sup>22,23</sup> Hence, the decision whether the antibiotic should be prescribed or not for odontogenic reasons may not be straight forward and involves various parameters.

Dr. Thomas J. Pallasch adopted guidelines for antibiotic dosing,<sup>24</sup> which consider the drug's serum concentration, bioavailability, duration of treatment (favoring shorter treatment periods), as well as dosing amounts and intervals considering the drug's half-lives. In case of antibiotics for the treatment of orofacial infections, such as amoxicillin, the drug's half-life is short. Thus for orofacial infections, the recommended loading dose is double that of the maintenance dose. It is vital to consider the post antibiotic consequences of the drug and associated benefits of intermittent versus continuous dosing. For example for beta-lactam bactericidal activity, microorganisms need to be undergoing cellular division (as this drug mode of action is to interfere with cell wall development); hence, steady-state blood levels must be maintained as most of the bacteria divide at a variable times and pace. Therefore, beta-lactam antibiotics are considered to exhibit a slow and time-dependent bactericidal activity. Recently, Harneet *et al.*, reported the effective management of anti-bioma using intralesional injections of triamcinolone acetonide

and amoxiclav.<sup>25</sup> Antibiotics should be considered as an adjunct to appropriate management of odontogenic infections. For example in case of the poor drainage of pus or the sealing of residual microorganisms, the patient may not obtain significant benefits from antibiotic treatment, leading to further complications such as anti-bioma formation. Public awareness programmes and educating health professional can be promising in controlling the unnecessary use of antibiotics hence avoiding relevant unwanted effects.<sup>26</sup>

## REFERENCES.

1. Dar-Odeh N, Ryalat S, Shayyab M, Abu-Hammad O. Analysis of clinical records of dental patients attending Jordan University Hospital: Documentation of drug prescriptions and local anesthetic injections. *Ther Clin Risk Manag.* 2008;4(5):1111-7.
2. Bahl R, Sandhu S, Singh K, Sahai N, Gupta M. Odontogenic infections: Microbiology and management. *Contemp Clin Dent.* 2014;5(3):307-11.
3. Poveda Roda R, Bagan JV, Sanchis Bielsa JM, Carbonell Pastor E. Antibiotic use in dental practice. A review. *Med Oral Patol Oral Cir Bucal.* 2007;12(3):E186-92.
4. Dar-Odeh NS, Abu-Hammad OA, Al-Omiri MK, Khraisat AS, Shehabi AA. Antibiotic prescribing practices by dentists: a review. *Ther Clin Risk Manag.* 2010;6:301-6.
5. Muzaffar D, Mahdey HM, Sonjaya D, Zafar MS. Tendency of self-medication among various Malaysian ethnicities. *Br J Pharmacol.* 2016;9(2):1-7.
6. Afolabi AO, Akinmoladun VI, Adebosede IJ, Elekwachi G. Self-medication profile of dental patients in Ondo State, Nigeria. *Niger J Med.* 2010;19(1):96-103.
7. Longman LP, Preston AJ, Martin MV, Wilson NH. Endodontics in the adult patient: the role of antibiotics. *J Dent.* 2000;28(8):539-48.
8. Palmer NO, Martin MV, Peeling R, Ireland RS. An analysis of antibiotic prescriptions from general dental practitioners in England. *J Antimicrob Chemother.* 2000;46(6):1033-5.
9. Demirbas F, Gjermo PE, Preus HR. Antibiotic prescribing practices among Norwegian dentists. *Acta Odontol Scand.* 2006;64(6):355-9.
10. Marra F, George D, Chong M, Sutherland S, Patrick DM. Antibiotic prescribing by dentists has increased: Why? *J Am Dent Assoc.* 2016;147(5):320-7.
11. Narang S, Khurana MS. Use of antibiotics in Pediatric Dentistry: Not a child's play. *Int J Periodontol Implantol.* 2017;2(4):109-11.
12. Alrahabi M, Sohail Zafar M. Evaluation of root canal morphology of maxillary molars using cone beam computed tomography. *Pak J Med Sci.* 2015;31(2):426-30.
13. Zafar MS, Alrahabi M. Cone Beam Computed Tomography for Exploring Morphology of Mandibular First Molar. *Br J Med Med Res.* 2015;6(5):514-21.
14. American Dental Association Council on Scientific Affairs. Combating antibiotic resistance. *J Am Dent Assoc.* 2004;135(4):484-7.
15. Kuriyama T, Nakagawa K, Karasawa T, Saiki Y, Yamamoto

## CONCLUSION.

The negligence regarding judicious antibiotic usage during the management of odontogenic infections may result in serious consequences. Therefore, the merits and disadvantages of prescribing antibiotics should be seriously considered. Further training and continuing education programs are required to educate health professionals as well as the general public about the proper usage of antibiotics and the associated side effects. Such measures are likely to reduce the unnecessary use of antibiotics.

- E, Nakamura S. Past administration of beta-lactam antibiotics and increase in the emergence of beta-lactamase-producing bacteria in patients with orofacial odontogenic infections. *Oral Surg Oral Med Oral Pathol Oral Radiol Endod.* 2000;89(2):186-92.
16. Bascones-Martínez A, Aguirre-Urizar JM, Bermejo-Fenoll A, Blanco-Carrión A, Gay-Escoda C, González-Moles MA, Gutiérrez-Pérez JL, Jiménez-Soriano Y, Liébana-Ureña J, López-Marcos JF, Maestre-Vera JR, Perea-Pérez EJ, Prieto-Prieto J, Vicente-Rodríguez JC. Documento de consenso sobre el tratamiento antimicrobiano de las infecciones bacterianas odontogénicas. *Av Odontostomatol.* 2005;6(1):311-9.
17. Gay Escoda C, Berini Aytés L. *Tratado de Cirugía Bucal.* 1st Ed. Madrid: Ergón; 2004.
18. Maestre Vera JR. Opciones terapéuticas en la infección de origen odontogénico. *Med Oral Patol Oral Cir Bucal.* 2004;9 Suppl:S19-31.
19. Kirkwood KL. Update on antibiotics used to treat orofacial infections. *Alpha Omegan.* 2003;96(4):28-34.
20. Groppo FC, Simões RP, Ramacciato JC, Rehder V, de Andrade ED, Mattos-Filho TR. Effect of sodium diclofenac on serum and tissue concentration of amoxicillin and on staphylococcal infection. *Biol Pharm Bull.* 2004;27(1):52-5.
21. de Cássia Bergamaschi C, Motta RH, Franco GC, Cogo K, Montan MF, Ambrosano GM, Rosalen PL, Del Fiol Fde S, Groppo FC. Effect of sodium diclofenac on the bioavailability of amoxicillin. *Int J Antimicrob Agents.* 2006;27(5):417-22.
22. Tsviou E, Melakopoulos I, Kotsiou A, Anagnostopoulou S, Tesseromatis C. Alterations in cephalosporin levels in the serum and mandible of hyperlipaemic rats after co-administration of ibuprofen. *Eur J Drug Metab Pharmacokinet.* 2005;30(3):171-4.
23. Oh Y, Han HK. Pharmacokinetic interaction of tetracycline with non-steroidal anti-inflammatory drugs via organic anion transporters in rats. *Pharmacol Res.* 2006;53(1):75-9.
24. Pallasch TJ, In: Ingle JI, Bakland LK, eds. *Pharmacology of Anxiety, Pain and Infection. Endodontics.* 4th Ed. Malvern, PA: Williams and Wilkins; 1994.
25. Harneet S, Ambika G, Aarti S, Samidha K. Non surgical treatment of anti-bioma in oro-facial region. *Int J Curr Res.* 2017;9(8):56666-7.
26. Patil N, Kaul D, Tambuwala A, Pingal C, Sheikh MS, Pendharkar S. Large anti-bioma resulting from injudicious use of antibiotics: A case report. *Int J Dent Med Res.* 2015;1(5):89-92.