

Temporary restorative treatment in children and adolescents with amelogenesis imperfecta: Scoping review.

Cristhian Cisneros,¹ Maritza Gómez,¹ Mayra Vaca,¹
 Lucas Guimarães Abreu,² Patricia Méndez¹ & Liliana Otero.³

Affiliations: ¹Division of Pediatric Dentistry, Faculty of Dentistry, Pontificia Universidad Javeriana, Bogotá, Colombia. ² Division of Pediatric Dentistry, Faculty of Dentistry, Universidade Federal de Minas Gerais, Belo Horizonte, Brazil. ³Center of Dental Research, Faculty of Dentistry, Pontificia Universidad Javeriana, Bogotá, Colombia.

Corresponding author: Liliana Otero Mendoza. Pontificia Universidad Javeriana Carrera 7 No. 40-62, Bogotá, Colombia. Phone: (571) 3208320. E-mail: lotero@javeriana.edu.co

Receipt: 10/13/2017 **Revised:** 11/07/2017
Acceptance: 12/18/2017 **Online:** 12/18/2017

Conflict of interests: The authors declare no conflict of interest.

Ethics approval: Not required.

Funding: None.

Authors' contributions: Authorship included participation in study conception, drafting and final approval of the manuscript. All authors contributed equally.

Acknowledgements: None.

Cite as: Cisneros C, Gómez M, Vaca M, Abreu LG, Méndez P & Otero L. Temporary restorative treatment in children and adolescents with amelogenesis imperfecta: Scoping review. *J Oral Res* 2017; 6(12):324-330. doi:10.17126/joralres.2017.091

Abstract: Background: Amelogenesis imperfecta (AI) is a group of disorders that affect the enamel of the teeth, either in quality or quantity. This alteration causes sensitivity and is associated with factors that could affect the strength of the adhesive bond of the restorative material. Aim: To review the literature regarding the most used temporary restorative treatment in children and adolescents with AI. Methods: This scoping review aimed to include case reports, literature reviews and original studies that evaluated restorative materials for the teeth of children and adolescents with AI. Editorials, meeting abstracts and letters to the editor were excluded. The following electronic databases were used: Medline (Ovid), PubMed, Ebsco, Scopus (Elsevier) and Web of Science (Thomson Reuters). Manual searches in the reference lists of the included articles were also carried out. Finally, a search in Google Scholar restricted to the first 100 hits was performed. Duplicates were eliminated upon identification. The search covered a period between the years of 2011 and 2016. PRISMA guidelines were used for reporting the review. The evidence ranking was carried out by means of the Oxford criteria. Results: Six articles met the eligibility criteria and were included in this scoping review. Three articles were case reports, one was a review and two were original studies. For the treatment of AI, direct or indirect composite resins were the most commonly used material of choice in the retrieved studies because they demonstrate greater longevity, aesthetics and function compared to the other materials used. Conclusions: Among children and adolescents with AI, the temporary restorative treatment that demonstrated better long-term results in permanent teeth was the direct and indirect composite resins. However, high quality studies should be conducted to confirm the results presented herein.

Keywords: Amelogenesis imperfecta; treatment; children.

INTRODUCTION.

Amelogenesis imperfecta (AI) is a group of clinically and genetically heterogeneous hereditary disorders that affect the enamel of the teeth, either in quality or quantity.^{1,2} The clinical manifestation of AI is characterized by the poor development or absence of tooth enamel caused by the inadequate differentiation of ameloblasts affecting apposition, mineralization and maturation of the enamel in both primary and permanent dentition.³⁻⁵ The reduction in mineral content causes sensitivity and is associated with a higher protein content of the enamel, which could affect the strength of the adhesive bond of restorative materials.⁶⁻⁸

The etiology of AI is genetic and presents different types of inheritance patterns: autosomal dominant, autosomal recessive, X-linked and sporadic, each corresponding to variations in different genomic sites.^{1,5,6} Although the most common form of AI is non-syndromic or isolated, it may also be associated with other alterations such as dental anomalies, including: impacted teeth, agenesis, taurodontism, alterations in eruption, anterior open bite and pulpal calcifications.^{9,10}

The prevalence of AI is from 1/700 to 17/10,000. This difference is due to the different diagnostic parameters used across studies taken place in several geographical areas.^{2,3} Studies have shown values ranging from 43/10,000 in Turkey, 14/10,000 in Sweden, 10/10,000 in Argentina and 1.25/10,000 in Israel. These values indicate that the overall mean prevalence is 1/200.⁸

There are at least 15 AI subtypes, depending on the form and mode of inheritance.³⁻⁵ According to Witkop (1989), AI can be classified into four main types: hypoplastic AI, hypomaturation, hypocalcification, hypoplastic hypomaturation with taurodontism.¹¹ Regardless of the subtype, clinical findings reveal similar oral complications, including abnormal color and enamel texture, dental caries, dental hypersensitivity, reduction of the vertical dimension, and alterations in aesthetics.²

The challenges faced by dentists in managing a patient with AI are numerous. In pediatric dentistry, this is further intensified due to a child's lack of dental healthcare experience, self-perception, dental anxiety and parental expectations, which further complicates their treatment. Therefore, treatment in children is intended to alleviate symptoms, maintain vertical dimension, functionality and aesthetics.¹ Planning for such treatment depends on many factors, including the type and severity of the disorder, extent of destruction, age and socioeconomic status of the patient.^{2,12}

Dental treatment for individuals with AI varies from prevention to oral rehabilitation and orthognathic surgery. Regarding restorative treatment, the management of this group of patients is particularly important since a large body of restorative dental treatments are available, such as resin fillings, amalgam, ionomers and crowns. Treatment aims to control sensitivity and re-establish aesthetics and function. However, the clinician may face

challenges about the adhesion, retention and longevity of the restorations. The general dentist or pediatric dentistry team provide early and comprehensive treatment for AI patients, which will allow timely and effective care for affected individuals.^{4,5} However, in the literature, there are few reviews of the long-term follow-up of different modalities of restoratives treatment for children and adolescents with AI, including ceramic or ceramo-metallic crowns, glass ionomer cements, composite resins and overdentures.

A summary may be useful for professionals to acquire knowledge and to guide and direct future investigations in the treatment of AI.¹² The aim of this scoping review is to answer the following clinical question: Among children and adolescents with AI, what is the temporary restorative treatment with better long-term results in permanent teeth?

MATERIALS AND METHODS.

The reporting of this scoping review complies with the Preferred Reporting Items for Systematic Reviews (PRISMA) statement.¹³

Eligibility criteria

The inclusion criteria for this scoping review were as follows: case reports, literature reviews and original studies that evaluated the efficacy of restorative materials for teeth of children and adolescents with amelogenesis imperfecta. Editorials, meeting abstracts and letters to editor were excluded. No restriction to language of publication was imposed.

Information sources

A computerized search was conducted in the following electronic databases: Medline (Ovid), PubMed, Ebsco, Scopus (Elsevier) and Web of Science (Thomson Reuters) from 2001 to 2016. Manual searches in the reference lists of the included articles were also carried out. Finally, a search in Google Scholar restricted to the first 100 hits was performed. Duplicates were eliminated upon identification.

Search

The following search strategy was adapted for each database: *amelogenesis imperfecta AND child OR children OR adolescent OR infant OR toddler AND restorations OR restorative treatment OR dental material OR dental*

treatment OR glass ionomer OR glass-ionomer OR resin OR composite OR composer OR amalgam OR steel crown.

Study selection

The selection of the included articles for this critical review was carried out by two review authors. Initially, titles/abstracts were evaluated independently by both authors. The titles/abstracts that did not show any suitability for inclusion were excluded.

For the references that did not provide enough information for a decision based on abstracts, the full-texts were retrieved and read. Discrepancies between the two review authors were resolved by means of discussion.

Data extraction

Data extraction was also carried out by two review authors independently. Divergences were resolved by means

of discussion. If necessary, a third party was involved.

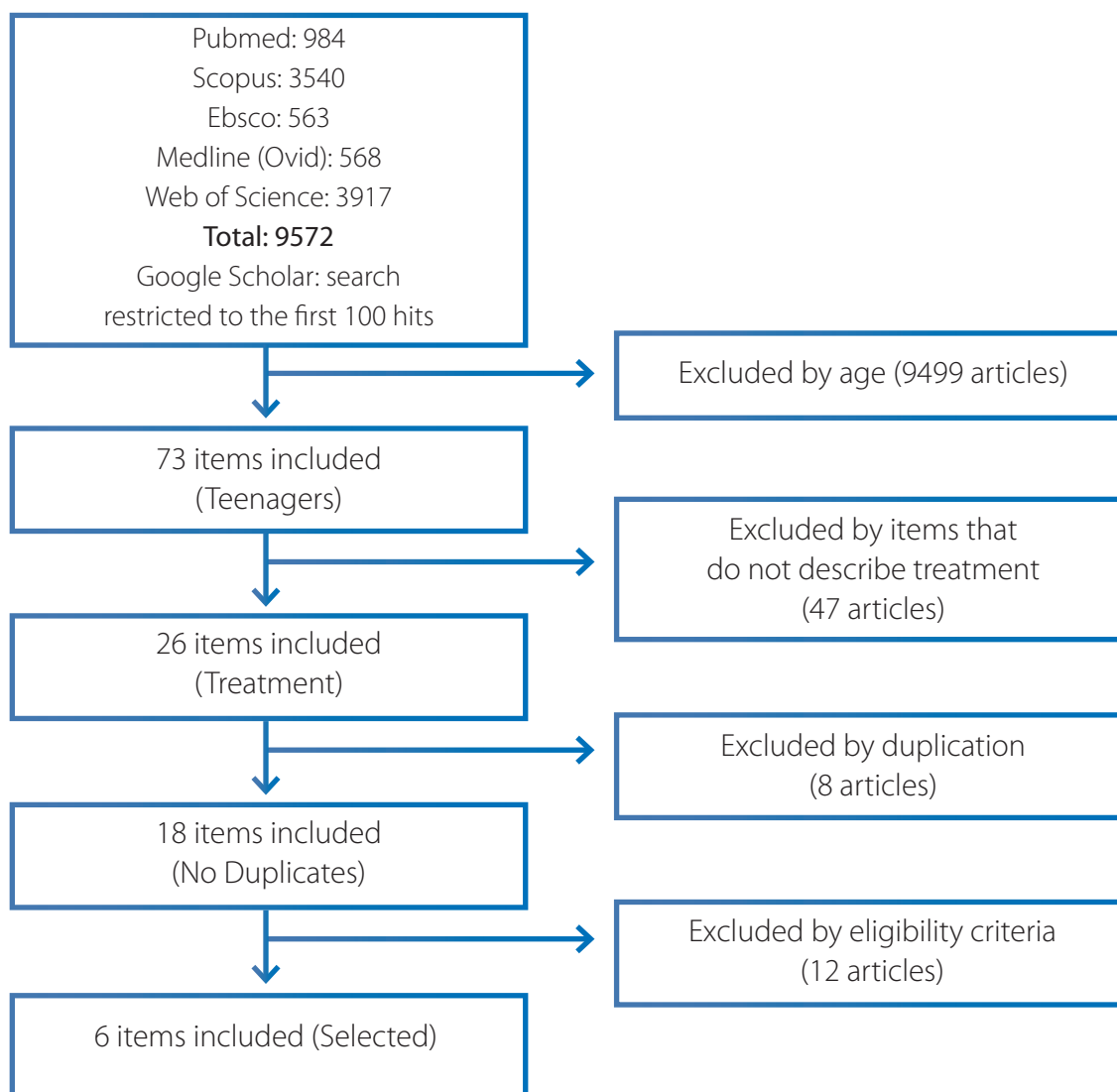
Data items

The following items were extracted: publication year, authors' name, article title, article objective, simple size, results and conclusions, type of study, evidence level and clinical recommendation.

Evidence ranking of the studies

The evidence ranking of the included studies was based on the criteria of the Oxford Centre for Evidence-Based Medicine (OCEBM). The OCEBM Levels of Evidence consists in a series of steps designed to identify the papers with the best evidence and less risk of bias and to generate grades of recommendation based on level of evidence.¹⁴ The evidence ranking was performed by two authors. Disagreements were resolved by consensus.

Figure 1. Flowchart of the study.



RESULTS.

Of the 9572 studies identified, six were selected according to the inclusion and exclusion criteria, which were case reports,^{6,7,15} an observational analytical,³ a retrospective cross-sectional study,⁶ and a Cochrane systematic review.⁷ Figure 1 displays the flow chart of the study.

According to the review of the selected articles, the restoration materials used were direct and indirect resin restorations, steel crowns in molars, glass ionomer restorations in permanent molars, porcelain crowns, celluloid plastic forms, resin-modified glass ionomer

resins, amalgam restorations, restorations with steel crowns with front aesthetic, and crown restorations with zirconium reinforcement.

Only one of the articles evaluated the longevity of the restoration until 18-20 years in terms of its aesthetics and function,⁷ that is, patients in whom there was no need for repeated treatment or other reinterventions. The longevity of the restorations is assessed according to the complications presented, such as: recurrent caries, failure of the restoration, pigmentation, pain and sensitivity. The characteristics of the included articles are shown in Table 1 and Table 2.

Table 1. Unit of analysis.

| Unit of analysis | Age of the population | Type of Restoration | Duration of treatment | Longevity of restorations |
|--------------------------------------------------------------------------------------------------------------------------------------------------------------------------------------------------------|-----------------------|------------------------------------------------------------------------------------------------------------------------------------------------------------------------------------------------------------------------|--------------------------------------------------------------------------------|---------------------------|
| Rehabilitation of teeth affected by amelogenesis imperfecta in mixed dentition period. <i>Saurabh Kumar, Runki Saran. (2016)</i> | 9 years | Crowns of stainless steel in the permanent and primary molars and celluloid crowns and resin veneers, direct and indirect on the anterior teeth. Use of stainless steel crowns on anterior teeth with aesthetic front. | During the growth period up to the end of the eruption of permanent dentition. | Not included |
| Restoration of function and esthetics in a patient with amelogenesis imperfecta. <i>Deepak Chauhan, Kapil Rajeev Sharma, Tripti Chauhan. (2017)</i> | 11 years | Composite restorations Glass Ionomers Resin-modified glass ionomers | Not included | Not included |
| Amelogenesis Imperfecta: A Conservative and Progressive Adhesive Treatment Concept. <i>S Ardu, O Duc, I Krejci, R Perroud. (2013)</i> | 14 years | Composite resin (direct technique) | 4 years | Up to 18 - 20 years |
| Assessment of Restorative Treatment of Patients With Amelogenesis Imperfecta. <i>Chiung-Fen Chen, Eduardo Bresdani, Jan Ching Chun Hu. (2013)</i> | 8 to 18 years | Crowns made of steel, Amalgam Direct restorations (composite resin restorations) indirect restorations (resin veneers or acrylic crowns) | Not included | Not included |
| Outcome of restorative treatment in young patients with amelogenesis imperfecta. A cross-sectional, retrospective study. <i>G. Pousette Lundgren, G. Dahllo. (2016)</i> | 6 to 25 years | Composite resin Porcelain crowns Glass ionomer | Not included | Not included |
| Interventions for the restorative care of amelogenesis imperfecta in children and adolescents. (Review systematic) <i>Mayssoon Dashash, C Albert Yeung, Issam Jamous, Anthony Blinkhorn. (2017)</i> | 6 to 25 years | Composite resin Porcelain veneers Resin-modified glass ionomer Steel crowns Crowns with zirconia reinforcement | 2-year follow-up | Not included |

Table 2. Structural summary of articles included in the study.

| Title Article Author, Year | Objectives | Sample Size | Results and Conclusions | Type of Study | Evidence Level (According to Oxford) | Clinical Recommen- dation |
|-----------------------------------------------------------------------------------------------------------------------------------------------------------------|------------------------------------------------------------------------------------------------------------------------------------------------------------------------------------------------------------------------------|----------------------------------------------------------------------------------------------------|---------------------------------------------------------------------------------------------------------------------------------------------------------------------------------------------------------------------------------------------------------------------------------------------------------------------------------------------------------------------------------------|-------------------------------------|--------------------------------------------|---------------------------------|
| Rehabilitation of Teeth Affected By Amelogenesis Imperfecta in Mixed Dentition Period. (Saurabh Kumar, Runki Saran., 2012) | Patient with mixed dentition, who underwent temporary treatment with the aim of improving dental aesthetics and preserving oral function. | A 9-year-old female patient with hypoplastic Amelogenesis imperfecta. | Provide a treatment that can rehabilitate, aesthetics, chewing function and reduce dental hyper-sensitivity and last until the patient approaches adulthood when a permanent treatment can be planned. | Case report | 4 | C |
| Restoration of function and esthetics in a patient with amelogenesis imperfect (Deepak Chauhan, Kapil Rajeev Sharma, Tripti Chauhan, 2013) | The treatment aims to decrease the sensitivity of the teeth and preserve both the structure of the tooth and prevent further loss of teeth, maintain the masticatory function, and finally improve the aesthetic appearance. | A 11-year-old male patient with diagnosis of hypoplastic amelogenesis imperfecta. | This case demonstrates a minimally invasive treatment. A simple option for correction of hypoplastic AI with resin restorations. | Case report | 4 | C |
| Amelogenesis Imperfecta: A Conservative and Progressive Adhesive Treatment Concept (S Ardu, O Duc, J Krejci, R Perout, 2013) | The objective of this work is to present a case report of a patient affected by amelogenesis imperfecta that shows a possible approach to adhesive and conservative treatment. | A 14-year-old male patient. | The application of a minimally invasive method in a young adolescent. Through a conservative adhesive treatment allows a two-stage intervention that accompanies the patient during his adolescence until the complete formation of hard and soft tissues. | Case report | 4 | C |
| Assessment of Restorative Treatment of Patients with Amelogenesis Imperfecta (Chiung-Fen Chen, Eduardo Bressiani, Jan Ching Chun Hu., 2013) | To evaluate the results of restorative treatment in the mixed dentition of patients with amelogenesis imperfecta (AI) and to determine the post-rehabilitation oral health status. | Population of 8 patients. (8-18 years) | Direct restorations, such as composite resin crowns, showed a high failure considered "provisional restorations". After the restorative treatment the sensitivity decreased and the aesthetics were acceptable. | Analytical observational | 2b | C |
| Interventions for the restorative care of amelogenesis imperfecta in children and adolescents. (Dashash M, Yeung CA, Jamous J, Blinkhorn A Dashash., 2013) | To compare the success rates of different restorative materials and techniques used for the restoration of anterior and posterior teeth with AI in terms of patient satisfaction (aesthetics and sensitivity) and function. | Children and adolescents with AI, 6 to 25 years of age, referred for oral rehabilitation | We did not find randomized controlled trials of restorative treatments for children and adolescents with AI, so there is no evidence of the best restoration. Well-defined randomized controlled trials involving children and adolescents should be performed and focus on the type and severity of the disorder to determine the best intervention for restoring AI-affected teeth. | Systematic review | 1a | A |
| Outcome of restorative treatment in young patients with amelogenesis imperfecta. A cross-sectional, retrospective study (G. Pausette Lundgren, G. Dahllo, 2014) | The aim of this paper is to compare oral health and longevity of dental restorations in a group of young patients with AI compared to a control group. | 82 patients (42 girls and 40 boys) aged 6- 25 years with AI: Hypomineralización and hypomaturación | The clinical significance of this study demonstrates the need for long-term restorative solutions for AI patients. It also shows the importance of establishing an early permanent therapy plan for these patients to avoid frequent dental visits | Retrospective cross-sectional study | 3b | B |

DISCUSSION.

In general, in all articles, the duration of treatment in patients with AI included the growth period until the permanent dentition had fully erupted. Of these, only three articles (an analytical observational, a cross-sectional retrospective and a systematic review) present a level of evidence 2b, 3b and 1a and a degree of recommendation B, C and A, respectively.

Oral outcomes may have psychological and social consequences for children and adolescents,¹⁸ and their parents^{19,20} and families.²¹ The literature has recognized that AI may have negative psychosocial effects on the affected individuals. Due to the unfavorable aesthetics, patients may present low self-esteem.²² The quality of life of these individuals is also negatively affected due to impairment of quality of life domains, such as oral symptoms, functional limitations, emotional and social discomfort. Therefore, to have a more comprehensive evaluation of their patient, the clinician should supplement the use of normative dental indices with subjective measures. Aware of the oral health condition of the patient and their psychosocial situation, the dentist may provide a more individualized restorative treatment for the individual.²³

According to the review of the selected articles, the most often used restorative materials were: restorations in direct and indirect resins in both anterior and posterior teeth presenting greater longevity, aesthetics and function compared to the other materials used for AI treatment. However, composite resin restorations on fewer than four surfaces and composite resin strip crowns show a high percentage of failure.³ Additionally, the longevity of composite resin and glass-ionomer restorations in AI patients are shorter than in controls, but prosthetic crown therapy has longer longevity than composite resin and glass-ionomer restorations in AI patients, and the outcomes are better for hypoplastic AI.¹⁶

Another frequent treatment option was steel crowns in primary and permanent molars and restorations with glass ionomer in permanent molars. Plastic forms, amalgam restorations, porcelain crowns and zirconium crowns were other types of restorations occasionally used.¹⁷ Difficulties in adhesion can hinder the union of the restorative material to the tooth;^{3,7} additionally, the

loss of occlusal dimension and skeletal open bite could increase the complexity of treatment.⁶ Thus, adhesive restorations appear to be the most suitable because they allow an adequate bonding to the enamel without the need for retentive preparations,²⁴ and adhesive treatment in two-stage interventions during the mixed dentition period until permanent dentition and growth of hard and soft tissues, could provide acceptable aesthetics and reduce pain caused by teeth sensitivity.⁷

The present critical review shows there are several treatment strategies for AI and the introduction of new restorative materials such as glass ionomer cements, resin modified glass ionomer cements, resin compounds modified with polyacids, resin compounds and indirect adhesives, or porcelain or zirconia inlays or crowns for AI patients, has been quantitatively and qualitatively evaluated in recent decades. However, clinical performance evaluation is still based on case reports and there is insufficient support to provide high quality evidence to establish guidelines for clinical practice. Nonetheless, one of the conclusions of the articles analyzed in this review is that all restorations cause inflammation and plaque accumulation in AI patients. However, the conclusions of this scoping review are similar to those of Dashash's systematic review,¹⁷ because the samples were not representative of the population of children with AI affiliated to a dental office and the included studies were mainly case reports and descriptive studies, prone to risk of bias, and as a consequence, the validity of the included studies is limited. Therefore, questions related to longevity of restorations and treatment complications in children with AI with mixed dentition remain unanswered.

Further studies are necessary to obtain larger sample sizes, and also to overcome the limited level of evidence and degrees of recommendation.¹⁷ In this regard, future research should consider the performance of high quality randomized controlled trials assessing the effect of different restorative materials by means of data analysis before and following the interventions. This prospective design allows the researcher to infer causal associations between interventions and outcomes providing the highest evidence regarding different therapies.²⁵ Further studies should be conducted among different age groups including different ethnic groups and types of AI to

evaluate aesthetics, longevity and function of materials employed for AI treatment. Since adhesion and aesthetics are difficulties involved in the dental treatment of any individual presenting enamel alterations, promising dental materials already tested in normal teeth should be evaluated in clinical trials involving AI patients.¹⁷

REFERENCES.

1. Arkutu N, Gadhia K, McDonald S, Malik K, Currie L. Amelogenesis imperfecta: the orthodontic perspective. *Br Dent J.* 2012;212(10):485–9.
2. Patil PG, Patil SP. Amelogenesis imperfecta with multiple impacted teeth and skeletal class III malocclusion: complete mouth rehabilitation of a young adult. *J Prosthet Dent.* 2014;111(1):11–5.
3. Chen CF, Hu JC, Estrella MR, Peters MC, Bresciani E. Assessment of restorative treatment of patients with amelogenesis imperfecta. *Pediatr Dent.* 2013;35(4):337–42.
4. Pousette Lundgren G, Dahllöf G. Outcome of restorative treatment in young patients with amelogenesis imperfecta. a cross-sectional, retrospective study. *J Dent.* 2014;42(11):1382–9.
5. Kumar S, Saran R. Rehabilitation of teeth affected by amelogenesis imperfecta in mixed dentition period. *Natl J Int Res Med.* 2011;3(2):169–72.
6. Chauhan D, Sharma KR, Chauhan T. Restoration of function and esthetics in a patient with amelogenesis imperfecta. *Int J Stud Res.* 2013;3(1):20–2.
7. Ardu S, Duc O, Krejci I, Perroud R. Amelogenesis imperfecta: a conservative and progressive adhesive treatment concept. *Oper Dent.* 2013;38(3):235–41.
8. Gadhia K, McDonald S, Arkutu N, Malik K. Amelogenesis imperfecta: an introduction. *Br Dent J.* 2012;212(8):377–9.
9. Martín-González J, Sánchez-Domínguez B, Tarilonte-Delgado ML, Castellanos-Cosano L, Llamas-Carreras JM, López-Frías FJ, Segura-Egea JJ. Anomalías y displasias dentarias de origen genético-hereditario. *Av Odontoestomatol.* 2012;28(6):287–301.
10. Bailleul-Forestier I, Molla M, Verloes A, Berdal A. The genetic basis of inherited anomalies of the teeth. Part 1: clinical and molecular aspects of non-syndromic dental disorders. *Eur J Med Genet.* 2008;51(4):273–91.
11. Witkop CJ Jr. Amelogenesis imperfecta, dentinogenesis imperfecta and dentin dysplasia revisited: problems in classification. *J Oral Pathol.* 1988;17(9-10):547–53.
12. Sudhapalli S, Sudhapalli SK, Bharathi S, Sharma N. Treatment Of Amelogenesis Imperfecta: A Literature Review. *Indian J Dent Sci.* 2014;6(5):113–5.
13. Liberati A, Altman DG, Tetzlaff J, Mulrow C, Gøtzsche PC, Ioannidis JP, Clarke M, Devereaux PJ, Kleijnen J, Moher D. The PRISMA statement for reporting systematic reviews and

CONCLUSION.

As reported in the literature analyzed for this critical review, the temporary restorative treatment in children and adolescents with amelogenesis imperfecta that demonstrated better long-term results in permanent teeth are direct and indirect composite resins.

- meta-analyses of studies that evaluate health care interventions: explanation and elaboration. *Ann Intern Med.* 2009;151(4):W65–95.
14. Every-Palmer S, Howick J. How evidence-based medicine is failing due to biased trials and selective publication. *J Eval Clin Pract.* 2014;20(6):908–14.
 15. Kumar S, Runki S. Rehabilitation of teeth affected by amelogenesis imperfecta in mixed dentition period. *Natl J Integr Res Med.* 2012;3(2):169–72.
 16. Pousette Lundgren G, Dahllöf G. Outcome of restorative treatment in young patients with amelogenesis imperfecta. a cross-sectional, retrospective study. *J Dent.* 2014;42(11):1382–9.
 17. Dashash M, Yeung CA, Jamous I, Blinkhorn A. Interventions for the restorative care of amelogenesis imperfecta in children and adolescents. *Cochrane Database Syst Rev.* 2013;6:CD007157.
 18. Abreu LG, Melgaço CA, Bastos Lages EM, Paiva SM. Impact of malocclusion on adolescents' oral health-related quality of life. *Gen Dent.* 2016;64(6):e1–e5.
 19. Abreu LG, Melgaço CA, Abreu MH, Lages EM, Paiva SM. Agreement between adolescents and parents/caregivers in rating the impact of malocclusion on adolescents' quality of life. *Angle Orthod.* 2015;85(5):806–11.
 20. Abreu LG, Melgaço CA, Abreu MH, Lages EM, Paiva SM. Perception of parents and caregivers regarding the impact of malocclusion on adolescents' quality of life: a cross-sectional study. *Dental Press J Orthod.* 2016;21(6):74–81.
 21. Abreu LG, Melgaço CA, Abreu MH, Lages EM, Paiva SM. Effect of malocclusion among adolescents on family quality of life. *Eur Arch Paediatr Dent.* 2015;16(4):357–63.
 22. Coffield KD, Phillips C, Brady M, Roberts MW, Strauss RP, Wright JT. The psychosocial impact of developmental dental defects in people with hereditary amelogenesis imperfecta. *J Am Dent Assoc.* 2005;136(5):620–30.
 23. Pousette Lundgren G, Karsten A, Dahllöf G. Oral health-related quality of life before and after crown therapy in young patients with amelogenesis imperfecta. *Health Qual Life Outcomes.* 2015;13:197.
 24. Elhennawy K, Schwendicke F. Managing molar-incisor hypomineralization: A systematic review. *J Dent.* 2016;55:16–24.
 25. Levin KA. Study design VII. Randomised controlled trials. *Evid Based Dent.* 2007;8(1):22–3.