

Available online at [www.sciencedirect.com](http://www.sciencedirect.com)

ScienceDirect

journal homepage: <http://www.elsevier.com/locate/pjnns>

## Case report

# Life-threatening parkinsonism-hyperpyrexia syndrome following bilateral deep brain stimulation of the subthalamic nucleus



Mehmet Osman Akçakaya<sup>a,\*</sup>, Nihan Hande Akçakaya<sup>b,c</sup>,  
Mustafa Ömür Kasımcı<sup>a</sup>, Talat Kırış<sup>a</sup>

<sup>a</sup>Department of Neurosurgery, Liv Hospital, Istanbul, Turkey

<sup>b</sup>Department of Genetics, Institute of Aziz Sancar Experimental Medicine (ASDETAE), Istanbul University, Istanbul, Turkey

<sup>c</sup>Turkey Spastic Children Foundation, Consultant Neurologist, Istanbul, Turkey

## ARTICLE INFO

## Article history:

Received 12 July 2017

Accepted 30 November 2017

Available online 6 December 2017

## Keywords:

Parkinson's disease

Deep brain stimulation

Subthalamic nucleus

Parkinsonism-hyperpyrexia

syndrome

Neuroleptic malignant syndrome

## ABSTRACT

Parkinsonism-hyperpyrexia syndrome (PHS), or neuroleptic malignant syndrome (NMS), is a neurophysiologic reaction to the acute withdrawal/decrease of central dopamine levels. It is a severe complication characterized by rigidity, change in consciousness level, fever, hypertension, and autonomic instability, that can be fatal. To the best of our knowledge, PHS following deep brain stimulation (DBS) of subthalamic nucleus (STN) surgery due to anti-Parkinson drug discontinuation has been previously reported only six times. Half of these cases resulted in fatalities. Herein, we report on an early diagnosed case of PHS following bilateral STN-DBS which was successfully treated with the administration of dopamine agonists, fluid replacement, and activation of DBS.

© 2017 Published by Elsevier Sp. z o.o. on behalf of Polish Neurological Society.

## 1. Introduction

Deep brain stimulation (DBS) of the subthalamic nucleus (STN) is an established option for the treatment of advanced Parkinson's disease (PD). Patients with tremor-affected quality of life, medically uncontrollable motor fluctuations, or dyskinesia are candidates for DBS [1]. These patients usually

have a long history of multiple, high-dose, anti-PD drug usage [2]. Prior to DBS surgery, the anti-PD drugs are temporarily discontinued to better observe patients' responses during surgery in most centers [2]. There is also a common tendency to reduce the use of anti-PD drugs postoperatively. The sudden withdrawal of anti-PD drugs may trigger a severe, fatal complication known as parkinsonism-hyperpyrexia syndrome (PHS), which is characterized by rigidity, change in consciousness level, fever, hypertension, and autonomic

\* Corresponding author at: Liv Hospital Ulus, Ahmet Adnan Saygun Ave. Canan Street, no: 5, Besiktas, Istanbul, Turkey.

E-mail address: [moakcakaya@gmail.com](mailto:moakcakaya@gmail.com) (M.O. Akçakaya).

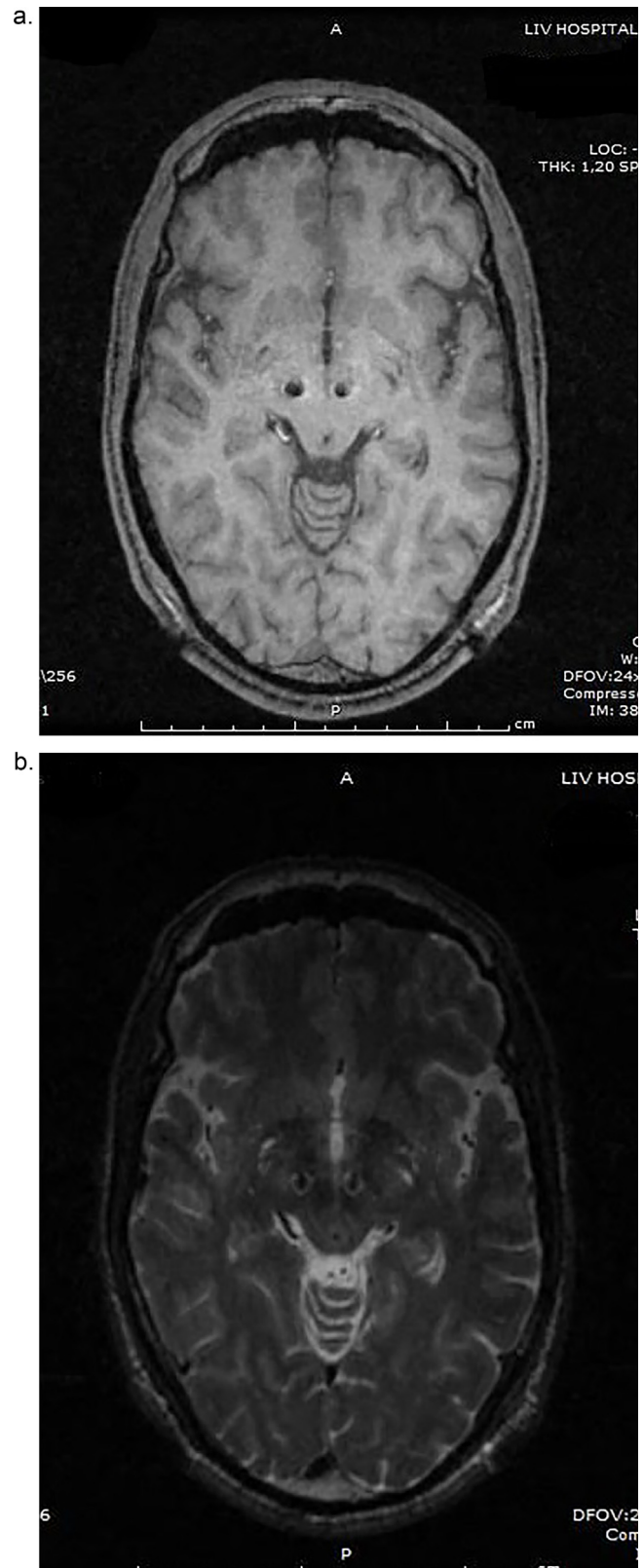
<https://doi.org/10.1016/j.pjnns.2017.11.012>

0028-3843/© 2017 Published by Elsevier Sp. z o.o. on behalf of Polish Neurological Society.

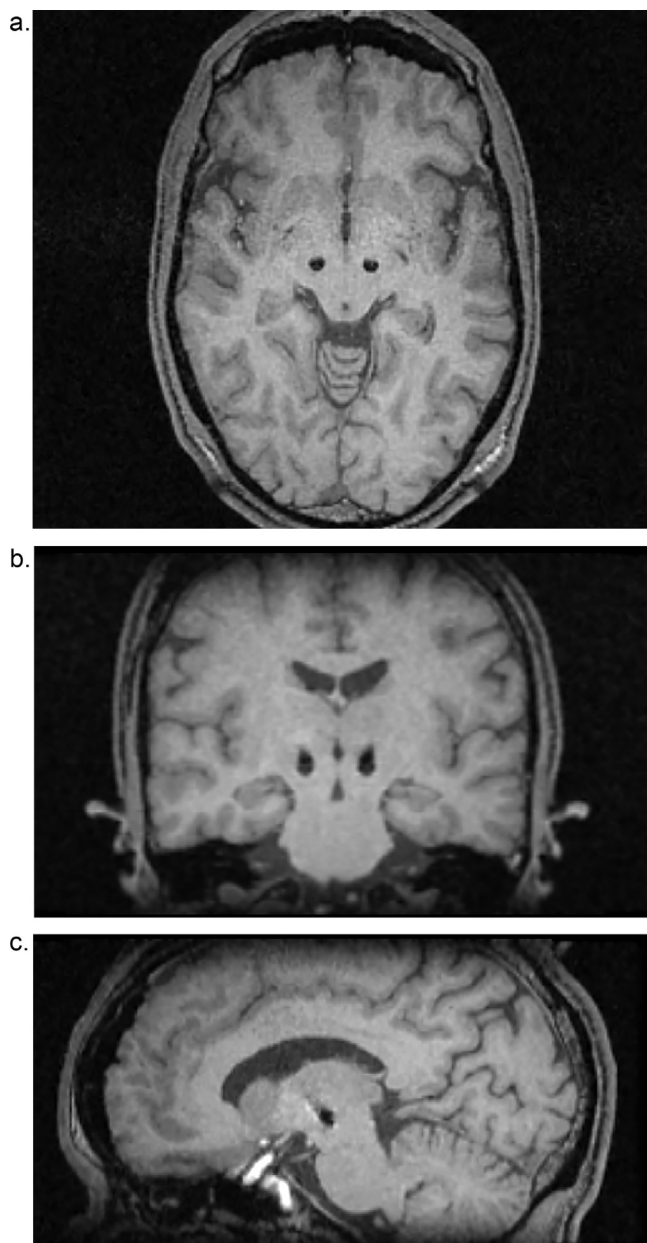
instabilities [2,3]. To the best of our knowledge, although anti-PD drug withdrawal is routinely used in clinical practice, to date, only six cases of PHS have been reported following STN-DBS surgery [2-7]. Fifty percent of these cases resulted in fatalities despite aggressive medical treatment efforts [3-5]. Herein, we report on a case of PHS which was recognized early on, following bilateral STN-DBS, and successfully treated with the administration of dopamine agonists, fluid replacement, and DBS activation.

## 2. Case report

A 61-year-old male with a 14-year history of PD was admitted for DBS surgery. His symptoms had progressed over the years with a predominant tremor. The Unified Parkinson Disease Rating Scale Part III (UPDRS-III) showed an improvement of 24% on the levodopa test. Although motor response to levodopa test is accepted as the primary selection criteria for DBS in Parkinson disease, in our patient who do not meet the 33% threshold, DBS was performed for medication-refractory tremor. The patient had been taking levodopa-benserazide, 600-150 mg/day, trihexyphenidyl 6 mg/day, and amantadine 300 mg/day preoperatively. 12 h before the operation, medications that the patient had been taking were withdrawn in order to observe the clinical response to the microelectrode stimulation. On the day of surgery, following magnetic resonance imaging (MRI) of the brain, a stereotactic frame (Integra CRW, New Jersey, USA) was placed onto patients head and patient underwent computed tomography (CT) scan. Then, the MRI and CT images were auto-fused using an image fusion program (Atlas Integra Software, New Jersey, USA) in order to target anterolateral side of right and left STN. Bilateral microelectrode recordings and macro stimulation tests were performed (Alfa Omega NeuroNav Micro Recording System, Nazareth, Israel). DBS electrodes were placed then bilaterally to anterolateral sides of both STNs (St. Jude Medical 6149 40 cm lead, Minnesota, USA). The cranial skin incisions were closed and the patient was brought to the radiology unit. A control cranial MRI revealed that the left sided STN electrode position found to be inappropriate (Fig. 1a and b). The left sided electrode was corrected under microelectrode recording and macro stimulation tests. Then permanent electrode positioning was confirmed with cranial MRI (Fig. 2a-c). The stereotactic frame was removed, the patient was intubated. Under general anesthesia, the impulse generator (St. Jude Medical Libra XP 6644, Minnesota, USA) was implanted and connected to the leads. The total length of this procedure was 12 h. Our protocol dictates that every patient who undergoes DBS surgery is routinely followed up overnight in the intensive care unit (ICU). Starting from the sixth postoperative hour in the ICU, the patient suffered from a high fever (up to 39 °C), confusion, generalized tremor, elevated blood pressure, and extreme axial rigidity. Autonomic dysfunctional attacks presented with tachycardia, blood pressure fluctuations, and diaphoresis. Deterioration of consciousness was also encountered. Intravenous (IV) hydration and empiric antibiotic treatment (vancomycin 4 × 500 mg and meronem 2 × 2000 mg) were administered immediately to counteract a possible central nervous system infection, although it is unusual in such an



**Fig. 1 – (a) and (b) Control MRI scan showed that the position of the depth electrode is appropriate on the right side, however too much medially located in the left side as shown by the axial T1 (a) and T2-weighted (b) images.**



**Fig. 2 – (a)–(c) Postoperative control T1-weighted MRI (a: axial, b: coronal, c: sagittal) confirmed the DBS final electrode positioning in STN.**

early postoperative period. A postoperative cranial CT scan showed no abnormalities except mild pneumocephalus and no evidence of late onset hemorrhage. Blood tests, including complete blood count, liver enzymes, and electrolytes, were all within normal limits. There was a mild increase in the C-reactive protein test which is in accordance with postoperative values (34.31). The creatinine kinase (CK) level was elevated to 1524 U/L. A PHS diagnosis was established, and the patient's preoperative medical treatment was restarted immediately. In addition, bromocriptine treatment of 7.5 mg/day ( $3 \times 2.5$  mg) was administered. On the second postoperative day, the clinical picture had not changed significantly. The CK level continued to increase up to 2170 U/L. Under normal circumstances, we prefer to activate the DBS system one-week after

surgery in order to observe reduction of the lesion effect of the DBS lead for more precise device programming. However, considering the mortality risk and the unchanged clinical picture in this case, the DBS system was activated (Bipolar stimulation, left and right STN Amplitude: 1.5 mA, pulse width: 60  $\mu$ S, frequency: 130 Hz) at the second postoperative day, and the bromocriptine dosage was increased to 15 mg/day ( $6 \times 2.5$  mg). With this treatment strategy, the CK values decreased from the third postoperative day. At fourth postoperative day stimulation parameters were increased to 2 mA in amplitude and to 70 in pulse width bilaterally. Tremor, rigidity, and confusion resolved gradually, and the number of autonomic dysfunctional attacks decreased. The CK level was down to 340 U/L on the sixth postoperative day, and the patient was discharged from the ICU. With four additional days of service care, stimulation parameters were rearranged (right and left STN Amplitude: 2.5 mA, pulse width: 70  $\mu$ S, frequency: 130 Hz) and the patient was discharged from the hospital on the 10th postoperative day. Considering the PHS, the patient's medication could not be decreased until three months following the surgery. There was an improvement of 35% in UPDRS-III scores on 6th month postoperatively; the disabling tremor, especially, was significantly improved.

### 3. Discussion

PHS or acute dopamine depletion syndrome is a neurophysiologic reaction to the acute withdrawal/decrease of central dopamine levels [8,9]. As well as being caused by the withdrawal of dopaminergic (anti-parkinsonian) drugs, PHS has also been reported due to the discontinuation of DBS. Diagnostic criteria were proposed by Granner and Wooten in 1991, which included "primary" (proper pharmacologic setting use of dopamine-receptor antagonists, or withdrawal of L-dopa or dopamine agonists, Parkinsonism, and fever in the absence of infection) and "secondary" (autonomic instability, altered mental state, and elevated creatinine kinase) manifestations [8].

Early recognition and diagnosis of PHS is essential in order to prevent morbidity and mortality. Clinical deterioration of Parkinsonism and increased body temperature are the primary signs of PHS. Readministration of the dopaminergic drugs that the patient used in the past is of utmost importance. According to the clinical picture, bromocriptine (7.5–15 mg/day), amantadine oral/IV, or IV methylprednisolone (1 g) should be added to the medical treatment [9]. Proper supportive treatment (hydration, reduction of fever, respiratory support, etc.) and detailed ICU follow-up are essential. To reduce rigidity, sodium dantrolene (2–3 mg/kg/day IV) may be used. The patient should be closely monitored for renal and hepatic functions and coagulation factors. The CK levels also need to be closely monitored. Possible complications of PHS may include rhabdomyolysis, acute renal failure, deep venous thrombosis, pulmonary embolism, disseminated intravascular coagulation, aspiration pneumonia, and seizures [9]. Differential diagnoses may include infectious diseases, alcohol, and other drug (benzodiazepines) withdrawal states [8].

Treatment options that affect central dopamine levels, such as electroconvulsive therapy (ECT), have been performed



on patients whose response to medical therapy remained insufficient [10]. It is thought that STN stimulation also contributes to our patient with a similar mechanism as ECT. Because it is known that STN stimulation causes negligible amounts of dopamine release in the striatum similar to the resting state in humans [11].

The drug withdrawal before DBS surgery was seen as the cause of PHS in most cases. However, in each of these cases published in the literature including the current report, there was also a drug withdrawal for levodopa test. Although we observed no significant changes or deterioration during levodopa tests, clinicians should kept in mind that they may observe some clinical signs, which may give a clue of a possible PHS risk.

In late onset cases of PHS unlike ours, drug reduction regimens may play a role. Unfortunately there are no certain guidelines or sufficient studies that addresses drug based management of PD patients following DBS. A recent review by Fasano et al., documented that although there are many studies focusing on the outcome of DBS, there is no study about the drug management in the postoperative period [12]. They underlined that to date, the best way to manage motor and non-motor symptoms in PD while balancing levodopa and a dopamine agonist remains largely unknown and this management was solely based on personal or institutional preferences and experience [12]. But in general, care must be taken by drug reduction to prevent immediate and significant reductions in levodopa and dopamine agonists.

To our knowledge, there have been only six other cases of PHS following DBS surgery published in the literature [2–7]. Three of these six cases resulted in fatalities, despite aggressive treatment [3–5]. DBS surgery of STN generally reduces PD symptoms; however, it may sometimes result in an increase of dyskinesia similar to that of a dopamine overdose state [3]. Dyskinesia, however, is usually seen as a favorable sign as it indicates improvement of motor symptoms in PD [3]. Urasaki et al. suggested that continuous STN stimulation may suppress PHS and possibly result in a delay in the diagnosis [3]. On the other hand, continuous STN stimulation has been pointed out as the cause of early recovery from PHS [2,7]. We believe that the close monitoring of our patient in ICU was very important in the early recognition of the disease. Once the diagnosis had been established, STN stimulation played a positive role by accelerating our patient's recovery. However, one must be aware that STN stimulation may mask the clinical features of PHS and leave the diagnosis uncertain.

We reinstated medical therapy, and, in addition, bromocriptine treatment was given. The patient was followed up according to the clinical course and CK level monitoring. We think that the complete and quick clinical recovery in our patient with PHS, which is known for its high mortality rate, is related to the early recognition of the disease, early establishment of appropriate medical and supportive therapy, and early activation of the DBS system.

### Author's contribution

In the course of development of this work, Akcakaya MO and Akcakaya NH equally gave an allround contribution towards

all endeavors pertaining to this work. Akcakaya MO approved the final version of the manuscript on behalf of all authors. Kasimcan MO carried out data collection work, data analysis and interpretation of data. Kırış T participated in study design, and drafting of the article. All the four authors reviewed the submitted version of the manuscript.

### Conflict of interest

None declared.

### Acknowledgement and financial support

None declared.

### REFERENCES

- [1] Reuter S, Deuschl G, Falk D, Mehdorn M, Witt K. Uncoupling of dopaminergic and subthalamic stimulation: life-threatening DBS withdrawal syndrome. *Mov Disord* 2015;30:1407–13.
- [2] Kim JH, Kwon TH, Koh SB, Park JY. Parkinsonism–hyperpyrexia syndrome after deep brain stimulation surgery: case report. *Neurosurgery* 2010;66:E1029.
- [3] Urasaki E, Fukudome T, Hirose M, Nakane S, Matsuo H, Yamakawa Y. Neuroleptic malignant syndrome (parkinsonism-hyperpyrexia syndrome) after deep brain stimulation of the subthalamic nucleus. *J Clin Neurosci* 2013;20:740–1.
- [4] Factor SA. Fatal parkinsonism–hyperpyrexia syndrome in a Parkinson's disease while actively treated with deep brain stimulation. *Mov Disord* 2007;22:147–8.
- [5] Govindappa ST, Abbas MM, Hosurkar G, Varma RG, Muthane UB. Parkinsonism hyperpyrexia syndrome following deep brain stimulation. *Parkinsonism Relat Disord* 2015;21:1284–5.
- [6] Linazasoro G, Van Blercom N, Castro A, Dapena MD. Subthalamic deep brain stimulation masking possible malignant syndrome in Parkinson's disease. *Neurology* 2004;63:589–90.
- [7] Themistocleous MS, Boviatsis EJ, Stavrinou LC, Stathis P, Sakas DE. Malignant neuroleptic syndrome following deep brain stimulation surgery: a case report. *J Med Case Rep* 2011;5:255.
- [8] Granner MA, Wooten GF. Neuroleptic malignant syndrome or Parkinsonism hyperpyrexia syndrome. *Semin Neurol* 1991;11:228–35.
- [9] Newman EJ, Grosset DG, Kennedy PG. The Parkinsonism-hyperpyrexia syndrome. *Neurocrit Care* 2009;10:136–40.
- [10] Meagher LJ, McKay D, Herkes GK, Needham M. Parkinsonism-hyperpyrexia syndrome: the role of electroconvulsive therapy. *J Clin Neurosci* 2006;13:857–9.
- [11] Thobois S, Fraix V, Savasta M, Costes N, Pollak P, Mertens P, et al. Chronic subthalamic nucleus stimulation and striatal D2 dopamine receptors in Parkinson's disease – a [(11)C]-raclopride PET study. *J Neurol* 2003;250:1219–23.
- [12] Fasano A, Appel-Cresswell S, Jog M, Zurowski M, Duff-Canning S, Cohn M, et al. Medical management of Parkinson's disease after initiation of deep brain stimulation. *Can J Neurol Sci* 2016;43:626–34.