

Available online at www.sciencedirect.com

ScienceDirect

journal homepage: <http://www.elsevier.com/locate/pjnns>

Letter to Editor

Optic neuritis in a patient with celiac disease



Keywords:

Celiac disease
Optic neuritis
Ophthalmoparesis
Brain MRI

Celiac disease is defined as permanent gluten intolerance. Proximal small intestine mucosa chronic inflammation which is healed by a gluten-free diet is one of the most significant characteristics of this disease; however, it can be reintroduced if gluten is returned to diet [1]. Presumably, neurologic presentations may be the prime manifestation of celiac disease. Cerebellar ataxia, epilepsy, peripheral neuropathy, autism, depression, and headache, especially in unknown cases, might be the neurologic presentations of celiac disease. The neuro-ophthalmic involvement as a manifestation of celiac disease is extremely rare [2]. This letter studies a patient with celiac disease presented with ophthalmoparesis.

The patient was a 43-year-old female who was referred to our center by an ophthalmologist because of right-sided optic neuritis. The other neurologist examinations were unremarkable. Brain magnetic resonance imaging (MRI) showed nonspecific white matter lesions (Fig. 1-A). Cervical and orbital MRI did not show any significant results. Vasculitis tests were normal and anti-aquaporin 4 antibody was negative too. Lumbar puncture was done for the patient. The cerebrospinal fluid (CSF) analysis was normal. The oligoclonal band (OCB) was negative. The optic neuritis was improved by intravenous (IV) methylprednisolone pulse therapy 1 g for 5 days. The drug and familial history of patient were unremarkable. The patient had a history of a right-side third nerve palsy 11 years ago which was recovered with 5 days IV methylprednisolone pulse therapy. The brain MRI of that time had revealed some nonspecific bright white matter lesions. Three years ago, she had complained of recurrent urticaria. Laboratory examination indicated recurrent elevated erythrocyte sedimentation rate (ESR). IgG Anti Endomesial antibody (EMA) test and Tissue Transglutaminase (TTG) antibody were elevated too. Upper

gastrointestinal endoscopy showed moderate corporal gastritis and moderate duodenitis. Duodenal mucosal biopsy demonstrated significant lymphocytic proliferation, crypt hyperplasia, and villi atrophy compatible with type III modified Marsh classification of celiac disease (Fig. 1-B and C). Gluten restriction regime was prescribed for her. As a result, the urticaria improved.

According to the patient's past medical history, the neurologic complication of celiac disease was considered. In addition, the MRI and OCB did not support the diagnosis of multiple sclerosis (MS) (Fig. 1-D). Therefore, no special drug was prescribed and it was decided to have close monitoring on her case.

The prevalence of celiac disease in general population is relatively high [1]. EMA and TTG antibody are useful as they are celiac disease's initial screen tests. Characteristic histologic changes were classified by Marsh and initially put forward by him, although they were modified later [1]. 22% of patients with celiac disease presented neurologic and psychiatric manifestations [3]. Seizure, ataxia, cerebellar degeneration, neuropathy, myopathy, depression, anxiety, schizophrenia, autism, migraine headache, multiple sclerosis, myasthenia gravis, attention deficit hyperactive disorders and nonspecific white matter lesions were reported in patients with celiac disease [2,3]. Neuro-ophthalmic involvement of celiac disease is extremely rare and restricted to pseudotumor cerebri, uveitis, orbital myositis, retinopathy, and cataract [4].

Anti-aquaporin 4 antibody positive optic neuritis, associated with celiac disease, was reported but the patient had a past history of recurrent episodic abdominal pain and psoriasis, and optic neuritis was not the first manifestation [5]. Anti-aquaporin 4 antibody in our patient was negative. Another probable diagnosis for our patient is MS. According to atypical brain imaging of the patient, lumbar puncture was done and OCB was reported to be negative. Thus, MS was not considered as a probable diagnosis in this patient.

To the best of the authors' knowledge, this case is the first celiac disease presenting neuro-ophthalmologic symptoms as a prim manifestation and optic neuritis in the course of disease.

The authors suggest that celiac disease is supposed to be considered in atypical neuro-ophthalmologic presenta-

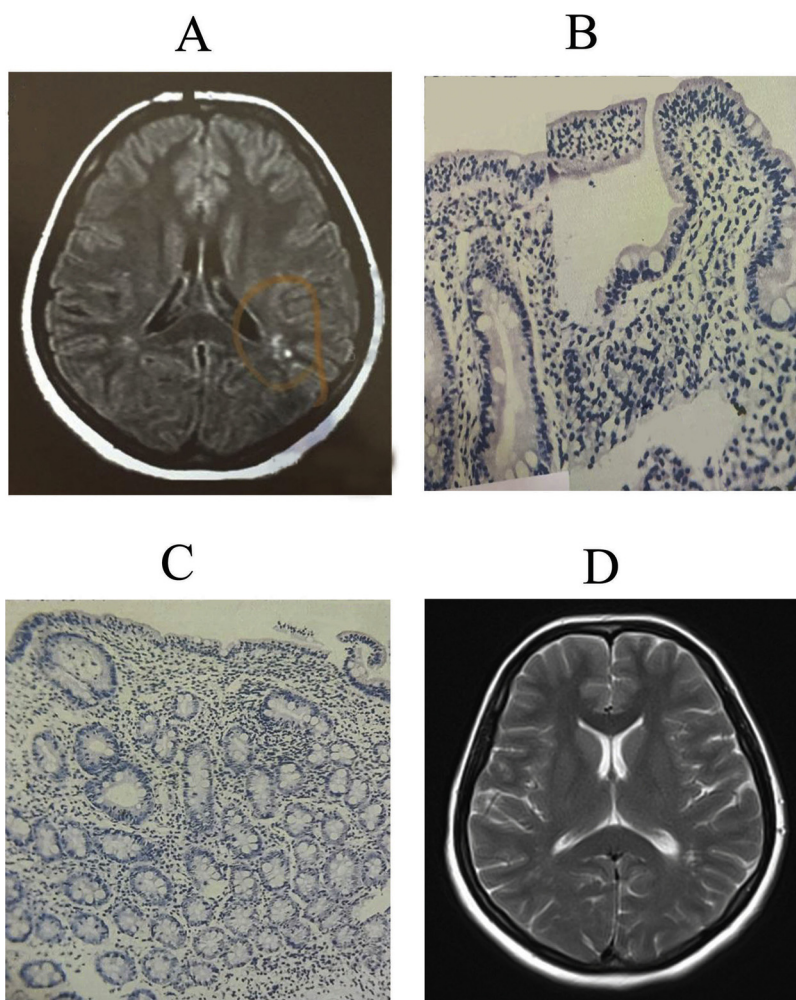


Fig. 1 – (A) Brain MRI showed nonspecific white matter lesions. (B and C) Duodenal mucosal biopsy demonstrated significant lymphocytic proliferation, crypt hyperplasia, and villi atroph. (D) The brain MRI which had been done 11 years ago had revealed some non specific bright white matter lesions.

tion or optic neuritis, especially when they co-exist with vague clinical and laboratory findings favored on a systemic autoimmune problem.

Compliance with ethical standards

For this type of study formal consent is not required.

Informed consent was obtained from all individual participants included in the study.

Conflict of interest

None declared.

Acknowledgement and financial support

The authors gratefully thank to the MS Research Center for their support.

REFERENCES

- [1] Guandalini S, Assiri A. Celiac disease: a review. *JAMA Pediatr* 2014;168(3):272–8.
- [2] Briani C, Zara G, Alaedini A, Grassivaro F, Ruggero S, Toffanin E, et al. Neurological complications of celiac disease and autoimmune mechanisms: a prospective study. *J Neuroimmunol* 2008;195:171–5.
- [3] Luostarinen L, Pirttila T, Collin P. Coeliac disease presenting with neurological disorders. *Eur Neurol* 1999;42:132–5.
- [4] Martins TG, Costa AL, Oyamada MK, Schor P, Sipahi AM. Ophthalmologic manifestations of celiac disease. *Int J Ophthalmol* 2016;9(1):159–62.
- [5] Meyts I, Jansen K, Renard M, Bossuyt X, Roelens F, Régal L, et al. Neuromyelitis optica-IgG+ optic neuritis associated with celiac disease and dysgammaglobulinemia: a role for tacrolimus? *Eur J Paediatr Neurol* 2011;15(3):265–7.

Seyed Mohammad Baghbanian
Neurology Department, Boalichina Hospiatal, Mazandaran
University of Medical Sciences, Sari, Iran

Abdorreza Naser Moghadasi*

MS Research Center, Neuroscience institute, Tehran University of
Medical Sciences, Tehran, Iran

*Corresponding author at: Sina MS research Center, Sina
Hospital, Tehran University of Medical Sciences, Hasan Abad
Sq., Tehran, Iran

E-mail address: abdorrezamoghadasi@gmail.com
(A. Naser Moghadasi)

Received 5 May 2017

Available online 1 August 2017

<http://dx.doi.org/10.1016/j.pjnns.2017.07.014>

0028-3843/

© 2017 Published by Elsevier Sp. z o.o. on behalf of Polish
Neurological Society.