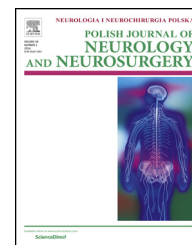

Available online at [www.sciencedirect.com](http://www.sciencedirect.com)

ScienceDirect

journal homepage: <http://www.elsevier.com/locate/pjnns>

## Case report

# Visual and somatosensory phenomena following cerebral venous infarction



Aleksandra Loster-Niewińska<sup>a</sup>, Edyta Dziadkowiak<sup>a</sup>,  
Justyna Chojdak-Łukasiewicz<sup>a,\*</sup>, Anna Zimny<sup>b</sup>, Bogusław Paradowski<sup>a</sup>

<sup>a</sup>Department of Neurology, Wrocław Medical University, st. Borowska 213, 50-556 Wrocław, Poland

<sup>b</sup>Department of General Radiology, Interventional Radiology and Neuroradiology, Wrocław Medical University, st. Borowska 213, 50-556 Wrocław, Poland

## ARTICLE INFO

## Article history:

Received 28 September 2016

Accepted 6 July 2017

Available online 14 July 2017

## Keywords:

Visual/somatosensory  
hallucinations

Visual/somatosensory illusions

Venous stroke

Irritation of cortical centers

## ABSTRACT

**Background:** The most frequent clinical presentation of occipital or visual tract lesion is hemianopsia or quadrantanopsia. However, damage to the primary or secondary visual cortex can also manifest as visual hallucinations (photopsiae or complex phenomena). We report visual and somatosensory phenomena following cerebral venous infarction based on a study of a patient with a history of recent head injury.

**Case presentation:** We report a 61-year-old man with a history of recent head injury presented with a headache of two weeks duration. He was complaining of transient visual abnormalities, which he described as impaired ability to recognize faces, dark spots moving in the visual field and distorted contours of an objects. Clinical examination showed a balance disorder with no evidence of visual deficit. During further observation the patient started to experience more complex visual and sensory phenomena of: waving of the ceiling, clouds that he could form and feel, he had an impression of incorrect sizes of given objects, he could see a nonexistent pack of cigarettes and the character from the arcade game Pac-Man “eating” an existing drip stand.

**Conclusions:** The patient mentioned above possessing simple and complex visual and somatosensory hallucinations and illusions in the course of venous stroke. A possible mechanism involves irritation of cortical centers responsible for visual processing.

© 2017 Polish Neurological Society. Published by Elsevier Sp. z o.o. All rights reserved.

## 1. Background

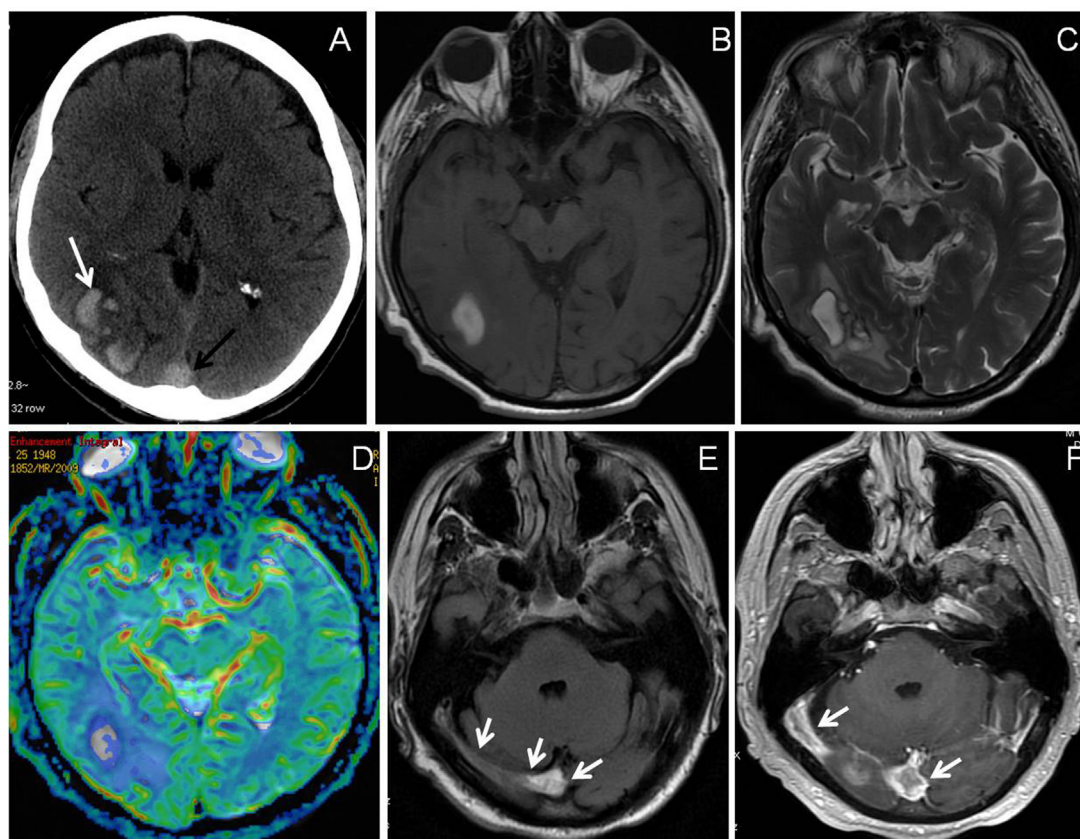
Hemianopsia or quadrantanopsia is the most frequent clinical presentation of occipital or visual tract lesion. However,

damage to the primary or secondary visual cortex can also manifest as visual hallucinations. It can present as elementary (photopsia) or complex phenomena. Photopsiae, consisting of bright lights (points, flashes, sparks) are more likely to appear with occipital pathologies, whereas complex hallucinations, defined as formed images of objects or persons, are combined

\* Corresponding author.

E-mail addresses: [olaloster@poczta.onet.pl](mailto:olaloster@poczta.onet.pl) (A. Loster-Niewińska), [ebkow@esculap.pl](mailto:ebkow@esculap.pl) (E. Dziadkowiak), [justyna.chojdak@wp.pl](mailto:justyna.chojdak@wp.pl) (J. Chojdak-Łukasiewicz), [abernac@wp.pl](mailto:abernac@wp.pl) (A. Zimny), [bogusparad@poczta.onet.pl](mailto:bogusparad@poczta.onet.pl) (B. Paradowski).  
<http://dx.doi.org/10.1016/j.pjnns.2017.07.007>

0028-3843/© 2017 Polish Neurological Society. Published by Elsevier Sp. z o.o. All rights reserved.



**Fig. 1** – CT image (A) showing hemorrhagic venous infarction within right occipital lobe (white arrow) and hyperdense superior sagittal sinus indicating CVT (black arrow). T1-weighted (B) and T2-weighted (C) MR images showing hyperintense right occipital hematoma surrounded by edema without hyperperfusion on perfusion map (D). FLAIR MR image (E) showing hyperintense right transverse sinus indicating CVT (arrows) and post contrast T1-weighted image (F) showing a filling defect in the confluence of the sinuses and in the right transverse sinus indicating thrombus (arrows).

with abnormalities of the occipitotemporal and occipitoparietal region.

## 2. Case presentation

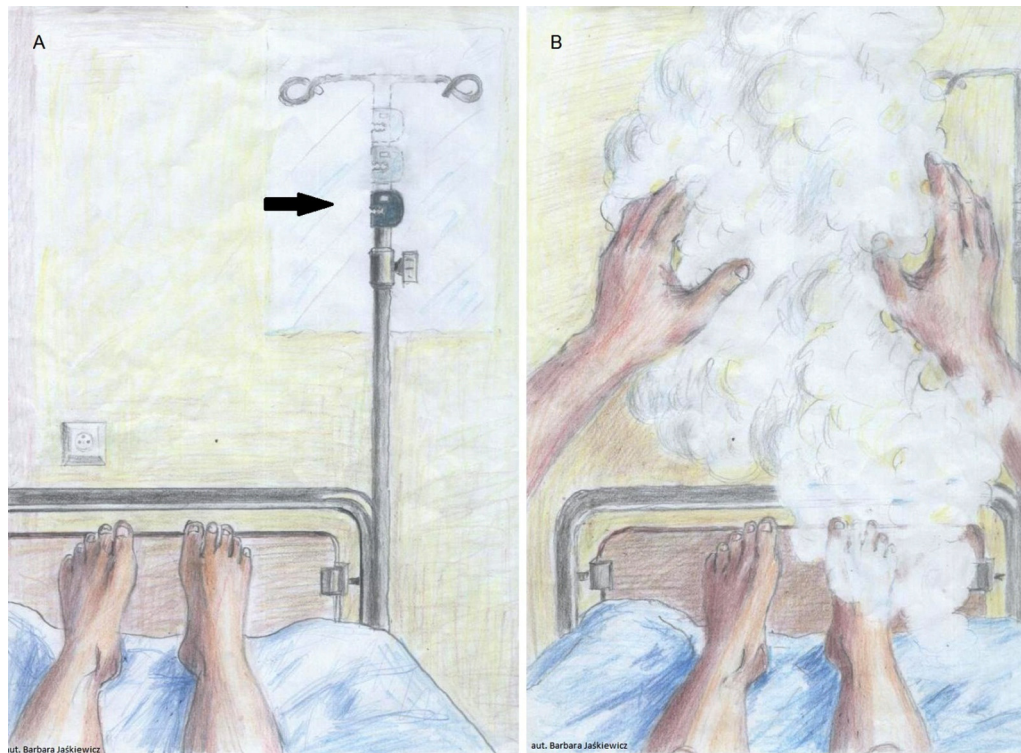
A 61-year-old man with a history of recent head injury presented with a headache of two weeks duration. He also reported occasional visual disturbances such as: impaired facial recognition, dark spots moving in the visual field and distorted contours of the observed objects. Clinical examination revealed a balance disorder with no evidence of visual deficit. Computed tomography (CT) and magnetic resonance imaging (MRI) demonstrated cerebral venous sinus thrombosis (CVT) complicated by right-sided occipital hemorrhagic infarction (Fig. 1). During further observation the patient started to experience more complex visual and sensory phenomena of: waving of the ceiling, clouds that he could form and feel, he had an impression of incorrect sizes of given objects, he could see a nonexistent pack of cigarettes and the character from the arcade game Pac-Man “eating” an existing drip stand (Fig. 2). Except for the head trauma, no other pathologies contributing to CVT were found. The patient was treated with a weight-adjusted dose of heparin. The visual phenomena lasted for about two weeks and then resolved completely.

## 3. Conclusion

The most frequent clinical presentation of an occipital or visual tract lesion is hemianopsia or quadrantanopsia. Damage to the primary or the secondary visual cortex can also manifest as visual hallucinations often localized to the affected part of the visual field [1,2]. It can present as elementary (photopsia) or complex phenomena. Photopsiae, consisting of bright lights (points, flashes, sparks), are more likely to appear with occipital pathologies, whereas complex hallucinations, defined as formed images of objects or persons, are related to abnormalities of the occipitotemporal and occipitoparietal regions [3]. The patient described above presented with coexisting simple and complex visual and somatosensory hallucinations and illusions in the course of venous stroke [4]. A possible mechanism involves irritation of cortical centers responsible for visual processing [1,3].

## Consent

Written informed consent was obtained from the patient for publication of this Case report and any accompanying images.



**Fig. 2 – Drawings of the patient's hallucinations. (A) Pac-Man (arrow) “eating” a drip stand. (B) Clouds-like structures that the patient could form and feel.**

A copy of the written consent is available for review by the Editor of this journal.

---

### Conflict of interest

None declared.

---

### Acknowledgement and financial support

None declared.

### REFERENCES

- [1] Beniczky S, Keri S, Voros E, et al. Complex hallucinations following occipital lobe damage. *Eur J Neurol* 2002;9:175–6.
- [2] Brzecki A, Podemski R, Kobel-Buys K, Buys G. Illusions and hallucinations in posterior cerebral artery thrombosis — a case study. *Udar Mózgu* 2001;3(2):71–6.
- [3] Menon GJ, Rahman I, Menon SJ, Dutton GN. Complex visual hallucinations in the visually impaired: the Charles Bonnet Syndrome. *Surv Ophthalmol* 2003;48(1):58–72.
- [4] Saposnik G, Barinagarrementeria F, Brown Jr RD, et al. Diagnosis and management of cerebral venous thrombosis: a statement for healthcare professionals from the American Heart Association/American Stroke Association. *Stroke* 2011;42(4):1158–92.