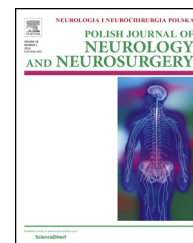

Available online at www.sciencedirect.com

ScienceDirect

journal homepage: <http://www.elsevier.com/locate/pjnns>

Case report

Airgun shot wound to the orbit with retention of pellet. Case report and review of the literature

Paweł Daszkiewicz^{a,*}, Dariusz Dziedzic^b, Piotr Daszkiewicz^b

^aDept. of Neurosurgery, the Children's Memorial Health Center, Warsaw, Poland

^bMedical Division, Medical University of Warsaw, Warsaw, Poland

ARTICLE INFO

Article history:

Received 11 April 2016

Accepted 27 May 2016

Available online 1 July 2016

Keywords:

Airgun pellet

Orbit

Shot wound

ABSTRACT

Shot wounds become a growing clinical concern in the civilian setting, due to increasing popularity of air guns among minors. We present a pediatric case of a shot wound to the orbit with sparing of the eyeball and retention of airgun pellet in the retrobulbar space. The pellet was removed 3 months after injury via lateral orbitotomy. Pathophysiology and ballistics of shot wounds are briefly reviewed and current views on the management strategy of shot wounds with retained projectile are discussed.

© 2016 Polish Neurological Society. Published by Elsevier Sp. z o.o. All rights reserved.

1. Case report

An 11 y.o. girl, with unremarkable previous medical history, was admitted to our facility on 18th October 2015 after suffering an accidental air gun shot. Admission findings included a small entry wound on the lower eyelid and edema of the conjunctiva of her left eye. Ophthalmological examination revealed a normal right eye, and on the left – slight elevation and blurred margins of optic disk, small subretinal echymoses, rupture of choroid and retina surrounded by multiple subretinal and intravitreal hematomas. Visual acuity was 1.0 on the right and 2/50 on the left. Emergency CT scan revealed a foreign body (air gun pellet of the “diabolo” type, Fig. 1) embedded in the inferior wall of the orbit lateral to the inferior orbital fissure, small intraorbital air bubbles, with ocular globe and optic nerve appearing grossly intact. Conservative and symptomatic treatment resulted in uneventful healing of the entry wound and improvement of

visual acuity in the left eye. The girl was discharged home in a good overall condition, with no general nor local signs of infection.

ENT and neurosurgical consultations were obtained in order to plan further treatment. Contemplated techniques for removal of the retained pellet included endoscopy via maxillary sinus and open orbitotomy (Figs. 2–4).

The girl was readmitted on 17th January 2016 for scheduled surgery. On admission she was in a good overall condition, neurologically intact, with no local nor systemic signs of infection. Local findings included healed scar in the inferior eyelid of the left eye, normal mobility of the globe, visual acuity of the left eye 0.5. The girl was operated on by lateral orbitotomy (Kroenlein). The pellet was located under fluoroscopic guidance. No signs of local infection were found. The pellet was removed without problem and the wound was closed in the standard fashion. Further postoperative course was uneventful and the wound healed with a satisfactory cosmetic result.

* Corresponding author at: Klinika Neurochirurgii IPCZD, Al. Dzieci Polskich 20, 04-730 Warszawa, Poland. Tel.: +48 600184518.
E-mail address: marta.daszkiewicz3@gmail.com (P. Daszkiewicz).

<http://dx.doi.org/10.1016/j.pjnns.2016.05.007>

0028-3843/© 2016 Polish Neurological Society. Published by Elsevier Sp. z o.o. All rights reserved.

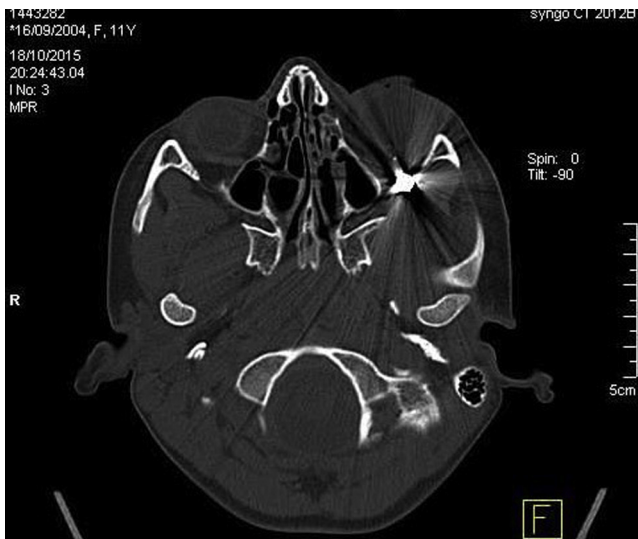

Fig. 1 – CT scan, transverse view. Intraorbital air gun pellet adjacent to the inferior orbital fissure (arrow).

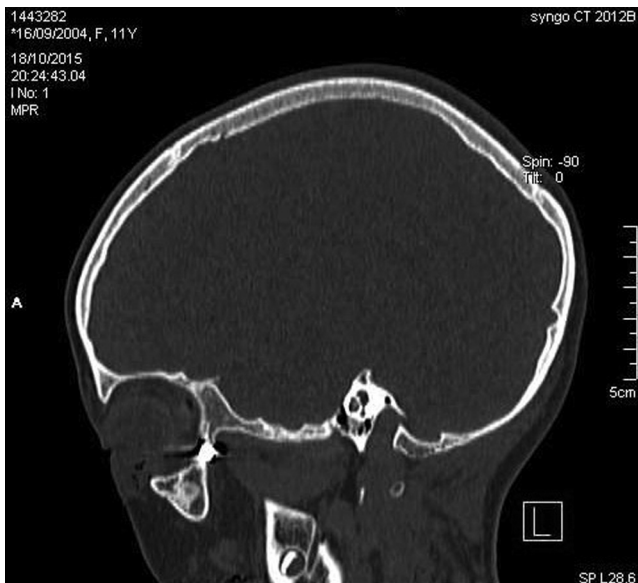

Fig. 2 – Same patient; CT scan, sagittal view.

2. Discussion

Increasing popularity of sport shooting and easy access to air guns will most probably contribute to growing incidence of accidental and purposeful air gun shot wounds in the near future. Regulatory limitations when buying an air gun delivering less than 17 kJ energy are very liberal. Only weapons delivering over 17 kJ require registration with the police, ophthalmologic examination and community interview [1]. At the place and time we currently live, shot wounds in the civilian setting are fortunately rare, but events accompanying preparation of this manuscript (March 2016, shortly after terrorist attacks in Belgium) might forecast a greater risk of shot wounds and other military-type injuries among civilians in the future. Medical personnel will be faced with this

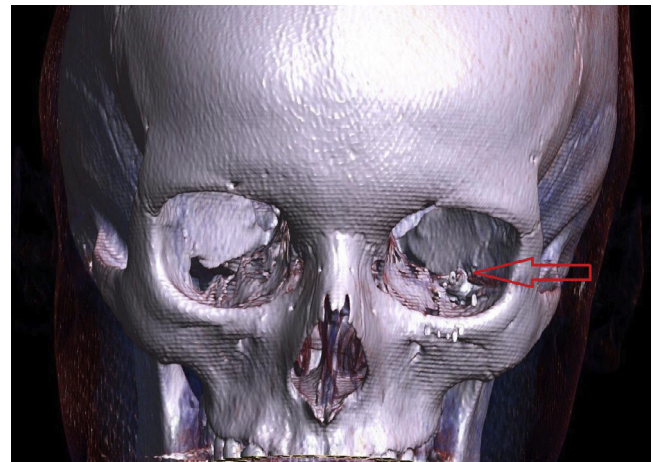


Fig. 3 – Same patient; CT scan, 3-D reconstruction. Intraorbital air gun pellet (arrow).




Fig. 4 – Recovered diablo-type air gun pellet.

problem and should be able to manage these persons in the best possible way [2,3].

Our case deserves attention for several reasons. These include general strategy of management of shot wounds with and without retained bullet, timing and technique of surgery and collaboration of several medical specialties in the case of borderline location of injury.

A lot has been written to date on ballistics and pathophysiology of shot wounds [4,5], so the most basic issues will be addressed briefly. Currently observed trends in the development of firearms result in a definite differentiation of military and hunting rifles. In the military setting, a shot is designed to wound the enemy rather than to kill, because wounded soldier (or civilian) will require assistance, consuming far more resources in terms of material and man-power that a dead one. Therefore, a modern military bullet has high kinetic energy and relatively small caliber, ensuring greater penetration and smaller extent of tissue damage. Furthermore, smaller cartridges are lighter, thus facilitating transport of supplies to fighting troops. In the hunting setting, a shot is designed to provide a “clean kill”, because prompt death of the

animal will hopefully spare it unnecessary suffering and will prevent it escaping from the scene of action with all possible consequences thereof. Hunting bullet carries slightly smaller kinetic energy but has larger caliber, providing inferior penetration but extensive tissue damage. Air guns are a kind of non-powder fire arms designed for sport shooting and hunting small game, so an air gun pellet is characterized by low kinetic energy, small penetration ability and small extent of tissue damage. Nevertheless, with nearly unlimited availability of air guns and its frequent use by minors, the risk of serious or even fatal injuries is considerable [5].

After being shot, the bullet meets and overcomes air resistance gradually losing its energy. Hitting the target, it transfers the remaining energy, thus providing the desired effect of injury. If the remaining kinetic energy drops to 0, the bullet becomes retained within the target, resulting in a blind wound (entry wound only). If its remaining energy is sufficiently high, it travels all the way through the target, creating tangential or through wounds and stops somewhere behind the target (entry and exit wounds). In the case of air gun shot and small kinetic energy of the projectile, we are frequently confronted with a blind wound and a retained pellet, which was also our case.

Shot wounds are a kind of penetrating injury. Extent of tissue damage depends on energy delivered and shape and trajectory of the projectile. In the case of low-velocity and low-energy instruments, e.g. stab or cut wounds, extent of injury is limited mostly to the diameter of the instrument or extent of cut. In the case of high-velocity and high-energy wounds, tissue damage by far exceeds bullet diameter due to cavitation and shock wave [5].

All penetrating injuries result in dragging of fragments of clothing, tissues (e.g. bones) and bacteria along trajectory of the wounding instrument, greatly increasing the risk of infection. The bullet may or may not penetrate tissues with high bacterial burden load (large bowel or paranasal sinuses), resulting in essentially contaminated or essentially clean wounds [6,7]. Risk of infection certainly increases with retained foreign body or necrotic debris. Some authors argue that high temperature generated by the shot and air resistance results in sterilization of the bullet, but clinical experience always favors removal of retained bullets, if only for medico-legal reasons [8].

In general, potentially infected and relatively easily accessible bullets should be removed, while potentially clean and hardly accessible ones may be treated conservatively, with close monitoring of the patient [9]. Over time, strategy of managing these patients has changed. In the past, with lack of antibiotics and poor access to qualified medical care, the aim was to debride effectively on the first (and often only) occasion, saving the patient's life at the price of greater mutilation. At present, with all the resources of modern medicine at our disposal, staged and more sparing debridement or even conservative treatment are justified [10,11]. This is particularly the case when a potentially sterile bullet is located in a high-risk or eloquent area, when risk of surgery outweighs its potential benefits. In our case, the wound was considered essentially clean (sparing of paranasal sinuses) and after a 3-months follow-up no signs of infection developed, thus justifying an expectant attitude and deferral of scheduled

surgery until resolution of local inflammation and stabilization of the patient's condition. Certainly, in life-threatening situations and high risk of infection, emergency surgery is mandatory. All other cases deserve scheduled approach after a good diagnostic work-up and in optimal conditions, both in terms of instruments and experienced personnel available.

Penetrating wounds of the orbit may be classified as those with or without injury to the globe and those with or without injury to adjacent paranasal sinuses. In our case, both eye globe and paranasal sinuses were spared. Furthermore, good baseline health status of the child further justified expectant approach adopted initially [12,13].

Some authors raise the issue of deleterious effect of lead and other elements contained in retained bullet and absorbed to the circulating blood (according to British Standard, a bullet contains 99.2–99.8% of lead, 0.1% of antimony, 0.005% of zinc, 0.07% of copper, 0.5% of tin and 0.075% of other elements) [14].

Posterior part of the orbit and its inferior wall adjacent to the maxillary sinus are to some extent a “no man's land”, at the borderline of interest of ophthalmologists, neurosurgeons, maxillary surgeons and ENT specialists [6,7]. In our case, the final decision to remove the bullet was based on closeness of the maxillary sinus and risk of infection on the long run. Contemplated access routes included endoscopic approach through the maxillary sinus and open orbitotomy. Finally, the latter option was chosen, providing superior exposure of retrobulbar part of the orbit with sparing of important structures, no risk of sinus-associated infection and a relatively favorable cosmetic effect. Endoscopic option would provide a disputable benefit of lack of surgical scar at the price of higher risk of infection and poor exposure.

3. Conclusions

Management of shot wounds to the orbit requires an individual approach, nevertheless based on general surgical principles. Both protection to the globe, prevention of infection and cosmetic considerations must be taken into account. In selected cases, conservative treatment is justified.

Conflict of interest

Paul Dashkevich, Dariusz Dziedzic, Piotr Dashkevich not report any conflict of interest in connection with uploaded to the publication of the work.

Acknowledgement and financial support

Authors Paweł Daszkiewicz, Dariusz Dziedzic, Piotr Daszkiewicz were financed from own funds of the Department of Neurosurgery CMHI.

Ethics

The work described in this article has been carried out in accordance with The Code of Ethics of the World Medical

Association (Declaration of Helsinki) for experiments involving humans; Uniform Requirements for manuscripts submitted to Biomedical journals.

REFERENCES

- [1] Ustawa z dnia 21.05.1999; Dz. Ustaw 1999 Nr 52, Poz. 549.
- [2] Ceylan H, McGowan A, Stringer M. Air weapon injuries: a serious and persistent problem. *Arch Dis Child* 2002;86:234–5.
- [3] Osemlak P, Osemlak J, Obel M. Postępowanie w postrzałach głowy u dzieci. *Roczniki Dziecięce. Chirurgii Urazowej* 2005;9(XXXIII):25–9.
- [4] Farjo LA, Miclau T. Ballistics and mechanisms of tissue wounding. *Injury* 1997;28(Suppl. 3):SC12–36.
- [5] Santucci RA, Chang YJ. Ballistics for physicians: myths about wound ballistics and gunshot injuries. *J Urol* 2004;171:1408–14.
- [6] Enger C, Schein OD, Tielsch JM. Risk factors for ocular injuries caused by air guns. *Arch Ophthalmol* 1996;114:469–74.
- [7] Arkuszewski P, Przygoński A, Kozakiewicz M. Urazy postrzałowe części twarzowej czaszki – obraz kliniczny i leczenie. *Czas Stomatol* 2004;LVII(8):537–42.
- [8] Kobek M, Chowaniec C, Rygoł K, Jabłoński C. Niezwykły przypadek postrzału z broni pneumatycznej. *Arch Med Sąd Kryminal* 2011;LXI:58–61.
- [9] Jacobs NA, Morgan LH. On the management of retained airgun pellets; a survey of 11 orbital cases. *Br J Ophthalmol* 1988;72:97–100.
- [10] Badran K, Sudhoff H, Gray R. An unusual air gun injury to the ethmoidal sinus. *Eur Arch Otorhinolaryngol* 2007;264:1253–6.
- [11] Lubianca Neto JF, Mauri M, Machado JR. Air dart injury in paranasal sinus left alone. *Int J Pediatr Otorhinolaryngol* 2000;52:173–6.
- [12] Reymond J, Podsiadło M, Kepa A, Wyskiel M. Ciała obce w oczodole – opis trzech przypadków. *Czas Stomatol* 2006;LIX(6):446–50.
- [13] Shuttleworth GN, Galloway PH. Ocular air-gun injury: 19 cases. *J R Soc Med* 2001;94:396–9.
- [14] Lyons JD, Filston HC. Lead intoxication from a pellet entrapped in the appendix of a child: treatment considerations. *J Pediatr Surg* 1994;29:1618–22.