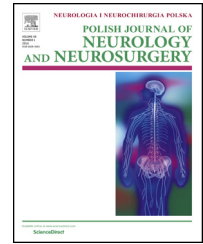


Available online at [www.sciencedirect.com](http://www.sciencedirect.com)

ScienceDirect

journal homepage: <http://www.elsevier.com/locate/pjnns>

## Case report

# Silent killer: A scalpel in the aortic wall after spinal surgery



Gokalp Altun <sup>a,\*</sup>, Dogus Hemsinli <sup>b</sup>, Dilek Kutanis <sup>c</sup>, Gurkan Gazioglu <sup>d</sup>

<sup>a</sup> Department of Cardiovascular Surgery, Faculty of Medicine, Karadeniz Technical University, Trabzon, Turkey

<sup>b</sup> Department of Cardiovascular Surgery, Kanuni Education and Research Hospital, Trabzon, Turkey

<sup>c</sup> Department of Anesthesiology, Faculty of Medicine, Karadeniz Technical University, Trabzon, Turkey

<sup>d</sup> Department of Neurosurgery, Faculty of Medicine, Karadeniz Technical University, Trabzon, Turkey

## ARTICLE INFO

## Article history:

Received 12 May 2015

Accepted 2 April 2016

Available online 12 April 2016

## Keywords:

Vascular injury

Spinal surgery

Scalpel

## ABSTRACT

Iatrogenic vascular injury during lumbar spinal surgery is rare, but may lead to serious complications in unrecognized cases. Especially, injuries to aorta or its major branches may result in death unless diagnosed and treated immediately.

We present a rare case of aortic injury with a scalpel in a 56-year-old male patient undergoing lumbar disk surgery. The vascular injury was successfully treated with open surgery. The post-operative period was uneventful and the patient was discharged in a healthy condition on the 8th day. This case once again reminds us that surgery is always open to complications and that early diagnosis and appropriate interventions are of paramount importance to overcome these complications.

© 2016 Polish Neurological Society. Published by Elsevier Sp. z o.o. All rights reserved.

## 1. Introduction

Iatrogenic vascular injury during lumbar spinal surgery is rare, but may lead to serious complications in unrecognized cases. Especially, injuries to aorta or its major branches may result in death unless diagnosed and treated immediately. The incidence of vascular injuries during lumbar discectomy varies between 0.01% and 0.17% [1]. Major vascular injury can cause retroperitoneal massive hemorrhage and circulatory instability in the early postoperative period. Other complications such as arteriovenous fistula and pseudoaneurysm may occur in the late period [2]. In this paper, we discussed a unique case of

injury of the abdominal aorta with a scalpel during lumbar disk surgery.

## 2. Case report

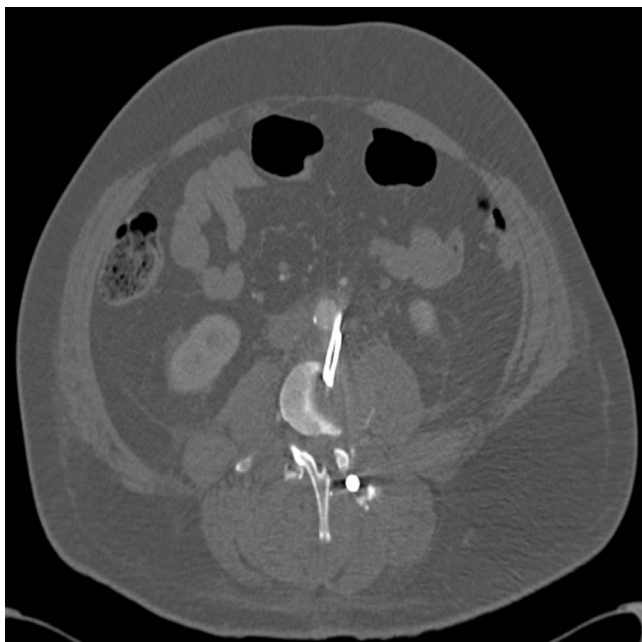A 56-year-old male patient was operated for lumbar degenerative disk disease and spondylosis, and a L3–4, L4–5 discectomy and posterior stabilization was performed. While removing the intervertebral disk at L3–L4 level, the tip of a scalpel was broken and was lost in the disk space. Attempts to retrieve the tip resulted in a further descend of the knife into the disk, and finally, it crossed the anterior longitudinal

\* Corresponding author at: Department of Cardiovascular Surgery, Faculty of Medicine, Karadeniz Technical University, 61040 Trabzon, Turkey. Tel.: +90 532 3718692.

E-mail address: [gokalpaltun@gmail.com](mailto:gokalpaltun@gmail.com) (G. Altun).

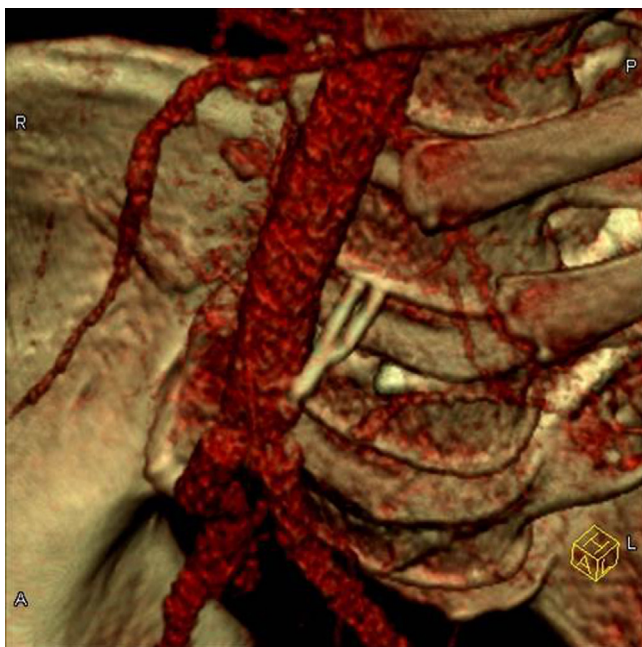<http://dx.doi.org/10.1016/j.pjnns.2016.04.002>

0028-3843/© 2016 Polish Neurological Society. Published by Elsevier Sp. z o.o. All rights reserved.



**Fig. 1 – Computed tomography scan of the abdomen shows a scalpel, which is located at the level of the lower pole of the kidney.**

ligament. Intraoperative radiological imaging revealed that much of the scalpel was in the retroperitoneal region (Figs. 1 and 2). After the lumbar surgery, no sign of significant intraoperative or early postoperative bleeding involving sudden onset bleeding, hypotension, shock and weak or absent pulses in the limb was observed, and hemodynamics were not abnormal. At the first postoperative follow-up,



**Fig. 2 – 3D-VRT scan. A scalpel is seen next to the left of the abdominal aorta. The rear portion of the scalpel is in intervertebral space.**

hemoglobin was 11.2 g/dl and hematocrit was 34.8%, while at the 12th hour hemoglobin levels decreased to 9.2 g/dl and hematocrit to 27.8%. CT of the abdomen revealed minimal free fluid in the bilateral perirenal area and a foreign body partly extending into the abdominal aorta at the L3–L4 level, without causing active extravasation. The patient was then transferred to our clinic. He was immediately taken for surgery, and a self-limiting hematoma was observed in the retroperitoneum. The abdominal aorta and both iliac arteries were clamped from the infrarenal level. The scalpel tip was stable, with the distal part being embedded in the vertebral column, with up to half of the tip entering the aorta from the rear left part of the inferior mesenteric artery. Pseudoaneurysm 2 cm × 3 cm in size had formed around it. Since this region of the aorta is not suitable for primary repair, interposition graft was inserted from the level of the inferior mesenteric artery to 1.5 cm proximal to the aortic bifurcation using 16 mm Dacron. This had to be ligated to the inferior mesenteric artery. The post-operative period was uneventful and the patient was discharged in a healthy condition on the 8th day.

### 3. Discussion

Iatrogenic vascular injuries, particularly injuries of major vessels like aorta or large veins and their major branches, are rare but generally fatal complications of spinal surgery. Therefore, rapid recognition and initiation of effective intervention is critical for good outcome. Physicians fairly commonly fail or delay to recognize the symptoms intra-, and postoperatively. Yet, depending on the nature of vessels injury, the symptoms being initially very mild or may manifest very late and the diagnosis is not often obvious to even meticulous clinicians. The vascular injuries can manifest through a variety of symptoms, which includes acute open or closed bleeding, hypotension, hemoglobin drop, abdominal pain and distension [3–5].

Injury may be seen in the form of vascular damage leading to acute and severe bleeding or of arteriovenous fistula or pseudoaneurysm leading to longer-term clinical symptoms [6–8]. Findings such as sudden onset severe bleeding, hypotension, shock and lack of peripheral pulse are seen in arterial injuries that constitute 30% of vascular injuries. The prone position during disk surgery can limit bleeding for a time by creating compression [4,8–10]. Less dangerous venous bleeding may stop without requiring intervention. However, it may subsequently lead to venous thrombosis findings in the pelvic region and lower extremities. Pseudoaneurysms represent 67% of arterial lesions. They may give findings with a pulsatile mass, findings of pressure on neighboring organs, thrombosis or rupture-related bleeding in the late period [4].

Mortality levels vary from 15% to 65% depending on the vascular structure injured, the type of injury and the duration of the intervention [4,6,7,11,12]. Anterior longitudinal ligament and annulus fibrosis degeneration, aggressive surgery, vertebral anomalies, revision discectomy, previous degenerative disk surgery and retroperitoneal inflammatory processes causing adhesions between vascular structures and disks are factors that increase the risk of vascular injury [4,6,8]. The majority of vascular injuries occur in L4–5 disk surgery, since this is the

most common site of disk surgery and because of the close proximity between the intervertebral disk in the region and the main vascular structures anterior to it. The most frequently injured vessels are the right common iliac vessels [4,9,10].

When vascular injury is suspected, lumbar surgery must be discontinued and intervention in the area of injury must be performed at once [4,7]. If severe bleeding is present in the area of surgery and hemodynamics do not improve despite the requisite replacements being given, emergency laparotomy is indicated [6,7,13]. The mortality rate in arterial injuries in which intervention is delayed may be as high as 100% [11,13]. Surgical intervention without loss of time using imaging techniques is important in terms of preventing mortality [7]. Computed tomography is the most appropriate technique permitting endovascular treatment for diagnosis in patients with stable hemodynamics even though vascular injury is suspected [2,7].

Avoidance of these injuries can be achieved thorough safe clinical practice, adequate illumination, avoiding undue tractions and constant awareness of the anatomy of the surgical field and its neighboring vascular structures. In case of critical hemodynamic instability, vascular repair is associated with high mortality [4]. The endovascular approach is becoming increasingly common in the treatment of traumatic vascular injuries, mortality and morbidity are lower compared to the open approach and that long-term outcomes are good [4,14,15]. In our clinic we also prefer endovascular approach in the treatment of vascular injuries. However, in this case, approximately half of the tip of the scalpel was embedded in the wall of abdominal aorta from the posterior aspect and extended inside to aorta. Since the endovascular approach would be risky and open to complications for this case, we elected to use open surgery.

#### 4. Conclusion

The retrieval of a broken or lost surgical equipment such as a scalpel tip must be performed very carefully and patiently to prevent more serious complications such as major vascular injuries. In the presence of findings suggestive of acute arterial laceration, such as abundant bleeding, hypotension, tachycardia and shock, it is important to perform a multidisciplinary surgical intervention without loss of time. This case once again reminds us that surgery is always open to complications and that early diagnosis and appropriate interventions are of paramount importance to overcome these complications.

#### Conflict of interest

None declared.

#### Acknowledgement and financial support

None declared.

#### Ethics

The work described in this article has been carried out in accordance with The Code of Ethics of the World Medical Association (Declaration of Helsinki) for experiments involving humans; Uniform Requirements for manuscripts submitted to Biomedical journals.

#### REFERENCES

- [1] Shih PY, Lau HP, Jeng CS, Hung MH, Cheng YJ. Iatrogenic left internal iliac artery perforation during lumbar discectomy. *Acta Anaesthesiol Taiwan* 2009;47:196-9.
- [2] Keskin M, Serin KR, Genc FA, Aksoy M, Yanar F, Kurtoglu M. Iatrogenic major vascular injury during lumbar discectomy: report of three cases. *Turk Neurosurg* 2013;23:385-8.
- [3] Sugimoto Y, Tanaka M, Gobara H, Misawa H, Kunisada T, Ozaki T. Management of lumbar artery injury related to pedicle screw insertion. *Acta Med Okayama* 2013;67:113-6.
- [4] Canaud L, Hireche K, Joyeux F, Annoville D, Berthet T, Marty-Ane P, et al. Endovascular repair of aorta iliac artery injuries after lumbar spine surgery. *Eur J Vasc Endovasc Surg* 2011;42:167-71.
- [5] Kakkos SK, Shepard AD. Delayed presentation of aortic injury by pedicle screws: report of two cases and review of the literature. *J Vasc Surg* 2008;47:1074-82.
- [6] Erkut B, Unlu Y, Kaygin MA, Colak A, Erdem AF. Iatrogenic vascular injury during to lumbar disc surgery. *Acta Neurochir* 2007;149:11-6.
- [7] Skippage P, Raja J, McFarland R, Belli AM. Endovascular repair of iliac artery complicating lumbar disc surgery. *Eur Spine J* 2008;17:228-31.
- [8] Aras AB, Ozkan OF, Alar T, Ozkan A, Arık MK, Kosar S, et al. A wandering intravascular scalpel fragment after lumbar discectomy: a case report. *Turk Neurosurg* 2014;24:774-7.
- [9] De Praetere H, Vanden Eycken C, Meuris B, Herijgers P. Migration of broken scalpel into the heart after spine surgery. *Interact Cardiovasc Thorac Surg* 2014;18:527-9.
- [10] Duz B, Kaplan M, Gunay C, Ustunsoz B, Ugurel MS. Iliocaval arteriovenous fistula following lumbar disc surgery: endovascular treatment with a stent-graft. *Turk Neurosurg* 2008;18:245-8.
- [11] Goodkin R, Laska LL. Vascular and visceral injuries associated with lumbar disc surgery: medicolegal implications. *Surg Neurol* 1998;49:358-72.
- [12] Prabhakar H, Bithal PK, Dash M, Chaturvedi A. Rupture of aorta and inferior vena cava during lumbar disc surgery. *Acta Neurochir* 2005;147:327-9.
- [13] Dosoglu M, Is M, Pehlivan M, Yildiz KH. Nightmare of lumbar disc surgery: iliac artery injury. *Clin Neurol Neurosurg* 2006;108:174-7.
- [14] van Zitteren M, Fan B, Lohle PN, de Nie JC, de Waal Malefijt J, Vriens PW, et al. A shift toward endovascular repair for vascular complications in lumbar disc surgery during the last decade. *Ann Vasc Surg* 2013;27:810-9.
- [15] Wu CY, Hung YN, Liu YH, Ko PJ. Endovascular treatment of iatrogenic iliac artery disruption in lumbar disc surgery. *Ann Vasc Surg* 2009;23(255):e7-11.