

Available online at www.sciencedirect.com

ScienceDirect

journal homepage: <http://www.elsevier.com/locate/pjnns>

Case report

Nucleus accumbens stimulation in pathological obesity

Marek Harat^a, Marcin Rudaś^b, Piotr Zieliński^{c,*}, Julita Birska^b, Paweł Sokal^b^aDepartment of Public Health, Collegium Medicum, Nicolaus Copernicus University in Torun, Poland^bDepartment of Neurosurgery, 10 Military Hospital Bydgoszcz, Poland^cDepartment of Sports Medicine, University of Physical Education and Sport in Gdansk, Poland

ARTICLE INFO

Article history:

Received 27 June 2015

Accepted 26 January 2016

Available online 5 February 2016

Keywords:

Deep brain stimulation

Obesity

Nucleus accumbens

ABSTRACT

One of the potential treatment methods of obesity is deep brain stimulation (DBS) of nucleus accumbens. We describe the case of 19 years old woman with hypothalamic obesity. She weighted 151.4 kg before DBS and the non-surgical methods proved to be inefficient. She was treated with implantation of DBS electrode to nucleus accumbens bilaterally. Results were measured with body mass index and neuropsychological tests. Follow-up was 14 months. Fourteen months after surgery weight was 138 kg, BMI was 48.3. Neuropsychological test results were intact. The presented case supports the thesis of treatment of obesity with nucleus accumbens stimulation.

© 2016 Polish Neurological Society. Published by Elsevier Sp. z o.o. All rights reserved.

1. Introduction

According to WHO, overweight and obesity are defined as abnormal or excessive fat accumulation that may impair health. For the classification and definition of overweight and obesity BMI index is used and is defined as a person's weight in kilograms divided by the square of his height in meters (kg/m^2). BMI greater than or equal to 25 means overweight, BMI greater than or equal to 30 is obesity. Worldwide obesity is a major health problem constituting the fifth leading risk for global deaths [1].

Obesity is preventable by changes in dietary and physical activity patterns. Modification of diet and exercises has important but limited impact on overcome of obesity and

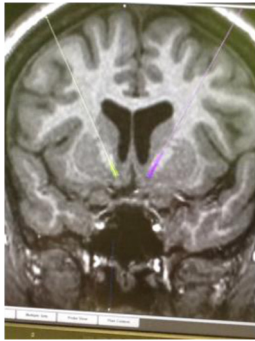
overweight [2]. Pharmacologic therapy show rather modest effects and is associated with side effects e.g. orlistat causing gastrointestinal intolerance. Surgical options in management of obesity aim decrease of volume of stomach: bands placed around stomach, sleeve gastrectomy, gastroplasty and gastric bypass surgery creating small stomach pouch. These procedures cause vitamin and protein, microelements deficiencies and have high risk of postoperative complications [3]. Several experimental studies on animals showed beneficial effect of hypothalamic stimulation on reduction of hunger, inhibition of food intake and weight loss [4,5]. Few studies on deep brain stimulation of hypothalamus in humans demonstrated influence on feeding behavior and weight reduction but showed also some adverse effects and followed regain of the weight. Therefore some authors propose another therapeutic approach,

* Corresponding author at: Department of Neurosurgery, 10 Military Hospital, Powstańców Warszawy 5 Str, 86-681 Bydgoszcz, Poland. Tel.: +48 523787096/501042521; fax: +48 523787094.

E-mail address: pziel@awf.gda.pl (P. Zieliński).

<http://dx.doi.org/10.1016/j.pjnns.2016.01.014>

0028-3843/© 2016 Polish Neurological Society. Published by Elsevier Sp. z o.o. All rights reserved.



Picture 1 – Planned electrode trajectory on coronal MRI.

to modulate immediate reward circuits, including nucleus accumbens (NAcc) [5–11].

2. Case

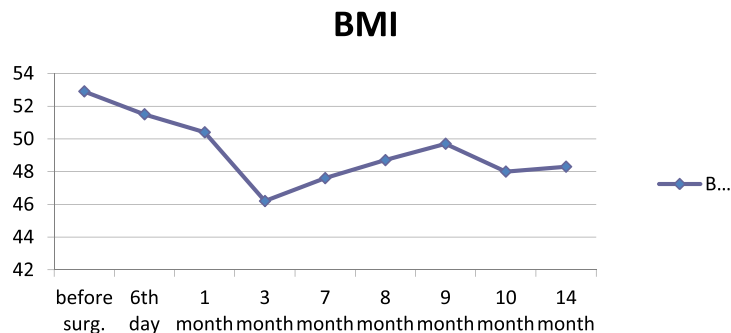
We describe the case of 19 years old woman with pathological obesity. She suffered from hypothalamic obesity due to the earlier craniopharyngioma surgery performed in 2004. She had damaged hypothalamus by tumor and surgery. She weighted 151.4 kg before surgery and all of the current non-surgical methods proved to be inefficient. She suffered from glucose intolerance, lumbar spondylosis, low self-assessment and mild depression. The patient was gaining weight, craving for food like an addict for drugs. She was under parental control all the time, even the refrigerator was locked with a padlock. She was qualified for bariatric surgery by her endocrinologist and general surgeons. But the patient and her family had some concerns about bariatric surgery. After approval of the local bioethical committee she was treated with implantation of DBS electrode to nucleus accumbens bilaterally. The follow-up lasted fourteen months.

The target of stimulation was defined bilaterally in nucleus accumbens. The trajectory was planned through the anterolateral part of the anterior limb of internal capsule (Picture 1). Then in general anesthesia both electrodes were inserted alongside the planned trajectories under the control of X-ray. The correct placement of the electrodes was confirmed by intraoperative CT-MRI fusion. In the next stage of the operation the stimulator was implanted in the right subcutaneous

subclavian pocket. The procedure lasted about three hours. On the day of surgery the stimulator was turned on. We used in both electrodes bipolar stimulation with polarity (–) to contact one electrode and (+) on the contact 4 electrodes, 208 μ s pulse width, frequency 130 Hz, 2 mA stimulation current. The patient very well tolerated the stimulation, there were no side effects of treatment. During her stay at the hospital and at monthly outpatient visits the parameters of stimulation were modified reaching at last the value of 3.75 mA, while keeping the other parameters without alteration. Patient since surgery was under neuropsychological and psychotherapeutic care. She had been monitored on mental state, cognitive performance, and weight control. The process of psychotherapy was to maintain therapeutic effect of surgery. It was focused on patient lifestyle changes, taking into account the context of her family. To assess the severity of depressive symptoms we used Beck Depression Inventory (BDI). The following neuropsychological tests of cognitive performance testing were carried out: Wisconsin Card Sorting Test (WCST), Trail Making Test (TMT), A and B and Interference Test Names and Color Stroop (Stroop Color-Word Interference Test). The neuropsychological examination and measurement of body weight before surgery was performed implantation in the 6th postoperative day, and 1, 3, 7 and 14 months after surgery.

3. Results

Three months after surgery weight was 132 kg, BMI was 46.2. Neuropsychological test results were intact. Weight control and neuropsychological test results before and after the treatment further studies are presented in Picture 2. Prior to surgery the patient weight was 151.4 kg and height 160 cm (BMI – 52, 9). BDI results testify to the presence of mild depressive syndrome, confirming the information obtained from the conversation with the patient. The results of neuropsychological tests before surgery showed a significantly reduced psychomotor speed in a simple visual-spatial task (TMT A) and the reduction of motor parameters, visual-spatial working memory while retaining the ability to combine the two principles of action of her memory (TMT B). Executive functions (WCST), the speed of reading and verbal working memory (Stroop) were normal. After surgery in the other three examinations the progressive loss of body weight of the patient was observed. Three months after the treatment she weighted 19.6 kg less. The decline in body weight was



Picture 2 – Body Mass Index before surgery and in follow-up.

accompanied by improvement in the emotional state (BDI). Over the next four months the patient took on the weight reaching in the 9th month 142 kg. In the next 4 months, the patient lost 5 kg. During a latest visit her weight was 138 kg. These fluctuations may be related to the switching off by accident of the pacemaker, which was noted twice. During the switch off periods she reported increased craving for food. Currently, she shows no evidence of a depressive syndrome. The patient reported feeling better, having more energy and willingness to act. She has no feeling of increased appetite nor increased need for food. She is satisfied with the results brought by the treatment. Before the operation she had failed to get the weight loss of more than 5 kg. It should be noted, however, that during the growth of body weight (142 kg) patient experienced a slight discomfort (6 points on the BDI), but it was not significant. In terms of cognitive neuropsychology the test results indicate a gradual improvement in psychomotor performance in visual-spatial working memory, which in the third examination were normalized and remained at that level until the last test. In the first two tests performed after surgery tests examining the efficiency of executive functions decreased slightly (WCST), but they remained consistently within normal limits. In the third examination, the improvement of the results was close to the level before treatment.

4. Discussion

Food intake and energy balance is under control of homeostatic and non-homeostatic pathways [12–15]. Homeostatic control pathways are based on hypothalamus with inputs from digestive tract and vagal nerve. Sometimes non-homeostatic systems overtake control over hypothalamus [12]. They depend on reward system and cortico-limbic structures [12,16,17]. We describe a patient with pathological obesity after craniopharyngioma surgery. Such hypothalamic obesity is common in patients after any lesions in the hypothalamic region, affecting homeostatic mechanisms of hunger and satiety [18–21]. Some authors state that bariatric obesity is inefficient in such cases [3]. There are several approaches based on deep brain stimulation of different targets in the treatment of pathological obesity, among them hypothalamus and nucleus accumbens [6,7,11]. These approaches are targeted on modulation of hypothalamic homeostatic networks or on modulation of immediate reward (“limbic”) circuits.

The data on weight and BMI indicate the presence of morbid obesity, which significantly limited the patient's daily functioning. The patient also reported distimia, unwillingness to act, understated self-esteem and lack of motivation to make further efforts for weight loss, which was connected with earlier failures in this regard. Attempts to make physical activity and diet did not produce the desired effect. We have chosen nucleus accumbens because a scar after craniopharyngioma surgery distorted anatomy of hypothalamic region, thus making the targeting less reliable. Moreover, the published data on neurophysiology, animal models and human cases suggest the role of nucleus accumbens in immediate reward circuits [11]. NAcc stimulation is proven

to be effective for example in drugs, nicotine and alcohol dependence [7,8,22]. We have decided to treat the patient as dependent from food intake. This approach may be also supported with our own experience with surgical treatment of obsessive-compulsive disease (OCD). The results of the neuropsychological tests indicate the relative stability of cognitive functioning of verbal memory and psychomotor speed after the surgery. Our yet unpublished case of a patient with OCD treated with bilateral nucleus accumbens stimulation proves the role of this structure in compulsive behavior, which may be also connected with craving for food. Modulation of Nacc activity resulted in fast weight loss in the presented case without psychological deterioration. This may support the hypothesis of important role of limbic system in pathogenesis of obesity after hypothalamic lesion.

5. Conclusion

The presented case supports the hypothesis that modulation of immediate brain reward system may play a significant role in treatment of hypothalamic obesity.

Conflict of interest

None declared.

Acknowledgement and financial support

Only the authors provided work to the manuscript, there was no other help in providing language verification, writing assistance nor proof reading the article.

Ethics

The work described in this article has been carried out in accordance with The Code of Ethics of the World Medical Association (Declaration of Helsinki) for experiments involving humans; Uniform Requirements for manuscripts submitted to Biomedical journals.

REFERENCES

- [1] World health statistics. Geneva: WHO Press; 2012. p. 109–20.
- [2] Global health risks: mortality and burden of disease attributable to selected major risks. Geneva: World Health Organization; 2009. http://www.who.int/healthinfo/global_burden_disease/GlobalHealthRisks_report_full.pdf.
- [3] Weismann D, Pelka T, Bender G, Jurowich C, Fassnacht M, Thalheimer A, et al. Bariatric surgery for morbid obesity in craniopharyngioma. *Clin Endocrinol (Oxf)* 2012. <http://dx.doi.org/10.1111/j.1365-2265.2012.04409.x>
- [4] Melega WP, Lacan G, Gorgulho AA, Behnke EJ, De Salles AA. Hypothalamic deep brain stimulation reduces weight gain in an obesity-animal model. *Neurosurg Rev* 2012;35(1):37–42.
- [5] Tomycz ND, Whiting DM, Oh MY. Deep brain stimulation for obesity – from theoretical foundations to designing the

- first human pilot study. *Acta Neurochir (Wien)* 2011;153:2293-306.
- [6] Benabid AL, Torres N. New targets for DBS. *Parkinsonism Relat Disord* 2012;18(Suppl 1):S21-3.
- [7] Halpern CH, Torres N, Hurtig HI, Wolf JA, Stephen J, Oh MY, et al. Expanding applications of deep brain stimulation: a potential therapeutic role in obesity and addiction management. *Acta Neurochir (Wien)* 2011;153:2293-306.
- [8] Mantione M, van de Brink W, Schuurman PR, Denys D. Neurosurgery smoking cessation and weight loss after chronic deep brain stimulation of the nucleus accumbens: therapeutic and research implications: case report. *Neurosurgery* 2010;66:E218.
- [9] Halpern CH, Wolf JA, Bale TL, Stunkard AJ, Danish SF, Grossman M, et al. Deep brain stimulation in the treatment of obesity. *J Neurosurg* 2008;109:625-34.
- [10] Sun B, Li D, Lin G, Zhan S, Zhang XX. Grading refractory anorexia nervosa for surgical treatment. *Stereotact Funct Neurosurg* 2012;90(Suppl 1):99.
- [11] Taghva A, Corrigan JD, Rezai AR. Obesity and brain addiction circuitry: implications for deep brain stimulation. *Neurosurgery* 2012;71:224-38.
- [12] Berthoud HR. Homeostatic and non-homeostatic pathways involved in the control of food intake and energy balance. *Obesity* 2006;Suppl 5:197S-200S.
- [13] Teasure J. Eating disorders. *Medicine* 2008;36:430-5.
- [14] Stankovic A, Potenza MN. Obesity and binge eating disorder. In: Koob GF, Le Moal M, Thompson RF, editors. *Encyclopedia of behavioral neuroscience*. Oxford: Elsevier Ltd; 2010. p. 477-83.
- [15] Volkov ND, Wang GJ, Fowler JS, Telang F. Overlapping neuronal circuits in addiction and obesity: evidence of systems pathology. *Philos Trans R Soc Lond B Biol Sci* 2008;393:3191-200.
- [16] Haahr ME, Rasmussen PM, Madsen K, Marnier L, Ratner C, Gillings N, et al. Obesity is associated with high serotonin 4 receptor availability in the brain reward circuitry. *Neuroimage* 2012;61:884-8.
- [17] Stoeckel LE, Kim J, Weller RE, Cox JE, Cook III EW, Horwitz B. Brain effective connectivity of a reward network in obese women. *Res Bull* 2009;79:388-95.
- [18] Skorzewska A, Lal S, Wasserman J, Guyda H. Abnormal food-seeking behavior after surgery for craniopharyngioma. *Neuropsychobiology* 1989;21:17-20.
- [19] Vinchon M, Weill J, Delestret I, Dhellemmes P. Craniopharyngioma and hypothalamic obesity in children. *Childs Nerv Syst* 2009;25:347-52.
- [20] Simoneau-Roy J, O'Gorman C, Pencharz P, Adeli K, Daneman D, Hamilton J. Insulin sensitivity and secretion in children and adolescents with hypothalamic obesity following treatment for craniopharyngioma. *Clin Endocrinol (Oxf)* 2010;72:364-70.
- [21] Iughetti L, Bruzzi P. Obesity and craniopharyngioma. *Ital J Pediatr* 2011;37:38.
- [22] Goncalves-Ferreira A, Simoes Do Cuto F, Rainha Campos A, Lucas Neto L, Salgado L, Lauterbach M, et al. Deep brain stimulation for the treatment of refractory cocaine dependence. *Stereotact Funct Neurosurg* 2012;90(Suppl 1):90.