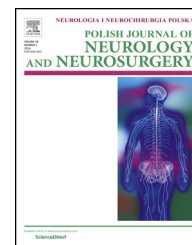

Available online at www.sciencedirect.com

ScienceDirect

journal homepage: <http://www.elsevier.com/locate/pjnns>

Case report

Emergency microsurgical embolectomy in acute ischemic stroke with diffusion-negative MRI



Ki Seong Eom, Daw Won Kim, Sungdon Kang *

Department of Neurosurgery, Wonkwang University School of Medicine, Iksan, Republic of Korea

ARTICLE INFO

Article history:

Received 6 April 2015

Accepted 5 August 2015

Available online 17 August 2015

Keywords:

Diffusion-weighted imaging

Acute ischemic injury

Microsurgical embolectomy

ABSTRACT

Although diffusion-weighted imaging (DWI) is highly sensitive and specific for the detection of acute ischemic injury, there are increasing reports that it may fail to demonstrate an acute stroke. Here, we present a case involving an acute ischemic stroke with a false-negative DWI in a 64-year-old woman who had undergone an emergency microsurgical embolectomy for an occluded middle cerebral artery (MCA). Although the endovascular mechanical embolectomy failed in treating the occluded MCA, we were able to successfully treat our patient with the second treatment option of a microsurgical embolectomy. Microsurgical embolectomy might be the treatment of choice, especially if the mechanical catheter is expected to not be able to access the target artery due to tortuous vascular structures.

© 2015 Polish Neurological Society. Published by Elsevier Sp. z o.o. All rights reserved.

1. Introduction

In order to optimize stroke recovery, rapid recognition of symptoms, early diagnosis with radiological images, and immediate appropriate treatment are paramount. Diffusion-weighted imaging (DWI) is highly sensitive and specific for acute ischemia. During the last few years, DWI has been shown to be an excellent tool for the detection of acute stroke. However, its sensitivity in this regard appears to have limitations, as evidenced by the increasing number of false-negative reports [1–3]. Here, we present a case involving an acute ischemic stroke with a false-negative DWI in a 64-year-old woman who had undergone an emergency microsurgical embolectomy for an occluded middle cerebral artery (MCA). This patient was successfully treated due to early recognition and proper rapid treatment.

2. Case report

In August 2012, a 64-year-old woman was admitted to the emergency room at 1200 after the sudden onset of speech disturbances and left facial palsy that developed around 0900. Four years before the present admission, she had undergone conservative treatment for an acute cerebral infarction in the territory of the left MCA and a left internal cerebral artery (ICA) occlusion. Since then, she had lived with right hemiparesis of grade 4+ as a sequela of the cerebral infarction. Two years before the present admission, she had undergone burr-hole trephination and closed-system drainage for a chronic subdural hematoma in the right convexity. In addition, she had been taking warfarin (2 mg) for the past 10 years for atrial fibrillation and obstructive cardiomyopathy. DWI that was obtained 4 h after the onset of symptoms revealed no acute

* Corresponding author at: Department of Neurosurgery, Wonkwang University School of Medicine, 344-2 Shinyongdong, Iksan 570-749, Republic of Korea. Tel.: +82 63 859 1463; fax: +82 63 852 2606.

E-mail addresses: kseom@wonkwang.ac.kr (K.S. Eom), kimdw@wonkwang.ac.kr (D.W. Kim), kangsd@wonkwang.ac.kr (S. Kang).
<http://dx.doi.org/10.1016/j.pjnns.2015.08.001>

0028-3843/© 2015 Polish Neurological Society. Published by Elsevier Sp. z o.o. All rights reserved.

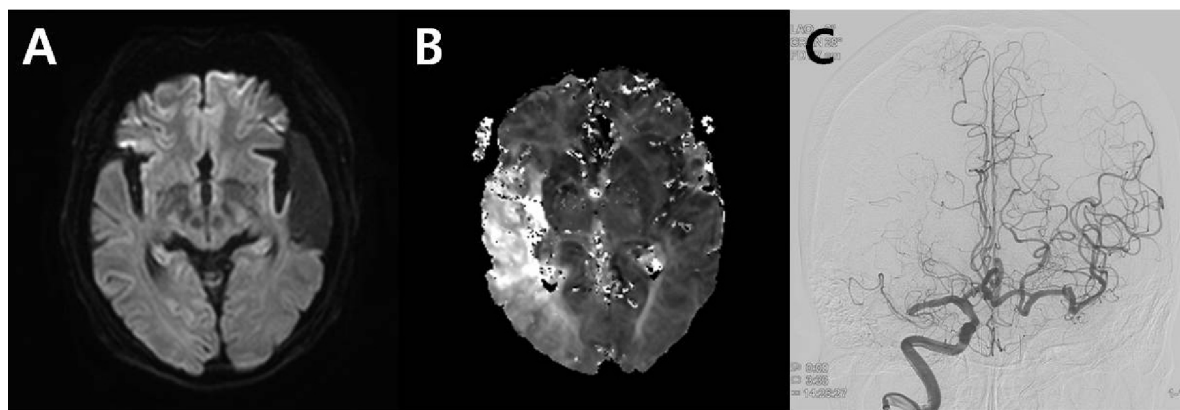


Fig. 1 – (A) Diffusion-weighted image (DWI) that was obtained 4 h after the onset of symptoms shows no acute lesions, except for the preexisting multiple encephalomalacic brain lesion in the right temporal lobe. (B) Perfusion-weighted image (PWI) of magnetic resonance imaging (MRI) shows a severe diffuse perfusion deficit at the right middle cerebral artery (MCA) territory and diffusion-perfusion mismatch. (C) A cerebral angiogram showing the occlusion of the right MCA bifurcation and total occlusion of the left proximal cervical internal cerebral artery.

lesions, including acute infarction, except for the preexisting multiple encephalomalacic brain lesion in the left temporal lobe (Fig. 1A). However, perfusion-weighted imaging (PWI) of magnetic resonance imaging (MRI) revealed a severe diffuse perfusion deficit in the right MCA territory, which exhibited diffusion-perfusion mismatch (DPM) (Fig. 1B). A cerebral angiogram revealed an acute thromboembolic occlusion of the right MCA bifurcation and chronic total occlusion of the left proximal cervical ICA (Fig. 1C). An endovascular mechanical embolectomy with a penumbra reperfusion catheter was performed at 1430. However, the endovascular mechanical embolectomy failed to recanalize the occluded right MCA bifurcation because the penumbra catheter could not advance to the target artery due to the tortuous proximal cervical ICA. Six hours after the onset of symptoms, her consciousness gradually deteriorated to a Glasgow Coma Scale score of 11 (E2, V4, M5), and her left-sided motor power exacerbated to a grade 2. We performed an emergency microsurgical embolectomy through the right pterional approach. A right distal MCA

occlusion was confirmed in the operative field, and the thrombus was removed at 1700. The sites of arteriotomy were closed using mini-clips. Her left-sided motor power recovered to a grade 5, and her consciousness gradually improved to alertness 4 h after the operation. Follow-up DWI and PWI MRI that were obtained 36 h after the operation revealed no diffusion restrictions or perfusion defects along the right MCA territory, except for postoperative hemorrhages in the sylvian fissure and perisylvian parenchyma (Fig. 2A and B). A postoperative computed tomography angiogram revealed successful MCA recanalization with sufficient blood flow in the right MCA territory (Fig. 2C). The patient was doing well 2 months postoperatively.

3. Discussion

The treatment options for acute ischemic strokes vary depending on the time of onset, the imaging findings, and

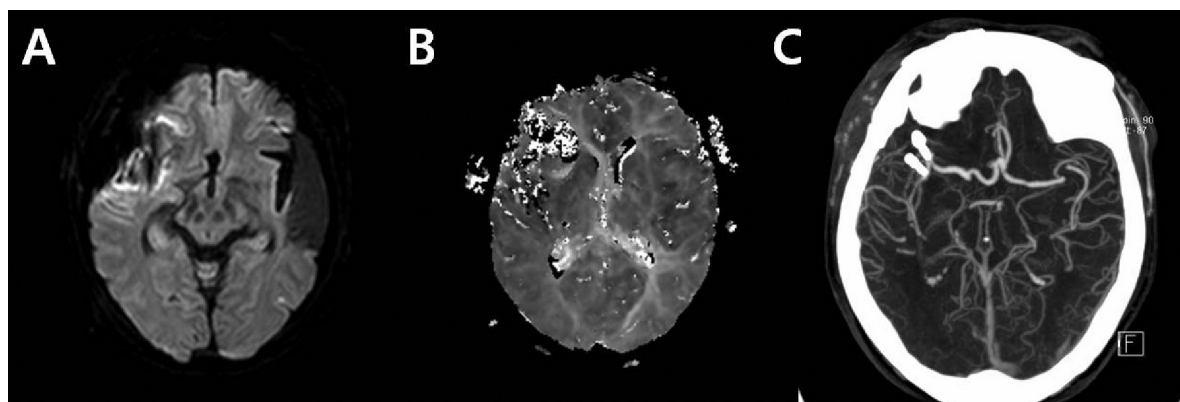


Fig. 2 – Diffusion-weighted image (DWI) (A) and perfusion-weighted image (PWI) (B) of the middle cerebral artery that was obtained 36 h after the operation revealed no diffusion restrictions or perfusion defects along the right middle cerebral artery (MCA) territory. (C) A postoperative computed tomography angiogram shows successful MCA recanalization with sufficient blood flow in the right MCA territory. Two mini-clips for closure of arteriotomy are noted.

the type of stroke. The use of intravenous (IV) tissue plasminogen activator (tPA) is an effective thrombolytic therapy for acute strokes when given during the 0- to 4.5-h time window. If IV tPA treatment fails or patients are not suitable for this treatment, clinicians may consider the use of endovascular mechanical clot retrieval for up to 8 h after symptoms begin. Although emergency microsurgical embolectomies have been performed sporadically for acute major artery occlusions since the late 1950s, they have not been widely performed since the introduction of local thrombolysis [4]. Some authors have suggested that microsurgical embolectomies that are conducted within 8 h of the onset of the stroke are an alternative treatment option for major artery occlusions. They have suggested that microsurgical embolectomies can be safely performed with less morbidity even after IV thrombolytic therapy. Moreover, previous studies have indicated that the recanalization rate of microsurgical embolectomies is 100% [4].

DWI, which provides the earliest imaging evidence of ischemic injury, can reveal abnormalities before other conventional MRI sequences, even in transient ischemic attacks. However, DWI that is conducted as an isolated sequence may fail to demonstrate an acute stroke in up to 20% of the cases [1-3]. Because of these findings, the reliability of negative DWI studies for excluding ischemic stroke seems questionable. Wang et al. [1] suggested 3 possible mechanisms to explain the lack of diffusion changes in the acute phase in patients that were eventually shown to have an infarction. First, the cerebral blood flow (CBF) may have been at an intermediate level, which was below the threshold for neuronal dysfunction but above the threshold for reduced diffusion. Second, reperfusion may have occurred and restored the diffusion constant to normal but not enough to prevent the eventual delayed infarction. Third, a second ischemic event may have caused the eventual infarction. To varying extents, the above 3 hypotheses all involve the ischemic penumbra concept [3]. The concept of the ischemic penumbra, which was originally introduced in 1981, was defined as an area of reduced CBF with electrical failure but with preserved ion homeostasis and transmembrane electrical potentials. When an ischemic stroke occurs, the peripheral vessels of the lesion initially dilate in order to sustain blood filling. Such compensatory vasodilation occurs in areas with mild decrease in CBF, resulting in an increase in collateral blood flow and the maintenance of normal cerebral blood volume. However, the decreased levels of CBF may not be sufficient to maintain normal electrical activity, which is reflected by functional neurologic deficits [3]. When this autoregulatory mechanism is unsuccessful because of an excessive reduction in the blood filling pressure so that CBF becomes remarkably reduced in the involved region, the oxygen extraction fraction (OEF) must be increased in order to maintain the oxygen supply in this area. This phenomenon is sometimes referred to as misery perfusion [3]. When the OEF reaches its upper limit, the cerebral metabolic rate for oxygen begins to reduce, and, subsequently, irreversible ischemic changes with cytotoxic edema produces a positive DWI in MRI. Shintani et al. [3] have suggested that the prolonged penumbra state that occurs due to unknown reasons results in false-negative DWIs. Oppenheim et al. [2] have suggested

that false-negative DWI studies are not uncommon during the first 24 h of a stroke. Thus, negative DWI findings that are obtained in the first 24 h after onset are not a reliable indicator by which to exclude a stroke lesion, especially if the symptoms are suggestive of a stroke in the posterior circulation and if false-negative DWI findings are no longer observed after 24 h.

DWI can detect acute ischemic strokes in the hyperacute stage, while PWI MRI can be used to measure the hypoperfused areas of the brain [5]. Positive DPM is defined as the difference between the hypoperfused area on PWI and the smaller area of the corresponding ischemic lesion on DWI. Identification of DPM is believed to be of considerable therapeutic importance and to provide a guideline in patient triage for thrombolytic therapy [5]. Recent studies have demonstrated that DPM does not optimally define the ischemic penumbra because early abnormalities on DWI overestimate the infarct core by including part of the penumbra and the abnormalities on PWI overestimate the penumbra by including areas of benign oligemia [5].

Our case was worth reporting in a number of respects. First, our patient was admitted 3 h after the development of the first symptom. Upon admission, DWI revealed no abnormal findings. However, we could detect the right MCA territory ischemic stroke through PWI and angiography. This suggested that diagnoses of acute ischemic strokes that are made based only on DWI is very dangerous for making decisions of the appropriate treatment. Second, although the endovascular mechanical embolectomy failed in treating the occluded MCA, we were able to successfully treat our patient with the second treatment option of an emergency microsurgical embolectomy. Postoperative PWI revealed the disappearance of the perfusion defect in the right MCA territory. This suggested that emergency microsurgical embolectomy is another option in treating acute ischemic stroke patients. Microsurgical embolectomy might be the treatment of choice, especially if the mechanical catheter is expected to not be able to access the target artery due to tortuous vascular structures, as in our patient, or due to patients who are ineligible to receive IV thrombolysis.

4. Conclusion

We should always pay attention to the varieties of hemodynamic changes that occur in acute ischemic strokes. In addition, we should be aware of the proper and rapid treatment options among the variable treatment modalities depending on the progress of the acute ischemic stroke.

Conflict of interest

The authors report no conflict of interest.

Acknowledgement and financial support

This paper was supported by Wonkwang University in 2014.

Ethics

The work described in this article has been carried out in accordance with The Code of Ethics of the World Medical Association (Declaration of Helsinki) for experiments involving humans; Uniform Requirements for manuscripts submitted to Biomedical journals.

REFERENCES

- [1] Wang PY, Barker PB, Wityk RJ, Uluğ AM, van Zijl PC, Beauchamp Jr NJ. Diffusion-negative stroke: a report of two cases. *Am J Neuroradiol* 1999;20:1876–80.
- [2] Oppenheim C, Stanescu R, Dormont D, Crozier S, Marro B, Samson Y, et al. False-negative diffusion-weighted MR findings in acute ischemic stroke. *Am J Neuroradiol* 2000;21:1434–40.
- [3] Shintani S, Yokote H, Hanabusa K, Shiigai T. False-negative and false-positive diffusion-weighted MR findings in acute ischemic stroke and stroke-like episodes. *J Rural Med* 2005;1:27–32.
- [4] Kim DW, Jang SJ, Kang SD. Emergency microsurgical embolectomy for the treatment of acute intracranial artery occlusion: report of two cases. *J Clin Neurol* 2011;7:159–63.
- [5] Chen F, Ni YC. Magnetic resonance diffusion-perfusion mismatch in acute ischemic stroke: an update. *World J Radiol* 2012;4:63–74.