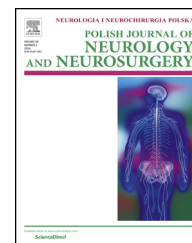


Available online at www.sciencedirect.com

ScienceDirect

journal homepage: <http://www.elsevier.com/locate/pjnns>

Original research article

Low-symptomatic skeletal muscle disease in patients with a cardiac disease – Diagnostic approach in skeletal muscle laminopathies



Agnieszka Madej-Pilarczyk^{a,*}, Michał Marchel^b, Karolina Ochman^c,
Joanna Cegielska^d, Roman Steckiewicz^b

^a Neuromuscular Unit, Mossakowski Medical Research Center, Polish Academy of Sciences, Warsaw, Poland

^b 1st Department of Cardiology, Medical University of Warsaw, Banacha 1a, Warsaw, Poland

^c Clinics and Medical Laboratories INVICTA, Genetics Clinic, Gdansk, Poland

^d Department of Neurology, Medical University of Warsaw, Bielanski Hospital, Warsaw, Poland

ARTICLE INFO

Article history:

Received 12 April 2017

Accepted 14 September 2017

Available online 25 September 2017

Keywords:

LMNA gene

Lamin A/C

Laminopathy

Emery-Dreifuss muscular dystrophy

Cardiac involvement

ABSTRACT

Mild skeletal muscle symptoms might be accompanied with severe cardiac disease, sometimes indicating a serious inherited disorder. Very often it is a cardiologist who refers a patient with cardiomyopathy and/or cardiac arrhythmia and discrete muscle disease for neurological consultation, which helps to establish a proper diagnosis. Here we present three families in which a diagnosis of skeletal muscle laminopathy was made after careful examination of the members, who presented with cardiac arrhythmia and/or heart failure and a mild skeletal muscle disease, which together with positive family history allowed to direct the molecular diagnostics and then provide appropriate treatment and counseling.

© 2017 Published by Elsevier Sp. z o.o. on behalf of Polish Neurological Society.

1. Introduction

Discrete skeletal muscle symptoms, which are associated with cardiac disease and which are present especially in younger patients sometimes could indicate a serious systemic inherited disorder. The term “discrete symptom” usually describes a mild symptom, which could bother patients, but it is not disabling or it does not exclude them from everyday life. Discrete symptoms are often neglected both by patient and by

his/her physician. Patients easily adapt to the restrictions, associated with subclinical disease of skeletal muscles. This is also related to a doctor who observes the symptoms, like abnormal gait pattern, local muscle atrophy, mild muscle weakness causing problems when climbing stairs or getting up from the squatting position. Some skeletal muscle symptoms or abnormal results of diagnostic test almost always lead to diagnostic steps, e.g. joint contractures or elevated creatinine kinase, while others need longer observation before any diagnostic action, e.g. slight muscle weakness or pain, which

* Corresponding author at: Neuromuscular Unit, Mossakowski Medical Research Center, Polish Academy of Sciences, Pawlowskiego 5, 02-106 Warsaw, Poland.

E-mail address: agamadpil@gmail.com (A. Madej-Pilarczyk).

<http://dx.doi.org/10.1016/j.pjnns.2017.09.006>

0028-3843/© 2017 Published by Elsevier Sp. z o.o. on behalf of Polish Neurological Society.

might be explained by excessive physical effort, radiculopathy or psychosomatic disease. When similar muscle symptoms are also found in patient's relatives, it could further support the hypothesis of inherited disease: it helps to establish a diagnosis, to calculate a risk of recurrence of a disease in patient's progeny and to choose adequate therapeutic approach.

Since the majority of genetic skeletal muscle diseases might be associated with defect of cardiomyocytes and subsequent cardiomyopathy with heart failure and/or arrhythmia, they are increasingly perceived as systemic disorders and they are treated by both neurologists and by cardiologists/internists [1]. Inherited skeletal muscle diseases with proved cardiological component include but are not limited to dystrophinopathies [4,5], Emery-Dreifuss muscular dystrophy (EDMD1) [2,3], in limb-girdle muscular dystrophies (LGMD): sarcoglycanopathies associated with defect in α -, β - γ - or δ -subunits of the dystrophin-associated sarcoglycan complex (LGMD2D, E, C, F, respectively) [6,7], titinopathies (LGMD2J) and LGMD2I associated with mutations in fukutin-related protein (FKRP), both types of myotonic dystrophy (DM1, DM2) [8], nemalinopathies [9], desminopathies [10] and Danon disease [11].

Patients with diagnosed heart disease presenting symptoms which are suggestive for skeletal muscle disease should be asked about similar symptoms in their family members, and their relatives should also be consulted. It is important to establish possible familial nature of a disease and trait of inheritance (dominant, recessive) and to select genes for molecular testing. Isolate discrete muscle symptoms, which are to be looked for in family members, include e.g. slight elbow and ankle contractures, muscle atrophy in hands, shoulder instability, muscle pain, lack of reflexes, elevated creatinine kinase (CK).

We present below a diagnostic approach which resulted in diagnosis of skeletal muscle laminopathy in members of 3 different families. Initially they presented with cardiac failure and/or arrhythmia what prompted them to search for medical attention. Further detailed examination revealed then a mild skeletal muscle disease, which together with positive family history allowed to initiate molecular diagnostics and to provide appropriate treatment and counseling.

2. Family reports

2.1. Family 1

31-years old male (II:2) was referred to a neuromuscular consultation because of slowly progressing weakness of the lower limbs, hindering from climbing stairs and getting up from a squatting and sitting position. Since the school years he was perceived as less agile than peers and he had worse results in running. At the age of 31 he was implanted pacemaker DDD type because of atrioventricular block (AVB) II grade (2:1) with episodes of bradycardia of 21/min. Conduction disorders were seen on ECG done routinely during obligatory periodic testing at work. The patient did not report syncope; however he noticed decreased tolerance of physical effort and periodic edemas of the legs. On echocardiography borderline enlargement of the left atrium was found (4.2 cm) with general

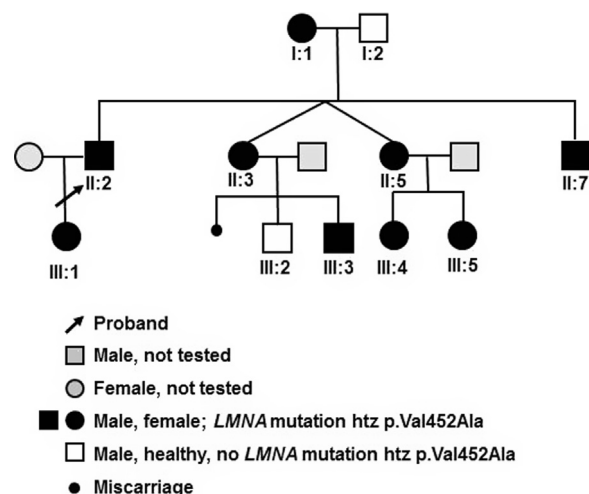


Fig. 1 – Pedigree of the Family 1. Note autosomal dominant trait of inheritance.

hypokinesia of the left ventricle, while ejection fraction (EF) was within the normal range (60%). NTproBNP was at the level of 66.9 pg/mL ($N < 400$ pg/ml). On neurological examination there were observed waddling gait, lumbar hyperlordosis, slight elbow and ankle contractures, cervical spine rigidity, slim shoulder girdle with preserved strength of arms and lack of tendon reflexes in mm. biceps and mm. triceps. Diagnostic tests showed moderately increased level of creatine kinase (CK) – 404 U/l, then 310 U/l ($N < 170$ U/l). Electromyography (EMG) revealed myopathic pattern in the m. biceps brachii. The family history (Fig. 1) revealed that slight elbow contractures and cervical spine rigidity were observed in 29-years old twin sisters of the proband (II:3, II:5), and waddling gait in 52-years old mother (I:1). Neurological examination was done in the proband's mother (I:1), father (I:2), sister (II:3) and 18-years old brother (II:7). The proband's mother (I:1) has been less agile than peers since childhood. At the age of 35 there were noticed problems with climbing stairs and standing from squatting position. She did not seek medical attention. On neurological examination waddling gait, lumbar hyperlordosis, slight cervical spine rigidity and lack of Achilles tendon reflexes were observed. No skeletal muscle wasting or contractures were seen. Periodically she has palpitations. In previous ECG atrioventricular block II Wenckebach type was found, but no diagnostics was initiated then. At the age of 52 the patient was qualified to a gynecological procedure. During routine evaluation before surgery a conduction defect was found. On 24-hours Holter monitoring AVB II Wenckebach type was confirmed again; it was leading to night bradycardia (HR 35/min). In addition 3 pauses (the longest of 2.5 s) was seen. No complex ventricular arrhythmia was observed. On echocardiography borderline enlargement of the left atrium was found (4.3 cm), slightly impaired diastolic function and decreased EF (45%). NTproBNP was 40.3 pg/mL. At that time the patient I:1 had been implanted with a pacemaker DDD type. The proband's father (I:2) was healthy. The proband's sister (II:3) was weaker and less clever than peers. She had scoliosis. She was not able to walk on heels. Since childhood cervical spine rigidity and trace elbow contractures were noted. No muscle

weakness/wasting were seen. The patient reported palpitation after greater physical efforts. 24-hour ECG monitoring revealed night bradycardia of 35/min, with PQ 200 ms – borderline for AVB I. Echocardiography was normal, with good systolic (EF 64%) and diastolic function of the left ventricle. Her first pregnancy was ended with spontaneous miscarriage in the 6th week. She has two children: 6-years old son (III:2), clinically healthy and 3-years old (III:3) son with trisomy 21. Family history revealed that the second twin woman (II:5) is less agile than her sister (II:3). Since childhood cervical spine rigidity, lumbar hyperlordosis, elbow contractures and weakness of proximal muscles of the legs were seen. Periodically she reports pain and stinging sensation in the chest or cardiac disease. 24-hour ECG monitoring revealed AVB I. Echocardiography was normal, with good systolic function (EF 60%). She has two daughters, the older one (III:4) is overweighted and less agile than peers, the younger one (III:5) at presentation has not presented any symptoms of skeletal muscle disease. The proband's brother (II:7) is slim, at school he was less physically fit than peers. He easily gets tired. He is not able to walk on heels. He has thoracic scoliosis, cervical spine rigidity and slight elbow contractures. No muscle weakness was seen. Periodically palpitations and postural hypotonia occur. No conduction defect has been found until now, but echocardiography revealed slightly decreased EF (50%). Summary of the neurological and cardiological evaluation is shown in Tables 1 and 2.

Since the disease affected both men and women from two consecutive generations (Fig. 1), we suspected muscular dystrophy with cardiac involvement with autosomal dominant trait of inheritance. There are presumptions indicating EDMD2, associated with laminopathy: neurological presentation with dominating spine rigidity and joint contractures, discrete and variable weakness of different muscle groups and type of cardiac dysfunction in the proband, who had atrioventricular block type II requiring pacemaker implantation. Once written informed consents had been acquired, we performed genetic analysis in the proband, his parents, siblings and siblings' children. Genomic DNA was extracted from peripheral blood lymphocytes. All 12 exons of LMNA and exon-intron boundaries were amplified by PCR, sequenced using the Big Dye Terminator Sequencing Ready Reaction kit

(Applied Biosystems), and analyzed on an ABI PRISM 373 fluorescent DNA sequencer (Applied Biosystems). Primer sequences and PCR protocols are available upon request. Molecular testing revealed a heterozygous missense mutation c.1355T>C, p.Val452Ala in exon 7 of LMNA gene, encoding lamin A/C in several members of this family (Fig. 1): in the proband, his mother, 4 siblings from the generation II and in 4 of 5 children from the generation III. The mutation was not found in 110 control chromosomes. The family was included to regular cardiological supervision. Genetic counseling was provided.

2.2. Family 2

57-years old female was referred to neuromuscular consultation by a cardiologist. At the age of 47 the patient had been implanted pacemaker because of atrioventricular block III grade; at the age of 57 it was replaced by ICD (implantable cardioverter-defibrillator) due to deterioration of her cardiac function (EF 15%). She underwent diagnostics because of clinical signs of mild myopathy, but without definite molecular diagnosis. On physical examination there was found decreased strength of quadriceps muscles, which resulted in problems with climbing stairs and standing from squatting position. Also, she could not stand on her heels. No muscle wasting, no elbow contractures were seen. EMG revealed myopathic pattern in m.biceps brachii. She also complained of the spine stiffness, however MRI revealed osteoarthritis, so this symptom could not be surely the attribute of any underlying muscle disease. Clinical presentation in this patient might be consistent with quadriceps myopathy or mild limb-girdle muscular dystrophy (LGMD). Survey of the family history revealed sudden cardiac deaths in young and middle-aged members of this three generations family (Fig. 2). Heart failure with conduction defect and mild skeletal muscle disease directed the molecular diagnostics to laminopathies. Molecular testing revealed the recurrent heterozygous missense mutation c.1130G>T, p.Arg377Leu in exon 6 of LMNA gene. The only family members available for physical examination and genetic testing were two adult sons of the proband, but fortunately both they are free of the LMNA mutation detected in their mother.

Table 1 – Neurological characteristics of the patients from Families 1, 2 and 3.

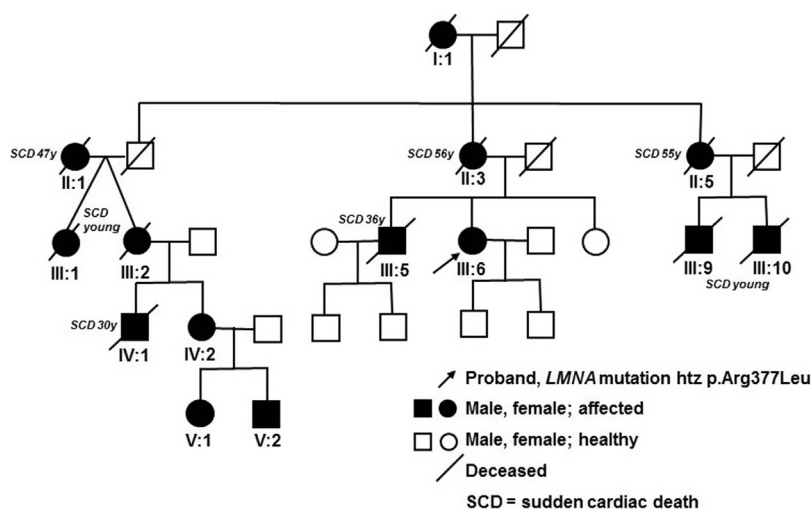
	Muscle weakness/ wasting		Reflexes			Contractures		Cervical spine rigidity	Lumbar hyperlordosis	
	mm. quadriceps	mm. biceps	mm. biceps	Radial bone	Knee	Ankle	Elbow			Ankle
Family 1										
I:1	Yes/no	No/no	+	–	+	–	No	Trace	Yes	Yes
II:2	Yes/no	No/yes	+	+	+	+	Yes	Trace	Yes	Yes
II:3	No/no	No/no	–	+	+	+	Yes	Trace	Yes	Yes
II:5	Yes/no	No/yes					Yes	Trace	Yes	Yes
II:7	No/yes	No/yes	+	–	–	+	Yes	Trace	Yes	Yes
Family 2										
III:6	Yes/no	Yes/no	–	–	–	–	No	No	Yes	No
Family 3										
Proband	Yes/yes	Yes/yes	+	+	–	L/P +/-	Trace	Yes	Yes	Yes

Table 2 – Cardiological characteristics of the patients from Families 1, 2 and 3.

	LA (cm)	LVDD (cm)	LVDS (cm)	LVEF (%)	Contractility	Arrhythmia	Cardiac device
Family 1							
I:1	4.2	4.2	2	60	Normal	Sporadic SVB, VB AVBII Wenckebach, bradycardia 21/min	Pacemaker DDD (52 y)
II:2	4.3	5.1	3.3	45	General hypokinesia of the left ventricle	AVBII 2:1, VB	Pacemaker DDD (31 y)
Proband II:3	3.2	4.5	2.7	64	Normal	Night bradycardia 35/min, PQ 200ms	No
II:5	3.6	4.4	2.8	60	Normal	AVBI	No
II:7	2.9	4.0	2.5	50	Normal	no	No
Family 2							
III:6 Proband	3.5	5.1	nd	15%	Impaired	AVBIII	Pacemaker (47 y) ICD (57 y)
Family 3							
Proband	4.5	5.8	4.6	45% then 15%	Hypokinesia of IVS and anterior wall of LV	AVBI/II Mobitz 2:1/Wenckebach, bradycardia 26/min, AF, AVBIII, sVT	Pacemaker VVI (44 y) ICD (46 y) CRT-D (48 y)

Normal ranges: LA (left atrium): 1.9–4.0 cm; LVDD (left ventricle end-diastolic diameter): 3.5–5.6 cm; LVDS (left ventricle end-systolic diameter): 2.2–3.8 cm; LVEF (left ventricle ejection fraction): $\geq 55\%$.

SVB – supraventricular beats; VB – ventricular beats; AVB – atrioventricular block; AF – atrial fibrillation; sVT – sustained ventricular tachycardia; IVS – interventricular septum.

**Fig. 2 – Pedigree of the Family 2. Note family members who died suddenly at young age.**

2.3. Family 3

46-years old male with implanted with CRT-D (Cardiac Resynchronization Therapy Implantable Cardioverter Defibrillator) because of recurrent ventricular tachycardia (VT) with high-energy intracardiac shocks and a very low EF (15%). Other echocardiographic parameters were: LA – 4.5 cm; LVDD – 5.8 cm; LVDS – 4.6 cm. Two years earlier he had been implanted with cardioverter defibrillator (ICD-VR) because of sustained VT; 4 years earlier he had been implanted with pacemaker VVI due to atrial fibrillation with AVB III; at that

time contractility of the left ventricle has been already impaired, with EF of 45–50%. Asymptomatic AVB I/II Mobitz 2:1/Wenckebach, had been observed since the age of 25. The patient was referred to neuromuscular consultation by a cardiologist, however since childhood non-progressing mild Achilles tendon and elbow contractures, slight spine rigidity together with wasting and weakness of the proximal muscles have been found. CK was 283 U/L. On electromyography myogenic pattern was seen in m. deltoideus, m. vastus lateralis and m. tibialis anterior. The clinical presentation was the most likely consistent with EDMD2, however a clinical

diagnosis has been established relatively late, after considering characteristic skeletal and cardiac muscle symptoms. Family history was negative, so it did not provide any suggestion on a potential trait of inheritance, but life-threatening arrhythmia indicated with greater probability of laminopathy than emerinopathy. In fact, molecular testing revealed the recurrent heterozygous missense mutation c.1357C>T (p.Arg453Trp) in exon 7 of *LMNA* gene.

3. Discussion

Laminopathies are rarely inherited diseases associated with structural/functional defect of genes that encode the nuclear envelope proteins. One of the best known one is lamin A/C, the main component of nuclear lamina, which is encoded by *LMNA* gene, located on chromosome 1 and translated on two proteins, being splice variants – lamin A and lamin C. Mutations in *LMNA* gene cause a wide spectrum of diseases that affect tissues of mesenchymal origin [12]. Muscle laminopathies create so-called organ-specific subgroups, which include several phenotypes of various onset and severity, from the most severe *LMNA*-related congenital muscular dystrophy (L-CMD) [13] in children, EDMD [2,3], LGMD1B [14], and isolated dilated cardiomyopathy with conduction defects (CMD1A) [15]. This report presents patients with discrete skeletal muscle disease associated with *LMNA*-dependent phenotypes consistent with EDMD2, LGMD1B and quadriceps myopathy, respectively.

EDMD is clinically characterized by humero-peroneal muscle atrophy and weakness, multijoint contractures with spine rigidity and cardiac insufficiency with conduction defects in later decades of life [16,17]. Great intrafamilial and interfamilial variability of clinical course of EDMD is seen [18]. There are two main types of EDMD: EDMD1 associated with mutations in *EMD* gene, encoding emerin, with X-linked recessive inheritance [2] and EDMD2 associated with mutations in *LMNA* gene, encoding lamin A/C, with autosomal dominant inheritance [3].

When analyzing disease symptomatology in the Family 1, we could note that in proband and his siblings the clinical picture is consistent with EDMD2, while in their mother – with quadriceps myopathy, although clinical course seems to be mild. Weakness of mm. quadriceps was seen exclusively in proband (II:2) and his mother (I:1). Contrary to the children (II:2, II:3, II:5, II:7) their mother (I:1) did not have elbow contractures. All affected patients had cervical spine rigidity, lumbar hyperlordosis and trace Achilles tendon contractures. Sequence and severity of cardiological and skeletal muscle symptoms might vary individually. Therefore observation toward discrete muscle symptoms could be of great importance to find etiology of severe heart disease in young patients with idiopathic cardiomyopathy, paroxysmal arrhythmia (supraventricular tachycardia, atrial flutter/fibrillation), atrio-ventricular block, sick sinus syndrome, especially when sudden cardiac deaths/heart disease/skeletal muscle disease were identified in family history. Conduction defects, which required cardiological procedure (pacemaker implantation) has been diagnosed so far in two members of the Family 1: proband (II:2) and his mother (I:1). Although slight proximal

muscle weakness in proband was present before asymptomatic arrhythmia, initially no neurological diagnostics was initiated. Correlation of cardiac failure and/or arrhythmia and discrete skeletal muscle symptoms helped to direct of diagnostics toward genetic disease. Confirmation of laminopathy in proband initiated molecular testing in other members of his family, who presented similar slight muscle and joint symptoms: elbow contractures, cervical spine rigidity and hyperlordosis.

The proband's mother has been implanted with pacemaker after confirmation of the atrio-ventricular block II and decreased ejection fraction (45%). It has been suggested that implantation of a pacemaker could not be sufficient to prevent sudden cardiac death in some patients with laminopathy, namely with non-sustained ventricular tachycardia, left ventricle EF < 45%, male sex and non-missense mutation in *LMNA* gene [19]. As one of the four risk factors listed above is present in the patient I:1, i.e. borderline EF, she requires re-evaluation toward qualification to implantable cardioverter-defibrillator. In case of the female from Family 2 the main reason to replace pacemaker with ICD was gradual deterioration of cardiac function, with decrease of EF to 15%. The patient from Family 3 had three of four risk factors of SCD in laminopathy, listed in the paper of van Rijsingen et al. [19] i.e. VT, male sex and EF < 45%, finally he required implantation of CRT-D. Although until now no cardiac arrhythmia requiring electrotherapy has been found in the siblings of the proband from Family 1 (i.e. II:3, II:5, II:7), they require annual follow-up, which should include physical examination, ECG, Holter monitoring and echocardiography, which is recommended not only in all carriers of *LMNA* mutation, but in all patients with muscular dystrophies, even asymptomatic and with normal ECG [20,21].

In addition to cardiac failure, requiring implantation of cardioverter-defibrillator in primary prevention of SCD, the proband from the Family 2 presented also signs that might correspond to quadriceps myopathy or mild LGMD, but without previous definite diagnosis, despite some attempts. Positive family history toward SCD in numerous young and middle-aged members of consecutive generations in this family, which indicated autosomal-dominant trait of inheritance, allowed to direct the diagnostics to laminopathies. In fact, the recurrent mutation in *LMNA* gene: c.1130G>T (p.Arg377Leu) was detected; it had been previously described in patients with EDMD2 [22], LGMD1B [23], DCM-CD [24], quadriceps myopathy with DCM-CD [9] and EDMD2 with peripheral neuropathy [25].

Phenotype of the patient from the Family 3 was consistent with EDMD2, but non-progressing muscle weakness and mild joint contractures with quite good physical ability prevented him to seek neurological diagnosis at younger age. Severe cardiological involvement which occurred in his fifth decade of life, in association with skeletal muscle symptoms, directed diagnostic pathway to inherited disease and it was the cardiologist who was the first specialist referring this patient to neuromuscular center. The disease-causing mutation in exon 7 of *LMNA* gene, i.e. c.1357C>T (p.Arg453Trp), has been reported in other EDMD2 patients, also of Polish origin [26,27].

Discrete muscular symptoms and signs observed in all patients with laminopathy presented above were the main

cause of somewhat late decision for referring them to neurological and genetic consultations. It was a cardiac disease which trigger diagnostics toward neuromuscular disease, mainly due to high awareness of cardiologists, who were the first specialists asked for consultation. It should also be stressed that laminopathies may manifest as isolated cardiac disease (DCM-CD) and the later muscle symptoms appear, the less severe and easier to overlooked they might be. Patients are often well-adapted to them, so they do not seek medical attention. Only serious cardiac disease or sudden cardiac deaths in family raise the significance of genetic diagnosis and proper counseling. LMNA gene mutations are characterized by almost full penetration as for heart disease in adulthood and constitute a real threat to life if left undiagnosed and untreated. Establishing diagnosis of laminopathy may be crucial since these patients may require implantation of the ICD instead of the classic pacemaker due to significantly higher risk of sudden death spawned by ventricular tachyarrhythmia which is not preventable by pacemaker itself. The 57 years old female patient from the family 2 might be a good example of this strategy.

Finally, discrete muscle symptoms should not be underestimated. Carefully collected history, physical examination, diagnostic procedures would help in shaping so as not to overlook the systemic disease. Patients and carriers with subtle skeletal muscle symptoms/signs are to be routinely sent to cardiologists for early recognition and treatment of cardiomyopathy and/or life-threatening arrhythmias. Currently, screening for cardiac should be offered to all patients suspected/diagnosed with muscular dystrophy or myopathy [21]. Identification of all patients in the family presenting subclinical symptoms of muscle disease and determination of proper diagnosis might help establishing therapeutic approach, as well as genetic and career counseling.

Conflict of interest

None declared.

Author's contributions

Study concept and design: AMP. Clinical assessment and data collection: AMP, MM, KO, JC, RS. Molecular analysis: AMP, KO. Data analysis and interpretation: AMP, MM, KO, JC, RS. Manuscript preparation: AMP, MM, KO.

Acknowledgement and financial support

This study was supported by a grant from the Polish National Science Centre No. 2015/17/B/NZ5/01368.

Ethics

All procedures were conducted in accordance with the standards of the bioethical committee and the Declaration of Helsinki.

REFERENCES

- [1] Verhaert D, Richards K, Rafael-Fortney JA, Raman SV. Cardiac involvement in patients with muscular dystrophies: magnetic resonance imaging phenotype and genotypic considerations. *Circ Cardiovasc Imaging* 2011; 4(1):67–76.
- [2] Bione S, Maestrini E, Rivella S, Mancini M, Regis S, Romeo G, et al. Identification of a novel X-linked gene responsible for Emery-Dreifuss muscular dystrophy. *Nat Genet* 1994; 8(4):323–7.
- [3] Bonne G, Di Barletta MR, Varnous S, Becane HM, Hammouda EH, Merlini L, et al. Mutations in the gene encoding lamin A/C cause autosomal dominant Emery-Dreifuss muscular dystrophy. *Nat Genet* 1999; 21(3):285–8.
- [4] Finsterer J, Stöllberger C. The heart in human dystrophinopathies. *Cardiology* 2003;99(1):1–19.
- [5] Russell MW, Townsend D, Metzger JM. Cardiac involvement in the dystrophinopathies. *J Pediatr Rehabil Med* 2008;1(3):211–23.
- [6] Semplicini C, Vissing J, Dahlqvist JR, Stojkovic T, Bello L, Witting N, et al. Clinical and genetic spectrum in limb-girdle muscular dystrophy type 2E. *Neurology* 2015; 84(Apr (17)):1772–81.
- [7] Fayssol A, Ognia A, Chaffaut C, Chevret S, Guimarães-Costa R, Leturcq F, et al. Natural history of cardiac and respiratory involvement, prognosis and predictive factors for long-term survival in adult patients with limb girdle muscular dystrophies type 2C and 2D. *PLOS ONE* 2016; 11(4):e0153095.
- [8] Bienias P, Łusakowska A, Ciurzyński M, Rymarczyk Z, Irzyk K, Kurnicka K, et al. Supraventricular and ventricular arrhythmias are related to the type of myotonic dystrophy but not to disease duration or neurological status. *Pacing Clin Electrophysiol* 2016;39(9):959–68.
- [9] Finsterer J, Stöllberger C. Review of cardiac disease in nemaline myopathy. *Pediatr Neurol* 2015;53(6):473–7.
- [10] Goldfarb LG, Olivé M, Vicart P, Goebel HH. Intermediate filament diseases: desminopathy. *Adv Exp Med Biol* 2008;642:131–64.
- [11] Boucek D, Jirikowic J, Taylor M. Natural history of Danon disease. *Genet Med* 2011;13(6):563–8.
- [12] Worman HJ, Bonne G. “Laminopathies”: a wide spectrum of human diseases. *Exp Cell Res* 2007;313(10):2121–33.
- [13] Quijano-Roy S, Mbieleu B, Bönnemann CG, Jeannot PY, Colomer J, Clarke NF, et al. De novo LMNA mutations cause a new form of congenital muscular dystrophy. *Ann Neurol* 2008;64(2):177–86.
- [14] Muchir A, Bonne G, van der Kooij AJ, van Meegen M, Baas F, Bolhuis PA, et al. Identification of mutations in the gene encoding lamins A/C in autosomal dominant limb girdle muscular dystrophy with atrioventricular conduction disturbances (LGMD1B). *Hum Mol Genet* 2000;9:1453–9.
- [15] Fatkin D, MacRae C, Sasaki T, Wolff MR, Porcu M, Frenneaux M, et al. Missense mutations in the rod domain of the lamin A/C gene as causes of dilated cardiomyopathy and conduction-system disease. *N Engl J Med* 1999;341:1715–24.
- [16] Maggi L, Carboni N, Bernasconi P. Skeletal muscle laminopathies: a review of clinical and molecular features. *Cells* 2016;5(3). pii: E33.
- [17] Bonne G, Quijano-Roy S. Emery-Dreifuss muscular dystrophy, laminopathies, and other nuclear envelopopathies. *Handb Clin Neurol* 2013;113:1367–76.
- [18] Rankin J, Auer-Grumbach M, Bagg W, Colclough K, Nguyen TD, Fenton-May J, et al. Extreme phenotypic diversity and

- nonpenetrance in families with the LMNA gene mutation R644C. *Am J Med Genet A* 2008;146A(12):1530-42.
- [19] van Rijsingen IA, Arbustini E, Elliott PM, Mogensen J, Hermans-van Ast JF, van der Kooij AJ, et al. Risk factors for malignant ventricular arrhythmias in lamin A/C mutation carriers a European cohort study. *J Am Coll Cardiol* 2012;59(5):493-500.
- [20] Priori SG, Blomström-Lundqvist C, Mazzanti A, Blom N, Borggrefe M, Camm J, et al. 2015 ESC Guidelines for the management of patients with ventricular arrhythmias and the prevention of sudden cardiac death: The Task Force for the Management of Patients with Ventricular Arrhythmias and the Prevention of Sudden Cardiac Death of the European Society of Cardiology (ESC). Endorsed by: Association for European Paediatric and Congenital Cardiology (AEPC). *Eur Heart J* 2015;36(41):2793-867.
- [21] Hermans MC, Pinto YM, Merkies IS, de Die-Smulders CE, Crijns HJ, Faber CG. Hereditary muscular dystrophies and the heart. *Neuromuscul Disord* 2010;20(8):479-92.
- [22] van Tintelen JP, Hofstra RM, Katerberg H, Rossenbacker T, Wiesfeld AC, du Marchie Sarvaas GJ, et al. High yield of LMNA mutations in patients with dilated cardiomyopathy and/or conduction disease referred to cardiogenetics outpatient clinics. *Am Heart J* 2007;154:1130-9.
- [23] Perrot A, Sigusch HH, Nägele H, Genschel J, Lehmkuhl H, Hetzer R, et al. Genetic and phenotypic analysis of dilated cardiomyopathy with conduction system disease: demand for strategies in the management of presymptomatic lamin A/C mutant carriers. *Eur J Heart Fail* 2006;8:484-93.
- [24] Charniot JC, Desnos M, Zerhouni K, Bonnefont-Rousselot D, Albertini JP, Salama JZ, et al. Severe dilated cardiomyopathy and quadriceps myopathy due to lamin A/C gene mutation: a phenotypic study. *Eur J Heart Fail* 2006;8:249-56.
- [25] Madej-Pilarczyk A, Kotruchow K, Kabzińska D, Cegielska J, Kocharński A, Hausmanowa-Petrusewicz I. Emery-Dreifuss muscular dystrophy type 2 associated (?) with mild peripheral polyneuropathy. *Folia Neuropathol* 2015; 53(3):270-4.
- [26] Niebroj-Dobosz I, Madej-Pilarczyk A, Marchel M, Sokołowska B, Hausmanowa-Petrusewicz I. Circulating tenascin-C levels in patients with dilated cardiomyopathy in the course of Emery-Dreifuss muscular dystrophy. *Clin Chim Acta* 2011;412(17-18):1533-8.
- [27] Hausmanowa-Petrusewicz I, Madej-Pilarczyk A, Marchel M, Opolski G. Emery-Dreifuss dystrophy: a 4-year follow-up on a laminopathy of special interest. *Neurol Neurochir Pol* 2009;43(5):415-20.