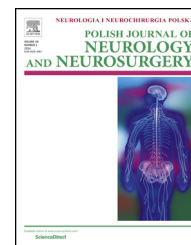


Available online at [www.sciencedirect.com](http://www.sciencedirect.com)

ScienceDirect

journal homepage: <http://www.elsevier.com/locate/pjnns>

## Original research article

## Efficacy of endoscopic third ventriculostomy in old aged patients with normal pressure hydrocephalus

Young Sill Kang<sup>a,b,1</sup>, Eun-Kyung Park<sup>c,1</sup>, Ju-Seong Kim<sup>c</sup>, Dong-Seok Kim<sup>c</sup>, Ulrich-Wilhelm Thomale<sup>b</sup>, Kyu-Won Shim<sup>c,\*</sup><sup>a</sup> Department of Neurosurgery, Universitätsmedizin, Mainz, Germany<sup>b</sup> Division of Pediatric Neurosurgery, Charité Universitätsmedizin, Berlin, Germany<sup>c</sup> Pediatric Neurosurgery, Severance Children's Hospital, Yonsei University College of Medicine, Seoul, Republic of Korea

## ARTICLE INFO

## Article history:

Received 21 March 2017

Accepted 13 October 2017

Available online 23 October 2017

## Keywords:

Normal pressure hydrocephalus

Endoscopic third ventriculostomy (ETV)

Aqueductal peak velocity

## ABSTRACT

Normal pressure hydrocephalus (NPH) is a chronic disorder caused by interrupted CSF absorption or flow. Generally, shunt placement is first option for NPH treatment. Due to complications of ventriculo-peritoneal (VP) shunt placement, endoscopic third ventriculostomy (ETV) can be considered as an alternative treatment option. Here we report the efficacy of ETV especially in old aged patients with normal pressure hydrocephalus.

Total 21 old aged patients with communicating hydrocephalus with opening pressure, measured via lumbar puncture, less than 20 cm H<sub>2</sub>O underwent ETV. 15 patients had primary/idiopathic NPH and 6 patients had secondary NPH. All patients were studied with a MRI to observe the flow void at aqueduct and the fourth ventricle outflow. And all of them underwent ETV. In a group with peak velocity was higher than 5 cm/s, nine patients (75%) were evaluated as 'favorable' and three of them (25%) was scored 'poor'. In another group with peak velocity less than 5 cm/s, three of them were scored 'poor' and two of them were scored 'stable'. None of them was evaluated as 'favorable'. We also evaluated the outcomes according to etiology: 12 patients (80% of the patients with primary NPH) were evaluated with 'favorable' after ETV treatment. Two patients (13.3%) were as 'stable'. And one patient was as 'poor' evaluated. Five patients (83.3%) among patients with secondary NPH were as 'poor' evaluated and one of them was stable and no patient was as 'favorable' evaluated. 4 patients, which was as 'poor' evaluated in the group with the secondary NPH, underwent additional VP shunt implantation. Overall, the outcomes of the group with the idiopathic NPH after ETV treatment were more favorable than of the group with the secondary NPH.

Our study suggest that ETV can be effective for selected elderly patients with primary/idiopathic NPH, when they satisfy criteria including positive aqueduct flow void on T2 Sagittal MRI and the aqueductal peak velocity, which is greater than 5 cm/s on cine MRI.

© 2017 Published by Elsevier Sp. z o.o. on behalf of Polish Neurological Society.

\* Corresponding author at: Pediatric Neurosurgery, Severance Children's Hospital, Department of Neurosurgery, Yonsei University College of Medicine, Seoul, Republic of Korea.

E-mail address: [shimkyuwon@yuhs.ac](mailto:shimkyuwon@yuhs.ac) (K.-W. Shim).<sup>1</sup> These authors contributed equally.

Abbreviations: NPH, normal pressure hydrocephalus; iNPH, idiopathic normal pressure hydrocephalus; sNPH, secondary normal pressure hydrocephalus; VP shunt, ventriculo-peritoneal shunt; CSF, cerebrospinal fluid.

<https://doi.org/10.1016/j.pjnns.2017.10.004>

0028-3843/© 2017 Published by Elsevier Sp. z o.o. on behalf of Polish Neurological Society.

---

## 1. Introduction

NPH is a chronic disorder, which is caused by impaired CSF circulation. Hydrocephalus can be subdivided into communicating and non-communicating 'obstructive' hydrocephalus. The normal pressure hydrocephalus belongs to the communicating form in that the cause of CSF circulation is low brain compliance. The exact pathogenesis of normal pressure hydrocephalus has not been elucidated. NPH was first described by Hakim and Adams in 1965 [1,2]. It is characterized by the clinical triad of gait disturbance, dementia, and urinary incontinence [3,4]. The gait disturbance, which represents with a combination of motor deficits, failure of postural righting reflexes, abnormal smooth pursuit, and failed suppression of vestibuloocular reflexes [5,6] is usually the first symptom of normal pressure hydrocephalus to appear, followed by dementia and last by urinary incontinence [7]. Generally, VP shunt placement is considered as first option for NPH treatment. However, several complications, including shunt infection, over drainage and malfunction including obstruction [8-13] limit its application for treating NPH. Some studies report an overall shunt failure rate as high as 59%, with the majority of failures, occurring within the first 6 months after shunt placement [14]. Due to such complications, endoscopic third ventriculostomy (ETV) has emerged as a surgical intervention to treat hydrocephalus, as an alternative to shunt implantation. ETV has become as one of ideal treatment options generally for the most forms of obstructive hydrocephalus. In the last decade ETV has been proposed as an alternative surgical intervention for treating iNPH. However, debate over VP shunt implantation versus ETV for the treatment is still ongoing. Although reported therapeutic efficacy of ETV over shunt implantation reported in some studies [15,16], Chan et al. reported high complication rate associated with ETV intervention [17]. However, therapeutic effect without implanting any foreign material renders this method preferable to VP shunting for a large ETV population. Several studies reporting the efficacy of the ETV predominantly include the pediatric patient group [18-21] or combined pediatric and adult populations [22-27]. To our knowledge, there is no study, suggesting selecting criteria for ETV especially in old aged patients with normal pressure hydrocephalus. In this present study, we report on the follow up of ETV in a series of 21 patients (mean 70 years old) with normal pressure hydrocephalus and suggest patients selecting criteria for successful ETV intervention.

---

## 2. Materials and methods

In our present study, clinical data of 21 patients diagnosed with normal pressure hydrocephalus, who chose the endoscopic third ventriculostomy from January 2013 to January 2014 were reviewed (Table 1a). Patients were fully informed about their treatment options including surgical procedures, anticipated results, complications and anticipated benefits. The patients fulfilled following diagnostic criteria (Table 1b): (1) older than sixty years of age – age ranged from 60 to 82 years old (mean 70 years old). (2) Communicating hydrocephalus (flow void was observed at aqueduct and 4th ventricle outflow

on cine MRI). (3) Positive results of CSF tap test. (4) Opening pressure less than 20 cm H<sub>2</sub>O. 15 patients among them had iNPH and rest of them had sNPH. Causes for sNPH include cerebral infarction and cerebral hemorrhagic contusion.

All 21 patients presented with gait ataxia. 48% of them have urinary incontinence and 57% of them had memory deficiency. 63.6% of patients had more than two symptoms of NPH triad. Preoperatively all patients were studied with MRI to observe the flow void at aqueduct and the fourth ventricle outflow. All patients underwent ETV. The follow up period ranged from 1 month to 12 months (mean 6.4 months). Based on etiology, we separated the patients into two groups. The first group included 15 patients with iNPH, defined as primary communicating hydrocephalus. The second group included 6 patients with sNPH. Evaluation of the efficacy of ETV based on the postoperative patients' status was performed comprehensively by physician. It was evaluated as 'preferable' when the comprehensive postoperative status of patients indicates improvement. If there were no big differences between pre- and postoperative but only with a bit of improvement, we evaluated as 'stable'. When there was no improvement or worsening symptoms, we evaluated it as 'poor'. 'expire' was categorized as 'poor'.

---

## 3. OP procedure: endoscopic third ventriculostomy

Endoscopic third ventriculostomy was performed using rigid neuro-endoscope consisted of a 30-degree Hopkins pediatric telescope (Karl Storz, Tuttlingen, Germany) with an outside diameter of 2.7 mm, a sheath for the telescope with an outside diameter of 3.8 mm, and a stylet. For perforating the third ventricle floor, a monopolar-coagulating electrode was applied. This operation was performed under general anesthesia. The patient was positioned supine, and routine skin preparation and draping were performed. A burr hole was placed at Kocher's point. The right lateral ventricle was tapped using a ventricular catheter through the burr hole, and peel-away catheter was placed via a tract. The tip of a tapping catheter was directed to the glabella and tragus of the right ear. A telescope with sheath was advanced into the lateral ventricle through the peel-away catheter. Foramen of Monro was identified, and the telescope could be advanced through the foramen of Monro to visualize the floor of the third ventricle. The site for a third ventriculostomy was located halfway along the midline between the infundibular recess and the mammillary body. For penetration of the third ventricular floor, the coagulating electrode or forceps was advanced via a working channel in the sheath and electric coagulation with the monopolar electrode was used. As the third ventricular floor was perforated, a flow of CSF was seen. The hole could be enlarged with the insertion of the telescope or balloon dilator if needed. The telescope and its sheath were removed and the cortical incision was packed with a piece of gel-foam and sealed with fibrin glue.

---

## 4. Results

Peak CSF flow velocity at cerebral aqueduct on cine MR was measured from 17 patients pre-operatively (Table 2). 4 Rest

**Table 1a – Clinical features of preoperative patients.**

No.	Age	Sex	Gate disorder	Urinary incontinuity	Memory deficiency
1	72	M	y	y	y
2	73	F	y	y	y
3	82	M	y	y	y
4	66	M	y	n	n
5	65	F	y	n	n
6	67	F	y	y	y
7	75	M	y	n	n
8	61	F	y	y	n
9	80	F	y	n	n
10	76	M	y	n	y
11	72	M	y	n	n
12	72	M	y	n	n
13	60	F	y	y	n
14	60	F	y	y	y
15	73	M	y	n	y
16	73	M	y	n	y
17	75	M	y	n	n
18	63	M	y	n	y
19	72	F	y	y	y
20	72	M	y	y	y
21	65	F	y	y	y

**Table 1b – CSF flow on MR imaging before the ETV and outcomes.**

No.	Pre	Intervention		Post	Intervention	
	Opening pressure	Peak velocity	Flow void on stoma	Immediate outcome	Follow-up outcome	VP shunt after ETV
1	9	14.7	y	Favorable	Favorable	n
2	11	–	y	Favorable	Poor (expired)	n
3	11	–	y	Favorable	Favorable	n
4	14	7.54	y	Favorable	Poor	y
5	6.5	22.3	y	Favorable	Favorable	n
6	7	9.98	n	Favorable	Favorable	n
7	16	11.6	y	Favorable	Favorable	n
8	16	8.25	y	Favorable	Poor	y
9	9	–	y	Favorable	Stable	n
10	9	2.18	y	Favorable	Poor	y
11	9.5	7.73	y	Favorable	Favorable	n
12	10	14.4	y	Stable	Favorable	n
13	10	–	y	Favorable	Favorable	n
14	5	10.1	y	Favorable	Favorable	n
15	10	7.55	y	Favorable	Favorable	n
16	5	3.42	y	Poor	Poor	n
17	5	9.85	n	Favorable	Poor	n
18	3	9.02	y	Favorable	Favorable	n
19	8	1.19	y	Favorable	Stable	n
20	6	1.66	y	Poor	Poor	y
21	13	2.92	y	Favorable	Stable	n

patients of all 21 patients were excluded because preoperative cine MR was not performed on them.

In a group with peak velocity of higher than 5 cm/s, nine patients of them (75%) were evaluated as 'preferable' and three of them (25%) were evaluated as 'poor'. In another group with peak velocity of less than 5 cm/s, three of them were evaluated as 'poor' and two of them as 'stable'. None of them was evaluated as 'preferable' ( $p < 0.008$ ).

All 21 patients were evaluated based on post-operative status. 15 patients of them were with iNPH and 6 of them had sNPH. Among patients with iNPH, 12 patients (80%) were

evaluated with 'preferable'. Two patients (13.3%) were evaluated as 'stable'. And one patient was as 'poor' evaluated. Five patients (83.3%) among patients with sNPH were evaluated as 'poor' (Table 3). None of them in the group with sNPH was evaluated as 'preferable'. 4 patients in this group of sNPH had to undergo additional VP shunt (ProGAV) implantation. One of these patients who underwent VP shunt insertion, had shunt complication due to recurrent chronic subdural hemorrhage caused by over-drainage. One patient, who underwent ETV, was expired within the follow up period due to sepsis following sore infection.

**Table 2 – Peak velocity of cine MR (performed before the ETV).**

Peak velocity	Poor	Stable	Preferable	Total
<5 cm/s	3 (60%)	2 (40%)	0 (0%)	5 (100%)
>5 cm/s	3 (25%)	0 (0%)	9 (75%)	12 (100%)
Total	6 (35.3%)	2 (11.8%)	9 (52.9%)	17 (100%)

**Table 3 – Primary NPH vs. secondary NPH.**

- Primary NPH (15 patients)
  - Good/Stable/Poor; 12(80%)/2(13.3%)/1(6.7%)
- Secondary NPH (6 patients)
  - Good/Stable/Poor; 0(0%)/1(16.7%)/5(83.3%)

## 5. Discussion

Generally, shunt implantation is considered as primary treatment option for hydrocephalus. However, since endoscopic technic was introduced, ETV has emerged as alternative therapeutic option to shunt implantation due to lack of complications associated with shunt infection, over drainage and malfunction of the shunt [28–30]. Risk of shunt malfunction is relatively high: 25–40% in the first year after shunt placement, 4–5% per year thereafter, and 81% of shunted patients require revision after 12 years, which demonstrates that shunt failure is almost inevitable during a patient's life [24,31]. So far, ETV has been employed mainly in patients with 'non-communicating' form of hydrocephalus [32]. In the last decade, ETV become considered as one of options for communicating hydrocephalus in context on retrieving CSF flow pathways.

According to Hakim et al. [33], brain parenchyma is spongy viscoelastic, so that CSF pressure can be distributed along the brain parenchyma. However, in NPH, compliance of artery is decreased and vascular resistance are increased, so that the increased pulsatile vascular expansion occurs [34]. As the CSF pressure exceeds the venous pressure, the ventricles become enlarged and the systolic pulsations continually damage the brain parenchyma [33,35]. This series of process decreases elasticity of the brain parenchyma. In case of iNPH, ETV may be able to cause a consequent increase in the systolic outflow from the ventricle and decrease in the intraventricular pulse pressure and width of the ventricle, so that overall intracranial compliance can be increased [36]. The transmission of the pressure wave through ETV toward the basal cistern may contribute to normalizing the CSF dynamics [35].

Underlying diseases, which may cause sNPH, include cerebral infarction, cerebral hemorrhage, and meningitis. In our study five out of six patients had cerebral infarction. In most cases of sNPH, arachnoid membrane is thick and adhesive. Due to this defect of arachnoid membrane, CSF flow can be disturbed. An experimental study demonstrated that impact of adhesions of the basal subarachnoid space is worse than an intraventricular obstruction [36]. Present study suggests that the transient increased site flow through a small perforation in the thinned floor of the third ventricle may not

improve the CSF dynamic in sNPH compared to the cases of iNPH. In most cases of sNPH, VP shunt placement was inevitable. The circulation of CSF is hampered in sNPH due to defect arachnoid membrane, so that local perforation via ETV may not enough to retrieve normal CSF circulation.

MR imaging is generally considered the best technique to evaluate intracranial CSF dynamic, partly because of its ability to image directly in the mid sagittal plane and partly due to the various pulse sequences available. Cine-phase contrast MRI is currently more used to evaluate pathophysiology of CSF dynamic in patients with hydrocephalus. With the increasing frequency of neuroendoscopic procedures including ETV, cine MR imaging has been applied for evaluating the patency of third ventriculostomy [37–40]. Several studies demonstrated that the low intracranial compliance is associated with NPH [41–44]. Lower aqueduct flow velocity can account for low brain compliance in communicating hydrocephalus. In our study, nine out of twelve patients, in whom the peak velocity was greater than 5 cm/s, experienced 'preferable' clinical outcome. When the peak velocity is low (less than 5 cm/s) on preoperative MR, ETV may not bring benefits. In these patients, the CSF dynamic may be not enough to squeeze the CSF through ETV stoma site. To have positive effect and avoid treatment failure through ETV, aqueduct peak velocity on cine MR should be greater than 5 cm/s on cine MRI.

Our present study comprises several limitations including the fact that the following period is relatively short (mean 6.4 months) so that complications, which can occur a year later, were not counted so that a longer follow up is desirable. The postoperative status of patients was comprehensively and subjectively evaluated by physicians based on postoperative clinical symptoms compared to the preoperative status of patients so that bias may have occurred while evaluating the result of the intervention. Small size of study group should be also as limitation noted. Further studies with large population and longer follow-up periods are mandatory to confirm the efficacy of the treatment with ETV. Our results are not sufficient to determine its superiority over shunting for NPH. However, when they are cautiously selected, ETV can be effective for therapy of NPH.

## 6. Conclusion

Our present study emphasize that patient selection is the key point for successful outcome in ETV. Our study suggests that ETV is effective for selected elderly patients with primary NPH. Criteria for ETV candidate in adult NPH patients may include positive aqueduct flow void on T2 Sagittal MRI and the aqueductal peak velocity should be greater 5 cm/s on cine MRI.

## Ethical approval

All procedures performed in studies involving human participants were in accordance with the ethical standards of the institutional and/or national research committee and with the 1964 Helsinki declaration and its later amendments or comparable ethical standards.

## Conflict of interest

None declared.

## Acknowledgement and financial support

None declared.

## REFERENCES

- [1] Hakim S, Adams R. The special clinical problem of symptomatic hydrocephalus with normal cerebrospinal fluid pressure. Observations on cerebrospinal fluid hydrodynamics. *J Neurosurg* 1965;2:307–27.
- [2] Adams R, Fisher C, Hakim S, Ojemann R, Sweet W. Symptomatic occult hydrocephalus with “normal” cerebrospinal fluid pressure: a treatable syndrome. *N Engl J Med* 1965;273:117–26.
- [3] Algin O, Hakyemez B, Taskapilioglu O, Ocakoglu G, Bekar A, Parlak M. Morphologic features and flow void phenomenon in normal pressure hydrocephalus and other dementias: are they really significant? *Acad Radiol* 2009;16:1373–80.
- [4] Pople I. Hydrocephalus and shunts: what the neurologist should know. *J Neurol Neurosurg Psychiatry* 2002;73(Suppl. 1):17–22.
- [5] Estanol B. Gait apraxia in communicating hydrocephalus. *J Neurol Neurosurg Psychiatry* 1981;44:305–8.
- [6] Corkill R, Cadoux-Hudson T. Normal pressure hydrocephalus: developments in determining surgical prognosis. *Curr Opin Neurobiol* 1999;12:671–7.
- [7] Graff-Radford N, Godersky J. Normal pressure hydrocephalus. Onset of gait abnormality before dementia predicts good surgical outcome. *Arch Neurol* 1986;43:940–2.
- [8] Drake J, Kestle J, Milner R, Cinalli G, Boop F, Piatt Jr J, et al. Randomized trial of cerebrospinal fluid shunt valve design in pediatric hydrocephalus. *Neurosurgery* 1998;43:294–305.
- [9] Hayden P, Shurtleff D, Stuntz T. A longitudinal study of shunt function in 360 patients with hydrocephalus. *Dev Med Child Neurol* 1983;25:334–7.
- [10] Hoppe-Hirsch E, Laroussinie F, Brunet L, Sainte-Rose C, Renier D, Cinalli G, et al. Late outcome of the surgical treatment of hydrocephalus. *Childs Nerv Syst* 2014;14:97–9.
- [11] Kestle J, Drake J, Milner R, Sainte-Rose C, Cinalli G, Boop F, et al. Long-term follow-up data from the shunt design trial. *Pediatr Neurosurg* 2000;33:230–6.
- [12] Keucher T, Mealey Jr J. Long-term results after ventriculoatrial and ventriculoperitoneal shunting for infantile hydrocephalus. *J Neurosurg* 1979;50:179–86.
- [13] Sainte-Rose C, Piatt J, Renier D, Pierre-Kahn A, Hirsch J, Hoffman H, et al. Mechanical complications in shunts. *Pediatr Neurosurg* 1991–1992;17:2–9.
- [14] Reddy G, Bollam P, Shi R, Guthikonda B, Nanda A. Management of adult hydrocephalus with ventriculoperitoneal shunts: long-term single-institution experience. *Neurosurgery* 2011;69:774–81.
- [15] Hailong F, Guangfu H, Haibin T, Hong P, Yong C, Weidong L, et al. Endoscopic third ventriculostomy in the management of communicating hydrocephalus: a preliminary study. *J Neurosurg* 2008;109:923–30.
- [16] Gangemi M, Maiuri F, Naddeo M. Endoscopic third ventriculostomy in idiopathic normal pressure hydrocephalus: an Italian multicenter study. *Neurosurgery* 2008;63:62–7.
- [17] Chan AK, McGovern RA, Zacharia BE, Mikell CB, Bruce SS, Sheehy JP, et al. Inferior short-term safety profile of endoscopic third ventriculostomy compared with ventriculoperitoneal shunt placement for idiopathic normal-pressure hydrocephalus: a population-based study. *Neurosurgery* 2013;73:951–60.
- [18] Beems T, Grotenhuis J. Is the success rate of endoscopic third ventriculostomy age-dependent? An analysis of the results of endoscopic third ventriculostomy in young children. *Childs Nerv Syst* 2002;18:605–8.
- [19] Beems T, Grotenhuis J. Long-term complications and definition of failure of neuroendoscopic procedures. *Childs Nerv Syst* 2004;20:868–77.
- [20] Cinalli G, Sainte-Rose C, Chumas P, Zerah M, Brunelle F, Lot G, et al. Failure of third ventriculostomy in the treatment of aqueductal stenosis in children. *Neurosurg Focus* 1999;6:e3.
- [21] Ray P, Jallo G, Kim R, Kim B, Wilson S, Kothbauer K, et al. Endoscopic third ventriculostomy for tumor-related hydrocephalus in a pediatric population. *Neurosurg Focus* 2005;19:E8.
- [22] Baldauf J, Fritsch M, Oertel J, Gaab M, Schroder H. Value of endoscopic third ventriculostomy instead of shunt revision. *Minim Invasive Neurosurg* 2010;53:159–63.
- [23] Fukuhara T, Vorster S, Luciano M. Risk factors for failure of endoscopic third ventriculostomy for obstructive hydrocephalus. *Neurosurgery* 2000;46:1100–9. discussion 9–11.
- [24] O'Brien D, Javadpour M, Collins D, Spennato P, Mallucci C. Endoscopic third ventriculostomy: an outcome analysis of primary cases and procedures performed after ventriculoperitoneal shunt malfunction. *J Neurosurg* 2005;103:393–400.
- [25] Rahme R, Rahme R, Hourani R, Moussa R, Nohra G, Okais N, et al. Endoscopic third ventriculostomy: the Lebanese experience. *Pediatr Neurosurg* 2009;45:361–7.
- [26] Sacko O, Boetto S, Lauwers-Cances V, Dupuy M, Roux F. Endoscopic third ventriculostomy: outcome analysis in 368 procedures. *J Neurosurg Pediatr* 2010;5:68–74.
- [27] Schroeder H, Niendorf W, Gaab M. Complications of endoscopic third ventriculostomy. *J Neurosurg* 2002;96:1032–40.
- [28] Piatt Jr JHC. A search for determinants of cerebrospinal fluid shunt survival: retrospective analysis of a 14-year institutional experience. *Pediatr Neurosurg* 1993;19:233–43.
- [29] Pudenz R, Foltz E. Hydrocephalus: overdrainage by ventricular shunts. A review and recommendation. *Surg Neurol* 1991;35:200–12.
- [30] Sehkar L, Moosy J, Guthkelch A. Malfunctioning ventriculoperitoneal shunts. Clinical and pathological features. *J Neurosurg* 1982;56:411–6.
- [31] Prusseit J, Simon M, von der Brölie C, Heep A, Molitor E, Volz S, et al. Epidemiology, prevention and management of ventriculoperitoneal shunt infections in children. *Pediatr Neurosurg* 2009;45:325–36.
- [32] Foster K, Deibert C, Choi P, Gardner P, Tyler-Kabara E, Engh J. Endoscopic third ventriculostomy as adjunctive therapy



- in the treatment of low-pressure hydrocephalus in adults. *Surg Neurol Int* 2016;7.
- [33] Hakim CA, Hakim R, Hakim S. Normal pressure hydrocephalus. *Neurosurg Clin N Am* 2001;12:761-73.
- [34] Greitz D, Hannerz J, Rahn T, Bolander H, Ericsson MR. Imaging of cerebrospinal fluid dynamics in health and disease. On the vascular pathogenesis of communicating hydrocephalus and benign intracranial hypertension. *Acta Radiol* 1994;35:204-11.
- [35] Gangemi M, Maiuri F, Buonamassa S, Colella G, de Divitiis E. Endoscopic third ventriculostomy in idiopathic normal pressure hydrocephalus. *Neurosurgery* 2004;55:129-34.
- [36] Heilong F, Guangfu H, Haibin T, Hong P, Yong C, Weidong L, et al. Endoscopic third ventriculostomy in the management of communicating hydrocephalus: a preliminary study. *J Neurosurg* 2008;109:923-30.
- [37] Kunz U, Goldmann A, Bader C, Waldbaur H, Oldenkott P. Endoscopic fenestration of the 3rd ventricular floor in aqueductal stenosis. *Minim Invasive Neurosurg* 1994;37:42-7.
- [38] Fischbein N, Ciricillo S, Barr R, McDermott M, Edwards M, Geary S, et al. Endoscopic third ventriculocisternostomy: MR assessment of patency with 2-D cine phase-contrast versus T2-weighted fast spin echo technique. *Pediatr Neurosurg* 1998;28:70-8.
- [39] Lev S, Bhadelia R, Estin D, Heilman C, Wolpert S. Functional analysis of third ventriculostomy patency with phase-contrast MRI velocity measurements. *Neuroradiology* 1997;39:1997.
- [40] Maeder P, Gudinchet F, Meuli R, Fankhauser H. Dynamic MRI of cerebrospinal fluid flow in endoscopic percutaneous ventriculostomy. *Br J Neurosurg* 1998;12:18-22.
- [41] Kim D, Choi J, Huh R, Yun P, Kim D. Quantitative assessment of cerebrospinal fluid hydrodynamics using a phase-contrast cine MR image in hydrocephalus. *Childs Nerv Syst* 1999;15:461-7.
- [42] Mase M, Yamada K, Banno T, Miyachi T, Ohara S, Matsumoto T. Quantitative analysis of CSF flow dynamics using MRI in normal pressure hydrocephalus. *Acta Neurochir (Wien)* 1998;71:350-3.
- [43] Matsumoto T, Nagai H, Kasuga Y, Kamiya K. Changes in intracranial pressure (ICP) pulse wave following hydrocephalus. *Acta Neurochir (Wien)* 1986;82:50-6.
- [44] Mase M, Miyati T, Yamada K, Kasal H, Hara M, Shibamoto Y. Non-invasive measurement of intracranial compliance using cine MRI in normal pressure hydrocephalus. *Acta Neurochir* 2005;95(Suppl.):303-6.