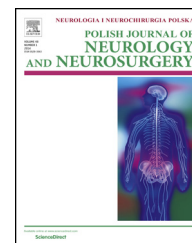


Available online at www.sciencedirect.com

ScienceDirect

journal homepage: <http://www.elsevier.com/locate/pjnns>

Original research article

Surgical treatment of neuronal-glia tumors of mesial-basal part of temporal lobe: Long term outcome and control of epilepsy in pediatric patients

Paweł Daszkiewicz^{*}, Paweł Kowalczyk, Marcin Roszkowski

Department of Neurosurgery, The Children's Memorial Health Institute, Head: professor Marcin Roszkowski, Warsaw, Poland

ARTICLE INFO

Article history:

Received 29 January 2017

Accepted 4 April 2017

Available online 19 April 2017

Keywords:

Neuronal-glia tumor

Mesial-basal temporal lobe

Epilepsy

Children

ABSTRACT

Background: Neuronal-glia tumors (ganglioglioma and dysembryoplastic neuroepithelial tumor) are a frequent cause of focal, drug-resistant and epilepsy in children and young adults, that is amenable for surgical treatment.

Aim of paper: Assessment of late outcome of surgical treatment and degree of seizure control, as well as prognostic significance of selected clinical factors.

Material and method: 52 Pediatric patients presenting with epilepsy, lesion of mesio-basal temporal lobe and histologically verified neuronal-glia tumor treated at our facility since 2000–2011.

Results: After the mean follow-up of 2.94 years, satisfactory treatment outcome (Engel classes I and II) was obtained in 92% of the patients ($n = 48$). Poor outcome (Engel class III) was seen in 8% of patients ($n = 4$). New neurological deficits appeared in 28% of the patients ($n = 20$) but in most of them resolved over time.

Conclusions: In patients with drug-resistant epilepsy and a lesion of mesial-basal part of temporal lobe suggestive of a glial-neuronal tumor, surgical treatment is strongly recommended, aiming at excision of tumor and elimination of seizures. Histological verification of the lesion is a pre-requisite for optimal treatment planning. In most patients, both treatment goals may be reached. Short duration of epilepsy prior to surgery and young age are favorable prognostic factors. Histological diagnosis of GG, co-existence of cortical dysplasia and location of tumor extending beyond mesial-basal temporal structures are associated with a higher risk of postoperative complications. These may out-weight expected benefits of surgery.

© 2017 Polish Neurological Society. Published by Elsevier Sp. z o.o. All rights reserved.

^{*} Corresponding author at: Klinika Neurochirurgii IPCZD, Al. Dzieci Polskich 20, 04-730 Warszawa, Poland.

E-mail address: pmdaszkiewicz@o2.pl (P. Daszkiewicz).

<http://dx.doi.org/10.1016/j.pjnns.2017.04.001>

0028-3843/© 2017 Polish Neurological Society. Published by Elsevier Sp. z o.o. All rights reserved.

1. Introduction

Neuronal-glia tumors (ganglioglioma and dysembryoplastic neuroepithelial tumor) are a frequent cause of focal epilepsy in children and young adults. They account for about 40% of all tumors located within the mesial-basal part of temporal lobe. This anatomic area is hardly accessible to both neurophysiological studies (detection of seizure activity arising here may require special techniques, e.g. foramen ovale electrodes), neuroimaging studies (visualization of low-grade tumors and dysplasia-like lesions may require special MRI acquisition techniques) and poses particular surgical problems due to close vicinity of brainstem, cranial nerves and vessels supplying highly eloquent brain areas. For a long time, these lesions evaded detection leaving these patients with a vague diagnosis of “idiopathic” or “cryptogenic” epilepsy, precluding cause-oriented and effective treatment. Only recently advances in neuroimaging and neurophysiology enabled detection of these lesions, their correlation with symptoms present and their relatively safe excision. This provides a chance for a cure of epilepsy in a considerable proportion of patients, which is fundamental in children and young adults.

2. Aim of paper

Assessment of late outcome of surgical treatment and degree of seizure control, as well as prognostic significance of selected clinical factors. Analysis encompassed a large group of patients relatively homogenous in what relates to clinical symptoms, location and type of lesion, diagnostic and therapeutic algorithm and surgical technique.

3. Material and method

Inclusion criteria (lesion located in mesial-basal part of the temporal lobe, histologically confirmed neuronal-glia tumor and at least 1 year follow-up) were fulfilled by 52 patients treated at our facility since 2000–2011. This group included 31 boys and 21 girls (ratio 1.47:1), aged 1.5–18 years (mean age 10.2 years). There were 30 left-sided lesions and 22 right-sided lesions (ratio 1.36:1). Mean follow-up was 2.94 (range 1–7 years).

Retrospective analysis of medical records took into account history, clinical symptoms, characteristics of MRI studies, surgical access used, results of histological studies, postoperative complications and late outcome concerning epilepsy control (assessed by the Engel scale) [1] (Table 1).

Location of tumors of the temporal lobe was assessed according to the Schramm-Allashkevich classification [2] (Table 2).

Due to the predefined scope of this paper, analysis encompassed tumors of types A, C and D only.

Statistical analysis used data concerning frequency of discrete features, mean and standard deviation, median and quartiles, as well as ranges for continuous features. Significance of differences among distribution of data in selected subgroups was verified using the Fisher exact test due to small

Table 1 – Engel scale assessing control of epilepsy after surgical treatment [1].

- Class I: Seizure free or no more than a few early, non-disabling seizures; or seizures upon drug withdrawal only
- Class II: Disabling seizures occur rarely during a period of at least 2 years; disabling seizures may have been more frequent soon after surgery; nocturnal seizures
- Class III: Worthwhile improvement; seizure reduction for prolonged periods but less than 2 years
- Class IV: No worthwhile improvement; some reduction, no reduction, or worsening are possible

Table 2 – Schramm-Allashkevich classification of temporal lobe tumors.

- Type A (“mesial”):** tumor limited to mesial-basal structures of temporal lobe (uncus, amygdaloid nucleus, hippocampus, parahippocampal gyrus, lingual gyrus).
- Type B (“temporo-lateral”):** tumor located lateral to Type A structures but not invading inferior and middle temporal gyrus.
- Type C:** tumor combining features of type A and B.
- Type D:** tumor consistent with type C, additionally invading temporal stem and basal part of central region of cerebral hemisphere.

number of observations in groups undergoing comparison. Discrimination analysis was used when appropriate. Significance threshold was set at $p < 0.05$. Results at the level of 0.06–0.09 were considered as a significant trend. Results above 0.09 were considered as non-significant and marked as “NS”. Calculations were performed using commercially available software STATA v.10.0 (Stata Corp., College Station, TX, USA).

4. Results

4.1. Symptoms

In all cases ($n = 52$) the leading clinical symptom were epileptic seizures. In 41 cases (79%) seizures persisted in spite of seemingly adequate pharmacotherapy, thus enabling the diagnosis of drug-resistant epilepsy. Median duration of seizures prior to admission to our facility was 2 years (range: 1 month–13 years). The most common type of seizures were generalized seizures ($n = 29$; 55%) and partial complex seizures ($n = 23$; 45%).

4.2. Tumor location and surgical treatment

The most common tumor location was type A ($n = 37$; 69%), while types C and D accounted for $n = 11$ (23%) and $n = 4$ (8%), respectively. Based on MRI-determined tumor location, three basic types of surgical approach were used. In the case of anteriorly located type A tumors, transsylvian Yassargil approach was used ($n = 24$; 46%). In posteriorly located type A tumors, transcortical Niemeyer approach was used ($n = 8$; 15%). In large type A tumors and in type C and type D tumors, Spencer anterior temporal lobectomy was used ($n = 20$; 39%).

In all cases, microsurgical tumor excision was performed under neuronavigation guidance and in cases of long-lasting, severe and drug-resistant epilepsy, intraoperative electrocor-

ticography was used, enabling detection and excision of secondary extra-lesional epileptogenic foci. Gross total tumor excision was obtained in 51 cases and partial excision – in 1 case of a type D tumor (DNT, residual tumor stable over 6 years' follow-up). Overall, within the mean follow-up period of 2.94 years, 3 patients with gross total tumor excision (no residual tumor visible in control MRI study) presented with tumor recurrence. In 1 case (DNT, no clinical signs, tumor recurrence in control MRI study) the patient was reoperated 7 years after the first procedure, obtaining apparently complete tumor removal. In 2 other cases (GG, no clinical signs, tumor recurrence after 1 and 2 years, respectively), with no tumor progression in subsequent imaging studies, patients are observed only.

4.3. Histological studies

In our material, neuronal-glioma tumors ($n = 52$) accounted for 74% of all tumors of mesial-basal part of temporal lobe ($n = 70$). Tumor types encountered in this area are presented in Table 3. Anatomical location of ganglioglioma ($n = 48$) was as follows: type A $n = 36$, type C $n = 10$ and type D $n = 2$. Location of dysembryoplastic neuroepithelial tumor ($n = 4$) was as follows: type A $n = 1$, type C $n = 1$ and type D $n = 2$. In 16 cases (15 GG and 1 DNT), tumor co-existed with focal cortical dysplasia (type IIIb), and in 5 – with hippocampal sclerosis (GG only) (“double pathology”).

4.4. Seizure control

The impact of surgery on severity of epilepsy was assessed based on the Engel scale presented in Table 4. Treatment outcome was considered good when epilepsy was entirely or nearly entirely eliminated (Engel classes I and II).

Within the above-mentioned mean follow-up time of 2.94 years, 87% of the patients ($n = 45$) are entirely seizure-free (Engel class IA), while satisfactory treatment outcome (Engel classes I and II) was obtained in 92% of the patients ($n = 48$). Poor outcome (Engel class III) was seen in 8% of patients ($n = 4$). Discontinuation of antiepileptic medication (implying cure of epilepsy in both medical and social aspect) was possible in 40% of the patients ($n = 21$).

One patient after complete excision of his tumor (GG) underwent a repeat surgery due to persistent seizures. Despite anatomical temporal lobectomy with hippocampectomy (histological study of surgical specimen revealed cortical dysplasia), no worthwhile improvement in epilepsy control was obtained.

Table 3 – Tumors of mesial-basal area of temporal lobe in our material ($n = 70$).

Tumor type	N
Ganglioglioma	48
Pilocytic astrocytoma	7
Polymorphic xanthoastrocytoma	6
Dysembryoplastic neuroepithelial tumor	4
Oligodendroglioma/oligodendroglioma-astrocytoma	3/1
Pilomyxoid astrocytoma	1
Ependymoma	1

Table 4 – Outcome of surgical treatment of epilepsy (Engel scale).

Class I: no seizures or auras only
Class II: up to 2 seizure days per year or nocturnal seizures only
Class III: reduction of seizure frequency by over 75%
Class IV: reduction of seizure frequency by less than 75% or no improvement.

Looking for factors affecting anti-epileptic efficacy of surgical treatment, our population of patients was subdivided into persons aged under 6 years ($n = 16$) and those aged over 6 years ($n = 36$). In the former group, complete cessation of seizures (Engel class I) was obtained in all patients. In the latter group, Engel class I result was obtained in 32/36 persons, while the remaining 4/36 were classified as Engel class II and III. The difference is statistically significant ($p < 0.05$), indicating that better results may be obtained in younger patients.

Patients were also subdivided according to duration of seizures into those with epileptic history of less than 1 year ($n = 13$) and those presenting seizures for over 1 year ($n = 39$). Again, in the former group, Engel class I outcome was obtained in 12/13 persons, while in the latter – in 33/39 persons. Engel class II/III outcome was obtained in 1/13 persons in the former group and in 6/39 persons in the latter. The difference is statistically significant ($p < 0.05$), indicating that shorter duration of seizures prior to surgery is associated with a better treatment outcome.

Worse treatment outcomes were seen in patients presenting with more extensive tumors (type C and type D) and in those with coexisting cortical dysplasia, but the difference did not reach statistical significance.

Neither surgical approach used, scope of tumor excision nor tumor recurrence affected late treatment outcome.

4.5. Complications

Immediately after surgery, new neurological deficits appeared in 28% of the patients ($n = 20$). These included: hemiparesis ($n = 18$), cranial nerve III paresis ($n = 4$), functionally significant hemianopsia ($n = 6$), isolated aphasia ($n = 3$). Some patients ($n = 11$) presented these disorders in various combinations. Over the mean follow-up time of 2.94 y, out of 18 patients with hemiparesis, in 4 cases it resolved completely and in the remaining 14 it improved to Lovet grade 3 and 4, not compromising the patient's overall performance. Aphasia resolved completely in 2 cases and improved significantly in 1.

Noteworthy is the correlation between tumor type and postoperative complication rate. In the GG group ($n = 48$), hemiparesis developed in 17 and did not resolve completely in 14, while in the DNT group ($n = 4$), it developed in 1 case and resolved completely. The difference is statistically significant ($p < 0.05$).

4.6. Late outcome

Treatment outcome was assessed at least 12 months after surgery based on the Glasgow Outcome Scale (Table 4) [3].

Satisfactory treatment outcome (GR and MD groups) was attained by all patients analyzed. Improvement of neurological status was seen in all patients discharged with a newly

acquired deficit after surgery. No cases of delayed deterioration of neurological status or death were noticed.

5. Discussion

Epilepsy is one of the most frequent neurological diseases and affects about 1% of general population [4]. In 75–80% of the cases, seizures may be controlled by pharmacotherapy (to be administered life-long), but in the remaining 20–25% epilepsy proves drug-resistant [5]. One of the most frequent causes of drug-resistant epilepsy in children are tumors within the mesial-basal structures of temporal lobe, accounting for 40–70% of all epilepsy-producing tumors in children [6]. Noteworthy is, that epilepsy is often the only clinically detectable symptom of the tumor [7]. Most of them are low-grade gliomas; high-grade tumors are rare at this location. Most common histological tumor types at this location include ganglioglioma (GG), pilocytic astrocytoma and dysembryoplastic neuroepithelial tumor (DNT) [8].

Neuronal-glia tumors are listed in group 1.7 of 2007 and 2016 WHO classification of CNS tumors (Table 5) [9,10]. Their common feature is the presence of cells presenting tissue markers typical both for neurons and glial cells [11,12]. Most common representatives of this group, arising in the temporal lobe and causing drug-resistant epilepsy are GG and DNT, therefore for the sake of histological homogeneity, we limited our analysis to these tumor types only. These tumors have also several common features: epilepsy as the first and only symptom in over 95% of the patients, young age at presentation and very slow clinical progression [13].

Computed tomography may detect about 50% of lesions in mesial-basal area of the temporal lobe. Advent of modern neuroimaging techniques, mainly high definition magnetic resonance, contributed to a significant reduction of number of cases previously described as “non-lesional”, “cryptogenic” or “idiopathic”. Modern MRI devices may detect structural lesions in nearly 100% of patients. Radiological image is similar in most cases. With T1 relaxation time, most tumors are hypointense and with T2 relaxation time—hyperintense. In FLAIR images nearly all are hyperintense [14]. They enhance heterogeneously with contrast media, rarely present peri- or intratumoral cysts and calcifications are less common than with other locations. In the diagnosis of medial-basal temporal tumors, functional MRI is rarely performed due to lack of standardized techniques enabling location of memory and speech functions, particularly in young patients. Furthermore,

MR study in non-cooperative children requires general anesthesia, so fMRI in small children is impossible [15].

Ganglioglioma accounts for about 1.3% of all CNS tumors in children and is usually circumscribed but may invade pia-arachnoid. This may cause problems with total excision, putting at risk adjacent vessels and other structures and resulting in significantly higher complication rate, as shown in our material. The tumor is composed of a mixed population of neurons and malignant glial cells. Glial component usually is consistent with pilocytic astrocytoma, rarely with other astroglial tumors. Tumor cells express both neuronal markers (synaptophysin and neurofilament epitopes) and glial markers (glial fibrillary acidic protein). Degree of malignancy depends on severity of anaplasia within the glial component [16–18].

Dysembryoplastic neuroepithelial tumor (DNT) accounts for about 13.5% of all CNS tumors in children. It may take 3 histological forms: simple (tumor tissue is composed of typical neuronal-glia cells), complex (tumor tissue is composed by glial nodules, glial-neuronal cells, foci of cortical dysplasia and disorganized cytoarchitecture) and non-specific (taking an atypical morphological appearance). Tumor may be surrounded by areas of disordered layered architecture consistent with focal dysplasia IIIb and neuronal heterotopias [12,19,20].

In our material, the incidence GG and DNT in mesial-basal area of temporal lobe is completely different to that reported for the entire CNS. This finding is noteworthy, indicating a possible local preference of specific types, also found elsewhere in the brain and concerning other tumor types [21].

Glial neuronal tumors usually take a benign clinical course and for several years may be stable, both in terms of severity of symptoms and radiological appearance. This is also confirmed by our findings. Malignant transformation, although described in the literature, is rare [22].

Epilepsy caused by a lesion within the mesial-basal part of temporal lobe usually has a typical symptom profile, exacerbates over time and in most cases proves resistant to pharmacotherapy. Particularly in young children, uncontrollable seizures result in progressive deterioration of cognitive functions and psychomotor retardation. Noteworthy is, that even clinically asymptomatic bioelectric seizures may result in severe behavioral disorders and deterioration of cognitive functions. Therefore, surgical treatment should always be considered, according to the principle “the sooner the better”. In our material, better outcomes were obtained in younger children and in those with shorter duration of their disease [23].

The mechanism of epileptogenesis in CNS tumors is not fully understood. At macroscopic level, there is direct compression and irritation of brain cortex and local alteration of brain perfusion. At the cellular level there is neuronal loss, glia proliferation, altered cell physiology, altered level and composition of neurotransmitters, calcium, glutamate and free radicals, affecting both neurons and glia. Altered composition of extracellular fluid and inter-cellular junctions may also play a role. As a result, neurons adjacent to the tumor show disturbed mechanisms of control of excitation and inhibition, resulting in hypersensitivity of neurons to external stimuli (both electric and chemical) and synchronous discharges of large groups of cells. Secondary epileptogenic foci developing over time may be functional (at first) or structural

Table 5 – Glasgow Outcome Scale.

GR (good result) – good overall condition, no deficits or mild neurological or cognitive deficit not affecting normal functioning (professionally active).
MD (moderate disability) – good overall condition, moderate neurological and cognitive deficit, patient independent in everyday activities.
SD (severe disability) – severe deficit, patient dependent on others in everyday activities.
VS (vegetative state).
D (death).

(later on). Upon elimination of the primary focus, functional secondary foci may disappear spontaneously. An epileptogenic focus is not equivalent with the tumor, thus confirming the thesis about multifactorial etiology of epilepsy. This has been also confirmed by our findings, where excision of tumor does not necessarily eliminate the epilepsy [24–26].

A separate problem associated with prolonged pharmacotherapy are side effects of anti-epileptic drugs (cognitive disorders, teratogenic effect on the fetus, hepatotoxicity, gingival hypertrophy, etc.), not to mention economic burden of life-long drug dependency. Thus the importance of a potentially curative procedure, enabling discontinuation of pharmacotherapy in a significant proportion of patients [27–29].

In terms of surgical strategy, tumors of mesial-basal temporal lobe pose essentially two interdependent clinical problems: tumor and epilepsy. Management must be comprehensive and aiming at elimination of both conditions. As in other fields of neurosurgery, the main goal of surgery is as complete as possible tumor excision without causing severe and permanent neurological deficits, that might significantly compromise the patients' quality of life. In the case of tumors of mesial-basal part of temporal lobe, surgical accessibility, low-grade histology, relatively well defined margins and modern surgical technique, enable complete excision of both lesion and co-existing epileptogenic focus, providing both oncological and neurological cure. However, even small residual tumor or epileptogenic focus may increase the risk recurrence and persistence of epilepsy. Seizures may recur even several years after an apparently radical surgery. In our material, treatment outcome in terms of antiepileptic efficacy, was stable over 2 years' follow-up [30–32].

There are three basic strategies: lesionectomy (excision of lesion within its anatomical boundaries), lesionectomy with focectomy (excision of lesion with adjacent epileptogenic focus) and lobectomy (excision of part of entire temporal lobe containing structural and functional lesions) [32,33]. In our facility, surgical strategy depends on tumor location, size and discernible epileptogenic focus. The following approaches are used:

- Anterior-mesial temporal excision (m. Spencer), consisting in excision of temporal pole (3–3.5 cm) and mesial structures but with sparing of the superior temporal gyrus (a less extensive procedure compared to classic lobectomy reduces the risk of postoperative speech and visual field deficits) [33].
- Selective anterior amygdalo-hippocampectomy (m. Yassar-gil) used in lesions of anterior part of hippocampus, approached through the lateral (Sylvian) fissure [35,36].
- Selective posterior amygdalo-hippocampectomy (m. Niemeyer) used in lesions of posterior part of hippocampus, approached through the middle temporal gyrus [34].

Subtemporal approach upon retraction of temporal lobe is rarely used nowadays, due to frequent complications caused by disruption of the vein of Labbe and contusion of undersurface of temporal lobe [35].

Surgery is always a serious and irreversible intervention into vital brain areas. Mortality (early and delayed) associated with surgical treatment of tumors of mesial-basal area of temporal lobe is estimated at 0–2%. Perioperative death is

caused usually by infection, hydrocephalus, hematoma or vasospasm and brain ischemia, while delayed death is caused usually by status epilepticus [36].

Morbidity rate is estimated at about 20% and has not decreased substantially within the past 30 years [37]. Complications may be subdivided into cognitive and neurological. The most common cognitive disorder associated with temporal lobe surgery is memory deficit [38]. It rarely develops in children but is far more common in adults with several years' long epileptic history. Neurological complications include motor aphasia (caused by damage to Broca's area and to the uncinate fascicle), visual field deficit (caused by damage to Meyer's loop, optic tract or choroidal artery), hemiparesis (damage to vessels supplying the central region) or diplopia (damage to nerve III and IV). The risk thereof may be reduced by limiting excision of the superior temporal gyrus to 3 cm and of middle temporal gyrus to 4.5 cm from the pole, by subarachnoid excision of the hippocampus and preservation of choroidal artery and nerves. The key issue is expertise and anatomical orientation on the part of operating surgeon [36–38].

In our material, fewer complications were seen in younger patients and in those harboring a DNT. It appears that growth pattern of GG with invasion of pia-arachnoid (as opposed to DNT, which is usually far better circumscribed) favors intraoperative damage to adjacent structures. The role of age is less evident in this context. This issue requires further study but a possible explanation is that functional disturbances are much more difficult to detect in small and uncooperative children. On the other hand, young people much better restore lost neurological function. Our results confirm these findings and further support the claim to operate these patients as early as possible.

Arguments promoting surgery in younger patients include: generally worse outcome of anti-epileptic pharmacotherapy than in adults, enhanced risk of developing side effects of anti-epileptic drugs, economic burden of treatment, social stigmatization, deterioration of quality of life, arrest of psychomotor development, intellectual collapse and risk of death during an uncontrollable status epilepticus. Gravity of these factors is further enhanced by a far longer expected survival time in children than in adults [39–41].

In the case of GG and DNT, the natural course of the disease is known and surgery provides at least an 80% chance of elimination of seizures, enabling normal psychomotor development and ensuring an acceptable quality of life. Qualifying a patient for surgical treatment requires a careful consideration of expected benefits and possible risk. In the setting of temporal epilepsy, superiority of surgical over conservative treatment has been demonstrated by prospective randomized trial. In 2003, American Academy of Neurology recommended surgical treatment as the first-choice option in drug-resistant epilepsy [42,43].

6. Conclusions

1. In patients with drug-resistant epilepsy and a lesion of mesial-basal part of temporal lobe suggestive of a glial-neuronal tumor, surgical treatment is recommended,

aiming at excision of tumor and elimination of seizures. Histological verification of the lesion is a pre-requisite for optimal treatment planning.

2. In most patients, both treatment goals may be reached.
3. Short duration of epilepsy prior to surgery and young age are favorable prognostic factors.
4. Histological diagnosis of GG, co-existence of cortical dysplasia and location of tumor extending beyond mesial-basal temporal structures are associated with a higher risk of postoperative complications. These may outweigh expected benefits of surgery.

Conflict of interest

None declared.

Acknowledgement and financial support

None declared.

Ethics

The work described in this article has been carried out in accordance with The Code of Ethics of the World Medical Association (Declaration of Helsinki) for experiments involving humans; Uniform Requirements for manuscripts submitted to Biomedical journals.

REFERENCES

- [1] Engel Jr J, Van Ness P, Rasmussen TB, Ojemann LM. Outcome with respect to epileptic seizures. In: Engel Jr J, editor. *Surgical treatment of the epilepsies*. 2nd ed. New York: Raven Press; 1993. p. 609–21. 727–9.
- [2] Schramm J, Aliashkevich AF. Temporal mediobasal tumors: a proposal for classification according to surgical anatomy. *Acta Neurochir* 2008;150:857–64.
- [3] Jennett B, Bond M. Assessment of outcome after severe brain damage. *Lancet* 1975;(7905):480–4.
- [4] Arts WF, Geerts AT, Brouwer OF, Boudewyn Peters AC, Stroink V, van Donselaar CA. The early prognosis of epilepsy in childhood: the prediction of a poor outcome. *The Dutch Study of Epilepsy in Childhood*. *Epilepsia* 1999;40:726–34.
- [5] Engel Jr J, Wiebe S, French J. Temporal lobe and localized neocortical resections for epilepsy: report of the Quality Standards Subcommittee of the American Academy of Neurology in association with the American Epilepsy Society and the American Association of Neurological Surgeons. *Neurology* 2003;60:538–47.
- [6] Blume WT, Girvin JP, Kaufmann JC. Childhood brain tumors presenting as chronic uncontrolled focal seizure disorders. *Ann Neurol* 1982;12:538–41.
- [7] Morris HH, Estes ML, Gilmore R, van Ness PC, Barnett GH, Turnbull J. Chronic intractable epilepsy as the only symptom of primary brain tumor. *Epilepsia* 1993;34:1038–43.
- [8] Perek D, Roszkowski M. Nowotwory ośrodkowego układu nerwowego u dzieci. Diagnostyka i leczenia. *Fundacja NEURONET* 2006;30–40.
- [9] Louis DN, Ohgaki H, Wiestler OD, Cavenee WK, Burger PC, Jouvet A, et al. The 2007 WHO classification of tumors of the central nervous system. *Acta Neuropathol* 2007;114(2):97–109.
- [10] Louis DN, Perry A, Reifenberger G, von Deimling A, Figarella-Branger D, Cavenee WK, et al. The 2016 WHO classification of tumors of the central nervous system: a summary. *Acta Neuropathol* 2016;131:803.
- [11] Daumas-Duport C, Scheithauer BW, Chodkiewicz JP, Laws Jr ER, Vedrenne C. Dysembryoplastic neuroepithelial tumor: a surgically curable tumor of young patients with intractable partial seizures. Report of thirty-nine cases. *Neurosurgery* 1998;23:545–56.
- [12] Kordek R, Biernat W, Zakrzewski K, Polis L, Liberski PP. Dysembryoplastic neuroepithelial tumor (DNT): an ultrastructural study of six cases. *Folia Neuropathol* 1999;37:167–70.
- [13] Zakrzewski K, et al. Nowotwory mózgu wieku dziecięcego. *Czelej*; 2004. p. 58–92.
- [14] Bronen RA, Fulbright RK, Spencer DD, Spencer SS, Kim JH, Lange RC. MR characteristics of neoplasms and vascular malformations associated with epilepsy. *Magn Reson Imaging* 1995;13:1153–62.
- [15] Koepp MJ, Woermann FG. Imaging structure and function in refractory focal epilepsy. *Lancet Neurol* 2005;4:42–53.
- [16] Blumke I, Wiestler OD. Gangliogliomas: an intriguing tumour entity associated with focal epilepsies. *J Neuropathol Exp Neurol* 2002;61:575–84.
- [17] Lang FF, Epstein FJ, Ransohoff J, Allen JC, Wisoff J, Abbott JR, et al. Central nervous system gangliogliomas. Part 2. Clinical outcome. *J Neurosurg* 1993;79:867–73.
- [18] Morris HH, Matkovic Z, Estes ML, Prayson RA, Comair YG, Turnbull J, et al. Ganglioglioma and intractable epilepsy: clinical and electrophysiologic features and predictors of outcome after surgery. *Epilepsia* 1998;39:307–12.
- [19] Fomekong E, Baylac F, Moret C, Chastagner P, Docrocq X, Marchal JC. Dysembryoplastic neuroepithelial tumors. Analysis of 16 cases. *Neurochirurgie* 1999;45:180–9.
- [20] Raymond AA, Fish DR, Sisodiya SM, Alsanayari N, Stevens JM, Sharvan SD. Abnormalities of gyration, heterotopias, tuberous sclerosis, focal cortical dysplasia, microdysgenesis, dysembryoplastic neuroepithelial tumor and dysgenesis of the archicortex in epilepsy: clinical, EEG and neuroimaging features in 100 adult patients. *Brain* 1995;118:629–60.
- [21] Farwell JR, Dohrmann GJ, Flannery JT. Central nervous system tumors in children. *Cancer* 1977;40:561–8.
- [22] Aronica E, Leenstra S, van Veelan CW, van Rijen PC, Hulsebos TJ, Tersmette AC, et al. Glioneuronal tumors and medically intractable epilepsy: a clinical study with long-term follow-up of seizure outcome after surgery. *Epilepsy Res* 2001;43:179–91.
- [23] Beaumont A, Whittle IR. The pathogenesis of tumour associated epilepsy. *Acta Neurochir* 2000;142:1–15.
- [24] Ben-Ari Y, Dudek FE. Primary and secondary mechanisms of epileptogenesis in the temporal lobe: there is a before and an after. *Epilepsy Curr* 2010;10:118–25.
- [25] Aronica E, Redeker S, Boer K, Spliet WG, van Rijen PC, Garter JA, et al. Inhibitory networks in epilepsy-associated gangliogliomas and in the perilesional epileptic cortex. *Epilepsy Res* 2007;74:33–44.
- [26] Shamji MF, Fric-Shamji EC, Benoit BG. Brain tumors and epilepsy: pathophysiology of peritumoral changes. *Neurosurg Rev* 2009;32:275–84.
- [27] Herranz JL, Armijo JA, Arteaga R. Clinical side effects of phenobarbital, primidone, phenytoin, carbamazepine, and

- valproate during monotherapy in children. *Epilepsia* 1988;29:794-804.
- [28] Vasconcellos E, Wyllie E, Sullivan S, Stanford L, Bulacio J, Kotagal P, et al. Mental retardation in pediatric candidates for epilepsy surgery: the role of early seizure onset. *Epilepsia* 2001;42:268-74.
- [29] Berg AT, Vickrey BG, Langfitt JT, Sperling MR, Shinnar S, Bazil C, et al. Multicenter Study of Epilepsy Surgery. Reduction of AEDs in postsurgical patients who attain remission. *Epilepsia* 2006;47:64-71.
- [30] Sandberg DI, Ragheb J, Dunoyer C, et al. Surgical outcomes and seizure control rates after resection of dysembryoplastic neuroepithelial tumors. *Neurosurg Focus* 2005;15: 18:E5.
- [31] Jooma R, Yeh HS, Privitera MD, Gartner M. Lesionectomy versus electrophysiologically guided resection for temporal lobe tumors manifesting with complex partial seizures. *J Neurosurg* 1995;83:231-6.
- [32] Babini M, Giulioni M, Galassi E, Marucci G, Martinoni M, Rubboli G, et al. Seizure outcome of surgical treatment of focal epilepsy associated with low-grade tumors in children. *J Neurosurg Pediatr* 2013;11:214-23.
- [33] Spencer DD, Spencer SS, Mattson RH, Williamson PD, Novelly RA. Access to the posterior medial temporal lobe structures in the surgical treatment of temporal lobe epilepsy. *Neurosurgery* 1984;15:667-71.
- [34] Schramm J, Aliashkevich AF. Surgery for temporal mediobasal tumors: experience based on a series of 235 patients. *Neurosurgery* 2007;60:285-94.
- [35] Bidziński J, Marchel A. Lezjonektomia w operacyjnym leczeniu padaczki. *Neurol Neurochir Pol* 1998;2:69-80.
- [36] Niemeier P. The transventricular amygdala-hippocampectomy in temporal lobe epilepsy. In: Baldwin M, Bailey P, editors. *Temporal lobe epilepsy*. Springfield; 1958. p. 461-82.
- [37] Wieser HG, Yasargil MG. Selective amygdalohippocampectomy as a surgical treatment of mesiobasal limbic epilepsy. *Surg Neurol* 1982;17:445-57.
- [38] Yeni SN, Tanriover N, Uyanik O, Ulu MO, Ozkara C, Karaagac N, et al. Visual field defects in selective amygdalohippocampectomy for hippocampal sclerosis: the fate of Meyer's loop during the transsylvian approach to the temporal horn. *Neurosurgery* 2008;63:507-13.
- [39] Behrens E, Schramm J, Zentner J, Koenig R. Surgical and neurological complications in a series of 708 epilepsy surgery procedures. *Neurosurgery* 1997;41:1-10.
- [40] Katz A, Awad IA, Kong AK. Extent of resection in temporal lobectomy for epilepsy. II. Memory changes and neurological complications. *Epilepsia* 1989;30:763-71.
- [41] Klein M, Engelberts NH, van der Ploeg HM, Kasteleijn-Nolst Trenite DG, Aaronson NK, Taphoorn MJ, et al. Epilepsy in low-grade gliomas: the impact on cognitive function and quality of life. *Ann Neurol* 2003;54:514-20.
- [42] Shewmon DA, Shields WD, Chugani HT, Peacock WJ. Contrasts between pediatric and adult epilepsy: rational and strategy for focal resection. *J Epilepsy* 1990;3:141-55.
- [43] Sinclair DB, Aronik K, Snyder T, McKean J, Wheatley M, Bhargava R, et al. Pediatric temporal lobectomy for epilepsy. *Pediatr Neurosurg* 2003;38:195-205.