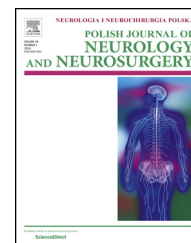


Available online at [www.sciencedirect.com](http://www.sciencedirect.com)

ScienceDirect

journal homepage: <http://www.elsevier.com/locate/pjnns>

## Original research article

# Syringomyelia associated with cervical spondylotic myelopathy causing canal stenosis. A rare association

Dirk Pillich<sup>a</sup>, Ehab El Refaee<sup>a,b,\*</sup>, Jan-Uwe Mueller<sup>a</sup>, Amr Safwat<sup>b</sup>,  
Henry W.S. Schroeder<sup>a</sup>, Joerg Baldauf<sup>a</sup>

<sup>a</sup>Department of Neurosurgery, Ernst Moritz Arndt University, Germany

<sup>b</sup>Department of Neurosurgery, Cairo University, Egypt

## ARTICLE INFO

## Article history:

Received 20 June 2016

Accepted 3 August 2017

Available online 14 August 2017

## Keywords:

Syringomyelia

Spondylotic myelopathy

Laminectomy

Laminoplasty

## ABSTRACT

**Background:** Although cervical spondylosis is extremely common, only few cases with associated syrinx have been reported. Depending on review of two large data bases, we report this case series. In addition, we evaluated the posterior decompression as the management option in treatment of this rare condition.

**Materials and methods:** Data of all cases with cervical spondylosis and canal stenosis that sought medical advice or needed decompressive laminectomy/laminoplasty between the years 2006 and 2015 were checked in manually. Perioperative data, together with follow up were reviewed.

**Results:** Out of five cases found in the reviewed data; four cases undergone posterior decompression (laminectomy in two cases and laminoplasty in the other). One case refused surgery. Along mean follow up period of 6.25 months; three cases improved markedly, while in one case no improvement occurred.

**Conclusion:** Cervical spondylotic myelopathy can rarely cause syringomyelia. Posterior decompression would be the preferable management option with clinical improvement of most of the cases.

© 2017 Published by Elsevier Sp. z o.o. on behalf of Polish Neurological Society.

## 1. Introduction

Syringomyelia is a disease characterized by cystic tubular cavitation of the spinal cord due to disturbance of the CSF flow. It has been often described as a common finding with Chiari I malformation together with tonsillar herniation [1,2]. Cervical trauma, fractures and tumors have been also described as

common causes of syringomyelia [1,3,4]. Although cervical spondylotic myelopathy with canal stenosis is a common condition, it has rarely been described to cause syringomyelia. Most of the cases found were published in reports, which indicates its rare incidence that needs more contribution in literature [2,5–7].

This series is aimed to report this rare association among the cases with cervical spondylotic myelopathy, where

\* Corresponding author at: Department of Neurosurgery, Ernst Moritz Arndt University, Germany.

<http://dx.doi.org/10.1016/j.pjnns.2017.08.002>

0028-3843/© 2017 Published by Elsevier Sp. z o.o. on behalf of Polish Neurological Society.

decompressive laminectomy/laminoplasty was offered as the management option, with highlighting the pre and postoperative clinical and radiological picture, depending on retrospective review of large databanks of two institutes.

## 2. Materials and methods

### 2.1. Clinical methods

In this series, the data banks of two neurosurgery institutions were thoroughly reviewed. The data from all cases with cervical spondylosis and canal stenosis that sought medical advice or needed decompressive laminectomy/laminoplasty between the years 2006 and 2015 were checked (Fig. 1). Manual search through the outpatient reports, operative and discharge letters in both institutions, in addition to records from the patients' Catalog of the senior Egyptian Neurosurgeon (A.S) was performed. All recorded cases have undergone MRI

examination (with variable magnets) of the cervical spine. Preoperative data were reviewed (including preoperative MRI, Clinical condition) in order to find-out the association of the Syrinx with cervical spondylotic myelopathy causing canal stenosis. Cases found with that association were thoroughly analyzed and reported with the inclusion of the clinical condition and follow up period. Patients with low quality MRI that couldn't show clearly the pathological findings were excluded. The Patients with Chiari malformation, previous trauma, fractures, tumors or infection were excluded from the study.

The amount of non-recorded data "including MRI, clinical condition" could not be obtained due to the loss of manual records in the outpatient clinic in some instances. Five cases were found "four males and one female" that had syringomyelia caused by the cervical stenosis without any other cause. Syrinx was extending more than three segments in four cases. Mean age of 61.4 and presenting symptoms of myelopathy with variable degrees of weakness.

### 2.2. Surgical methods

Depending on the clinical presentation and preoperative MRI, cases with cervical spondylotic myelopathy have undergone either decompressive laminectomy with lateral mass fixation in cases of lost or reversed cervical lordosis; decompression and laminoplasty, or anterior decompression and fusion in cases with no element of posterior compression.

## 3. Results

Out of five cases two cases undergone decompression and laminoplasty, and two cases undergone laminectomy (Figs. 2 and 3). One case refused surgery (Fig. 4). All cases were complaining from myelopathy and paresis with variable degrees (Table 1). Along the follow up period, Clinical improvement occurred in three cases. In one case, gradual deterioration of the motor power occurred upon three months follow up while the syrinx remained. Syringoperitoneal shunt was performed in this case with no improvement afterwards. Radiological improvement of the syrinx was reported in two cases (Figs. 2 and 3). In one case, follow up revealed the existence of the syrinx with marked clinical improvement.

## 4. Discussion

Syringomyelia is classified as tubular enlargements within the spinal cord that can originate from dilatation of the central canal whether communicating with the fourth ventricle or not. It can originate also as primary parenchymal cavitation not connected to the central canal [8]. As a rare cause, cervical spondylosis can be associated with syringomyelia. It is usually associated mainly with Chiari malformation or trauma. Infection, and tumor are considered also as causative factors [3,4,8]. Although cervical spondylosis is extremely common, only few cases with associated syrinx have been reported [7,9-12].

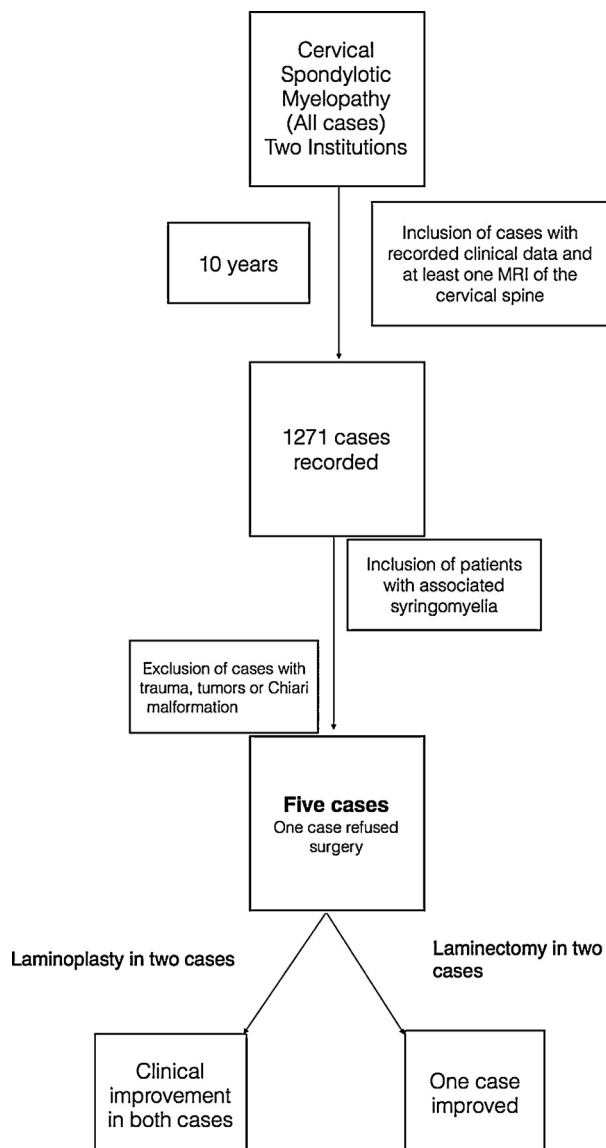


Fig. 1 – Patients' selection methodology and results.

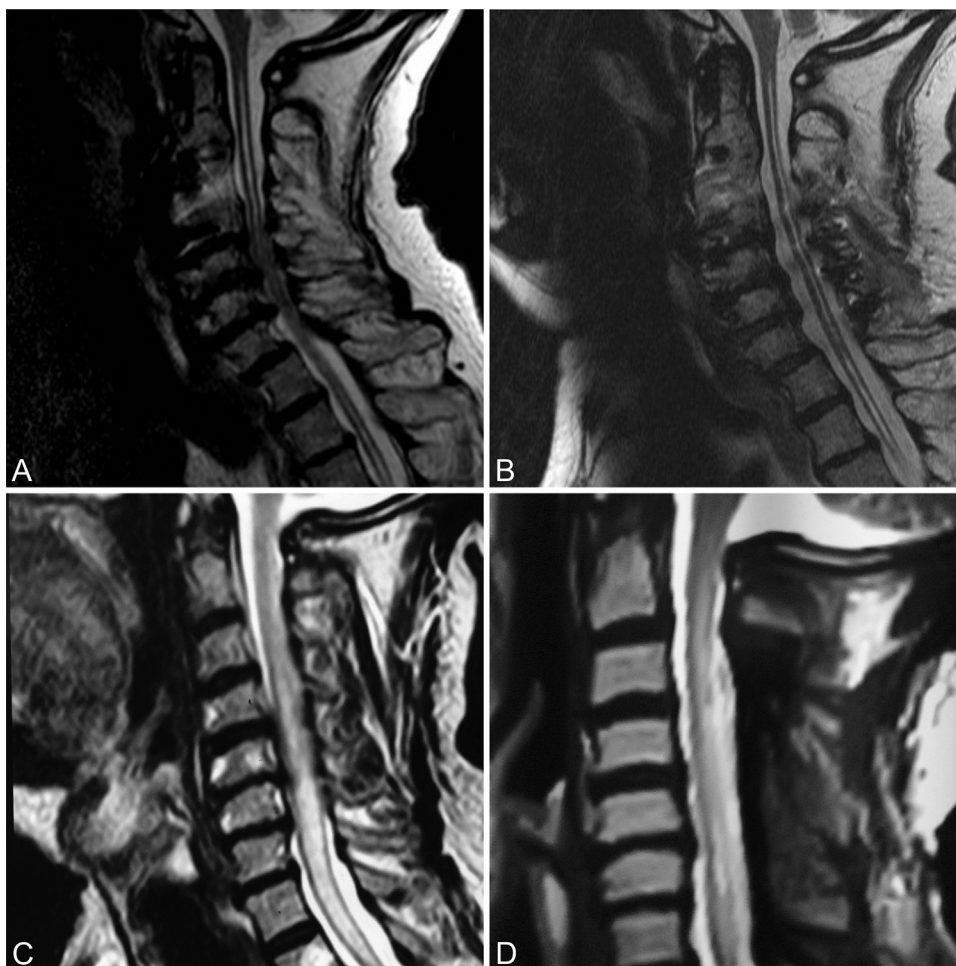
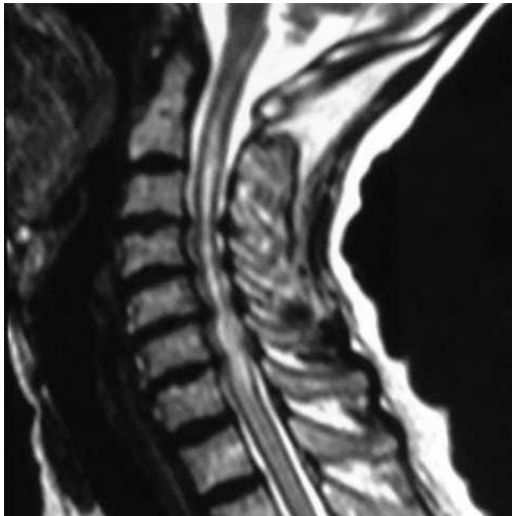


Fig. 2 – Sagittal T2 cervical MRI of two patients showing preoperative cervical canal stenosis and syringomyelia (A, C) and postoperative decompression with laminoplasty (B) and laminectomy (D) with marked reduction in the size of the syrinx.

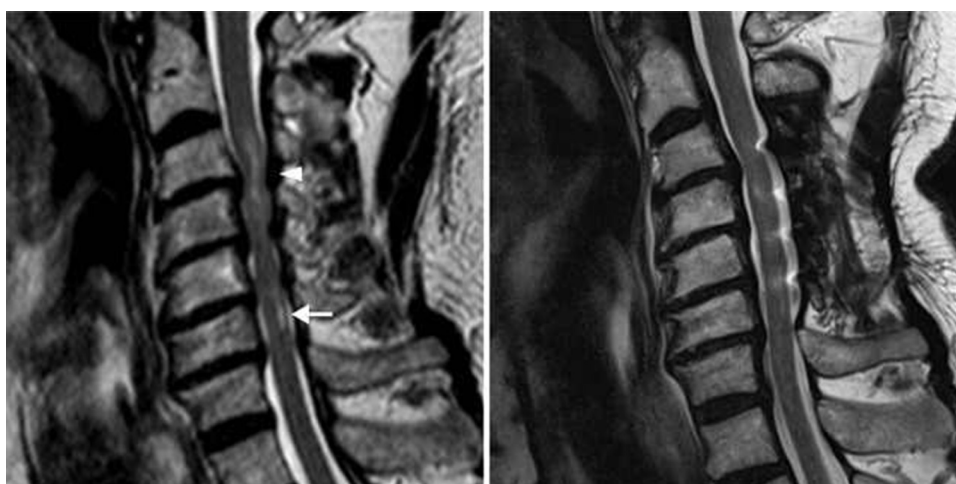

Fig. 3 – Preoperative sagittal T2 MRI showing cord edema at the level of C3,4 (arrow head) and starting syrinx at the level of C6 (arrow) supporting the theory of (pre-syrinx) (Left). Post operative MRI (T2 sagittal) showing complete resolution of the cord edema and the starting syrinx.



**Fig. 4 – Sagittal T2 MRI of 65 years old female showing tight canal stenosis and syringomyelia. The patient refused surgery with slowly progression of the quadriparesis.**

These reports started since early twentieth century. Patients with syringomyelia, exactly as those with cervical spondylosis causing canal stenosis, have complaints and present with findings correlated to central cord syndrome. Disturbance in the CSF dynamics, together with chronic compression and minor repetitive traumas lead to the occurrence of the cystic dilation in such cases [3,4,10,11].

Many theories tried to define the cause for syringomyelia. Al Mefty and his colleagues postulated the (myomalacia)

theory due to the chronic compression that is succeeded by degeneration and cavitation [10,13]. The theory of subarachnoid obstruction was adopted by Levine, who assumed that the obstruction would create increase in the CSF pressure above the block causing spasm in the blood vessels, therefore dilatation below which causes disruption of the blood brain barrier would take place, causing ultrafiltration of crystalloids and thus cystic dilation of the cord [4]. Goel adopted another theory which assumed that the fluid dissection in the cord occurs along the planes of least resistance “degenerated tissue”, could be a protective mechanism in severe stenosis to protect the viable nervous tissue and thus creating a “decompressive” space [14]. The association between the occurrence of syringomyelia and severe arachnoiditis has been also observed [3]. In another theory, the longstanding static and dynamic intermittent compression of the spinal cord, together with sloshing effect of the pulsatile CSF pressure have been supposed as causative factors for the occurrence of syringomyelia with cervical spondylosis [7]. One of the explanations to declare the pathophysiology is the cascade of events that begins with the obstruction in the CSF flow within the subarachnoid space, which subsequently affects the CSF dynamics, at which a spinal subarachnoid block would increase spinal subarachnoid pulse pressure above the block, producing a pressure differential across the obstructed segment of the sub arachnoid space. This would result in syrinx formation and progression. In comparison to healthy individuals, the pressure difference above and below the level of CSF block is thought to be the major cause of Syrinx formation [15].

In general, cervical spondylotic myelopathy can cause severe pathological changes within the spinal cord [16]. The theory of “presyrinx” is supported with one of the cases

**Table 1 – Case presentation.**

Case	Sex	Age	Clinic	Presentation	Imaging	Management	Clinical follow up	Radiological follow up	Follow up
1	Female	65	Cairo Univesity	Myelopathy Quadriparesis grade 4	C2–C6 osteophytes- canal stenosis and C2–C6 syringomyelia	Refused surgery			
2	Male	54	Cairo Univesity	Myelopathy Quadriparesis grade 3 Urinary incontinence	C3–C6 Canal stenosis C4-D1 Syringomyelia	Laminectomy	Improvement	Improvement of the syrinx	1 year
3	Male	50	Cairo Univesity	Myelopathy Quadriparesis grade 3–4	C3–C6 canal stenosis C2–C6 Syringomyelia	Laminectomy	Worsening of symptoms, needed syringoperitoneal shunt with no improvement	No improvement	6 months
4	Male	81	Greifswald University Medicine	Myelopathy Quadriparesis grade 2 left lower limb grade 3–4 upper extremities and right lower limb Urinary incontinence	C4–C7 canal stenosis C1–D2 syrinomyelia	Laminoplasty	Improvement	No improvement of the syrinx	1 month
5	Male	57	Greifswald University Medicine	Monoparesis right upper limb grade 4	Canal stenosis C4–C7 with small syrinx over C6	Laminoplasy	Improvement	Improvement	6 months

reported in this series, where the preoperative MRI showed cord edema and small “Starting syrinx” which was totally resolved postoperatively (Fig. 3) [6,17].

In cases of circumferential canal stenosis, posterior decompression would be sufficient to relieve the symptoms [18–20]. Although laminectomy can be performed without fusion in cases of preserved or minimally affected cervical lordosis, it may increase the incidence of progressive spinal deformity requiring subsequent spinal stabilization in some patients [19]. Effectiveness of laminoplasty over laminectomy and fusion in cases with cervical spondylotic myelopathy is still debatable [19,20]. In addition, anterior decompression and fusion could be performed in some cases with favorable outcome, especially when the anterior osteophyte is the main element of compression [11]. According to our results clinical improvement that is mostly associated with radiological improvement regarding the size of the syrinx. However clinical improvement can occur with out radiological reduction of the cavitation.

This case series is aiming for representation of more cases considering this rare condition, together with the support of the posterior decompression as management of choice in cases with cervical canal stenosis associated with syringomyelia. Failure of obtaining data from all cases with cervical spondylotic myelopathy that sought medical advice, thus analysis of the incidence of syrinx occurrence in these cases, represents the main limitation of this study. To our knowledge, this case series represents the first case series that presents cervical spondylotic myelopathy as a direct cause for syringomyelia. However, more contribution with wide-based search among databases is warranted.

## 5. Conclusion

Cervical spondylotic myelopathy can rarely cause syringomyelia. Posterior decompression would be the preferable management option with clinical improvement of most of the cases.

## Conflict of interest

None declared.

## Acknowledgment and financial support

None declared.

## REFERENCES

- [1] Heiss JD, Patronas N, DeVroom HL, Shawker T, Ennis R, Kammerer W, et al. Elucidating the pathophysiology of syringomyelia. *J Neurosurg* 1999;91:553–62.
- [2] Kato N, Tanaka T, Nagashima H, Arai T, Hasegawa Y, Tani S, et al. Syrinx disappearance following laminoplasty in cervical canal stenosis associated with Chiari malformation – case report. *Neurol Med Chir (Tokyo)* 2010;50:172–4.
- [3] Lee JH, Chung CK, Kim HJ. Decompression of the spinal subarachnoid space as a solution for syringomyelia without Chiari malformation. *Spinal Cord* 2002;40:501–6.
- [4] Levine DN. The pathogenesis of syringomyelia associated with lesions at the foramen magnum: a critical review of existing theories and proposal of a new hypothesis. *J Neurosci* 2004;220:3–21.
- [5] Arai A, Aihara H, Miyake S, Hanada Y, Kohmura E. Syringomyelia due to thoracic spinal stenosis with ossified ligamentum flavum – case report. *Neurol Med Chir (Tokyo)* 2011;51:157–9.
- [6] Bhagavathula Venkata SS, Arimappamagan A, Lafazanov S, Pruthi N. Syringomyelia secondary to cervical spondylosis: case report and review of literature. *J Neurosci Rural Pract* 2014;5:578–82.
- [7] Kimura R, Park YS, Nakase H, Sakaki T. Syringomyelia caused by cervical spondylosis. *Acta Neurochir (Wien)* 2004;146:175–8.
- [8] Milhorat TH. Classification of syringomyelia. *Neurosurg Focus* 2000;8(3). article 1.
- [9] Butteriss DJA, Birchall D. A case of syringomyelia associated with cervical spondylosis. *Br J Radiol* 2006;79:e123–5.
- [10] Jinkins JR, Bashir R, Al-Mefty O, Al-Kawi MZ, Fox JL. Cystic necrosis of the spinal cord in compressive cervical myelopathy: demonstration by iopamidol CT-myelography. *AJR Am J Roentgenol* 1986;147:767–75.
- [11] Landi A, Nigro L, Marotta N, Mancarella C, Donnarumma P, Delfini R. Syringomyelia associated with cervical spondylosis: a rare condition. *World J Clin Cases* 2013;1:111–5.
- [12] Lucci B, Reverberi S, Greco G. Syringomyelia and syringomielic syndrome by cervical spondylosis. Report on three cases presenting with neurogenic osteoarthropathies. *J Neurosurg Sci* 1981;25:169–72.
- [13] Al-Mefty O, Harkey LH, Middleton TH, Smith RR, Fox JL. Myelopathic cervical spondylotic lesions demonstrated by magnetic resonance imaging. *J Neurosurg* 1988;68:217–22.
- [14] Goel A. Is syringomyelia pathology or a natural protective phenomenon? *J Postgrad Med* 2001;47:87–8.
- [15] Heiss JD, Snyder K, Peterson MM, Patronas NJ, Butman JA, Smith RK, et al. Pathophysiology of primary spinal syringomyelia. *J Neurosurg Spine* 2012;17(5):367–80.
- [16] Kameyama T, Hashizume Y, Ando T, Takahashi A, Yanagi T, Mizuno J. Spinal cord morphology and pathology in ossification of the posterior longitudinal ligament. *Brain* 1995;118:263–78.
- [17] Fischbein NJ, Dillon WP, Cobbs C, Weinstein PR. The “presyrinx” state: is there a reversible myelopathic condition that may precede syringomyelia? *Neurosurg Focus* 2000;8:E4.
- [18] Mitsunaga LK, Klineberg EO, Gupta MC. Laminoplasty techniques for the treatment of multilevel cervical stenosis. *Adv Orthop* 2012;307916.
- [19] Yonenobu K, Wada E, Suzuki S, Kanazawa A. The dorsal approach in degeneratively changed cervical spine. *Orthopade* 1996;25:533–41.
- [20] Yoon ST, Hashimoto RE, Raich A, Shaffrey CI, Rhee JM, Riew KD. Outcomes after laminoplasty compared with laminectomy and fusion in patients with cervical myelopathy: a systematic review. *Spine* 2013;38:S183–94.