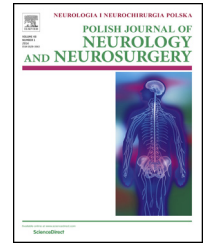


Available online at www.sciencedirect.com

ScienceDirect

journal homepage: <http://www.elsevier.com/locate/pjnns>

Original research article

The effectiveness of Penumbra 400 micro-coils in the embolization of large cerebral aneurysms



Tadeusz Jan Popiela^{a,*}, Paweł Brzegowy^a, Bartłomiej Łasocha^b,
Andrzej Urbanik^a

^aChair of Radiology, Jagiellonian University Collegium Medicum, Krakow, Poland

^bTrauma Center Diagnostic Imaging Unit, University Hospital, Krakow, Poland

ARTICLE INFO

Article history:

Received 15 September 2016

Accepted 3 May 2017

Available online 18 May 2017

Keywords:

Intracranial aneurysm

Embolization

Packing density

Recanalization

Radiation exposure

ABSTRACT

Background: The objective of this work is to analyze the effectiveness of Penumbra 400 micro-coils in the embolization of large cerebral aneurysms.

Material and methods: A retrospective analysis has been conducted in a group of 32 patients at the average age of 54.5 years (30–84) for whose embolization the P400 micro-coils (P400) have been used. A control group consisted of 44 patients at the average age of 52.7 years (24–82) in whose aneurysm embolization the 18 micro-coils (MC) have been utilized.

Results: The respective percentages of micro-coil packing density in aneurysm sacs were 31.5% for P400 and 29% for MC. The average P400 fluoroscopy time was 21 min, and 34 min in case of MC. The average number of used micro-coils was 3.9 for P400 and 5.6 for MC. The radiation dose received by a patient was 1.7 Gy/2.2 Gy, respectively. The recanalization of P400 has occurred in 14/31 cases (45%), and for MC it has occurred in 23/44 (52%) patients. One patient died due to early recanalization after P400 aneurysm embolization.

Conclusion: Procedures with use of the P400 demonstrate minimally higher effectiveness of large aneurysms embolization in comparison with the MS with a not much shorter duration and reduction of a radiation dose that a patient receives.

© 2017 Polish Neurological Society. Published by Elsevier Sp. z o.o. All rights reserved.

1. Background

It is believed that occurrence of recanalization in long-term follow up is connected mostly with a primary low packing density of coils in the aneurysm sac expressed as a percentage of closing aneurysm volume using given coils [1–4]. This appears to be particularly important in case of large aneurysms.

The above encourages works on developing coils of greater softness and volume. Such features can be found in the new generation of Penumbra 400 (P400) coils that was first introduced in 2011. Due to the largest primary diameter, amounting to 0.020 in. when compared to other available coils, they were mostly supposed to treat large aneurysms.

At the same time, taking into consideration quite a unique thickness of the primary coil, the Penumbra devices can be

* Corresponding author at: Angiography and Interventional Radiology Lab, Diagnostic Imaging Unit of the Kraków University Hospital Trauma Center, Botaniczna st. 3, Kraków, Poland. Tel.: +48 12 424 8688.

E-mail address: msjpopie@cyf-kr.edu.pl (T.J. Popiela).

<http://dx.doi.org/10.1016/j.pjnns.2017.05.002>

0028-3843/© 2017 Polish Neurological Society. Published by Elsevier Sp. z o.o. All rights reserved.

characterized by an increased ratio of the coil volume to the length of coil which is 400% more than conventional coils of a thickness of 0.010", and 178% for the 0.015" coils [5]. In conclusion, it seems that the use of even smaller quantities of P400 coils should ensure their higher packing density in the aneurysm sac and thus its better protection against recanalization.

In so far not very numerous publications on the subject matter, the effectiveness of P400 coils compared to standard coils with a thickness of 0.010–0.012" was described. The aim of this study is to analyze the effectiveness of P400 versus so-called 18 coils (MC), i.e. of a thickness from 0.014 to 0.015, in the embolization of large aneurysms.

2. Material and methods

We have retrospectively analyzed a group of 32 patients at a mean age of 54.5 (30–84) years in whom embolization was performed using P400 micro-coils. The control group has consisted of 44 patients at an average age of 52.7 years (24–82) and in whose aneurysm embolization 18 micro-coils were used. The latter's initial fiber diameter was ranging from 0.014 to 0.015 in. In all cases, the treatment applied to aneurysms whose sacs were equal or larger than at least 10 mm in one dimension. All the procedures were performed in the period from 1 January 2012 until 1 June 2015.

The study excluded cases in which other coils than herewith analyzed had been additionally used for embolization. Also, we have not taken into consideration those patients in whom the analyzed coils were used to complete or supplement previous embolization procedures performed with other equipment. The treatments were performed by three experienced interventional neuro-radiologists whose main objective was to achieve a maximum packing density of micro-coils in the aneurysm sac. In case of P400 coils, the delivery micro-catheter was the PX slim recommended by Penumbra, with a distal diameter of 2.6 F. For the control group, 1.7 F micro-catheters were utilized.

For the analysis purposes of the aneurysm sac volume, micro-coils utilized and their packing density, we have used the AngioCalc software that is available via Internet and widely accepted by micro-coils manufactures (<http://www.angiocalc.com>).

The procedure time has been calculated from first angiographic run to the time of the last control acquisition after the treatment. Additionally, we have calculated it on the basis of the total time of exposure of the patient to ionizing radiation which was counted automatically by the vascular X-ray device software from the start of patient registration to the end of the study (fluoroscopy time). The same software was also used to measure the total radiation dose received by a patient during the treatment procedure.

The first check digital subtraction angiography (DSA) has always been performed at the end of embolization. Another follow-up imaging test in the form of DSA or MR angiography was done 6 months after the treatment. In assessing the effectiveness of embolization, we have utilized the Raymond Roy Occlusion Classification (RROC) scale [6]:

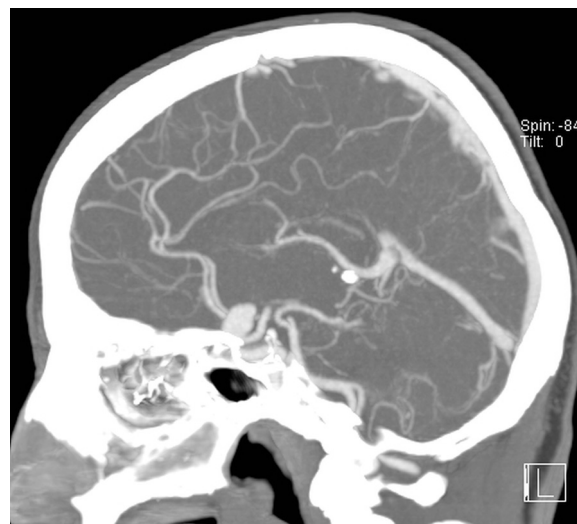


Fig. 1 – Initial CT angiography: there is a saccular aneurysm near the tip of the carotid artery on the left.

- I. Aneurysm sac has not been contrasted.
- II. Only neck/base of aneurysm sac has been contrasted.
- III. Aneurysm sac has been contrasted.

Qualifying an aneurysm sac within a follow up into one of the first two RROC groups, i.e. I–II, has been considered a therapeutic success (Figs. 1–4).

3. Results

All the treated patients were over 50 years old, and women dominated in both the groups. The vast minority of procedures were performed due to subarachnoid hemorrhages, with

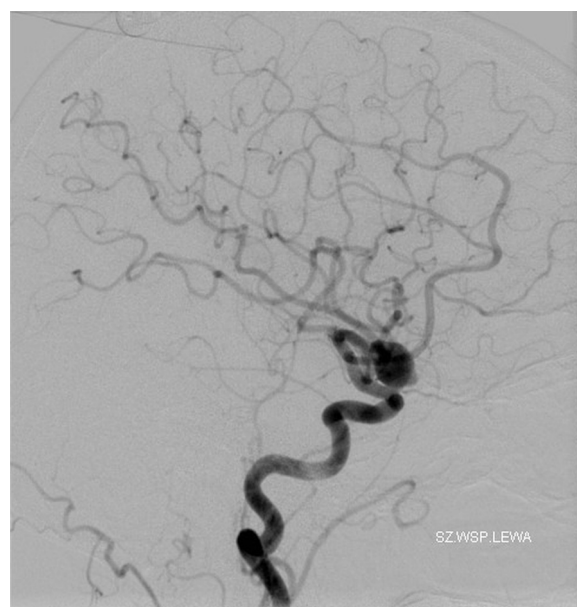


Fig. 2 – Pre-embolization angiography: a large optic artery aneurysm is visible.

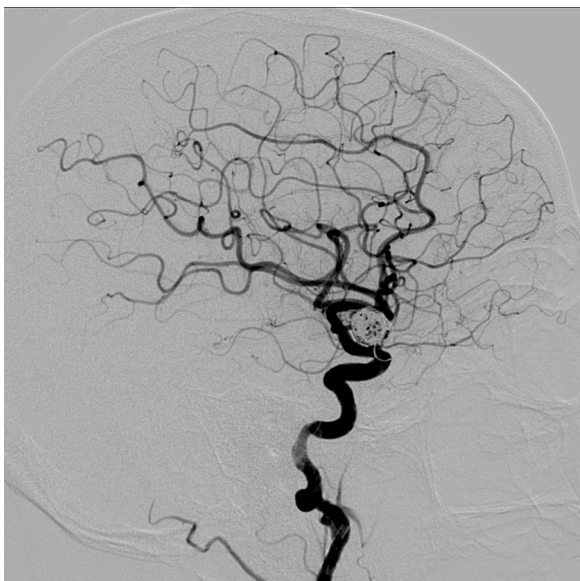


Fig. 3 – Post-embolization angiography depicts a prolapsing tip of the last coil. Antiplatelet treatment with 150 mg of aspirin daily was introduced.

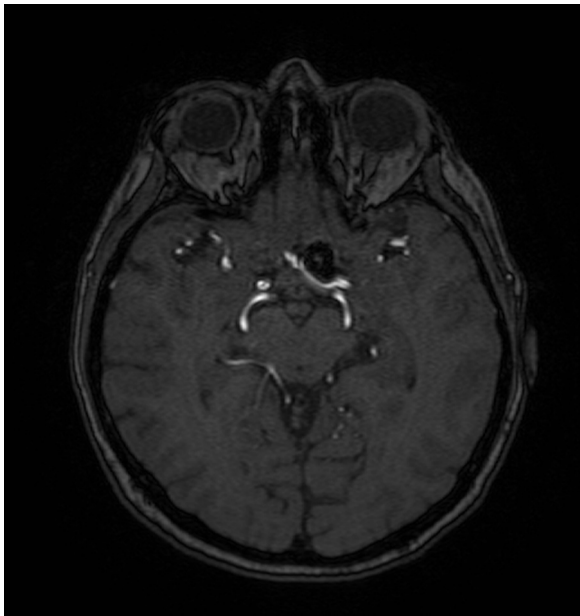


Fig. 4 – MR angiography, follow up exam, performed 18 months after embolization shows complete occlusion of the aneurysm with preserved flow in the parent vessel.

exceeding 80% of patients who were treated electively in the two groups. Because of the wide aneurysm neck in, respectively 2, (6%) and 6 (14%) patients in the P400 and MC groups, the embolization has been complemented by the implantation of intracranial stents of the LVIS Jr., Leo baby or Solitaire AB type. Furthermore, in 5 (16%) and 12 (27%) patients of the P400 and MS groups, Scepter C or XC balloons were used to cover the aneurysm neck during the deployment of micro-coils.

In one case – following the embolization with P400 micro-coils of a ruptured aneurysm arising from the basilar artery (the neck located between the left superior cerebellar artery and the left posterior cerebral artery), as well as the aneurysm neck protection with the Solitaire stent – a hemorrhage occurred on the second day after that intervention. A control angiography revealed a previously invisible additional aneurysm chamber below the lower outline of the previously embolized aneurysm sac. In spite of several attempts, the catheterization failed. The said contrast staining ceased to appear only after the introduction of 2 flow diverting stents. The lack of possibility for re-catheterization of the aneurysm sac was caused by the P400 packing density which, at the same time, did not protect against the leakage of blood to the newly visualized chamber (Figs. 5–8).

In 1 (3%) case of the P400 treatment and in 3 (7%) patients with MC, the terminal loops of micro-coils migrated from the aneurysm sac into the parent vessel, which in two patients with the MC was the reason for the introduction a Leo Baby stent. This result does not differ from other similar analyses [7].

In 5 (15.6%) cases, the P400 embolization failed to be performed due to impossibility of the aneurysm sac catheterization with the PX Slim delivery catheter. Such types of problems have not occurred in the control group for which 1.7 F Excelsior SL-10 or Headway 17 Advanced micro-catheters were used.

In the P400 group, most aneurysms were located in the anterior circulation, while in the MS 18 group they were mostly found in its posterior part. Due to the assumed criteria for the selection of patients, the two groups were dominated by aneurysms of large sacs whose average volume was around 1000 mm³, ranging respectively from 940 mm³ to 1240 mm³ for the P400 and MC groups. The diameter of the largest sacs reached 25 mm in both the groups (see Table 1).

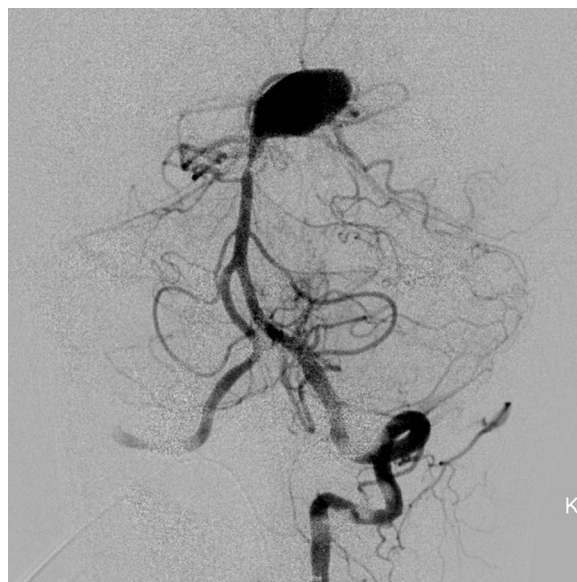

Fig. 5 – Another patient, angiography after acute subarachnoid hemorrhage: a giant aneurysm between superior cerebellar artery and posterior cerebral artery.

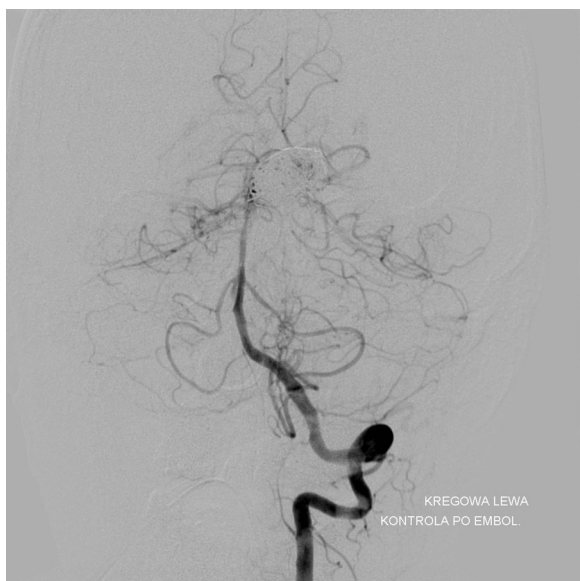

Fig. 6 – The same patient, angiography performed immediately after treatment. The aneurysm appears completely embolized.

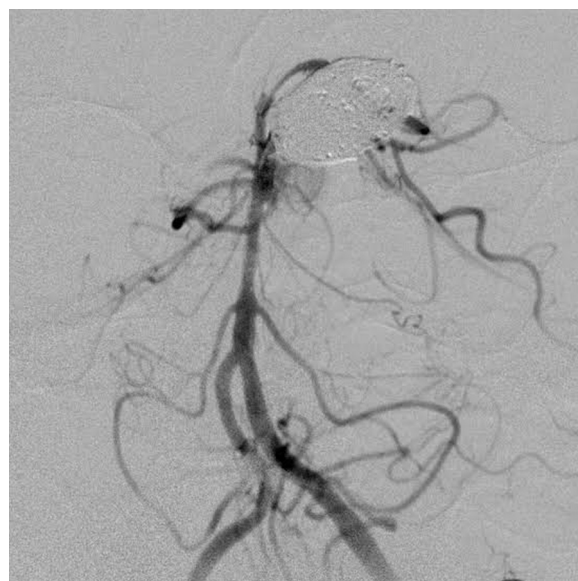


Fig. 8 – Two flow diverting stents enabled stasis in the aneurysm sac.

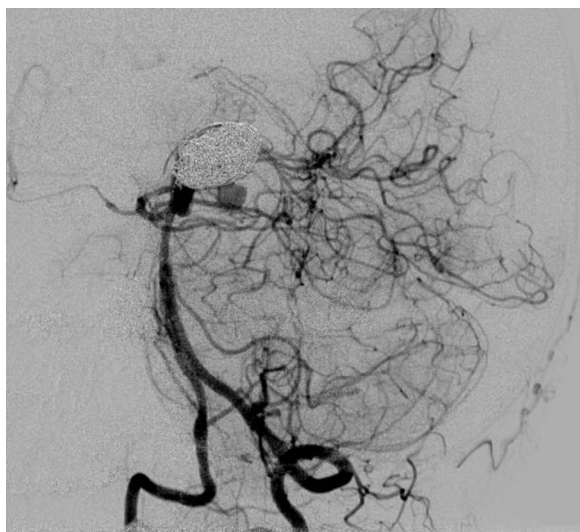

Fig. 7 – Two days later the patient rebled. Another compartment of the aneurysm is visible.

Despite significant differences in the number of introduced micro-coils, i.e. averagely 3.9 and 5.6, we achieved a similar result taking into account the micro-coil packing density which amounted to 31.5% in the P400 and 29.1% for the MC group.

The treatment duration time also differed quite significantly because, considering the whole procedure, it was an average of 115 min in the P400, while in the MC it was even up to 160 min. A similar result was achieved when a total fluoroscopy time itself was measured. It was also shorter for P400, i.e. 21 min compared to 34 min in the control group. The total exposure time is directly related to the total radiation dose absorbed by a patient, and it amounted from 1.7 Gy for the P400 to 2.2 Gy in the MC group.

Follow up examinations were conducted in all the patients with the P400 micro-coil embolization procedures performed, except in one case of the fore-said patient who died because of the re-hemorrhage. In the MC micro-coil embolization group, we screened 33 patients representing 75% of the original control group. Having analyzed the results of these studies, we found that more than a half of the patients treated with the Penumbra micro-coils, i.e. 17 (55%), were qualified to the RROC I-II groups, while in the MC group there were 16 (48%) such patients. Thus, the difference was not statistically significant (see [Table 2](#)).

4. Discussion

At the end of November 2015, only a few reports on the use of the P400 type in the embolization of cerebral aneurysms were available [7]. None of these reports compared the use of 18 type micro-coils available in the market as the largest in primary diameter after the P400. In order to ensure the homogeneity of the groups analyzed in the study, only large aneurysms were qualified in which at least one dimension was 10 mm or more. Furthermore, for the analysis purposes only those cases have been chosen in which the embolization procedures did not use different micro-coils but only those of the subject two types.

Given the volume of the used micro-coils, and also a similar volume of aneurysm sacs that were undergoing their embolization in both the groups, it is not surprising that a difference in the number of used coils is favorable to the P400 type which amounted to 3.9 while in case of MC the result was 5.5 coils. This result is consistent with reports of other authors who utilized 3.53 P400 micro-coils versus 5.44 in the control group which used the micro-coils of varying thicknesses [7,8].

Most researchers stress that with fewer P400 micro-coils higher packing density in the embolization of aneurysm sacs

Table 1 – The characteristics of analyzed groups.

	P400 (32 patients)	MS18 (44 patients)
Age	54.5 (30–84)	52.7 (24–82)
Sex (M/F)	11 (34%)/21 (66%)	21 (48%)/23 (52%)
Ruptured aneurysm	6 (19%)	7 (16%)
Elective treatments	26 (81%)	37 (84%)
Stent remodeling	2 (6%)	6 (14%)
Balloon remodeling	5 (16%)	12 (27%)
Aneurysm location		
Basilar artery	6 (19%)	23 (53%)
Vertebral artery/PICA	3 (9%)	3 (6%)
Internal carotid artery/posterior communicating artery	19 (59%)	15 (35%)
Anterior communicating artery	4 (13%)	2 (4%)
Medial cerebral artery	–	1 (2%)
Aneurysm sizes		
Volume	1240 mm ³ (120–4900 mm ³)	940 mm ³ (154–4120 mm ³)
Largest aneurysm diameter	25 mm	25 mm

Table 2 – The comparison of results depending on micro-coils applied.

	P400 (32 patients) Average ± SD (min–max)	MS18 (44 patients) Average ± SD (min–max)	Student's t-test
Number of used micro-coils	3.9 ± 1.0 (2–7)	5.6 ± 1.4 (3–10)	<i>p</i> = 0.005
Packing density volume [%]	31.5 ± 3.8 (22–37)	29.1 ± 3.3 (22–35)	<i>p</i> < 0.001
Procedure time [min]	115 ± 22.6 (90–170)	160 ± 33.7 (90–210)	<i>p</i> < 0.001
Total fluoroscopy procedure time [min]	21 ± 7.7 (14–45)	34 ± 5.3 (27–42)	<i>p</i> < 0.001
Radiation dose received by a patient [Gy]	1.7 ± 0.6 (1.1–3.4)	2.2 ± 0.7 (1.1–3.5)	<i>p</i> = 0.002
Complications	N (%)	n (%)	Yates-corrected Chi ²
Hemorrhages	1 (3%)	–	<i>p</i> = 0.872
Coil loop migration	1 (3%)	3 (7%)	<i>p</i> = 0.848
Control tests (RROC)			
I–II	17/31 ^a (55%)	21/44 (48%)	<i>p</i> = 0.816
III	14/31 (45%)	23/44 (52%)	<i>p</i> = 0.816

^a One patient died within 48 h after treatment.

was achieved as compared to control groups. Thus, Milburn [9] showed the P400 packing volume density at 33.7% versus 24.4%, while Mascitelli [8] showed 31.7% versus 24.8%, and Kaesmacher [7] – for aneurysms with a diameter above 7 mm – showed 42.2% versus 27.8%. These quoted numbers do not exactly correspond to the results obtained in this very work. It is true that the advantage of P400 over the control group is still visible, i.e. 31.5% versus 29.1%, but it is not as clear as in the above-cited works. This may be a result of the application of only 18-type micro-coils for the control group, and also because these coils possess relatively large filaments and are offered in a wide range of types, including so called “softs”, i.e. soft micro-coils with which one can complete the procedure by filling empty spaces around an aneurysm sac base. At the same time, it must be emphasized that a packing density in the range of 20–31% is considered as an effective protection against potential compaction of coils and a subsequent recanalization of aneurysms [7,11,12].

The duration of a procedure referred to in the literature varies between 48 and 167 min for the P400 versus 64 and 139 min in control groups [7,8]. In the hereby analyzed study,

the procedure time was in the range indicated by other authors, i.e. 115 min for the P400 versus 160 min in the control group. The difference probably resulted from a larger volume aneurysms in relation to other authors, which necessitated the use of more micro-coils and thus the elongation of a procedure time. On the other hand, the fact that in the study group we did not use other micro-coils than P400, did not force us to change a delivery micro-catheter, which, in other authors cited above, prolonged the procedure. Additionally, in the present study we have analyzed the overall working time resulting from the application of fluoroscopy, which should also have a direct impact on the total dose of ionizing radiation received by a patient. While the difference in fluoroscopy was significant, averaging at 21 min versus 34 min for P400 versus MC, respectively (*p* < 0.001), the difference in the calculated radiation doses was present though statistically not significant, i.e. 1.7 Gy versus 2.2 Gy, respectively. The obtained results confirm that a radiation dose depends not only upon a given exposure time but also upon magnification and a field which is irradiated. Especially acquisitions performed with projections other than the antero-posterior or lateral ones

increase the dose of radiation received. Still, this was not the subject of this study and therefore it requires further dedicated analyses.

For the analysis of the results of control examinations, taking into account the latest reports [10] suggesting that the results of several years back in the RROC I and II groups are similar, it has been assumed that a failure of embolization shall be considered only the cases classified into group RROC III. And so, Milburn [9] qualified as a clinical success 56% of patients versus 55%, Mascitelli [8] 79.5% versus 77.2%, and Kaesmacher [7] – for aneurysms with a diameter bigger than 7 mm – reported 76.2% versus 47.6%, respectively. A positive result achieved in this study, which is 53% for the P400 and 48% for the control group, is comparable to that presented by Milburn [9] and significantly smaller than reported by the other previously mentioned authors. It should be noted that in both the quoted studies the treatments were performed only with the same micro-coils, contrary to the remaining studies in which during the P400 embolization also other micro-coils were used. It was similar in control groups for which micro-coils of different diameters were used. Therefore, in all these cases it is difficult to define the unequivocal maintaining of homogeneity in the analyzed groups. Subsequently, the results achieved by Milburn [9] correspond better to those achieved by our team.

In one case – following the embolization with P400 micro-coils of a ruptured aneurysm arising from the basilar artery (the neck located between the left superior cerebellar artery and the left posterior cerebral artery), as well as the aneurysm neck protection with the Solitaire stent – a hemorrhage occurred on the second day after that intervention. A control angiography revealed a previously invisible additional aneurysm chamber below the lower outline of the previously embolized aneurysm sac. In spite of several attempts, the catheterization failed. The said contrast staining ceased to appear only after the introduction of 2 flow diverting stents. The lack of possibility for re-catheterization of the aneurysm sac was caused by the P400 packing density which, at the same time, did not protect against the leakage of blood to the newly visualized chamber (Figs. 5–8).

In 1 (3%) case of the P400 treatment and in 3 (7%) patients with MC, the terminal loops of micro-coils migrated from the aneurysm sac into the parent vessel, which in two patients with the MC was the reason for the introduction a Leo Baby stent. This result does not differ from other similar analyses [7].

In 5 (16.5%) patients, we failed to catheterize the aneurysm sac with PX Slim. In all the cases, the problem was the increased stiffness and diameter of a micro-catheter, which, with winding and narrow arteries, made its effective maneuverability impossible. For all these cases, the use of 1.7 F diameter micro-coils solved the problem and allowed to conduct the embolization procedure.

5. Conclusion

The use of P400 micro-coils in the embolization of large aneurysm gives a high percentage of micro-coils packing density volume and, at the same time, reduces their number, which results in a faster examination, and hence reduces a

radiation dose that a patient receives during the procedure. At the same time, the complication rate is comparable to a control group.

It shall be further emphasized that a difference between the P400 and the MC in terms of the micro-coil packing density, a received radiation dose, is not significant statistically. Also, the percentage of recanalization reported between the two groups was similar, i.e. 47% versus 52%.

Thus, we can state that from the point of view of a radiologist it actually does not matter which micro-coils are used because final results are quite similar. In addition, one needs to take into consideration that in case of a narrow and tortuous vessels the use of a delivery PX microcatheter is much more difficult and reduces a possibility of using this very type of micro-coils.

An open issue, not taken into account in this study, although very important in Polish conditions, is the cost and speed of an evaluated procedure financial refunding, which, however, requires a separate analysis.

Conflict of interest

None declared.

Acknowledgment and financial support

The authors declare the study was funded by departmental resources.

Ethics

The work described in this article has been carried out in accordance with The Code of Ethics of the World Medical Association (Declaration of Helsinki) for experiments involving humans; Uniform Requirements for manuscripts submitted to Biomedical journals.

REFERENCES

- [1] Satoh K, Matsubara S, Hodoh H, Nagahiro S. Intracranial aneurysm embolization using interlocking detachable coils: correlation between volume embolization and coil compaction. *Intervent Neuroradiol* 1997;3:125–9.
- [2] Tamatani S, Ito Y, Abe H, Koike T, Takeuchi S, Tanaka R. Evaluation of the stability of aneurysms after embolization using detachable coils: correlation between stability of aneurysms and embolized volume of aneurysms. *AJNR* 2002;23:762–7.
- [3] Uchiyama N, Kida S, Nomura M, Hasegawa M, Yamashima T, Yamashita J, et al. Significance of volume embolization ratio as a predictor of recanalization on endovascular treatment of cerebral aneurysms treated with Guglielmi detachable coils. *Intervent Neuroradiol* 2000;6:59–63.
- [4] Kawanabe Y, Sadato A, Taki W, Hashimoto N. Endovascular occlusion of intracranial aneurysms with Guglielmi detachable coils: correlation between coil packing density and coil compaction. *Acta Neurochir* 2001;143:451–5.

- [5] White JB, Ken CG, Cloft HJ, Kallmes DF. Coils in a nutshell: a review of coil physical properties. *AJNR* 2008;29:1242-6.
- [6] Roy D, Milot G, Raymond J. Endovascular treatment of unruptured aneurysms. *Stroke* 2001;32:1998-2004.
- [7] Kaesmacher J, Müller-Leisse Ch, Huber T, Boeckh-Behrens T, Haller B, Shibani E, et al. Volume versus standard coils in the treatment of intracranial aneurysms. *J Neurointervent Surg* 2015;0:1-8.
- [8] Mascitelli JR, Patel AB, Polykarpou MF, Patel AA, Moyle H. Analysis of early angiographic outcome using unique large diameter coils in comparison with standard coils in the embolization of cerebral aneurysms: a retrospective review. *J Neurointervent Surg* 2014;1-5.
- [9] Milburn J, Pansara AL, Vidal G, Martinez RC. Initial experience using the Penumbra coil 400: comparison of aneurysm packing, cost effectiveness, and coil efficiency. *J Neurointervent Surg* 2014;6:121-4.
- [10] Mascitelli JR, Oermann EK, De Leacy RA, Moyle H, Patel AB. Angiographic outcome of intracranial aneurysms with neck remnant following coil embolization. *J Neurointervent Surg* 2015;7:484-9.
- [11] Leng B, Zheng Y, Ren J, Xu Q, Tian Y, Xu F. Endovascular treatment of intracranial aneurysms with detachable coils: correlation between aneurysm volume, packing, and angiographic recurrence. *J Neurointervent Surg* 2014;6:595-9.
- [12] Mascitelli JR, Oermann EK, De Leacy RA, Moyle H, Mocco J, Patel AB. Predictors of treatment failure following coil embolization of intracranial aneurysms. *J Clin Neurosci* 2015;22:1275-81.