

Available online at www.sciencedirect.com

ScienceDirect

journal homepage: <http://www.elsevier.com/locate/pjnns>

Original research article

Magnetic resonance imaging and histology correlation in Cushing's disease



Václav Masopust^{a,*}, David Netuka^a, Vladimír Beneš^a, Martin Májovský^a,
Tomáš Belšán^b, Ondřej Bradáč^a, Daniel Hořínek^c, Mikuláš Kosák^d,
Václav Hána^d, Michal Kršek^d

^aDepartment of Neurosurgery and Neurooncology, 1st Faculty of Medicine, Charles University and Central Military Hospital, Prague, Czechia

^bDepartment of Radiology, Central Military Hospital, Prague, Czechia

^cDepartment of Neurosurgery, Faculty Hospital, Ústí nad Labem, Czechia

^d3rd Department of Medicine, 1st Faculty of Medicine, Charles University, Prague, Czechia

ARTICLE INFO

Article history:

Received 10 February 2016

Received in revised form

3 August 2016

Accepted 21 October 2016

Available online 2 November 2016

Keywords:

Pituitary adenoma

Endoscopic resection

Magnetic resonance imaging

ABSTRACT

Introduction: We continuously look for new techniques to improve the radicality of resection and to eliminate the negative effects of surgery. One of the methods that has been implemented in the perioperative management of Cushing's disease was the combination of three magnetic resonance imaging (MRI) sequences: SE, SPGR and fSPGR.

Material and methods: We enrolled 41 patients (11 males, 30 females) diagnosed with Cushing's disease. A 3D tumour model with a navigation console was developed using each SPGR, fSPGR and SE sequence. The largest model was then used. In all cases, a standard four-handed, bi-nostril endoscopic endonasal technique was used. Endocrinological follow-up evaluation using morning cortisol sampling was performed for 6–34 months in our study.

Results: In total, 36 patients (88%) were disease-free following surgery. Our results indicate we achieved 100% sensitivity of MR. Overall, the conformity of at least one donor site, as compared with the places designated on MR, was in 78% of patients. We searched the place of compliance in individual locations. There is a consensus in individual locations in 63 of the 123 cases (or 56%). The correlation gamma function at a 5% significance level was then 0.27.

Discussion: The combination of MR sequences (SE, SPGR, fSPGR), neuronavigation system and iMRI led to increased sensitivity of up to 100%. Specificity reached 56% in our study.

Conclusion: We found a high success rate in surgical procedure in terms of the correlation between MR findings and histology, which leads to remission of Cushing's disease.

© 2016 Published by Elsevier Sp. z o.o. on behalf of Polish Neurological Society.

* Corresponding author at: Department of Neurosurgery and Neurooncology, Central Military Hospital, U vojenské nemocnice 1200, Prague 16200, Czechia. Tel.: +420 973202961; fax: +420 973202933.

E-mail address: masopust@uvm.cz (V. Masopust).

<http://dx.doi.org/10.1016/j.pjnns.2016.10.005>

0028-3843/© 2016 Published by Elsevier Sp. z o.o. on behalf of Polish Neurological Society.

1. Introduction

Cushing's disease or central Cushing's syndrome is a condition of an increase in cortisone in the blood level caused by a benign pituitary tumour secreting adrenocorticotropic hormone (ACTH). In 1910, Harvey Cushing performed the first transsphenoidal surgery for pituitary adenoma using sublabial incision [1,2]. However, in 1925, Cushing replaced the transsphenoidal approach with the transcranial approach. Cushing's disease was first described by Harvey Cushing in 1932 [3]. Since then, pituitary surgery has undergone considerable development. The sublabial transsphenoidal approach was not forgotten largely thanks to the work of N. Dott and G. Guiot. The first transsphenoidal surgery in the Central Military Hospital in Prague was performed by E. Černý in 1972. In May 2006, an endoscopic mononostril technique was introduced at Neurosurgical Department of 1st Medical Faculty of Charles University. Since November 2006, a binostril endoscopic technique was employed and since April 2008, intraoperative magnetic resonance imaging (iMRI) has been used. We keep looking for new techniques to improve the radicality of resection, as well as to eliminate negative effects of surgery. One of the methods, that was implemented in the perioperative management of Cushing's disease, was the combination of three magnetic resonance imaging (MRI) sequences (SE – spine echo, SPGR – spoiled gradient recalled acquisition in steady state and fSPGR – fast spoiled gradient recalled acquisition). Tumour identification sensitivity of the SPGR sequence alone is 76% and specificity 33% [4]. The aim of our study was to correlate sensitivity and specificity of combined MRI with histological findings.

2. Material and methods

2.1. Cohort characteristics

We enrolled 41 patients (30 males, 11 females) diagnosed with Cushing's disease. The average age at the time of diagnosis was 40 years (range 8–78 years). The average age of males was 42 years (range 20–69 years) and of the females 40 years (range 8–78 years). Tumour dimensions were measured using neuronavigation software BrainLab™. The average volume of the tumours was 444 mm³ (range 4–3078 mm³). If we define microadenoma as a tumour smaller than 524 mm³, 36 patients had microadenoma and 5 had macroadenomas in our cohort.

Endocrinological follow-up using morning cortisol sampling was 6–34 months.

2.2. Biopsy samples collection

BrainLab iPLAN NET software was used during the whole surgery. Before surgery, the navigation SPGR sequence with gadolinium enhancement was uploaded to the navigation console. A 3D tumour model was designed using each sequence (i.e. SPGR, fSPGR and SE). The protocol consisted of following sequences. fSPGR 3D:fast AX 3D T1W sekvenca TR 7 ms, TE 4–5 ms, prep time 450 ms, flip angle 20°, NEX 2, slice 1 mm, matrix 256 (freq) × 512 (phase), FOV 25.6 cm, locs per

slab 50, frequency enc. direction AP, scanning time 11:05. SPGR 3D:AX 3D T1W sekvenca TR 23 ms, TE 6–11 ms, flip angle 20°, NEX 1, slice 1.6 mm, matrix 256 × 256, FOV 25.6 cm, locs per slab 60, frequency enc. direction AP, scanning time 4:02. SAG contrast enhanced T1W: 2D Fast SE sekvenca (FSE-XL) TR 420 ms, TE 15 ms, flip angle 90°, ETL 4, NEX 4, slice thickness 2 mm, matrix 384 × 224, FOV 14 cm, 12 slices, frequency enc. direction SI, 10 ml Multihance (Bracco Diagnostic Inc., USA) i.v., scanning time 3:12.

Each MRI was reviewed three times: initial analysis was performed by the radiologist who was on duty on the date of the investigation. The second review was done by the experienced neurosurgeon who was not performing the surgery but has got extensive experience with sellar region analysis on MRI. The third analysis was performed by neuroradiologist with special experience and interest in neuroimaging. Data underwent the final review, tumour volume was depicted and sent into the navigation system.

The Sella turcica was divided horizontally into thirds and labelled zone I (central third), II (left third) and III (right third) (Fig. 1). During surgery, a biopsy sample of minimum diameter (0.50) mm was carefully collected from each zone (I, II, III), leaving healthy adenohypophysis intact (Fig. 2). If healthy adenohypophysis were in the zone of biopsy, a sample from the nearest point was collected. After biopsy samples were harvested, the rest of the tumour was resected using a neuronavigation 3D model. The site of histological specimen removal was stored in navigation system in order to analyse the distance of the histological specimen removal and pituitary adenoma according to preoperative MRI.

Standard analysis of histological specimen was performed. Following investigations were performed: hematoxyllin-eosin stain, Wilder's reticulin stain and immunohistochemical stain for ACTH.

2.3. Surgical technique

All patients underwent surgery under general anaesthesia. In all cases, a standard four-handed, bi-nostril endoscopic endonasal technique was used. In the sella region, a rigid endoscope with 0° optics Karl Storz (180/4 mm), a high-definition HD camera and an Aesculap LED light source were employed. A surgical intradural technique is identical to microscopic surgery. We used blunt dissectors as well as sharp curettes. Eventual bleeding was controlled with haemostatic foam in order to keep good access to the biopsy zones. We tried to identify both tumour and adenohypophysis by endoscope and neuronavigation. In all patients, 3.0T iMRI was performed. Standard MRI follow-up was scheduled on postoperative day 1, day 90 (3 months), 9 months after and then periodically once a year.

3. Results

- (A) Disease remission during the follow-up period and correlation between MRI and histology
 (1) In total, 36 patients (88%) were disease-free after surgery.

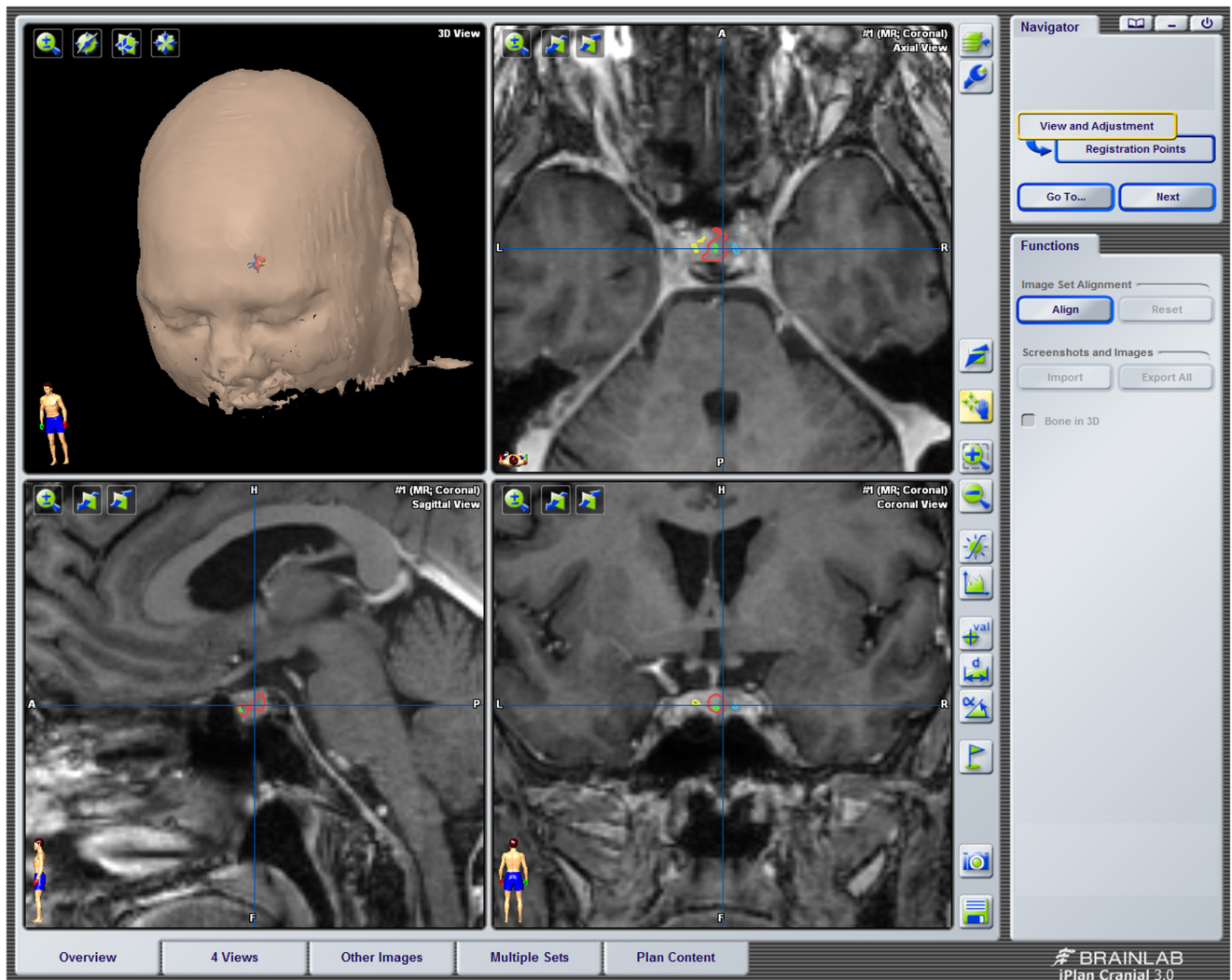


Fig. 1 – Plan – free thirds.

- (2) Full concordance between MRI and histological findings (i.e. all sites positive according to MRI were positive according to histology and vice versa, all negative sites according to MRI were negative according to histology) occurred in 8 cases (20%). In these 8 cases, disease remission was achieved in all 8 patients and the morning cortisol level was 23–462 nmol/l (Fig. 3).
- (3) No agreement between MRI findings and histology (i.e. there was a different adenoma location than according to MRI) was observed in 9 patients (22%).
- (4) The agreement on one point or more but not a complete match between MRI sites of adenoma and histological findings occurred in 24 patients (58%). Overall, the conformity of at least one donor site, in comparison with the places designated (the sum of the full match and at least one point of compliance) on MRI, occurred in 78% of the patients.
 - (a) Larger histology findings than those displayed on the MRI (i.e. there were positive samples from peripheral areas outside the findings displayed on MRI – tumour exceeded the area shown on MRI by

histology) was observed in 21 patients, i.e. 51%. In case of histology findings larger than the findings displayed on the MRI, then normalisation of morning serum cortisol level was observed at 19 in 21 patients (i.e. 90%). In these cases serum cortisol was between 6 nmol/L and 551 nmol/L in the follow-up period. Surgery was unsuccessful in two patients with histological findings exceeding the MRI findings. Their endocrinological levels were 649 nmol/L and 870 nmol/L.

There were 8 cases of full concordance of MRI and histological findings and 21 cases when histology was exceeding the MRI findings.

- (b) Less extensive histology findings (i.e. there were negative samples taken in place of MRI findings) were found in three patients (7%). If the histology were less extensive (i.e. there were negative samples taken in place of MRI findings or not any positive sample), then there was endocrinological remission in 1 of the 3 cases (33%) (Figs. 6 and 7).

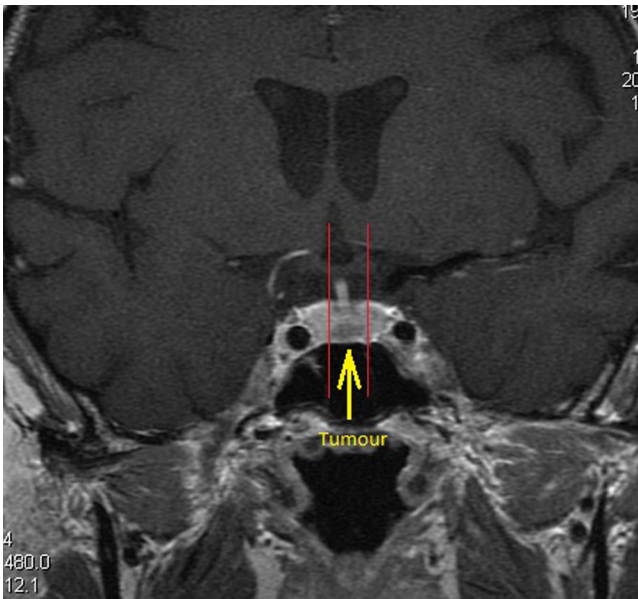


Fig. 2 – MR after surgery – histology I, II, III.

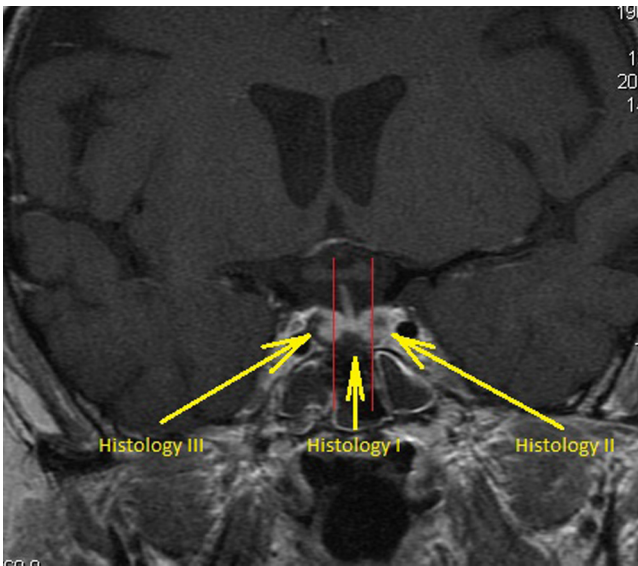


Fig. 3 – Full agreement between magnetic resonance imaging findings and histological evaluation.

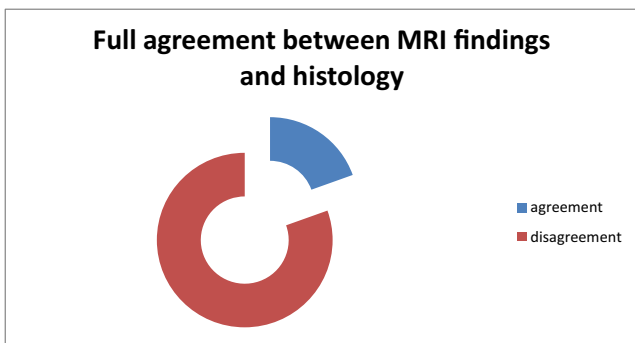


Fig. 4 – Match between magnetic resonance imaging findings and histological evaluation.

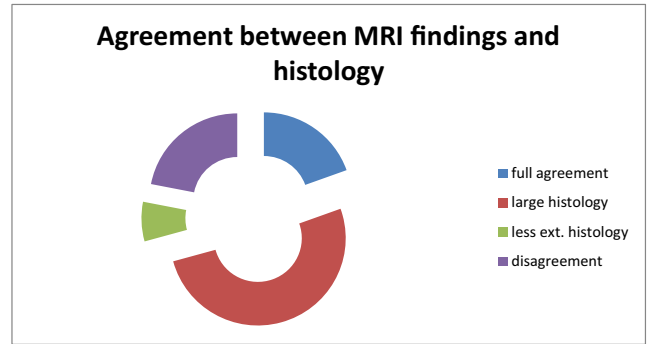


Fig. 5 – Match between magnetic resonance imaging findings and histological evaluation – more detail.

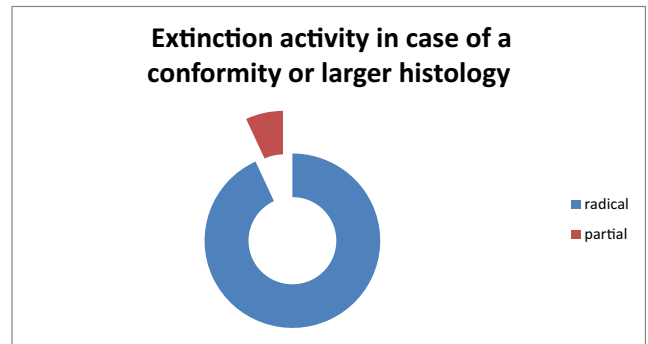


Fig. 6 – Extinction morning serum cortisol activity in case of conformity or larger histology findings than magnetic resonance imaging findings in the follow-up period.

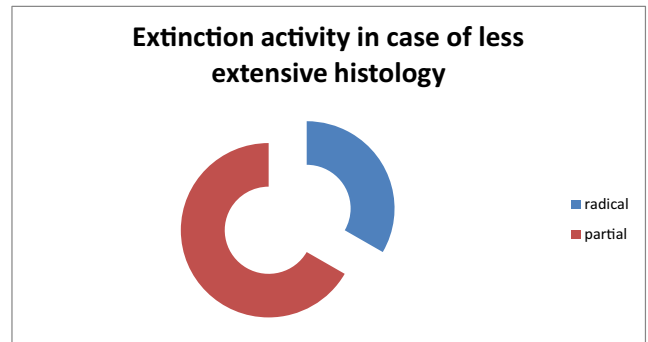


Fig. 7 – Extinction morning serum cortisol activity in case of less extensive histology findings than magnetic resonance imaging findings in the follow-up period.

(B) The agreement on individual points between findings on MRI and histological findings.

Each sampling area was shared and compared with similar areas of histological positivity for statistical calculations. We searched places of consensus in various areas (Table 1).

There is a consensus in individual locations in 63 of the 123 cases, i.e. 56%, as seen from Table 2.

Correlation gamma at the 5% significance level was then 0.27. Full compliance (i.e. all combinations consensus) was reached in only 20% per cent of cases (Table 3).

Table 1 – PivotTable on the agreement between MRI and histology findings.

PivotTable (correlation)			
The frequency of labelled cells > 10 (marginal totals are not labelled)			
MR	Histology	Histology	Line totals
	0	1	
0	20	40	60
1	14	49	63
All groups	34	89	123

Table 2 – The correlation gamma of a conformity of individual measuring points according to MRI and histology findings.

Gamm correlation (correlation)	
CHD dropped in pairs	
Ref. Correlations are significant in the hl. $p < .05000$	
MR	Histology
1.000000	0.272727
0.272727	1.000000

4. Discussion

In 1910, Harvey Cushing performed the first transsphenoidal surgery for pituitary adenoma using sublabial incision [1,2]. In 1925, Cushing replaced the transsphenoidal approach with the transcranial approach. The sublabial transsphenoidal approach continued to be used because of the work of N. Dott and G. Guiot. Dott and Guiot not only adopted the transsphenoidal technique but also introduced intraoperative fluoroscopy. In the same period, J. Hardy made an important breakthrough in pituitary surgery using an operative microscope, which led to the resurrection of the sublabial approach [5].

The first transsphenoidal pituitary surgery in the Central Military Hospital in Prague was performed by E. Černý in 1972. This technique was later improved by I. Fuks and eventually became a standard procedure [6]. In May 2006, the endoscopic endonasal monostril approach was introduced in the Neurosurgical Department of the 1st Medical Faculty of Charles University. Since November 2006, the binostril endoscopic endonasal technique was employed [7]. The arrival of intraoperative magnetic resonance imaging (iMRI) in April 2008 enabled increased radicality in pituitary surgery [8,9].

Four therapeutic modalities are currently available for sellar lesions: observation, neurosurgery, pharmacological

treatment and radiosurgery (Leksell Gamma Knife (LGK) is used in the Czech Republic). These four modalities are more complementary than they are contradictory. Modern surgical techniques clearly lead to increased radicality and a decrease in adverse effects [10].

Radicality is of great importance when evaluating any surgical procedure; in the case of hormonal active adenomas, radicality is defined as a hormone level decrease. To achieve higher radicality, new diagnostic methods are available. For Cushing's disease, diagnosis and adenoma localisation and selective cavernous sinus catheterisation were used. One of the largest studies that tried to show an advantage of cavernous sinus catheterisation over MRI occurred over 20 years ago, in 1994. This paper included 20 patients: catheterisation was unsuccessful in three (12%) of the 20 patients. Concordance of lateralisation of sinus sampling and tumour localisation during surgery were observed in 7 out of 11 (64%) patients without corticotropin-releasing hormone (CRH) stimulation and in 8 out of 11 (73%) patients after CRH stimulation. In 3 out of 12 (25%) patients, lateralisation changed after CRH stimulation [11]. Catheterisation is no longer in practise today because of the arrival of modern imaging techniques such as MRI, computed tomography (CT), positron emission tomography (PET) and sonography.

One study concerning sonographic diagnosis examined 68 patients with negative or inconclusive MRI results. Intraoperative ultrasonography identified tumours in 47 (69%) patients with a negative MRI finding. In three of these 47 patients, no tumour was found by the pathologist in the biopsy sample. Considering the difficult implementation of ultrasound in the surgical process and the need for relatively extensive skills, sonography offers only a more precise localisation of the tumour, but cannot measure the extent and size of the lesion [12]. Based on the above-mentioned data, the best diagnostic option is MRI with an SPGR sequence. One recent paper compared the sequence MRI SPGR, MRI SE and high-resolution positron emission tomography (hrPET). Ten patients were included in that study. MRI identified adenoma in four (40%) patients using SE and in seven (70%) patients using SPGR.

18F-fluorodeoxyglucose (F-FDG) hrPET diagnosed adenoma in four (40%) patients with tumour size 3–14 mm. Thus, hrPET was able to identify small, hormonally active adenomas in Cushing's disease better than SE MRI but not better than SPGR MRI [13]. In conclusion, SPGR MRI thus far is the most effective diagnostic method in Cushing's disease. What is still unknown is whether SPGR is precise enough to allow surgery.

As stated earlier in this paper, SPGR identifies adenoma very well. We do not know how specific and precise it is in diagnosing the extent of adenoma. We must keep in mind that

Table 3 – Complete agreement of all three combinations.

Category	Table of frequencies: a pair of grey (data)			
	Frequency	Cumulative frequency	Relative frequency	Cumulative relative frequency
0	33	33	80.48780	80.4878
1	8	41	19.51220	100.0000
ChD	0	41	0.00000	100.0000

up to 10% of the general population has pituitary adenoma without any clinical signs [14,15]. In other words, 10% of the population might harbour a hormonally active adenoma in addition to an inactive tumour. However, according to a large series of 660 patients, only 2% had Cushing's disease [16].

Gradient-echo MRI sequences could be divided into the spoiled gradient-echo and steady-state free precession (SSFP) sequence. SPGR or spoiled GRASS are among the spoiled gradient-echo sequences. In this group belongs also fasts PGR, which is an extremely low angle shot. Before the discovery of SPGR, some researchers tried to improve diagnostics using double perfusion of pituitary adenomas from the hypophyseal portal system and the meningo-hypophyseal trunk in conjunction with dynamic scanning after the application of a contrast agent. These studies showed no significant improvement over conventional MRI [17,18]. SPGR was first used in 1990 to diagnose Cushing's disease in six patients. Sensitivity was found to be 80% [19]. In another paper assessing diagnostic value in 76 prolactinoma patients, sensitivity was 75%, but only 15 had a surgically confirmed tumour in the depicted region. These patients were those in which hormonal treatment failed [20]. It obviously led to some scepticism on the diagnostic value of SPGR. Many factors are responsible for the seemingly excellent sensitivity and diagnostic precision of SPGR when compared with standard MRI [21-24].

The important question remains as to whether SPGR is a suitable tool to plan the extent of resection. In the largest study from 2003 that examined 50 surgical patients. The authors concluded that using SPGR during the planning phase would give false positive results [4]. In this study, sensitivity of detecting a tumour was 76% and specificity only 33%. Radiological examination underestimated the size of the tumour (≤ 5 mm) when compared with the intraoperative finding (6-10 mm). Despite the exceptional sensitivity of SPGR, precise tumour targeting is not possible.

Our goal was to prove that targeting was possible using a combination of state-of-the-art methods. Accordingly, we used a combination of preoperative MR (SE, SPGR, fSPGR), neuronavigation and iMRI. For pituitary adenoma depiction we followed current recommendations [25-27]. To a standard SE sequence we added SPGR, fSPGR sequences and analysis of their combinations. The study was surgically focused. Whether the data about the shape of the adenoma can help surgeon in resection of the adenoma. Aside of the presented sequences we used the sequences as recommended by the current review paper on this topic [28]. Therefore we do not discuss in this paper value of diffusion weighted imaging or perfusion weighted imaging in sellar region.

We achieved 100% sensitivity. Particularly noteworthy is that we cooperated with only one department that performs endocrinological examinations, namely the 3rd Medical Department of the 1st Medical Faculty, Charles University. Increased sensitivity could be attributed to the combination of all three MR sequences (SE, SPGR and fSPGR). Using these three sequences, a skilled neuroradiologist with more than 20 years of clinical practice was able to identify tumours in all cases, as well as to define the extent of the tumours and to properly set neuronavigation software. The main issue of specificity of these MR sequences remains.

For statistical analysis, each sampling area was shared and compared with similar areas of histological positivity. We searched the place of compliance in individual locations. There was a consensus in individual locations in 63 of the 123 cases (56%). The correlation gamma function at a 5% significance level was then 0.27. This result translates to a specificity of 56%. The specificity is the certainty of finding a pituitary adenoma at the measuring point. Overall, we are able to increase specificity by a combination of methods specificity of 33% (according to literature) at 56%. Complete agreement, i.e. compliance in all combinations, was achieved in only 20% of the cases. This is the overlap of the tumour outside the viewing area, or conversely, larger findings displayed on MR than findings on postoperative histology. This observation is consistent with the authors of the above-mentioned publications.

If we examine individual findings in our cohort, full concordance of results was attained in eight patients (20%). In 21 patients (51%), histological findings were more extensive than MR imaging, i.e. positive histology samples were found beyond the supposed limits defined by MRI. The opposite result, i.e. histological extent smaller than MRI extent, occurred in three patients (7%). Negative specificity was noted in nine patients (22%). In these cases, the extent of MRI differed from the histological finding. The role played by the number of patients, not statistical consensus at individual points.

Important is the correlation of MRI, histology and endocrinological outcome after surgery. In our study, remission of morning cortisol hypersecretion during the follow-up was achieved in case of the full agreement between MRI and histology in 100%. In this subgroup of complete concordance, the level of morning cortisol was 23-462 nmol/l.

In case of more extensive histological findings than what would be suspected on MRI, morning cortisol hypersecretion was achieved in 21 patients (90%), with serum levels reaching 6-551 nmol/l. There was the borderline between tumour and healthy adenohypophysis was distinct. The tumour was resected beyond the area shown on MRI. As a result, these surgeries led to high radicality of resection. On the other hand, less extensive histology findings (i.e. there were negative samples taken in place of MRI findings) were found in three patients (7%). If the histology were less extensive (i.e. there were negative samples taken in place of MRI findings or there were no positive samples), then there was endocrinological remission in 1 of the 3 cases (33%). There may also include a suitable place of sampling or an insufficiently transparent area to continue resection. Patients with sinus tumour infiltration belong to this group of patients. The overall result (i.e. the extinction morning serum cortisol activity) reached 88% in our group in the follow-up period.

Evidence shows that endocrinological remission after transsphenoidal surgery in Cushing's disease ranges from 79.5% to 89% [29,30]. iMRI led to a decision to continue with resection in one case (2.5%). Overall radicality is influenced by the relatively short follow-up time, which was 6-42 months in our study. We assume that the natural course of the disease will decrease radicality with time. In our cohort, two patients with high cortisol levels are on hormonal therapy, two patients were irradiated by LGK and one unsuccessfully irradiated patient underwent adrenalectomy.

In our cohort, postoperative CSF leakage occurred in two patients, who subsequently underwent revision surgery, including CSF fistula closure and lumbar drainage insertion. One patient with a chronic sphenoid sinus infection suffered postoperative meningitis without CSF leakage and was treated by antibiotics without need for surgical intervention.

Overall, mortality was 0% and morbidity 7.3% in our cohort. If we include long-term substitution of vasopressin analogue, morbidity reached 14.6%.

5. Conclusion

The aim of our study was an optimisation of preoperative MR diagnostic protocol in Cushing's disease and to prove its increased diagnostic yield in a prospective trial. Recent studies have shown sensitivity to be 76%, whereas specificity of exact tumour localisation has only been 33%. Our effort was to use a combination of modern diagnostic methods and to show that exact tumour localisation is possible. Combination of MR sequences (SE, SPGR, fSPGR), a neuronavigation system and iMRI resulted in an increase in sensitivity (up to 100%). Specificity reached as high as 56% in our study. We found a high success rate in surgical procedure in terms of the correlation between MR findings and histology, which leads to remission of Cushing's disease. Our results support the use of MR examination together with a navigation system and iMRI.

Conflict of interest

None declared.

Acknowledgement and financial support

Supported by IGA MZ NT 13631, IGA MZ NT 14256, P34/LF1/7.

Ethics

The work described in this article has been carried out in accordance with The Code of Ethics of the World Medical Association (Declaration of Helsinki) for experiments involving humans; Uniform Requirements for manuscripts submitted to Biomedical journals.

REFERENCES

- [1] Rosegay H. Cushing legacy to transsphenoidal surgery. *J Neurosurg* 1981;54:448–54.
- [2] Walker EA. *A history of neurological surgery*. Baltimore: Williams and Wilkins; 1982.
- [3] Cushing HW. The basophil adenomas of the pituitary body and their clinical manifestations (pituitary basophilism). *Bull Johns Hopkins Hosp* 1932;50:137–95.
- [4] Patronas N, Bulakbasi N, Stratakis CA, Lafferty A, Oldfield EH, Doppman J, et al. Spoiled gradient recalled acquisition in the steady state technique is superior to conventional postcontrast spin echo technique for magnetic resonance imaging detection of adrenocorticotropin secreting pituitary tumors. *J Clin Endocrinol Metab* 2003;88(4):1565–9.
- [5] Hardy J. Transsphenoidal hypophysectomy: neurosurgical techniques. *J Neurosurg* 1971;34:582–4.
- [6] Fusek I, Černý E. Transsphenoidal operation of hypophyseal tumors. *J Neurosurg Sci* 1977;21:2–3 [159–160].
- [7] Masopust V, Netuka D, Beneš V. Endonasal endoscopic transsphenoidal resection of sellar lesions. *Čes a slov neurologie a neurochirurgie* 2008;71/104(6):704–71.
- [8] Netuka D, Masopust V, Belšán T, Kramář F, Beneš V. Initial experience of the use of intraoperative MR in pituitary adenoma resections. *Čes a slov neurologie a neurochirurgie* 2009;105(1):45–50.
- [9] Netuka D, Masopust V, Belšán T, Kramář F, Beneš V. One year experience with 3.0T intraoperative MRI in pituitary surgery. *Acta Neurochir Suppl* 2011;109:157–9.
- [10] Masopust V, Netuka D, Beneš V, Bradáč O, Marek J, Hána V. Endonasal endoscopic pituitary adenoma resection: preservation of neurohypophyseal function. *J Neurol Surg Part A Cent Eur Neurosurg* 2014;75(5):336–42.
- [11] De Herder WW, Uitterlinden P, Pieterman H, Tanghe HL, Kwekkeboom DJ, Pols HA, et al. Pituitary tumor localization in patients with Cushing's disease by magnetic resonance imaging. Is there a place for petrosal sinus sampling? *Clin Endocrinol* 1994;40(1):87–92.
- [12] Watson JC, Shawker TH, Nieman LK, DeVroom HL, Doppman JL, Oldfield EH. Localization of pituitary adenomas by using intraoperative ultrasound in patients with Cushing's disease and no demonstrable pituitary tumor on magnetic resonance imaging. *J Neurosurg* 1998;89(6):927–32.
- [13] Chittiboina P1, Montgomery BK, Millo C, Herscovitch P, Lonser RR. High-resolution (18)F-fluorodeoxyglucose positron emission tomography and magnetic resonance imaging for pituitary adenoma detection in Cushing disease. *J Neurosurg* 2015;122(4):791–7.
- [14] Elster AD. Sellar susceptibility artifacts: theory and implications. *Am J Neuroradiol* 1993;14:129–36.
- [15] Hall WA, Luciano MG, Doppman JL, Patronas NJ, Oldfield EH. Pituitary magnetic resonance imaging in normal human volunteers: occult adenomas in the general population. *Ann Intern Med* 1994;120:817–20.
- [16] Ratliff JK, Oldfield EH. Multiple pituitary adenomas in Cushing's disease. *J Neurosurg* 2000;93:753–61.
- [17] Tabarin A, Laurent F, Catargi B, Olivier-Puel F, Lescene R, Berge J, et al. Comparative evaluation of conventional and dynamic magnetic resonance imaging of the pituitary gland for the diagnosis of Cushing's disease. *Clin Endocrinol (Oxf)* 1998;49:293–300.
- [18] Stadnik T, Spruyt D, van Binst A, Luypaert R, d'Haens J, Osteaux M. Pituitary microadenomas: diagnosis with dynamic serial CT, conventional CT and T1-weighted MR imaging before and after injection of gadolinium. *Eur J Radiol* 1994;18:191–8.
- [19] Stadnik T, Stevenaert A, Beckers A, Luypaert R, Buisseret T, Osteaux M. Pituitary microadenomas: diagnosis with two- and three-dimensional MR imaging at 1.5T before and after injection of gadolinium. *Radiology* 1990;176:419–28.
- [20] Girard N, Brue T, Chabert-Orsini V, Raybaud C, Jaquet P, Poncet M, et al. 3D-FT thin sections MRI of prolactin-secreting pituitary microadenomas. *Neuroradiology* 1994;36:376–9.
- [21] Rand S, Maravilla KR. Use and limitations of spoiled gradient-refocused imaging in the evaluation of suspected intracranial tumors. *Top Magn Reson Imaging* 1992;4:7–16.

-
- [22] Pui MH, Fok EC. MR imaging of the brain: comparison of gradient-echo and spin-echo pulse sequences. *Am J Roentgenol* 1995;165:959-62.
- [23] Mugler III JP, Epstein FH, Brookeman JR. Shaping the signal response during the approach to steady state in three-dimensional magnetization prepared rapid gradient-echo imaging using variable flip angles. *Magn Reson Med* 1992;28:165-85.
- [24] Runge VM, Kirsch JE, Thomas GS, Mugler III JP. Clinical comparison of three-dimensional MP-RAGE and FLASH techniques for MR imaging of the head. *J Magn Reson Imaging* 1991;1:493-500.
- [25] Bladowska J, Biel A, Zimny A. Are the T2 weighted images more useful than T1-weighted contrast-enhanced images in assessment of postoperative sella and parasellar region? *Med Sci Monit* 2011;17(10):MT83-90.
- [26] Bladowska J, Sasiadek M. Diagnostic imaging of the pituitary and parasellar region, in Rahimi-Movaghar V. *pituitary adenomas*. Intech Shanghai; 2012.
- [27] Bladowska J, Sokolska V, Sozanski T. Comparison of post-surgical MRI presentation of the pituitary gland and its hormonal function. *Pol J Radiol* 2010;75:293-6.
- [28] Bonneville JF, Bonneville F, Cattin F, Nagi S. *MRI of pituitary gland*. Switzerland: Springer International Publishing; 2016.
- [29] Esposito F, Dusick JR, Cohan P, Moftakhar P, McArthur D, Wang C, et al. Clinical review: early morning cortisol levels as a predictor of remission after transsphenoidal surgery for Cushing's disease. *J Clin Endocrinol Metab* 2006;91(1):7-13.
- [30] Acebes JJ, Martino J, Masuet C, Montanya E, Soler J. Early post-operative ACTH and cortisol as predictors of remission in Cushing's disease. *Acta Neurochir (Wien)* 2007;149(5):471-4.