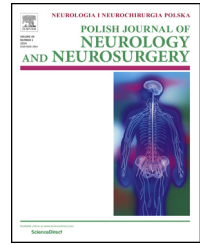


Available online at [www.sciencedirect.com](http://www.sciencedirect.com)

ScienceDirect

journal homepage: <http://www.elsevier.com/locate/pjnns>

## Original research article

# Stent-assisted embolization of wide-neck anterior communicating artery aneurysms: Review of consecutive 34 cases



Damian Kocur<sup>a,\*</sup>, Miłosz Zbrozczyk<sup>b</sup>, Nikodem Przybyłko<sup>a</sup>,  
Mariusz Hofman<sup>a</sup>, Tomasz Jamróz<sup>a</sup>, Jan Baron<sup>b</sup>, Piotr Bażowski<sup>a</sup>,  
Stanisław Kwiek<sup>a</sup>

<sup>a</sup>Department of Neurosurgery, School of Medicine in Katowice, Medical University of Silesia, Katowice, Poland

<sup>b</sup>Department of Radiology and Nuclear Medicine, School of Medicine in Katowice, Medical University of Silesia, Katowice, Poland

## ARTICLE INFO

## Article history:

Received 21 October 2015

Accepted 19 July 2016

Available online 26 July 2016

## Keywords:

Anterior communicating artery aneurysm

Wide-neck aneurysm

Stent-assisted embolization

## ABSTRACT

**Objective:** We report our experience with stent-assisted coiling of anterior communicating artery aneurysms with special consideration of angiographic and clinical outcomes, retreatment rate and periprocedural complications.

**Materials and methods:** The analysis included 34 consecutive ruptured and unruptured wide-neck aneurysms. The aneurysm size ranged from 2 to 18 mm (mean 5.47). Clinical examinations with the use of modified Rankin Score and angiographic outcomes were evaluated initially post-embolization and at a minimum follow-up of 6 months.

**Results:** Initial post-treatment complete and near-complete aneurysm occlusion was achieved in 32 (94%) and 2 (6%) cases, respectively. Imaging follow-up, performed in 28 (82%) patients, showed no change in the degree of occlusion in 25 (89%) cases and coil compaction in 3 (11%) patients. Of these, one (3.6%) patient underwent a second coil embolization. The periprocedural severe complication rate was 2.9% (1/35) and was associated with prolonged attempt of retrieval of migrated coil resulting in anterior cerebral artery infarct with serious clinical consequences. In another 3 patients periprocedural adverse events without delayed clinical consequences were noticed. The clinical follow-up evaluation achieved in 33 (97%) patients showed no change in 30 (91%) cases, one patient (3%) with clinical improvement and two (6%) cases of neurological deterioration.

**Conclusions:** The use of stent is feasible and effective for coil embolization of wide-necked anterior communicating artery aneurysms. Although periprocedural complications resulting in severe morbidity are rare, they should be noted, since in terms of thromboembolic events some of them presumably have a potential to be avoidable.

© 2016 Polish Neurological Society. Published by Elsevier Sp. z o.o. All rights reserved.

\* Corresponding author at: Department of Neurosurgery, School of Medicine in Katowice, Medical University of Silesia. Tel.: +48 507 230 509; fax: +48 327 894 501.

E-mail address: [damkocur@gmail.com](mailto:damkocur@gmail.com) (D. Kocur).

<http://dx.doi.org/10.1016/j.pjnns.2016.07.008>

0028-3843/© 2016 Polish Neurological Society. Published by Elsevier Sp. z o.o. All rights reserved.

## 1. Introduction

The anterior communicating artery (AcomA) is reported to be one of the most common site for intracranial aneurysms and this location of aneurysms is associated with subarachnoid hemorrhage (SAH) in up to 40% [1-4]. The complex arterial relationship in this region include the anterior communicating artery, bilateral anterior cerebral arteries, the recurrent artery of Heubner, hypothalamic and infundibular perforators, orbito-frontal and frontopolar branches and sometimes large pre-callosal or subcallosal artery [1,2,5]. The microsurgical clip ligation of the AcomA aneurysms is challenging and may result, inter alia, in postoperative cognitive and memory deficits related to the AcomA branches impairment and the frontal lobe retraction [5,6]. Less invasive endovascular approach is an effective treatment technique and remains an acceptable alternative to the traditional open surgery [2,3,6,7]. However, AcomA aneurysms in comparison with the other locations tend to be small in size with the narrow parent vessels and the acute angles between surrounding arteries [5,8]. Moreover, the main limitation of the AcomA aneurysms coil embolization is an unfavorable dome-to-neck ratio and a wide neck of an aneurysm [1,4,5,8,9]. The introduction of adjuvant devices such as multiple microcatheters, three-dimensional (3D) coils, balloon remodeling technique and intracranial stents has progressively allowed these aneurysms to be successfully repaired [3,8,10,11]. Moreover, the standard coil embolization (stand-alone coiling) applied for wide neck aneurysms harbors a higher risk of coil prolapse into the parent artery and the higher rate of recanalization in comparison with stent-assisted coiling [8,12,13]. There is a limited number of studies entirely dedicated to stent-assisted coiling of AcomA aneurysms and hence, this form of endovascular therapy in AcomA aneurysms is not yet well characterized [1,3-5]. The purpose of the current study is to present immediate and long-term clinical and angiographic results, procedure-related complications, and retreatment rate of the stent-assisted endovascular management of 34 patients harboring wide-neck AcomA aneurysms treated at our institution within the last 6 years.

## 2. Materials and methods

### 2.1. Patient population

Between April 2008 and December 2014, 71 patients harboring anterior communicating artery (AcomA) aneurysms were treated at our center via endovascular approach. Of these, 34 patients underwent stent-assisted coiling. Overall, there were 19 (56%) females and 15 (44%) males. The patients' ages ranged from 32 to 70 years (mean 54.7, SD 12.4).

Twenty-nine (85%) aneurysms were unruptured and five (15%) patients presented with SAH. All of them were categorized in Hunt and Hess Grade 3 at time of treatment.

Regarding the patients with SAH, two of them were treated within 3 days of rupture. In the remaining three patients treatment was postponed to 14-49 days after hemorrhage due to delayed diagnosis in two cases and acute respiratory failure in one case.

Except for 4 patients in whom microsurgical wrapping or incomplete clip ligation was previously performed beyond our institution, the remaining patients included in the current study were treated for the first time via endovascular approach, which is preferred to be the first-line treatment method for intracerebral aneurysms at our department.

### 2.2. Aneurysm characteristics

The aneurysm size ranged from 2 to 18 mm (mean 5.47, SD 3.07). Patient selection for treatment with stents was based only on the angioarchitectural characteristics of the each aneurysm. Thus, only the wide-neck AcomA aneurysms, defined as these with the aneurysm neck diameter  $\geq 4$  mm and/or these with the dome-to-neck ratio  $< 1.5$  were considered for this treatment.

### 2.3. Endovascular technique

All the procedures were performed by the same two extensively experienced interventional radiologists always after neurosurgical consultations. The patients were treated under general anesthesia. Anti-platelet premedication consisting of a 75 mg loading dose of acetylsalicylic acid and an additional 75 mg clopidogrel was performed several hours before endovascular procedure in patients after SAH and every single day for five days before treatment in case of patients harboring unruptured aneurysms. Both conventional and rotational digital subtraction angiographies (DSA) were performed for 3D reconstruction. A complete evaluation of the aneurysmal configuration, a neck size, an aneurysm width and height was done. A guiding catheter (Envoy; Cordis, Miami Lakes, Fla) was navigated into the target artery. Then, a microcatheter was inserted into the aneurysm lumen. For a stent deployment another microcatheter was placed distally in the ipsilateral or contralateral A2 segment depending on the aneurysm location and the surrounding vascular anatomy. The Neuroform stent (Boston Scientific) was advanced over the microguidewire and deployed when the precisely targeted location was confirmed. Then, the aneurysm was coiled using GDC Boston Scientific Detachable Coils in the same session with the help of the previously deployed microcatheter. The procedures were usually performed in a bi-plane angiography suite. Multiple stent placement was performed only in a case of coil protrusion. At the end of coiling an image was acquired to assess immediate angiographic results. Once it was technically feasible, an attempt was made to achieve complete occlusion in the first treatment session.

During the procedures heparinized saline was continuously infused into the arterial line. In the setting of intraprocedural thrombosis abciximab was administered locally. After embolization, the patient was transferred to the intensive care unit for clinical observation and monitoring of medical parameters. At that time, systemic heparin 15,000 IU for the next 24 h was administered intravenously to raise the activated partial thromboplastin time 2-3 times above normal values. Patients with unruptured aneurysms after uncomplicated treatment were typically discharged from hospital on postoperative day 3. Dual antiplatelet treatment consisting of 75 mg clopidogrel and 75 mg acetylsalicylic acid

was applied postoperatively every day for 6 weeks. Then, acetylsalicylic acid was continued with intention to be administered for the rest of the patient's life.

#### 2.4. Clinical and angiographic outcomes

A control angiography was obtained immediately after the embolization and at minimum follow-up of 6 months. The lack of contrast filling within the aneurysm and the residual filling in the aneurysm neck were classified as a complete and near-complete occlusion, respectively. In cases of complete aneurysm obliteration the patient was not followed-up any longer, except for selected cases (e.g. endovascular treatment of accompanying cerebral aneurysms). Recanalization was defined as any increase in aneurysmal filling at follow-up. Once there was enough space for an additional placement of coils, the retreatment was performed.

Modified Rankin Scale (mRS) scores were recorded at patients' discharge from hospital and during the last angiographic follow-up period. The remaining patients were interviewed by telephone if it was possible.

Detailed patient characteristics as well as the results are presented in [Table 1](#).

---

### 3. Results

#### 3.1. Angiographic results and retreatment

Post-embolization angiogram revealed a complete aneurysm occlusion in 32 (94%) cases. A near-complete aneurysm occlusion performed in 2 cases (6%) resulted from the difficulties of accessing the aneurysm for coiling in the patient who had undergone previous clipping and in the other one who suffered from advanced atherosclerosis.

Angiographic follow-up was achieved in 28 (82%) patients and ranged from 6 to 72 months, with a mean of 12.9 months. In 25 (89%) cases no change in the degree of occlusion at initial angiographic follow-up was detected. In 3 (11%) cases the control angiogram showed compaction of the coils into the aneurysm: one of these patients underwent a second coil embolization, whereas the remaining two patients were followed with angiography.

#### 3.2. Clinical outcome

The procedure-related severe morbidity rate of 2.9% (1/35) was associated with the coil protrusion into the parent artery with accompanying thromboembolism. Despite attempts to retrieve the prolapsed coil and to deploy a second rescue stent the migrated coil was left in situ. The control angiogram revealed occlusion of the anterior cerebral artery that resulted in an acute infarction in the territory of this vessel seen on the CT scan followed by the severe cognitive impairment experienced by the patient.

There was also another case of the neurological deterioration but it was not associated with the procedure and came about before the endovascular treatment. This patient initially with SAH (Hunt-Hess grade 1) experienced acute respiratory failure and depression of consciousness (Hunt-Hess grade 3)

due to brain swelling. After intensive care unit conservative therapy the stent-assisted coiling was performed uncomplicated.

Periprocedural mild adverse events occurred in 8.6% (3/35) procedures and all of them were associated, to some extent, with thromboembolism.

In two cases clinically silent thromboembolic events were associated with the procedure of stent deployment. After instant intraarterial administration of abciximab the improvement of arterial blood flow was observed in the control angiogram.

In one case intraoperative aneurysm rupture occurred when placement of a second coil was attempted. Another coil was immediately delivered into the aneurysm lumen what resulted in complete obliteration of the aneurysm and cessation of extravasation. Unfortunately, immediate control angiogram showed thromboembolic occlusion of anterior cerebral artery. After prompt administration of abciximab total recanalization was revealed on angiography. Post-procedural brain CT demonstrated insignificant blood clot around the AcomA aneurysm. The patient developed transient, mild hemiparesis and recovered completely in the next few days.

The clinical follow-up achieved in 33 (97%) patients and performed at minimum 6 months (mean 14.6 months) showed no change in 30 (90.9%) patients and one case (3%) of the clinical improvement in a patient with the initial disorientation after the aneurysm rupture. Of the two (6%) cases of the neurological worsening during the follow-up period one patient experienced a brainstem stroke with sustained dysarthria and dysphagia and in the other one undiagnosed increasing mental and gait disturbance occurred.

---

### 4. Discussion

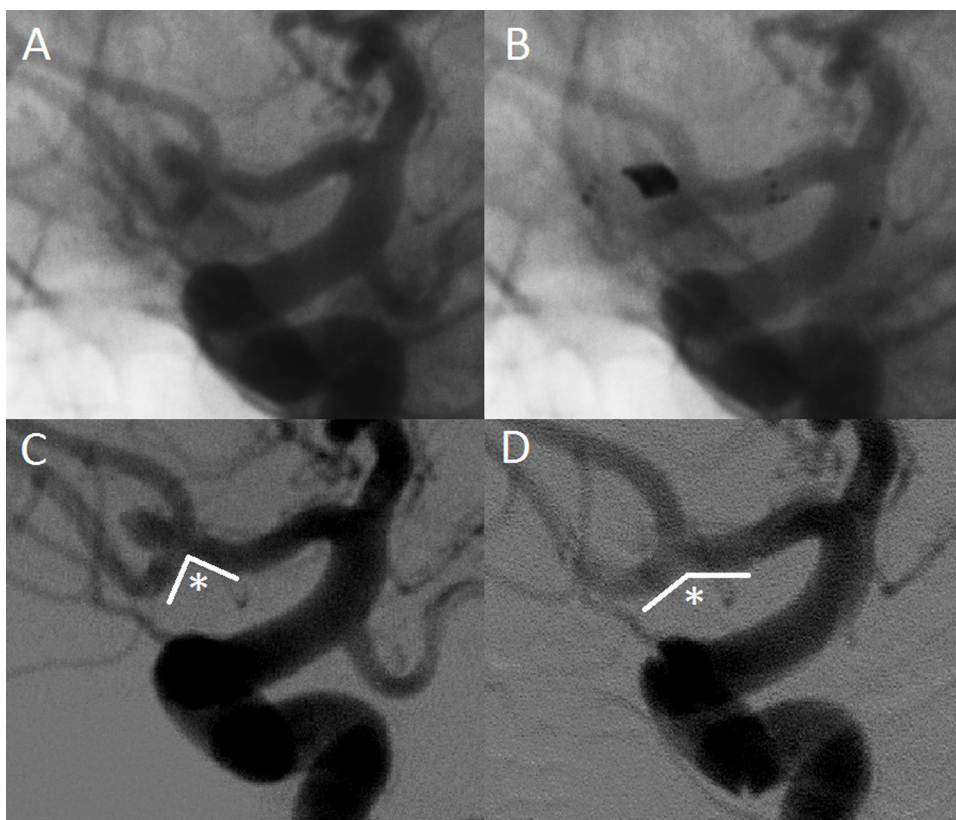
Stents deployed across the neck of the intracranial aneurysm during a coiling procedure prevent a coil mass herniation into the parent artery and allow denser packing of the aneurysm with coils, resulting supposedly in a better long-term occlusion rate [1,8,11,14,15]. In addition to these mechanical functions, hemodynamic and biologic effects of stenting are reported [8,16]. Endothelial growth induced by stents promote beneficial remodeling of the aneurysm neck and the parent artery but may also lead to unfavorable in-stent stenosis [8,16-19]. Alteration of intra-aneurysmal flow following stent implantation is considered to induce progressive thrombosis of incompletely occluded aneurysm; however it is not common in AcomA aneurysms compared with other aneurysm locations [5,12,16]. Changing the blood flow direction may also decrease the rate of recanalization [16]. Although, the great majority of stents currently applied in the endovascular treatment of AcomA aneurysms are not specifically created for the flow diversion, it is reported that aneurysms in this location treated with stent-assisted coiling recur rarely [5,12,16]. An example of the parent artery angle increase after stent placement is presented in [Fig. 1](#).

Treatment of wide-neck AcomA aneurysms with complex anatomy may sometimes require dual stent placement in X- or Y-configuration or using the "waffle cone" technique. Most

Table 1 – Patients characteristics and treatment results.

No.	Patients			Angiographic outcome					Clinical outcome		
	Age/sex	Clinical presentation	Aneurysm size (mm)	Instant occlusion	Technical complication	Occlusion at last follow-up	Follow-up period	Re-treatment	mRS at discharge	mRS at last follow-up	Follow-up period
1	48/M	incidental	6	Near-Complete	Thr	Near-Complete	72	None	0	1	72
2	42/M	SAH (III H-H)	5	Complete	None	Complete	8	None	0	0	8
3	68/F	headaches	6	Complete	None	Complete	22	None	0	0	22
4	34/M	SAH (III H-H)	3	Complete	None	Complete	31	None	0	0	31
5	59/F	incidental	4	Complete	Thr	Complete	25	None	0	0	25
6	67/F	incidental	6	Complete	None	N/a due to lack of consent		-	0	0	36
7	33/M	incidental	3	Complete	None	Complete	7	None	0	0	7
8	50/M	incidental	5	Complete	None	N/a due to lack of contact		-	0	N/a due to lack of contact	
9	63/F	incidental	5	Complete	None	N/a due to clinical status		-	0	4	32
10	63/M	SAH (III H-H)	4	Complete	None	Complete	7	None	2	2	7
11	56/M	incidental	18	Complete	None	Complete	13	Yes	0	0	13
12	67/F	incidental	4	Complete	None	Complete	6	None	0	0	6
13	57/F	incidental	3	Complete	None	N/a due to lack of consent		-	0	0	26
14	32/F	incidental	2	Complete	None	Complete	8	None	0	0	8
15	59/M	incidental	8	Complete	Coil prolapse, Thr	N/a due to clinical status		-	3	3	22
16	48/F	headaches	4	Complete	None	Near-Complete	18	None	0	0	18
17	49/F	incidental	4	Complete	None	Complete	7	None	0	0	7
18	34/M	incidental	4	Complete	None	Complete	7	None	0	0	7
19	57/F	incidental	5	Complete	None	Complete	6	None	0	0	6
20	64/F	incidental	4	Complete	None	Complete	6	None	0	0	6
21	68/F	incidental	8	Complete	None	Complete	8	None	0	0	8
22	66/F	incidental	5	Complete	None	Complete	6	None	0	0	6
23	70/F	headaches	6	Complete	None	Complete	9	None	0	0	9
24	58/F	incidental	7	Complete	None	Complete	12	None	0	0	12
25	36/F	incidental	5	Complete	None	Complete	6	None	0	0	6
26	51/M	SAH (III H-H)	4	Complete	None	Near-Complete	28	None	1	0	28
27	68/M	incidental	10	Complete	None	Complete	6	None	0	0	6
28	60/F	headaches	5	Complete	None	Complete	6	None	0	0	6
29	36/F	headaches	4	Complete	None	Complete	6	None	0	0	6
30	55/M	SAH (III H-H)	5	Complete	None	Complete	7	None	0	0	7
31	67M	headaches	4	Complete	None	Complete	8	None	0	0	8
32	40/M	headaches	13	Complete	None	Complete	9	None	0	0	9
33	65/F	incidental	3	Complete	IAR, Thr	Complete	6	None	0	0	6
34	70/M	incidental	4	Near-Complete	None	N/a due to lack of contact		None	0	0	7

SAH – subarachnoid hemorrhage, H-H – Hunt&Hess grade, Thr – thromboembolism, IAR – intraoperative aneurysm rupture, mRS – modified Rankin Score, N/a – not available.



**Fig. 1 – AcomA aneurysm treated with stent-assisted coiling. (A) Nonsubtracted and (C) subtracted projections before embolization. (B) Nonsubtracted angiogram after embolization shows the stent positioned with the proximal and distal markers and the coils introduced into the aneurysm. (D) Control subtracted angiogram shows total occlusion of the aneurysm. Note the parent arterial angle change after stent deployment (asterisk).**

commonly, though, stent-assisted endovascular treatment of AcomA aneurysms proceeds with the deployment of one stent across the aneurysm neck [1,4,5]. However, there are three possible stent placement configurations across the AcomA aneurysms: deploying stent from ipsilateral A1 to contralateral A2, from ipsilateral A1 to ipsilateral A2, and from ipsilateral A1 to contralateral A1. Generally, the implantation strategy depends on aneurysm neck location and symmetry of anterior cerebral arteries [4]. It is also a matter of vascular interventionalists' preferences, as stent configurations applied during treatment of AcomA aneurysms vary among authors [1,4,5]. Similarly, there are different operative methods depending on the timing of stent deployment in relation to coiling [1,4,5,20]. In the “trans-cell” technique a stent is deployed at the beginning of the procedure and a coiling microcatheter is inserted into the aneurysm dome through the stent struts. Stent-assisted coiling described in our study was performed using a “jailing” technique, in which a stent is navigated into the parent vessel after the aneurysm is catheterized but before coil deployment. It is reported that the placement of the microcatheter between the vessel wall and the stent in this technique helps to stabilize the microcatheter during coiling, although, embolization with an application of the “jailing” technique may be challenging in AcomA aneurysms due to small diameter of anterior cerebral artery

and vasospasm resulted from SAH [4]. However, taking into account the fact that deploying of a microcatheter into the aneurysm lumen is more difficult after stenting [21], we prefer to use the “jailing” technique as a first-choice in the treatment of all intracranial aneurysms at our center. Moreover, the aneurysms treated in the current study are on average small in size, so we apply this technique, as it is reported to be efficient for treatment of wide-neck, tiny intracranial aneurysms [22].

Considering the fact that significant morbidity rates in three series on stenting of AcomA aneurysms range from 0% to 5%, stent-assisted embolization of wide-neck AcomA aneurysms is reported to be a safe method what is confirmed by our results [1,4,5]. Mortality rate of 1.6% in Johnson's publication on AcomA aneurysms stent-assisted coiling was related to one fatal hemorrhagic case caused by the unfortunate deployment of a third additional rescue stent for stabilization of a herniated coil [5]. This author reports that implantation of a first or a second stent is a routine tool for coil prolapse into the parent artery. However, the implantation of a third stent is hazardous and in such cases leaving the coil herniated followed by aggressive antiplatelet therapy may be a better resolution [5]. It should be kept in mind that prolonged attempt of retrieval of migrated coil and implantation of a supplementary second stent may be associated with a thromboembolic event, as it was reported in our study. Delayed recognition and

treatment of the acute thromboembolic occlusion of anterior cerebral artery resulted in our case in ischemic stroke with serious clinical consequences. Finitis et al. report a case of coil protrusion during endovascular treatment of AcomA aneurysm. In that case the coil was left in place and the patient was put under anticoagulation with an excellent clinical outcome [7]. It is also worth pointing out that the immediate termination of the treatment session and the early administration of the glycoprotein IIb/IIIa receptor antagonist in the thromboembolic events prevented severe postoperative clinical complications in three patients of our study population.

It is widely known that thromboembolism is one of the most negative aspects of stent-assisted embolization, albeit the thromboembolic risk of AcomA aneurysms stenting is lower in relation to other aneurysm locations [5,23]. Nonetheless, to decrease the risk of periprocedural and delayed stent-related thromboembolic complications the use of antiaggregant agents is obligatory. Although, the optimal therapy for patients treated with stent-assisted coiling has not been determined yet, the dual antiplatelet therapy is most commonly applied in the treatment of AcomA aneurysms; however, the appropriate time of drug administration, dosage, duration of pharmacotherapy, monitoring of platelet activity by thromboelastography and the use of antiplatelet therapy in acute phase of SAH varies considerably among authors [1,4,5].

Results of studies on stent-assisted AcomA aneurysms coiling showed that initial post-embolization complete and near-complete occlusion rate was 66–95% and the percentage of patients with recanalization requiring retreatment was 5.5–12.1% [1,4,5]. It is reported that one of the factors decreasing the risk of recanalization is sufficient packing of the sac with coils [24]. Our philosophy of endovascular treatment is to achieve the possible maximal aneurysm occlusion at initial control angiography. It may be one of the reasons the retreatment rate of 3.6% achieved in our study is comparatively low. This relatively aggressive approach is particularly applied in the treatment of the AcomA aneurysms, as it is documented that these aneurysms treated with microsurgical clipping are amongst those with the highest recurrence rate in comparison to aneurysms at other locations [25].

As it was demonstrated in the International Subarachnoid Aneurysm Trial (ISAT), angiographic occlusion rates of coiling in long-term follow-up are worse than the rates for microsurgical clipping [26]. Hence, the imaging follow-up after endovascular treatment is mandatory [27]. It is reported that the majority of adequately coil-occluded cerebral aneurysms at initial follow-up of 6 months do not require further imaging follow-up [27]. Therefore, we perform routinely first follow-up angiography at 6 month after initial treatment and in cases of complete aneurysms obliteration we do not follow-up patients any longer.

Three mechanisms of aneurysm recurrence after coiling are described: coil compaction, aneurysm regrowth and fundal migration [28]. The identification of patients with aneurysm recurrences who will need a retreatment and the decision of which treatment method to choose is still made on individual judgment, as the definition of relevant aneurysm reopening is yet not clear [28]. Our strategy is to treat aneurysm recurrences by additional standard coiling procedures whenever technically possible, like we have done it in 1 of 3 cases of recanalization

in our study. The two remaining recurrent aneurysms were not amenable to re-embolization as the residual spaces were smaller than 2 mm and it was impossible to occlude them with the shortest available coil. We have followed-up these patients closely, being aware of the fact that nonprogressive aneurysmal remnants have still a potential to hemorrhage [29].

Introduction of stents designed for intracranial use have reinforced the role of endovascular therapy in terms of long-term angiographic durability. In comparison to earlier balloon remodeling technique, in which a non-detachable balloon is inflated across the aneurysm neck, the permanent presence of a stent in a parent artery is associated with significant reduction of aneurysm recanalization [10]. However, it gives the necessity for long-lasting administration of antiplatelet therapy and the very procedure of stent implantation is reported to be more hazardous than the above-mentioned balloon remodeling and it is performed at the expense of augmented risks of ischemic, as well as hemorrhagic complications [10].

The limitation of the current study is its retrospective and observational character. Additionally, there is also a patient-selection bias, as there was only few patients after SAH and all the cases reported in this series were from a single institution.

---

## 5. Conclusions

This study concurs with others and proposes that stent-assisted coiling of AcomA aneurysms is an effective treatment method with satisfactory long-term angiographic and clinical results. Periprocedural complications resulting in severe morbidity are rare and in terms of thromboembolic events some of them probably have a potential to be avoidable.

---

## Conflict of interest

None declared.

---

## Acknowledgment and financial support

None declared.

---

## Ethics

The work described in this article has been carried out in accordance with The Code of Ethics of the World Medical Association (Declaration of Helsinki) for experiments involving humans; Uniform Requirements for manuscripts submitted to Biomedical journals.

---

## REFERENCES

- [1] Raslan AM, Oztaskin M, Thompson EM, Dogan A, Petersen B, Nesbit G, et al. Neuroform stent-assisted embolization of incidental anterior communicating artery aneurysms:

- long-term clinical and angiographic follow-up. *Neurosurgery* 2011;69.
- [2] Choi J-H, Kang M-J, Huh J-T. Influence of clinical and anatomic features on treatment decisions for anterior communicating artery aneurysms. *J Korean Neurosurg Soc* 2011;50:81-8.
- [3] Fang S, Brinjikji W, Murad MH, Kallmes DF, Cloft HJ, Lanzino G. Endovascular treatment of anterior communicating artery aneurysms: a systematic review and meta-analysis. *AJNR Am J Neuroradiol* 2014;35:943-7.
- [4] Huang Q, Xu Y, Hong B, Zhao R, Zhao W, Liu J. Stent-assisted embolization of wide-neck anterior communicating artery aneurysms: review of 21 consecutive cases. *AJNR Am J Neuroradiol* 2009;30:1502-6.
- [5] Johnson AK, Munich SA, Heiferman DM, Lopes DK. Stent assisted embolization of 64 anterior communicating artery aneurysms. *J Neurointerventional Surg* 2013;5(Suppl. 3): iii62-5.
- [6] Guglielmi G, Vinuela F, Duckwiler G, Jahan R, Cotroneo E, Gigli R. Endovascular treatment of 306 anterior communicating artery aneurysms: overall, perioperative results. *J Neurosurg* 2009;110:874-9.
- [7] Finitisis S, Anxionnat R, Lebedinsky A, Albuquerque PC, Clayton MF, Picard L, et al. Endovascular treatment of ACom intracranial aneurysms. Report on series of 280 patients. *Interv Neuroradiol J Peritherapeutic Neuroradiol Surg Proced Relat Neurosci* 2010;16.
- [8] Yun JH, Cho C-S. Experiences of neuroform stent applications for ruptured anterior communicating artery aneurysms with small parent vessel. *J Korean Neurosurg Soc* 2010;48:53-8.
- [9] Schuette AJ, Hui FK, Spiotta AM, Obuchowski NA, Gupta R, Moskowitz SI, et al. Endovascular therapy of very small aneurysms of the anterior communicating artery: five-fold increased incidence of rupture. *Neurosurgery* 2011;68:731-7. discussion 737.
- [10] Piotin M, Blanc R. Balloons and stents in the endovascular treatment of cerebral aneurysms: vascular anatomy remodeled. *Front Neurol* 2014;5.
- [11] Knap D, Partyka R, Zbrozczyk M, Korzekwa M, Zawadzki M, Gruszczynska K, et al. Tętniaki mózgu - współczesne metody leczenia wewnątrznaczyniowego. *Pol Przegląd Neurol* 2010;6:22-6.
- [12] Piotin M, Blanc R, Spelle L, Mounayer C, Piantino R, Schmidt PJ, et al. Stent-assisted coiling of intracranial aneurysms: clinical and angiographic results in 216 consecutive aneurysms. *Stroke J Cereb Circ* 2010;41:110-5.
- [13] Kono K, Terada T. Hemodynamics of 8 different configurations of stenting for bifurcation aneurysms. *AJNR Am J Neuroradiol* 2013;34:1980-6.
- [14] Hwang S-K, Hwang G, Bang JS, Oh CW, Kwon O-K. Endovascular enterprise stent-assisted coil embolization for wide-necked unruptured intracranial aneurysms. *J Clin Neurosci Off J Neurosurg Soc Australas* 2013;20:1276-9.
- [15] Durst CR, Khan P, Gaughen J, Patrie J, Starke RM, Conant P, et al. Direct comparison of neuroform and enterprise stents in the treatment of wide-necked intracranial aneurysms. *Clin Radiol* 2014;69:e471-6.
- [16] Cho W-S, Kang H-S, Kim JE, Kwon O-K, Oh CW, Cho YD, et al. Angle change of the parent arteries after stent-assisted coil embolization of wide-necked intracranial bifurcation aneurysms. *Clin Radiol* 2014;69.
- [17] Fiorella D, Albuquerque FC, Woo H, Rasmussen PA, Masaryk TJ, McDougall CG. Neuroform in-stent stenosis: incidence, natural history, and treatment strategies. *Neurosurgery* 2006;59.
- [18] Kuhn AL, Hou SY, Puri AS, Silva CF, Gounis MJ, Wakhloo AK. Stent-assisted coil embolization of aneurysms with small parent vessels: safety and efficacy analysis. *J Neurointerventional Surg* 2015;8:581-5.
- [19] Aydin K, Arat A, Sencer S, Barbuoglu M, Men S. Stent-assisted coiling of wide-neck intracranial aneurysms using low-profile LEO baby stents: initial and midterm results. *AJNR Am J Neuroradiol* 2015;36:1934-41.
- [20] Biondi A, Janardhan V, Katz JM, Salvaggio K, Riina HA, Gobin YP. Neuroform stent-assisted coil embolization of wide-neck intracranial aneurysms: strategies in stent deployment and midterm follow-up. *Neurosurgery* 2007;61:460-8. discussion 468-9.
- [21] Lima I, Bonaf A. In: Murai Y, editor. *Stent-Assisted Techniques for Intracranial Aneurysms*. Aneurysm, InTech; 2012.
- [22] Li C-H, Su X-H, Zhang B, Han Y-F, Zhang E-W, Yang L, et al. The stent-assisted coil-jailing technique facilitates efficient embolization of tiny cerebral aneurysms. *Korean J Radiol* 2014;15:850.
- [23] Cho W-S, Hong HS, Kang H-S, Kim JE, Cho YD, Kwon O-K, et al. Stability of cerebral aneurysms after stent-assisted coil embolization: a propensity score-matched analysis. *Neurosurgery* 2015;77:208-17.
- [24] Knap D, Gruszczynska K, Partyka R, Ptak D, Korzekwa M, Zbrozczyk M, et al. Results of endovascular treatment of aneurysms depending on their size, volume and coil packing density. *Neurol Neurochir Pol* 2013;47:467-75.
- [25] Kunert P, Prokopienko M, Gola M, Dziedzic T, Jaworski M, Marchel A. Assessment of long-term results of intracranial aneurysm clipping by means of computed tomography angiography. *Neurol Neurochir Pol* 2013;47.
- [26] Molyneux AJ, Birks J, Clarke A, Sneade M, Kerr RSC. The durability of endovascular coiling versus neurosurgical clipping of ruptured cerebral aneurysms: 18 year follow-up of the UK cohort of the International Subarachnoid Aneurysm Trial (ISAT). *Lancet Lond Engl* 2015;385:691-7.
- [27] Mortimer AM, Marsh H, Klimczak K, Joshi D, Barton H, Nelson RJ, et al. Is long-term follow-up of adequately coil-occluded ruptured cerebral aneurysms always necessary? A single-center study of recurrences after endovascular treatment. *J Neurointerventional Surg* 2015;7:373-9.
- [28] Dorfer C, Gruber A, Standhardt H, Bavinzski G, Knosp E. Management of residual and recurrent aneurysms after initial endovascular treatment. *Neurosurgery* 2012;70: 537-53. discussion 553-4.
- [29] Byrne JV, Sohn MJ, Molyneux AJ, Chir B. Five-year experience in using coil embolization for ruptured intracranial aneurysms: outcomes and incidence of late rebleeding. *J Neurosurg* 1999;90:656-63.