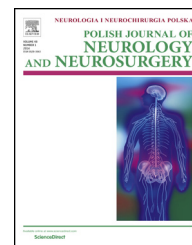

Available online at www.sciencedirect.com

ScienceDirect

journal homepage: <http://www.elsevier.com/locate/pjnns>

Original research article

Feasibility and accuracy of new insertion technique of S1 transpedicular screw. Computed tomography-based morphometric analysis

Łukasz Kubaszewski^a, Grzegorz Mięksiak^{b,*}, Andrzej Nowakowski^c,
Celina Pezowicz^d, Grzegorz Bajor^e, Zdzisław Kielbowicz^f, Wojciech Kinda^f,
Magdalena Wojtków^d, Jacek Kaczmarczyk^a

^a Department of Orthopedic and Traumatology, W. Dega University Hospital, Poznań, Poland

^b Department of Neurosurgery, Specialist Medical Center, Polanica-Zdrój, Poland

^c Department of Spine Surgery, Oncology, Orthopedics and Traumatology, W. Dega University Hospital, Poznań, Poland

^d Faculty of Mechanical Engineering, Wrocław University of Technology, Wrocław, Poland

^e Department of Human Anatomy, Medical University of Silesia, Katowice, Poland

^f Wrocław University of Environmental and Life Sciences, The Faculty of Veterinary Medicine, Wrocław, Poland

ARTICLE INFO

Article history:

Received 8 May 2016

Accepted 23 June 2016

Available online 1 July 2016

Keywords:

Anatomy

Pedicle screw

Sacrum

Entry point

ABSTRACT

Objective: To assess feasibility and accuracy of a new insertion technique of S1 transpedicular screw.

Summary of background data: Transpedicular stabilization in the first sacral vertebra (S1) is a technically demanding surgical procedure with inherent risk of loosening of the implant. A modification of the technique was recently proposed, along with the analytical verification which was performed based on the available literature. In the study, we performed radiological assessment of screws inserted into the S1 using the classical and modified techniques. **Methods:** The analysis was performed in two parts. The first part was performed on eight cadaver specimens after implantation of the screws. In the second part, we used computed tomography images of patients with degenerative disk disease with a superimposed representation of screws. The thickness of the posterior cortex adherent to the screws, screw trajectory and their position with regard to the spinal canal was measured. The area of posterior cortex in contact with the screws was also calculated.

Results: The contact length and area was found to be two times greater for screws introduced with the modified technique. The convergence angle was comparable between the techniques, despite the shift of entry point. There was no canal breach, although with the modified technique the screws passed closer to the spinal canal.

Conclusions: The modified technique is considered safe. In this technique, the screws pass through a thicker portion of the posterior cortex compared to the classical technique that aims at improving the stability of the fixation.

© 2016 Published by Elsevier Sp. z o.o. on behalf of Polish Neurological Society.

* Corresponding author at: Department of Neurosurgery, Specialist Medical Center, ul. Jana Pawła II 2, Polanica-Zdrój, 57-320 Poland. Tel.: +48 691 091 310.

E-mail address: gmięksiak@gmail.com (G. Mięksiak).

<http://dx.doi.org/10.1016/j.pjnns.2016.06.005>

0028-3843/© 2016 Published by Elsevier Sp. z o.o. on behalf of Polish Neurological Society.

1. Introduction

Pedicle screw fixation is the mainstay of stabilization in the thoracolumbar spine [1–4]. The technique requires the proper identification of entry-point followed by finding the optimal trajectory in order to achieve sufficient mechanical strength and structural risk minimization. In particular, fixation to the S1 vertebra seems to be technically demanding due to the lack of clear anatomical landmarks, such as transverse process.

In the current literature, the most widely recommended technique places the entry-point beneath and slightly lateral to the superior facet of the sacrum [5–9]. Other modifications to improve the stability make use of additional support points, such as the inclusion of the S2 vertebra. Some authors recommend perforation of the S1 superior end-plate by the screw apex [10,11].

In this work, another method is proposed, which moves the starting point from beneath and lateral to the superior facet to a more medial and rostral position, so that the starting point passes through the lower part of the superior facet rim of S1 after its partial removal (Fig. 1b) [12]. A rationale for the modification has been presented, with safety considerations regarding possible neural damage based on the anthropometric studies and quality of the bone tissue [9]. The key advantages of the new approach are: (1) unambiguous entry point definition, and (2) placing the screws within the superior S1 facet that enhances the purchase within the cortical bone, thus improving the mechanical strength. Theoretical foundations of the new technique have been laid out in an earlier study [13].

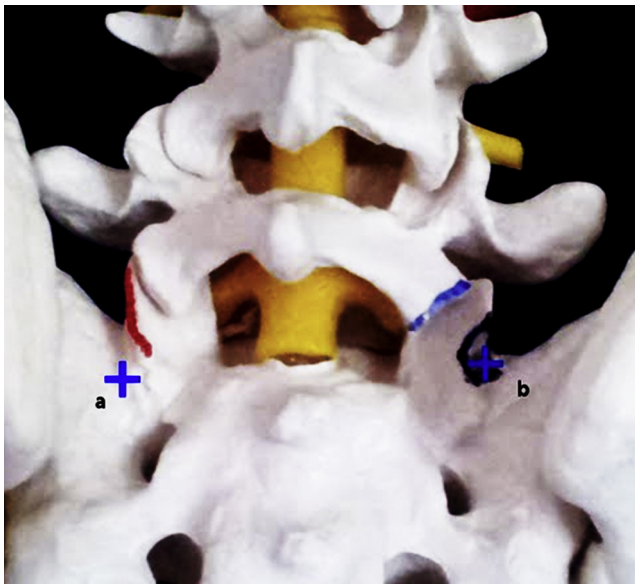


Fig. 1 – Presentation of the differences in starting points for the classical (a) and modified (b) techniques (red line – posterior border of the superior S1 facet, blue line – resection of the inferior L5 facet, black circumference – limited osteotomy site). (For interpretation of the references to color in this figure legend, the reader is referred to the web version of this article.)

The aim of this study was to analyze the radiological parameters of the new technique of placing the S1 screw and comparing them with the classical method.

2. Materials and methods

The assessment of the classical and modified techniques comprised of two parts. The first part of the analysis was performed with cadaver specimens (cadaver analysis: CA) with implanted transpedicular screws. The second part was a computed tomography (CT) morphometric analysis of simulated transpedicular screw placement on a casual sample of patients who underwent CT for spinal problems (intact sacrum image analysis: ISIA). In this part of the analysis, the presentation of the screws was superimposed over the relevant images.

2.1. Ethical statement

Written informed consents were obtained from the donors (CA) and alive participants (ISIA). The study was approved by the Bioethics Committee on 13 June 2013 (Reference no. 514/13).

Eight specimens of cadaver sacral bone were used. The mean age at death was 73 years (range = 70–85 years). The specimens were from three males and five females. In each specimen, two transpedicular screws of 6 mm in diameter were introduced into the S1. The screws on the left side were introduced according to the classical technique as described by Morse et al. [14]. On the right side, the screws were introduced using the modified technique [12], i.e., the screw was inserted into S1 through the superior facet at the rim of the articular surface after its partial removal. After implantation, CT scans of the specimens were performed (Fig. 2a–c). In the analysis, we took the following measurements in the transverse plane:

- (1) The length of contact of the screws with the posterior cortex on both the lateral and medial sides. The contact length was defined as the section of the screw surface adjoining to the posterior cortex.
- (2) Screw convergence angle with respect to the midline.
- (3) Least distance between the closest part of the screw and the spinal canal.

In the sagittal reconstruction, we measured: (1) The angle between the screw and the superior S1 end-plate; and (2) The distance of the screw thread ends, dorsal and ventral, to the superior S1 end-plate. Dorsal screw thread end was defined as the entry point into the sagittal plane.

ISIA scans were acquired from 50 (28 females and 22 males) consecutive patients who had degenerative disk disease of the lumbar spine with no history of operative treatment. The age range was 36–71 years. Among the scans performed in the transverse plane, we selected two scans that represented the entry point for S1 transpedicular screws, according to both the classical and modified techniques. After calibration of the absolute length on both sides, we superimposed a parallelogram on the selected scans that represented transpedicular screws perforating the dorsal cortical layer at a 30° convergence to the midline (Fig. 3a and b). The selection of the CT

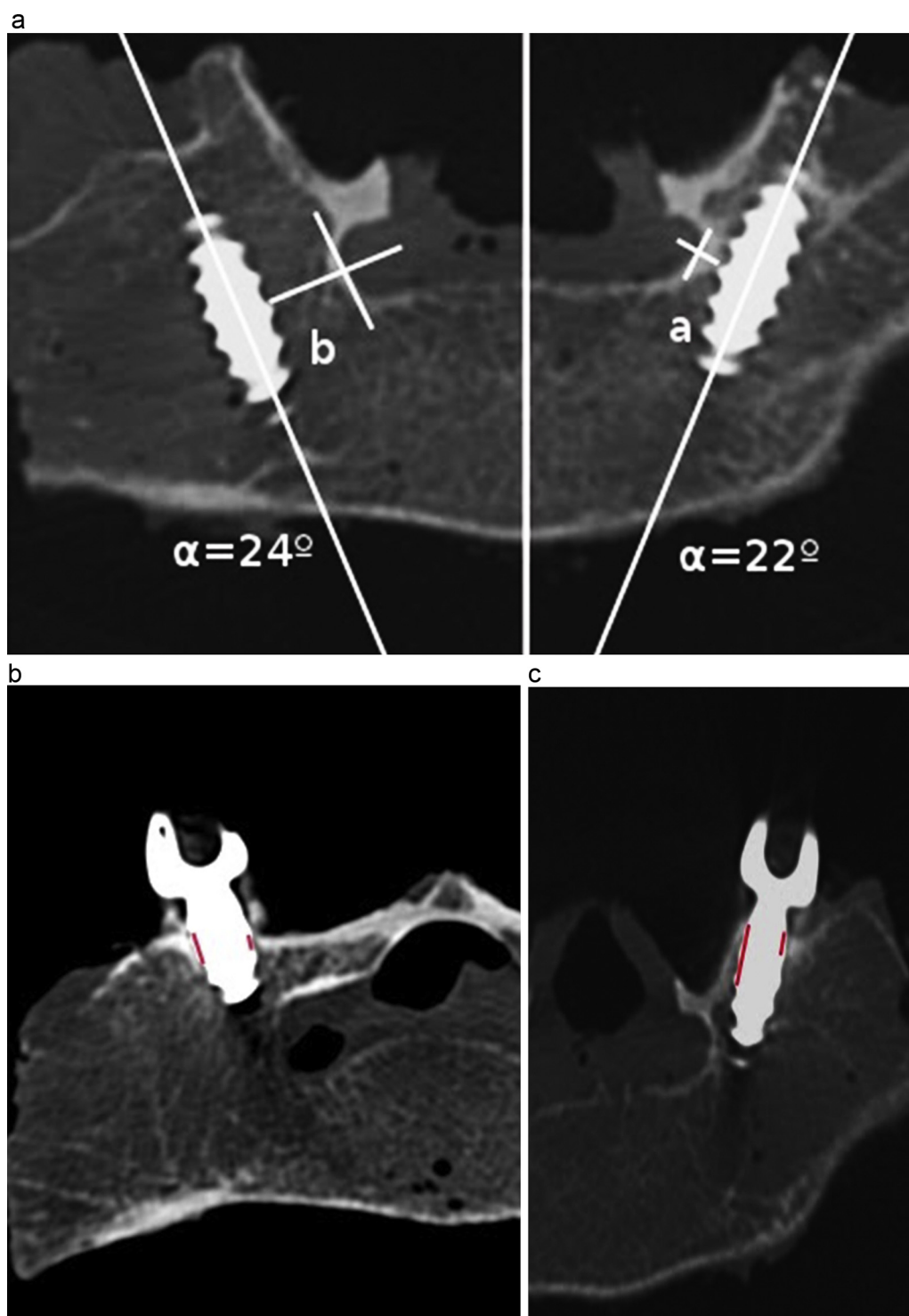


Fig. 2 – Computed tomography images from the cadaver group. (a) Convergence angle and distance from spinal canal of screws introduced with the modified (right side) and classical (left side) techniques. (b) Visualization of the posterior cortex adhering to the screw shaft (classical technique). (c) Visualization of the posterior cortex adhering to the screw shaft (modified technique).

layers for screw superimposition experienced in the spine surgery was collectively performed. The screws were presented as rectangles corresponding to a screw diameter of 6 mm. In the analysis, we measured the part of the circumference of the parallelogram crossing the posterior

cortex, representing the contact length of the screw representations with the posterior cortex, on both the lateral and medial sides for the classical as well as modified techniques.

We calculated the contact area between the screw and posterior cortex for both the techniques. During the calculation,

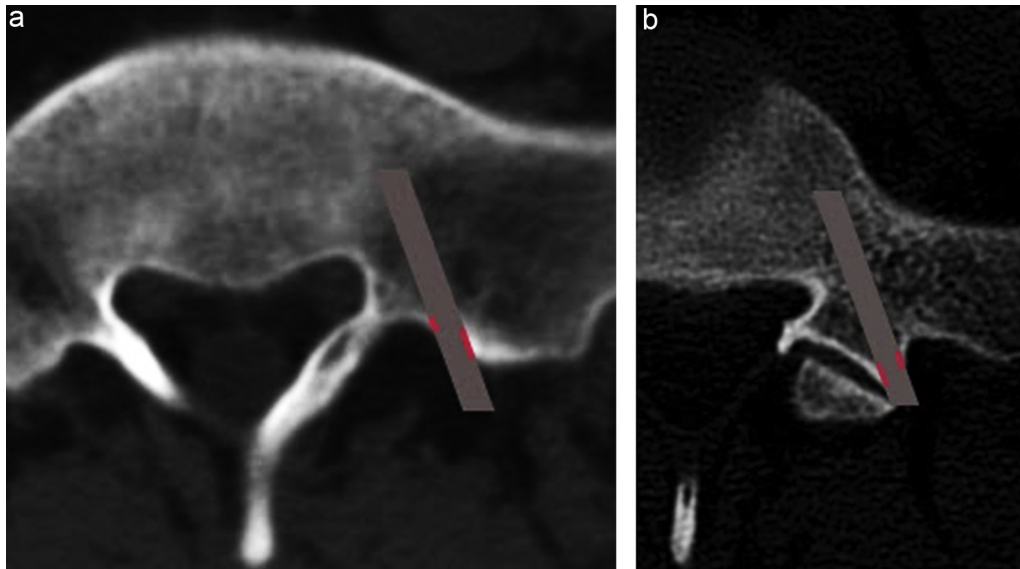


Fig. 3 – Representation of screws (gray rectangle), (a) superimposed on computer tomography image reflecting classical-method entry point in S1 and modified-method, (b) Red section represents contact length with posterior cortex. (For interpretation of the references to color in this figure legend, the reader is referred to the web version of this article.)

the absolute average lengths of lateral and medial contact needed for the determination of the cylinder height representing the contact surface between the screw and posterior cortex were excluded. In measurements, the medial contact length was found to be dominant. We decided to use a weighted average, in which the cranial and caudal contact lengths were assumed to be equal to the contact length at the lateral aspect.

2.2. Measurement tools

Measurements were performed on DICOM digital images with RadiAnt Dicom Viewer (Medixant, Poland). The measurement error of the tool was 0.1 mm.

2.3. Statistical analysis

To evaluate differences between the techniques in the CA group, we used the Mann–Whitney *U*-test. Student's *t*-test for dependent data was performed to compare the contact lengths and contact surface area for the classical and modified techniques in the ISIA group. Statistical significance was set to $p < 0.05$. Statistical software Statsoft (Tulsa, USA) was used.

3. Results

3.1. Cadaver analysis

The mean length of contact between the screw and dorsal cortex on the medial aspect was 5.15 mm (median 5.35 mm, range 1.5–8.2 mm) for the modified technique, and 2.90 mm (median 2.9 mm, range 0.7–5.1 mm) for the classical technique. The mean length of contact between the screw and dorsal cortex on the lateral aspect was 3.64 mm (median 3.45 mm,

range 2.6–5.3 mm) for the modified technique, and 2.41 mm (median 2.25 mm, range 1.3–4.5 mm) for the classical technique. For both the measurements, a difference between the two techniques was found to be statistically significant ($p = 0.02$).

The calculated mean surface area of contact between the screw and posterior cortical layer was 113.5 mm² (median 110.6 mm², range 85.5–149.8 mm²) for the modified technique, and 72.3 mm² (median 68.92 mm², range 40.2–113.8 mm²) for the classical technique. The difference between the two techniques was found to be statistically significant ($p = 0.006$). The contact area between the screw and posterior cortex of S1 was 61% greater in the modified technique.

The trajectory measurements of the screw are presented in Table 1. The mean convergence angle with respect to the midline for screws introduced with the modified technique was 24.6° (median 24.6°, range 16.8–35.6°).

For the classical technique, the mean convergence angle was 23.7° (median 23.2°, range 19.5–7.8°). The difference between the two techniques was not statistically significant ($p = 0.35$). The mean distance of the screw from the spinal canal with the modified technique was 3.59 mm (median 2.59 mm, range 1.3–8.7 mm). For the classical technique, the mean distance from the spinal canal was 7.0 mm (median 7.1 mm, range 1.4–17.9 mm). The difference between the two techniques was not statistically significant ($p = 0.06$).

With the modified technique, the mean distance of the entry point from the superior S1 end-plate was 9.7 mm (median 8.9 mm, range 3.4–16.2 mm). With the classical technique, the mean distance of the entry point from the superior S1 end-plate was 14.8 mm (median 15.0 mm, range 8.9–20.8 mm). With the modified technique, the mean distance of the screw tip from the superior S1 end-plate was 7.23 mm (median 6.4, range 3.3–13.6 mm). With the classical technique,

Table 1 – Measurements from the cadaver group for modified and classical technique.

Specimen	Transverse plane				Sagittal plane	
	Screw angle to mid-line [°]		Closest distance of the screw from spinal canal [mm]		Screw angle to end-plate	
	Modified	Classical	Modified	Classical	Modified	Classical
1	35.3	27.83	1.3	3.9	2.2	6
2	18.05	23.45	2.2	7.3	0.9	0.9
3	16.85	22.04	1.6	1.4	2.7	15
4	22.89	19.49	2.9	7.4	-15.4	0
5	27.09	19.65	8.7	2.8	11.5	19.8
6	28.7	24	2.2	6.9	0	11.8
7	22.1	25.3	3.5	8.3	15.5	15.5
8	26.4	24.8	6.3	17.9	2.1	11.7

the mean distance of the screw tip from the superior S1 end-plate was 6.7 mm (median 6.1 mm, range 5–11.9 mm). With the modified technique, the mean angle between the screw and superior end-plate was 5.4° of cranial orientation (median 2.7°, range 0–15.5°). The mean angle between the screw and superior end-plate with the classical technique was greater, at 9.86° of cranial orientation (median 8.9, range 0–19.8°). The differences were not statistically significant ($p = 0.16$).

3.2. Intact sacrum image analysis

The mean length of the contact between the screw and dorsal cortex on the medial aspect of the screw was 6.6 mm (SD 5.9 mm) for the modified technique, and 3.9 mm (SD 2.8 mm) for the classical technique. The mean length of contact between the screw and dorsal cortex on the lateral aspect was 4.3 mm (SD 2.7 mm) for the modified technique, and 1.9 mm (SD 0.7 mm) for the classical technique. The differences in the contact length (measured separately for the medial and lateral sides) between the two techniques were found to be statistically significant. The calculated surface area of contact between the screw and posterior cortical layer was 112.62 mm² (SD 50.6 mm²) for the modified technique and 45.9 mm² (SD 15.5 mm²) for the classical technique. The contact area was 2.5 times greater with the modified technique, and the difference between the two techniques was found to be statistically significant.

4. Discussion

Although several radiological analyses have been performed for transpedicular screws, they only investigated the accuracy of the screw placement with respect to the sacral canal or anterior cortex perforation and iliac crest conflict [8,15,16]. To the best of our knowledge, no studies so far have evaluated the radiological parameters of the bone in the proximity of the screw, although these parameters are known to influence the stability of the fixation. The morphometric analysis used in this study is similar to those previously performed to evaluate other modifications [17].

We performed the analysis with two different groups to compare the analytical methods as well as obtained complementary data for convincing conclusions. In the case of cadaver group, we were able to observe the actual screw

trajectory, which can change as the result of potential anatomical determinants. In the CA group, accurate measurements of the cortex adjacent to the screw shaft were impaired due to reflections produced by the metal implants and by the adjustments that were made to the imaging to allow for clear visualization of the anatomy. In addition, it is possible that the posterior cortex could have been mechanically modified by the implantation process. Potential differences between the CA and ISIA groups may also have been influenced by the different age spans of the two groups.

There were also possible limitations with respect to the ISIA group analysis. In the ISIA group, images representing the screws were superimposed arbitrarily by orthopedic surgeons over plain CT scans that represented the entry point levels. Although the surgeons were familiar with the radiological images, we cannot be sure that intraoperative recognition of the 3D anatomy was transferred without error to the CT scans. Further, in the CA group, we had threaded implants, while in the ISIA group, the screws were represented by regular rectangles. In our opinion, comparing the results from the two groups improved the strength of the analysis.

Analyses of both the CA and ISIA groups confirmed that the contact length between the screw and posterior cortex was greater in the modified technique. Consequently, the calculated anchoring surface area in the posterior cortex was higher with the modified technique by 160–250% compared to the classical technique. This improved the purchase of screw with the posterior cortex of the sacrum that aims at decreasing the risk of both the bone fracture and loosened implants.

The increase in the cortical thickness is related to the anatomical characteristics, as presented by Richards et al. [18], who showed an increased density of the posterior cortex in the medial direction. It should be noted that with the modified technique, the starting point in S1 is such that the screw passes through the superior facet, which may be altered by the osteoarthritic changes commonly observed in the degenerative diseases (e.g., spur formation). Additionally, in modified technique, posterior cortex forms the “sleeve” adhering to the dorsal thread (Fig. 2c) causing an increase in the contact area, where in the classical technique screw and cortex are oriented almost perpendicularly (Fig. 2b).

In the CA group, we were able to analyze the screw trajectory with both the modified and classical techniques. The main feature of the modified technique was that the entry point was located more medially and caudally compared to the

classical technique. Although a previously published evidence-based analysis confirmed the safety of the modification [12], it could pose a higher risk of perforating the spinal canal, with the possible neurological sequel. However, in our analysis, we observed no perforations of the neural canal, although the screws did tend to pass closer to it in the modified technique as compared to the classical technique. The convergence angle of the two techniques did not differ significantly. The optimal sacral pedicle anteromedial screw trajectory angle proposed by Arman et al. was recorded as $33.80^\circ \pm 4.34^\circ$ [19]. With both methods, in most of the cases, we did not obtain the ideal convergence angle proposed in the literature. In our analysis, we observed that moving the starting point more medially did not influence the convergence angle. Interestingly, the upper distance of the convergence angle was observed to be greater with the modified technique. In some cases, as we analyzed the implantation procedure with the classical technique, introduction of the screw with more lateral entry point was obstructed by the posterior part of the iliac wing forcing a steeper screw placement [20]. Thus, a medial shift of the entry point allowed more freedom with respect to the convergence angle selection. It is important to mention that the reference anatomy analysis performed by Arman et al. [19] was on sacra prepared at the sacroiliac joints, without considering the anatomy of the iliac wings.

Modification of the starting point also did not seem to be significantly influenced by the screw trajectory in the sagittal plane. Having the starting point closer to the end-plate allowed for a more-shallow screw trajectory with respect to the superior S1 end-plate, with the tip of the screws located at a similar position in the two groups. A screw path closer to the S1 end-plate may influence the stability of the screw as it passes through the trabecular bone of higher density [21].

5. Conclusions

Our analysis showed that with the modified technique for S1 screw implantation, there is a 1.6–2.5-fold greater surface area of contact between the screw and posterior cortex of S1.

We found that the starting point modification does not alter the screw trajectory and does not pose a higher risk of spinal canal perforation.

Conflict of interest

None declared.

Acknowledgement and financial support

None declared.

Ethics

The study was approved by the Bioethics Committee on 13 June 2013 (Reference no. 514/13).

REFERENCES

- [1] Nowakowski A, Dworak LB, Kubaszewski Ł, Kaczmarczyk J. Spinal alignment in surgical, multisegmental, transpedicular correction of adolescent idiopathic scoliosis. *Med Sci Monit* 2012;18:RA181–7.
- [2] Esenkaya I. A morphologic evaluation of the sacroiliac joint and plate fixation on a pelvic model using a S1 pedicular screw, transiliosacral screws, and a compression rod for sacroiliac joint injuries. *Acta Orthop Traumatol Turc* 2002;36:432–41.
- [3] Ferro FP, Borgo GD, Letaif OB, Cristante AF, Marcon RM, Lutaka AS. Traumatic spondylolisthesis of the axis: epidemiology, management and outcome. *Acta Orthop Bras* 2012;20:84–7. <http://dx.doi.org/10.1590/S1413-78522012000200005>
- [4] Bostan B, Esenkaya I, Gunes T, Erdem M, Asci M, Kelestemur MH, et al. A biomechanical comparison of polymethylmethacrylate-reinforced and expansive pedicle screws in pedicle-screw revisions. *Acta Orthop Traumatol Turc* 2009;43:272–6. <http://dx.doi.org/10.3944/AOTT.2009.272>
- [5] Esses SI, Botsford DJ, Huler RJ, Rauschnig W. Surgical anatomy of the sacrum. A guide for rational screw fixation. *Spine (Phila Pa 1976)* 1991;16:S283–8.
- [6] Xu R, Ebraheim NA, Gove NK. Surgical anatomy of the sacrum. *Am J Orthop (Belle Mead NJ)* 2008;37:E177–81. <http://dx.doi.org/10.1097/00007632-199106001-00021>
- [7] Roy-Camille R, Saillant G, Mazel C. Internal fixation of the lumbar spine with pedicle screw plating. *Clin Orthop Relat Res* 1986;7:17. <http://dx.doi.org/10.1097/00003086-198602000-00003>
- [8] Mirkovic S, Abitbol JJ, Steinman J, Edwards CC, Schaffler M, Massie J, et al. Anatomic consideration for sacral screw placement. *Spine (Phila Pa 1976)* 1991;16:S289–94. <http://dx.doi.org/10.1097/00007632-199106001-00022>
- [9] Cotrel Y, Dubousset J, Guillaumat M. New universal instrumentation in spinal surgery. *Clin Orthop Relat Res* 1988;227:10–23.
- [10] Margulies JY, Floman Y, Farcy J-P, Neuwirth MG, editors. *Lumbosacral and spinopelvic fixation*. Philadelphia: Lippincott-Raven; 1996.
- [11] Luk KDK, Chen L, Lu WW. A stronger bicortical sacral pedicle screw fixation through the s1 endplate: an in vitro cyclic loading and pull-out force evaluation. *Spine (Phila Pa 1976)* 2005;30:525–9. <http://dx.doi.org/10.1097/01.brs.0000154649.55589.bf>
- [12] Kubaszewski L, Kaczmarczyk J, Nowakowski A. A modified technique of placing transpedicular screws into the S1 vertebrae—surgical technique note. *Polish Orthop Traumatol* 2013;78:101–4.
- [13] Kubaszewski L, Nowakowski A, Kaczmarczyk J. Evidence-based support for S1 transpedicular screw entry point modification. *J Orthop Surg Res* 2014;9:22. <http://dx.doi.org/10.1186/1749-799X-9-22>
- [14] Morse BJ, Ebraheim NA, Jackson WT. Preoperative CT determination of angles for sacral screw placement. *Spine (Phila Pa 1976)* 1994;19:604–7.
- [15] Smith SA, Abitbol JJ, Carlson GD, Anderson DR, Taggart KW, Garfin SR. The effects of depth of penetration, screw orientation, and bone density on sacral screw fixation. *Spine (Phila Pa 1976)* 1993;18:1006–10. <http://dx.doi.org/10.1097/00007632-199306150-00009>
- [16] Robertson PA, Plank LD. Pedicle screw placement at the sacrum: anatomical characterization and limitations at S1. *J Spinal Disord* 1999;12:227–33.
- [17] Matsukawa K, Yato Y, Nemoto O, Imabayashi H, Asazuma T, Nemoto K. Morphometric measurement of cortical bone

- trajectory for lumbar pedicle screw insertion using computed tomography. *J Spinal Disord Tech* 2013;26:E248-53. <http://dx.doi.org/10.1097/BSD.0b013e318288ac39>
- [18] Richards AM, Coleman NW, Knight TA, Belkoff SM, Mears SC. Bone density and cortical thickness in normal, osteopenic, and osteoporotic sacra. *J Osteoporos* 2010;2010. <http://dx.doi.org/10.4061/2010/504078>
- [19] Arman C, Naderi S, Kiray A, Aksu FT, Yilmaz HS, Tetik S, et al. The human sacrum and safe approaches for screw placement. *J Clin Neurosci* 2009;16:1046-9. <http://dx.doi.org/10.1016/j.jocn.2008.07.081>
- [20] Kaptanoglu E, Okutan O, Tekdemir I, Beskonakli E, Deda H. Closed posterior superior iliac spine impeding pediculocorporeal S-1 screw insertion. *J Neurosurg* 2003;99:229-34. <http://dx.doi.org/10.3171/spi.2003.99.2.0229>
- [21] Zheng Y, Lu WW, Zhu Q, Qin L, Zhong S, Leong JC. Variation in bone mineral density of the sacrum in young adults and its significance for sacral fixation. *Spine (Phila Pa 1976)* 2000;25:353-7. <http://dx.doi.org/10.1097/00007632-200002010-00016>