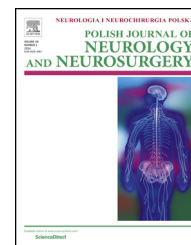


Available online at www.sciencedirect.com

ScienceDirect

journal homepage: <http://www.elsevier.com/locate/pjnns>

Original research article

Surgery for sporadic vestibular schwannoma. Part III: Facial and auditory nerve function



Przemysław Kunert, Tomasz Dziędzic*, Anna Podgórska, Tomasz Czernicki,
Arkadiusz Nowak, Andrzej Marchel

Department of Neurosurgery, Medical University of Warsaw, Warszawa, Poland

ARTICLE INFO

Article history:

Received 14 June 2015

Accepted 31 August 2015

Available online 6 September 2015

Keywords:

Vestibular schwannoma

Retrosigmoid approach

Functional outcome

Facial nerve

Hearing preservation

ABSTRACT

Objective: The aim of this analysis was to assess short-term and long-term outcomes with respect to the preservation of facial and auditory nerve function following surgery for sporadic vestibular schwannomas.

Material and methods: The study included 220 consecutive patients operated on with the retrosigmoid (217) or translabyrinthine (3) approach. The mean extrameatal diameter of the tumor was 30 mm. In 217 patients, gross total resection was performed and near-total in 3. Before surgery, the facial nerve (CNVII) weakness was found in 18% of patients and only 20% had serviceable hearing. Intraoperative neurophysiological CNVII monitoring was routinely used (the last 211 procedures). Intraoperative monitoring of the cochlear nerve function was used when the preservation of hearing was attempted (45 procedures).

Results: The rate of CNVII continuity loss during surgery was 11%, however, this decreased to 6% in the second half of the series. Facial nerve function deteriorated, in 88% of the patients shortly after surgery. However, it improved in 87% in follow-up. Delayed CNVII palsy was found in 5% of the patients and had a good prognosis in 88%. Final satisfactory CNVII function (CNVII-SF, HB grades I–III) was achieved in 76% of the patients when excluding the anastomosis results, and 87% when including them. In recent years, the rate of CNVII-SF has risen to 94%. Non-serviceable hearing was preserved in 49% of the patients, on whom it was attempted.

Conclusion: Considering the size of the tumors and extent of the resections, the preservation of CNVII function is currently very high. A close surveillance of CNVII function evolution following surgery is mandatory, as 2/3 of the patients discharged with deep paresis will need different face reanimation procedures. The preservation of useful hearing is still problematic, especially in patients with large tumors.

© 2015 Polish Neurological Society. Published by Elsevier Sp. z o.o. All rights reserved.

* Corresponding author at: Klinika Neurochirurgii, Warszawski Uniwersytet Medyczny, ul. Banacha 1a, 02-097 Warszawa, Poland.

Fax: +48 22 658 36 53.

E-mail address: tomasz_dziedzic@wp.pl (T. Dziędzic).

<http://dx.doi.org/10.1016/j.pjnns.2015.08.008>

0028-3843/© 2015 Polish Neurological Society. Published by Elsevier Sp. z o.o. All rights reserved.

1. Introduction

The neurosurgical approach to vestibular schwannoma treatment has essentially come full circle. In the era of Cushing, the aim of the treatment was to save lives at the expense of less radical surgery. Subsequently, neurosurgeons such as Dandy and Olivecrona strived for oncological cures. In the last decades of the 20th century, thanks to House and Samii, the aim of the treatment became total tumor resection with preservation of facial and auditory nerve function. Currently, a trend toward less radical VS surgery is seen again, which can be justified by the benign and slow growing nature of the tumor, as well as by the reduction of the risk of facial and auditory nerve dysfunction [1,2]. In these cohorts, nerve function preservation is exquisite, but only extended follow-up of 10–20 years can confirm the rationale of this approach.

The principles of vestibular schwannoma treatment in the Department of Neurosurgery, Medical University of Warsaw, are based on the ideas put forward by Samii and Matthies [3]. This means that the main goal of the treatment is to assure a permanent cure by complete tumor resection, as most patients are middle-aged and still have a long life expectancy. At the same time, however, attempts are made to preserve facial and auditory nerve function. The routine use of intraoperative neurophysiological monitoring methods has made the preservation of facial and auditory nerve function feasible even with radical surgery.

The aim of this analysis was to assess short-term and long-term outcomes with respect to the preservation of facial and auditory nerve function following surgery for sporadic vestibular schwannomas.

2. Materials and methods

The group of patients that was analyzed is characterized in the paper titled: "Surgery for sporadic vestibular schwannoma. Part I: General outcome and risk of tumor recurrence." The anatomical and functional preservation of CNVII was evaluated in three time frames: intraoperative, in the short term, and in the long term. One patient was excluded from the intraoperative analysis due to prior hypoglossal-facial nerve anastomosis performed at a different hospital (219 patients included). From the short-term postoperative analysis, one patient who died shortly after surgery was also excluded (218 patients included). From the long-term postoperative analysis, one patient lost to follow-up was additionally excluded (217 patients included).

Facial nerve weakness before surgery was found in 40 (18.2%) patients, including all seven patients who had received prior treatment for VS in other centers. Only 45 (20%) patients had serviceable hearing (AAO-HNS: class A and B, Table 1) before surgery.

2.1. Perioperative management with respect to the preservation of facial and auditory nerve function

Electroneurography of CNVII and electrically evoked blink reflexes were carried out in the preoperative period. Direct

Table 1 – Facial and auditory nerves function at pre-sentation.

Auditory nerve function (AAO-HNS)	Number of patients	%
Class A	9	4.1
Class B	36	16.4
Class C	6	2.7
Class D	169	76.8
Facial nerve function (HB grade)	Number of patients	%
I	180	81.8
II	28 (1 ^a)	12.7
III	7 (3 ^a) (1 ^b)	3.2
IV	2	0.9
V	1 (1 ^a)	0.5
VI	2 (2 ^a)	0.9

^a Including patients previously operated on and/or treated with SRS in other center.
^b Patient after hypoglossal-facial anastomosis in other center.

latencies and amplitudes of responses from the orbicularis oculi, orbicularis oris, and nasalis muscles were registered. The latencies of the R1 (unilaterally) and R2 (bilaterally) reflex responses were measured and compared. Immediately prior to surgery, patients were given 32 mg of dexamethasone intravenously. After surgery, dexamethasone was administered in decreasing doses over a period of seven days. Nimodipine was routinely administered since August 2009 (the last 50 patients), at a dose of 60 mg four times a day, starting 3 days before surgery and continuing up to day 7 post-surgery. In duly justified cases, i.e., when severe CNVII paresis (HB grades IV–VI) was observed, despite continuity preservation, intravenous infusion of nimodipine was administered via a central catheter at a rate of 10 ml (2 mg) nimodipine solution per hour.

Since 1994, intraoperative neurophysiological CNVII function monitoring was routinely used (the last 211 procedures). The following parameters were monitored simultaneously: 1. spontaneous EMG activity of the orbicularis oculi and orbicularis oris muscles with intermittent CNVII stimulation, 2. motor evoked potentials of the orbicularis oris muscle evoked by transcranial stimulation of the motor cortex, 3. orbicularis oculi muscle activity following unilateral supra-orbital nerve stimulation to evaluate the blink reflex (short-latency R1 response).

Sulfacetamide sodium ophthalmic solution 10% was administered locally every 2–4 h for conjunctivitis prophylaxis in all patients during a period of 3–7 days after surgery. Dexpanthenol gel 5% was administered overnight in patients with eyelid closure insufficiency. In these patients, an additional prophylaxis was applied: a simple cardboard cover on the eye in 58 patients (in the early years of the series), a moisture chamber in 24 patients and/or gold plate implantation in 51 patients.

Early rehabilitation of the facial muscles was introduced in the first day post-surgery in all cases of CNVII paresis. In patients with severe CNVII weakness, follow-up EMG at 3, 6 and 9 months post-surgery was planned.

Intraoperative monitoring of the cochlear nerve function, with the use of ABR and/or transtympanic ECochG (since 2004)

was used when preservation of hearing was theoretically possible and worth the effort (45 procedures). Nevertheless, continuity preservation of the auditory nerve was always attempted when technically possible, independent of the tumor size and grade of hearing loss.

Treatment outcome was assessed in the following categories:

1. CNVII continuity preservation during surgery. The outcome in this case was binary: the continuity could either be preserved or not preserved. In 3 cases, the facial nerve was partially damaged, i.e., some fibers were preserved and some transected. In these patients, end-to-end anastomoses of the transected fibers were made. All 3 cases were included in the group with preserved continuity, as less than half of the nerve fibers were transected.
2. CNVII function in the short term. CNVII function was evaluated at discharge, according to the House–Brackmann scale (HB).
3. CNVII function in long-term follow-up, i.e., at least 6 months after surgery. This analysis aims to evaluate treatment outcome without additional reconstructive procedures of the facial nerve, but takes into account the natural regeneration of CNVII only. For this reason, in this part, CNVII anastomosis results were omitted and those patients were treated as if still having CNVII palsy. House–Brackmann grades I–III were defined as a satisfactory outcome (patients with preserved facial symmetry at rest and able to close their eyelids), whereas grades IV–VI as unsatisfactory. House–Brackmann grades I–II were considered as very good results.
4. Delayed CNVII paresis. Delayed CNVII paresis was defined as a deterioration in facial nerve function of at least one HB grade, occurring at least 3 days following surgery [4].
5. Relative CNVII function evaluation. CNVII function in the short term was compared to the preoperative function. CNVII function in long-term follow-up was compared to the short-term result. Here, three outcomes were possible: deterioration, no change, or improvement.
6. Final CNVII functional results. The long-term CNVII function including the anastomosis results.
7. Evaluation of hearing after surgery. Following surgery, hearing was evaluated only in patients on whom preservation of hearing was attempted. In these cases, intraoperative cochlear nerve function monitoring was planned. Hearing was assessed according to the AAO-HNS scale.

3. Results

3.1. Continuity preservation of the facial nerve

Among 219 patients, continuity preservation was achieved in 194 (88.6%). The facial nerve was transected in 25 (11.4%) cases with subsequent end-to-end anastomosis during the same procedure performed on 13 patients. In the first eight patients, surgery was performed without electrophysiological monitoring of the facial nerve function. Nevertheless, structural continuity was accomplished in all of them. In the remaining group of 211 patients, with intraoperative monitoring, CNVII

Table 2 – Intraoperative anatomical and functional CNVII preservation.

No intraoperative monitoring of CNVII function	Anatomical continuity preserved	8 (3.7%)
	Anatomical continuity not preserved	0 (0%)
Operations with monitoring of CNVII function	Function preserved	156 (71.2%)
	Anatomical integrity preserved only, with the lack of response to final EMG stimulation	30 (13.7%)
	Anatomical integrity preserved	25 (11.4%)

continuity was preserved in 186 patients, of whom 156 were responsive and 30 unresponsive to the final intraoperative EMG stimulation following tumor resection (Table 2). The risk of CNVII continuity loss decreased to 6% in the second half of the analyzed series.

Three patients, in whom the CNVII was partially transected required end-to-end anastomosis of transected fibers. One of these nerves remained responsive to the final intraoperative stimulation and two nerves were unresponsive.

3.2. Facial nerve function in the short term

At discharge, only 18 (8.3%) patients did not have any CNVII dysfunction. In the remaining 200 patients (91.7%), we noted CNVII paresis of varying degrees (HB grades II–VI). Satisfactory early outcome was noted in 85 (39%) patients (Table 3). In the

Table 3 – The facial nerve functions at early and late follow-up.

CN VII function (HB grade)	Number (%)	Rate of satisfactory outcome (HB grades I–III)
Early outcomes		
I	18 (8.3%)	Satisfactory outcome 39%
II	27 (12.4%)	
III	40 (18.3%)	
IV	72 (33.0%)	Unsatisfactory outcome 61%
V	34 (15.6%)	
VI	27 (12.4%)	
Late outcomes (without CN VII anastomosis results)		
I	74 (34.1%)	Satisfactory outcome 76%
II	68 (31.3%)	
III	23 (10.6%)	
IV	11 (5.1%)	Unsatisfactory outcome 24%
V	14 (6.5%) ^a	
VI ^c	27 (12.4%) ^a	
Late outcomes (including CN VII anastomosis results)		
I	74 (34%)	Satisfactory outcome 87%
II	74 ^b (34%)	
III	41 ^c (19%)	
IV	14 (7%)	Unsatisfactory outcome 13%
V	7 (3%)	
VI	7 (3%)	

^a In many patients with HB grades V–VI facial nerve anastomosis was performed, but their results are omitted here.

^b Including 6 patients with end-to-end CNVII anastomosis.

^c Including 20 patients with different types of CNVII anastomosis.

remaining 133 (61%) patients, CNVII paresis of HB grades IV–VI was observed. Despite the routine use of a prophylactic cardboard cover on the affected eye, five patients developed severe conjunctivitis with corneal ulceration requiring ophthalmological management. Over the last five years, no severe ophthalmological complications occurred in the analyzed series. Similarly, no severe ophthalmological complications were found in patients treated with a moisture chamber and/or gold plate implantation.

3.3. Delayed facial nerve paresis

Occurred in 8 patients (4 men, 4 women), aged from 34 to 67 years old (mean 53 y.o.). If patients in whom a delayed CNVII paresis was theoretically possible are taken into account (i.e., patients with preserved CNVII continuity, function of HB grades I–IV over the first 3 days post-surgery), then the incidence of this complication was 5% (8/159). The onset of delayed CNVII paresis varied from 4 days to over 3 weeks (mean 10 days) after surgery. In 3 patients, delayed CNVII paresis was found after discharge. This complication was treated with steroids. A gold plate was implanted in three patients and a moisture chamber was used in the remaining patients. In all but one patient, the paresis was absent or significantly decreased at 6-month follow-up. In the long term, very good CNVII function (HB grades I–II) was achieved in 7 (88%) patients. In the oldest patient in this subgroup, no spontaneous regeneration of the CNVII was observed. In this case, HHFA was performed at 10 months following surgery with good results (HB grade III).

3.4. Facial nerve function in the long term

Until the last follow-up visit, a very good outcome (HB grades I–II) was found in 142 (65.4%) patients, whereas a satisfactory outcome (HB grades I–III) in 165 (76%) patients (Table 3). In 53 (24%) patients, effective CNVII regeneration did not occur or was not possible due to an intraoperative nerve disruption.

3.5. Evolution of facial nerve function from admission to discharge

Among patients who did not demonstrate CNVII paresis on admission, deterioration of the CNVII function was noted in 90% (161/179) in the short term after surgery. Among patients with HB grades II–V weakness on admission, deterioration was found in 86% (31/36). Two patients, who presented with CNVII palsy, did not change until discharge (Table 4). An overall deterioration rate of CNVII function was noted in 192 patients (88%) directly after surgery.

3.6. Evolution of CNVII function from discharge to the last follow-up

Results of CNVII anastomosis are not included here. Eighteen patients had no CNVII paresis (HB grade I) at discharge, which remained stable in the long term. Until long-term follow-up, CNVII function improved in 86.5% (149/172) of the patients with a paresis of HB grades II–V at discharge. Eighty-three percent of these patients (143/172) had satisfactory nerve function.

Table 4 – Evolution of CNVII function.

Change of CNVII function between admission and discharge from hospital			
Before surgery		Early outcome	
HB grade	Number	Change of CNVII function	Number (%)
I	179	No change	18 (10%)
		Deterioration	161 (90%)
II	28	No change	2 (7%)
		Deterioration	26 (93%)
III	6	No change	2 (33%)
		Deterioration	4 (67%)
IV	2	No change	1(50%)
		Deterioration	1(50%)
V	0	No change	0
		Deterioration	0
VI	2	No change	2 (100%)
		Deterioration	0
Change of CNVII function between discharge from hospital and late follow-up			
Early outcome		Late outcome	
HB grade	Number	Change of CNVII function	Number (%)
I	18	No change	18 (100%)
		Improvement to I ^a	24 (86%)
II	27	No change	3 (14%)
		Improvement to I ^a –II ^a	39 (97%)
III	40	No change	1 (3%)
		Improvement to I ^a –III ^a	67 (93%)
IV	72	No change	5 (7%)
		Improvement to I ^a –III ^a	13 (39%)
V	33	Improvement to IV ^a	6 (18%)
		No change ^b	14 (42%)
VI	27	No change ^b	27 (100%)

^a Improvement to HB grade IV is not satisfactory.

^b This group also contains the patients after CNVII anastomosis, but their results are not included here.

Among patients with HB grade IV at discharge, only 5 (7%) patients did not achieve satisfactory regeneration. However, among patients with HB grade V at discharge, satisfactory functional improvement was not seen in 20 patients (61%).

The group of 27 patients with HB grade VI at discharge includes 24 patients with transected nerves, of whom 23 were eligible for further reconstructive procedures. In one patient, effective spontaneous regeneration from the healthy side appeared which led to an improvement to HB grade IV. In the remaining 3 patients with HB grade VI, successful nerve regeneration did not occur in the long term in spite of preserved CNVII continuity (Table 4).

Among the group of 154 patients with preserved CNVII function confirmed electrophysiologically during surgery, 72 (47%) were discharged with HB grades IV–VI. Of these 72 patients, 16 (22%) had unsatisfactory long-term outcome.

Among the group of patients with preserved nerve continuity but negative final EMG stimulation, 93% (28/30) had HB grades IV–VI at discharge. Nevertheless, an improvement to HB grades I–III in the long term was not seen in only 25% (7/28).

Among 174 patients with preserved CNVII continuity but with HB grades II–VI at discharge, 148 (85.1%) improved by at least one HB grade in the long term.

Of the 107 patients with preserved CNVII continuity but with HB grades IV–VI at discharge, 80 (74.8%) improved to HB grades I–III in the long term. In other words, in 1 out of 4 patients with a severe CNVII weakness at discharge, satisfactory CNVII regeneration did not occur despite the fact that its continuity was preserved. If only patients with a CNVII paresis of HB grades V–VI in the short term are considered, then a satisfactory regeneration did not occur in as many as 62.9% (22/35) of the patients, despite the fact that CNVII continuity was maintained.

3.7. Final CNVII functional results (including anastomosis results)

Satisfactory outcome was found in 87% of the patients, including 68% with very good results (HB grades I–II, Table 3). Satisfactory CNVII function was achieved through various CNVII anastomosis techniques in 26 patients: end-to-end anastomosis in 8, end-to-end after partial nerve injury in 2, HHFA in 11 and HFA in 5.

Among 98 patients operated on over the last 5 years of the analyzed period, a satisfactory outcome was achieved in 92 (94%), of whom 72 (73%) had HB grades I–II. In 14 patients of that group, a satisfactory outcome was attributable to CNVII anastomosis.

3.8. Treatment failure analysis

A critical appraisal of the treatment outcomes shows that in the long term, a satisfactory CNVII function was not achieved in 13%, of whom only 10 out of 28 patients had a surgery-related CNVII interruption. Eight CNVII anastomosis, including 5 end-to-end procedures and 2 myoplastic surgeries were unsuccessful.

An extratemporal CNVII anastomosis was offered to the other 7 patients, but they did not consent. They were 4 men and 3 women, aged from 33 to 61 years (mean 48 years). For comparison, the group of 12 patients who agreed to have extratemporal CNVII anastomosis included 12 female and 6 male, aged from 18 to 67 years (mean 44 years). Another five patients did not come regularly for follow-up visits despite deep CNVII weakness, which resulted in persistent nerve paresis.

3.9. Hearing preservation

Among 45 patients with useful hearing before surgery and on whom hearing preservation surgery was attempted, a certain range of hearing was preserved in 22 (49%). Nevertheless, in all of these cases, the hearing was not useful after surgery (AAO-HNS Class D). In the group of patients with preserved hearing, predominantly small tumors were found: T2 – five, T3A – five, T3B – six, T4A – three, T4B – three, i.e., only 27% of the tumors were staged at T4. The mean size was 2.1 cm, and the mean volume 6 cm³. Nine patients with preserved hearing experienced chronic tinnitus unilaterally on the side that was operated on. In 4 of these patients, the tinnitus was troublesome.

4. Discussion

4.1. Continuity preservation of the facial nerve

The CNVII continuity was preserved in 88.6% of the operated patients. In the cohort of Samii, encompassing one thousand vestibular schwannoma surgeries, the anatomical CNVII continuity was preserved in 93% [3]. A value of over 98% has been reported in recent studies [5], which is attributable to less radical surgery [6].

In the subgroup of the last 110 surgeries in our series, the incidence of CNVII interruption decreased to 6%. This rate can be regarded as a satisfactory outcome when the size of the tumors and the radical strategy of surgical treatment are taken into account.

4.2. Facial nerve function after surgery and its evolution

At discharge, only 39% of the operated patients had a satisfactory CNVII function. Deterioration of CNVII function occurs in 9 out of 10 patients immediately after surgery, but if the CNVII is anatomically preserved, its function improves in 9 out of 10 patients within 6 months. Shortly after surgery, the majority of patients experience at least a transient CNVII paresis [7–9]. Therefore, there is a tendency to present only long-term results, which are much more satisfactory. Outcomes regarding CNVII function in the short term after surgery, despite being rarely reported, are important for several reasons. Until nerve regeneration takes place, patients should remain under constant care in order to monitor the evolution of the CNVII function as well as to prevent ophthalmological complications. This period is also important for active facial muscle rehabilitation. When no improvement is found, more radical management for facial reanimation should be used in a timely manner [10]. Furthermore, CNVII function at discharge might have a prognostic value with respect to long-term improvement.

In the long term, three-quarters of the patients from our series achieved satisfactory functional outcome when excluding the anastomosis results. When adding the CNVII anastomosis results, the rate of satisfactory CNVII function increases to 87%. A satisfactory outcome was achieved in 94% over the last 5 years of the analyzed period. Preservation of very good CNVII function (HB grades I–II) is achieved in 90% of the cases at centers specializing in VS surgery. The risk of persistent CNVII paralysis can be as low as 1.5% [8]. On the other hand, a meta-analysis performed by Sughrue et al., encompassing 11,873 patients showed that the preservation of a very good CNVII function in the long term is achieved in 78% of the patients operated on via the retrosigmoid approach [11]. Gurgel et al. published a meta-analysis on VS surgery outcomes for tumors >2.5 cm in relation to surgical approach sites and the extent of resection. Following RSA, 65% of patients had HB grades I–II. That group included patients with total and subtotal resections [12]. In our series, the rate of very good results was 59% for tumors >2.5 cm and 68% within the group of the last 50 operations. Moreover, in that group we performed, as a rule, gross total tumor resections. In the above-mentioned meta-analysis, only 47% of the patients

following GTR had very good CNVII function. To paraphrase Samii et al., there is still a long journey to successful management of this demanding disease [13]. The gradual improvement in the presented outcomes, over a period of more than 20 years, was not only a result of the multi-faceted progress in medicine, but was also related to the increasing experience of surgeons and multi-disciplinary teams. It should be noted that despite many changes in surgical techniques and perioperative care, the studied population is homogenous in three respects. Firstly, 90% of the procedures were performed by the same neurosurgeon (AM). Secondly, a strategy toward complete and durable cure of the disease was consequently implemented (NTR only 1.4%; STR–0%). Currently, this strategy is rather rare, because the proportion of sub- and near-total resections reported in recent studies has been increasing [6,14]. This makes it difficult to relate our results on the risk of CNVII damage to other studies. Thirdly, over the last two decades, the mean size of the tumor in our series has not decreased significantly; it is still approximately 3 cm. Therefore, our results can be applied for CNVII function prognostication following surgery of large vestibular schwannomas.

“Functional vestibular schwannoma surgery” assumes that functional outcome is a greater priority than completeness of tumor resection [1,2]. Worth noting is a technique of “near-total” tumor resection. This must be distinguished from partial or subtotal tumor resections. Near-total resection means that less than 2% of the tumor mass remains. In practice, it comes down to less aggressive separation of the tumor capsule from the CNVII at the site of closest adhesion, i.e., in the porus acusticus area or along the thinnest part of the CNVII [6]. This strategy decreases the risk of CNVII transection and its dysfunction and is not necessarily associated with less radical surgery. According to the study of Sasaki et al., the tumor capsule does not contain neoplastic cells [15]. This is confirmed by other studies in which tumor recurrence following near-total resection was very low [2,6]. Very good CNVII function was preserved in 57% of the patients following total resection and in 77% following near-total resection. The tumor recurrence rate was 1%, 2% and 40% for GTR, NTR and STR, respectively [2]. Based on histopathology researches and clinical reports, it seems that there is a significant difference in safety between GTR and NTR as well as a difference in oncological efficacy between NTR and STR. For that reason, NTR can be used in justified cases because it does not compromise the main goal of treatment.

Treatment failure analysis yields a number of conclusions. Firstly, patients with preserved CNVII continuity, but with severe paresis at discharge, require regular follow-up visits. A good doctor–patient relationship is the basis for achieving better treatment outcomes. Samii underlines that inadequate follow-up care and lack of experience in the treatment of the paralyzed face are frequent causes of persistent CNVII paresis [3]. Secondly, unsuccessful anastomosis in CPA is not a contraindication to subsequent extratemporal anastomosis. Thirdly, there is a need for a broader multidisciplinary collaboration with plastic surgeons in order to offer patients wider access to reconstructive procedures. Fourthly, the expectations of patients with respect to the reanimation of the face vary. It seems that some patients are not self-motivated enough to undertake long-term rehabilitation or

further reconstructive procedures. In our series, patients who agreed to have facial reanimation surgery were predominantly women in their 4th decade of life, whereas among patients who did not consent to undergo this procedure, male subjects comprised 57% and the mean age was 55 years old. This might mean that middle-aged and older males tend to accept the CNVII weakness rather than pursue further invasive treatment.

On the other hand, even small but noticeable facial asymmetry is usually a major problem for patients with low self-esteem, women, and young patients [16]. For that reason, each patient should be offered an individual comprehensive treatment plan. However, it is important to explain to the patient what can realistically be achieved with respect to facial reanimation. Moreover, patients should be encouraged to actively participate throughout the entire treatment process.

4.3. Hearing preservation

Currently, in the age of functional VS surgery, an attempt of hearing preservation is mandatory [17,18]. On the one hand, this can be achieved owing to an increasing proportion of patients with small tumors and serviceable hearing before surgery. On the other hand, in the Samii series of 1000 patients with VS, among patients with some preoperative hearing, some postoperative hearing was preserved in 40%, including only 2.4% with tumors >3 cm and good postoperative hearing [18]. In the next 200 patients, the percentage of serviceable hearing rose to 27–29% in T4 tumors, but the definition of useful hearing was more liberal (to 60 dB in PTA and to 40% SDS) [5]. Moreover, preservation of hearing was the main goal in certain cases in which Samii performed subtotal resections [19]. Fukushima and his team tried to preserve hearing in only 1 out of 4 patients with tumors >2 cm. This was achieved in 54% of the patients but at the expense of less radical resection in 24%. Here, preservation of hearing was defined in the following way: score of ≤80 dB in pure tone audiometry and ≥40 dB in verbal audiometry [20]. According to a review published by Khrais and Sanny in 2006, class A–B hearing (AAO-HNS) was preserved in 25% with a tumor diameter of 10–19 mm and only in 13% with tumors >20 mm [21]. In a prospective study from 2009 [22], useful hearing was not preserved in any of the 13 patients with tumors up to 25 mm. These reports show that the preservation of hearing is a real challenge for even the most experienced neurosurgeons. In our series, a certain range of hearing was preserved in 49% of the patients in whom such an attempt was made but not even a single patient maintained useful hearing.

Preservation of useful hearing is more likely (37–77%), when the middle fossa approach is used [17,23]. In comparison, useful hearing is preserved in 51% of the patients following stereotactic radiosurgery (SRS), 3–4 years after radiation [24]. On a more extended follow-up after radiosurgery, hearing diminishes gradually, possibly due to a decreasing rate of tumor size control and radiosurgery-induced damage of the cochlea and the cochlear nerve. Recently, it has been shown that useful hearing is preserved in only 23% of patients 10 years following SRS [25].

To conclude, neurosurgeons operating large VS are currently placed in a difficult position. They are confronted with

ever-increasing expectations from patients as well as better hearing preservation outcomes in small tumors. Obviously, in each case when useful hearing is present before surgery, all efforts should be made to preserve it during surgery. However, surgery outcomes in large VS are still frustrating. Therefore, according to the present state of knowledge, two approaches are possible. Radical resection at the expense of hearing loss seems reasonable when the cochlear nerve responses in ABR are lost. If hearing preservation is the main expectation of the patient then non-radical resection, completed before the deterioration of ABR wave V, is justified [6]. For further hearing preservation rate improvement, modern forms of intraoperative monitoring like transtympanic electrocochleography or cochlear nerve compound action potentials are crucial [26,27]. However, an attempt to preserve the structural continuity of the cochlear nerve, even with no detectable responses is indicated for several reasons: 1. this nerve constitutes an additional safety layer for the facial nerve, 2. we are not aware of future hearing prosthesis capabilities, 3. there is experimental evidence of the possibility of cochlear nerve regeneration following intrathecal immunotherapy [3,13,19,28].

5. Conclusions

The risk of facial nerve continuity loss during surgery was 11%, however, this decreased to 6% in the second half of the series. Facial nerve function deteriorated, at least temporarily, in 88% of the patients shortly after surgery. However, it improved in 87% at 6 months follow-up if CNVII was anatomically preserved. Delayed CNVII paresis was found in 5% of the patients and had a good prognosis in 88%. Final satisfactory CNVII function was achieved in 76% when excluding the anastomosis results and in 87% when including the anastomosis results. In recent years, the percentage of satisfactory outcomes has risen to 94%. However, in two thirds of the patients discharged with severe facial paresis (HB grades V–VI), satisfactory nerve regeneration did not occur despite the fact that its continuity was maintained. Therefore, a close surveillance of CNVII function evolution following surgery is mandatory as there are many possibilities of facial reanimation in different time frames after surgery. A certain range of hearing can be preserved in half of the patients in whom such an attempt is made. However, the preservation of useful hearing is still problematic especially in patients with large tumors. Considering the size of the tumors and the extent of the resections, our current results are comparable to those obtained at specialized centers worldwide.

Conflict of interest

None declared.

Ethics

The work described in this article has been carried out in accordance with The Code of Ethics of the World Medical Association (Declaration of Helsinki) for experiments

involving humans; Uniform Requirements for manuscripts submitted to Biomedical journals.

REFERENCES

- [1] Gurgel RK, Theodosopoulos PV, Jackler RK. Subtotal/near-total treatment of vestibular schwannomas. *Curr Opin Otolaryngol Head Neck Surg* 2012;20:380–4.
- [2] Martin TP, Fox H, Ho EC, Holder R, Walsh R, Irving RM. Facial nerve outcomes in functional vestibular schwannoma surgery: less than total tumour excision significantly improves results. *J Laryngol Otol* 2012;126:120–4.
- [3] Samii M, Matthies C. Management of 1000 vestibular schwannomas (acoustic neuromas): the facial nerve-preservation and restitution of function. *Neurosurgery* 1997;40:684–94.
- [4] Grant GA, Rostomily RR, Kim DK, Mayberg MR, Farrell D, Avellino A, et al. Delayed facial palsy after resection of vestibular schwannoma. *J Neurosurg* 2002;97:93–6.
- [5] Samii M, Gerganov V, Samii A. Improved preservation of hearing and facial nerve function in vestibular schwannoma surgery via the retrosigmoid approach in a series of 200 patients. *J Neurosurg* 2006;105:527–35.
- [6] Nonaka Y, Fukushima T, Watanabe K, Friedman AH, Sampson JH, Mcelveen Jr JT, et al. Contemporary surgical management of vestibular schwannomas: analysis of complications and lessons learned over the past decade. *Neurosurgery* 2013;72(Suppl. 2). ons103–15.
- [7] Yu LM, Yang SM, Han DY, Huang DL, Yang WY. Management of operative complications in acoustic neuroma surgery. *Zhonghua Er Bi Yan Hou Tou Jing Wai Ke Za Zhi* 2006;41:26–30.
- [8] Sampath P, Holliday MJ, Brem H, Niparko JK, Long DM. Facial nerve injury in acoustic neuroma (vestibular schwannoma) surgery: etiology and prevention. *J Neurosurg* 1997;87:60–6.
- [9] Prell J, Rampp S, Romstöck J, Fahlbusch R, Strauss C. Train time as a quantitative electromyographic parameter for facial nerve function in patients undergoing surgery for vestibular schwannoma. *J Neurosurg* 2007;106:826–32.
- [10] Kunert P, Smolarek B, Marchel A. Facial nerve damage following surgery for cerebellopontine angle tumours. Prevention and comprehensive treatment. *Neurochir Pol* 2011;45:480–8.
- [11] Sughrue ME, Yang I, Rutkowski MJ, Aranda D, Parsa AT. Preservation of facial nerve function after resection of vestibular schwannoma. *Br J Neurosurg* 2010;24:666–71.
- [12] Gurgel RK, Dogru S, Amdur RL, Monfared A. Facial nerve outcomes after surgery for large vestibular schwannomas: do surgical approach and extent of resection matter? *Neurosurg Focus* 2012;33:E16.
- [13] Koerbel A, Gharabaghi A, Safavi-Abbasi S, Tatagiba M, Samii M. Evolution of vestibular schwannoma surgery: the long journey to current success. *Neurosurg Focus* 2005;18:E10.
- [14] Haque R, Wojtasiewicz TJ, Gigante PR, Attiah MA, Huang B, Isaacson SR, et al. Efficacy of facial nerve-sparing approach in patients with vestibular schwannomas. *J Neurosurg* 2011;115:917–23.
- [15] Sasaki T, Shono T, Hashiguchi K, Yoshida F, Suzuki SO. Histological considerations of the cleavage plane for preservation of facial and cochlear nerve functions in vestibular schwannoma surgery. *J Neurosurg* 2009;110:648–55.
- [16] Cross T, Sheard CE, Garrud P, Nikolopoulos TP, O'Donoghue GM. Impact of facial paralysis on patients with acoustic neuroma. *Laryngoscope* 2000;110:1539–42.

- [17] Arriaga MA, Chen DA, Fukushima T. Individualizing hearing preservation in acoustic neuroma surgery. *Laryngoscope* 1997;107:1043-7.
- [18] Samii M, Matthies C. Management of 1000 vestibular schwannomas (acoustic neuromas): hearing function in 1000 tumor resections. *Neurosurgery* 1997;40:248-60.
- [19] Samii M, Matthies C. Management of 1000 vestibular schwannomas (acoustic neuromas): surgical management and results with an emphasis on complications and how to avoid them. *Neurosurgery* 1997;40:11-23.
- [20] Wanibuchi M, Fukushima T, McElveen Jr JT, Friedman AH. Hearing preservation in surgery for large vestibular schwannomas. *J Neurosurg* 2009;111:845-54.
- [21] Khrais T, Sanna M. Hearing preservation surgery in vestibular schwannoma. *J Laryngol Otol* 2006;120:366-70.
- [22] Myrseth E, Møller P, Pedersen PH, Lund-Johansen M. Vestibular schwannoma: surgery or gamma knife radiosurgery? A prospective, nonrandomized study. *Neurosurgery* 2009;64:654-61.
- [23] DeMonte F, Gidley PW. Hearing preservation surgery for vestibular schwannoma: experience with the middle fossa approach. *Neurosurg Focus* 2012;33:E10.
- [24] Yang I, Sughrue ME, Han SJ, Aranda D, Pitts LH, Cheung SW, et al. A comprehensive analysis of hearing preservation after radiosurgery for vestibular schwannoma. *J Neurosurg* 2010;112:851-9.
- [25] Carlson ML, Jacob JT, Pollock BE, Neff BA, Tombers NM, Driscoll CL, et al. Long-term hearing outcomes following stereotactic radiosurgery for vestibular schwannoma: patterns of hearing loss and variables influencing audiometric decline. *J Neurosurg* 2013;118:579-87.
- [26] Morawski KF, Niemczyk K, Bohorquez J, Marchel A, Delgado RE, Ozdamar O, et al. Intraoperative monitoring of hearing during cerebellopontine angle tumor surgery using transtympanic electrocochleography. *Otol Neurotol* 2007;28:541-5.
- [27] Yamakami I, Ito S, Higuchi Y. Retrosigmoid removal of small acoustic neuroma: curative tumor removal with preservation of function. *J Neurosurg* 2014;121:554-63.
- [28] Tatagiba M, Rosahl S, Gharabaghi A, Blömer U, Brandis A, Skerra A, et al. Regeneration of auditory nerve following complete sectioning and intrathecal application of the IN-1 antibody. *Acta Neurochir* 2002;144:181-7.