

Hemiparkinsonism-hemiatrophy syndrome – report on two cases and review of the literature

Zespół hemiparkinsonizm-hemiatrofia – opis dwóch przypadków i przegląd piśmiennictwa

Artur Dziadkiewicz^{1,2}, Monika Białecka³, Piotr Janik⁴, Jarosław Stawek^{1,2}

¹Zakład Pielęgniarstwa Neurologiczno-Psychiatrycznego, Gdański Uniwersytet Medyczny

²Oddział Neurologii, Szpital Specjalistyczny św. Wojciecha w Gdańsku

³Katedra Farmakologii, Pomorski Uniwersytet Medyczny w Szczecinie

⁴Katedra i Klinika Neurologii, Warszawski Uniwersytet Medyczny

Neurologia i Neurochirurgia Polska 2013; 47, 4: 387-392

DOI: 10.5114/ninp.2013.34557

Abstract

Hemiparkinsonism-hemiatrophy (HPHA) is a rare neurological syndrome. The main clinical features of HPHA consist of atrophy of one side of the body (face, trunk, limbs), ipsilateral hemiparkinsonism (bradykinesia, rigidity, tremor) and in many cases dystonia. There are no data on prevalence of HPHA as the condition is rare. The mean age of parkinsonism onset is earlier than in idiopathic Parkinson disease (43.7 years, range: 15-63). Changes in magnetic resonance imaging (MRI) (cortical, basal ganglia atrophy contralaterally to the side of clinical presentation) are described in 30% of patients. The pathogenesis of HPHA is unknown, but in many cases a history of prenatal injuries was reported.

We present two male patients with HPHA – 45 and 55 years old, with left-sided parkinsonism, dystonia and hemiatrophy (to our knowledge, the first Polish cases). Both patients had no atrophic changes in MRI and levodopa treatment was ineffective. In the discussion the authors review current literature on HPHA.

Key words: hemiparkinsonism, hemiatrophy, parkinsonism, dystonia, head injury.

Streszczenie

Zespół hemiparkinsonizm-hemiatrofia (*hemiparkinsonism-hemiatrophy* – HPHA) jest rzadkim schorzeniem neurologicznym. Głównymi objawami są zanik połowy ciała (w zakresie twarzy, tułowia, kończyn) oraz tożstronny zespół parkinsonowski (bradykinezja, sztywność, drżenie), któremu u wielu chorych towarzyszy także dystonia. Z powodu rzadkiego występowania tego schorzenia nie ma danych epidemiologicznych. Średnia wieku pojawienia się objawów parkinsonowskich jest niższa niż dla idiopatycznej choroby Parkinsona i wynosi 43,7 roku (zakres: od 15 do 63 lat). Zmiany w badaniu obrazowym mózgu (połowiczy przeciwstronny zanik korowy i podkorowy) opisywane są w 30% przypadków. Patogeneza choroby jest nieznana, ale w wielu przypadkach opisywano zaburzenia w okresie prenatalnym.

W pracy prezentujemy dwóch pacjentów z HPHA – mężczyzn w wieku 45 i 55 lat z objawami lewostronnego parkinsonizmu, dystonii i połowiczego zaniku ciała. U żadnego z pacjentów nie stwierdzono zmian w badaniu za pomocą rezonansu magnetycznego. Odpowiedź na lewodopę była ograniczona. Według naszej wiedzy jest to pierwsza polska publikacja prezentująca HPHA. W dyskusji dokonano także przeglądu piśmiennictwa na ten temat.

Słowa kluczowe: połowiczy parkinsonizm, połowiczy zanik, parkinsonizm, dystonia, uraz głowy.

Correspondence address: Artur Dziadkiewicz, Zakład Pielęgniarstwa Neurologiczno-Psychiatrycznego, Gdański Uniwersytet Medyczny, ul. Do Studzienki 38, 80-227 Gdańsk, Polska, e-mail: artur.dziadkiewicz@gumed.edu.pl

Received: 8.08.2012; accepted: 2.11.2012

Introduction

Hemiparkinsonism-hemiatrophy (HPHA), first described by Klawans in 1981 [1], is a rare neurological syndrome. The main clinical features of HPHA consist of atrophy of one body side (in a majority of cases observed since early childhood) and ipsilateral hemiparkinsonism, which usually appears later [2,3]. The hemiatrophy of one or more parts of the body (face, upper and lower limb, trunk) is observed with similar predilection for the left or right side. Magnetic resonance imaging (MRI) may show contralateral or ipsilateral atrophy of the cortex and the basal ganglia in inconsistent forms (i.e. focal or dif-

fuse atrophy). However, MRI changes are described in only 30% of HPHA patients [2,3].

The progression of parkinsonian symptoms (such as bradykinesia, rigidity and tremor) is relatively slow. Accompanying dystonic movements are observed in 70% of cases and were reported as the first HPHA symptom in 50% of patients [2]. In some HPHA studies, the presence of pyramidal signs (brisk tendon reflexes and Babinski sign) has been consistently noted [2,4].

The mean age of parkinsonism onset is 43.7 years, but it ranges from 15 to 63 years [2]. There are no data on prevalence of HPHA as the condition is rare and the largest observed group from the referral movement disorders centre consisted of 30 patients [2].

Levodopa response is variable – in 60% of cases it is noted as good; in 20% moderate; and in 20% low or no response was observed [2,4].

The pathogenesis of HPHA is unknown. However, in many cases a history of prenatal injuries was reported [1-3]. Recently, *parkin* mutations were found in one case [5].

The literature on HPHA is scarce and to our knowledge this unusual syndrome has never been reported in Polish patients.

Case reports

Case 1 was a 45-year-old, right-handed male patient without family history of parkinsonism or dystonia. The patient denied having any prenatal or birth-related problems or severe infections in early childhood. Age at the onset of parkinsonism was 34 and the first noticed symptom was left upper limb rest tremor. One year later the symptoms of bradykinesia within left extremities were observed. Subsequently, 3 years later, after one month of levodopa administration (which was not effective), he developed cervical dystonia (spasmodic torticollis to the left side) with subsequent progression. Levodopa was discontinued and botulinum toxin type A treatment was started with a good response.

The clinical presentation (at the fifth year after onset) was characterized by asymmetric, left-sided parkinsonism, multifocal dystonia (torticollis with head rotated to the left, jaw-opening dystonia and dystonia of the left foot) and left-sided hyperreflexia. Features of ipsilateral hemiatrophy included shortening of the left lower limb (length of the right lower limb was 84 cm, and length of the left lower limb was 81 cm); difference in thigh circumferences (right: 40 cm, left: 38 cm); left hand smaller than right hand (Fig. 1); and feet asymmetry (Fig. 2).

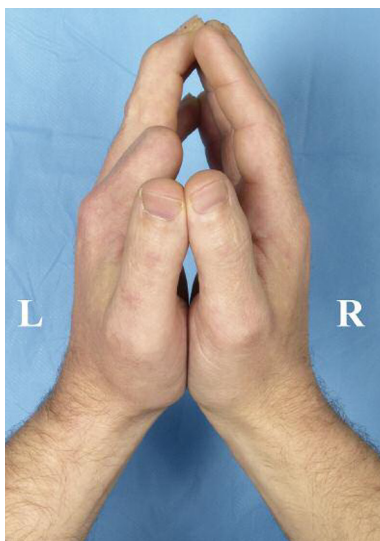


Fig. 1. Case 1. Left hand atrophy

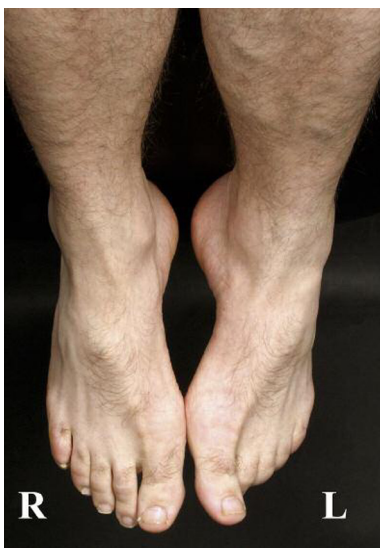

Fig. 2. Case 1. Left foot atrophy

MRI scans showed decreased signal within the globus pallidus bilaterally on T1- and T2-weighted images (Fig. 3) and regional cerebral blood flow (rCBF) assessed with single photon emission computed tomography (SPECT) using ^{99m}Tc -HMPAO showed normal brain perfusion. Mini-Mental State Examination (MMSE) showed no cognitive impairment (30 points). Progression of the disorder was observed at 5.5 years follow-up: Unified Parkinson's Disease Rating Scale (UPDRS) total score (I-IV) increased from 42 to 70, Hoehn-Yahr score from 2.5 to 3.0 and Schwab-England score decreased from 80% to 70%. Pharmacological treatment (levodopa, priribedil, ropinirole) was ineffective. Moderate improvement was observed only with biperiden.

Case 2 was a 55-year-old, right-handed male patient, without family history and without any prenatal or birth-related injuries or severe infections in early childhood. He reported a history of sensorineural hearing loss since childhood. The onset of parkinsonism was reported at the age of 49 and during the following two years rigidity of the left upper and lower limb (preceded by left shoulder pain) developed and after 5 years asymmetric bradykinesia of left extremities and gait disturbances (shuffling gait) occurred. At the time of the last examination (at the sixth year from onset), he presented hypomimia, asymmetric left-sided parkinsonism with rigidity, left-sided hyperreflexia and dystonic posturing of the left hand. Moreover, the following features of left-sided hemiatrophy were observed: mild hemifacial asymmetry and weakness; difference in thigh circumference (right thigh: 43 cm, left thigh: 40 cm); dorsal muscles atrophy (Fig. 4); left hand smaller than right one (Fig. 5); and feet asymmetry (Fig. 6).

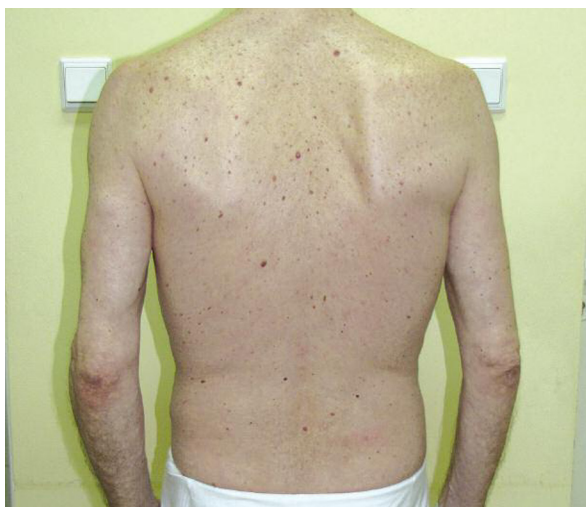

Fig. 4. Case 2. Dorsal muscles asymmetry – left side atrophy

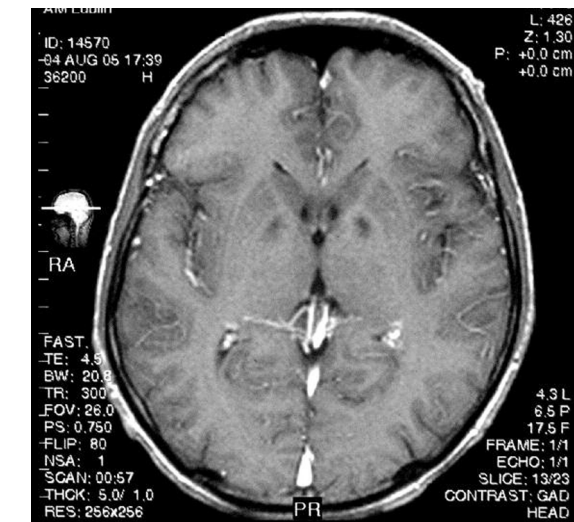


Fig. 3. Case 1. MRI scan shows hypointensities within the globus pallidus on both T1- and T2-weighted images

MRI scans showed mild cortical atrophy of frontal lobes, and bilateral small white matter hyperintensities (Fig. 7). In rCBF SPECT with ^{99m}Tc -HMPAO, global hypoperfusion was found without significant asymmetry. Complex neuropsychological assessment showed low mood (Beck Depression Inventory score was 18), language, executive function, visual memory and dynamic praxis impairment (assessed with: Boston Naming Test, Halstead-Reitan Category Test, Tower of London 2, CFT Rey, and Luria praxis performance). Verbal memory, short-term memory and operative memory were not impaired. MMSE score was 27.

The levodopa response was poor (UPDRS motor score part III on-medication: 18, off-medication: 19),

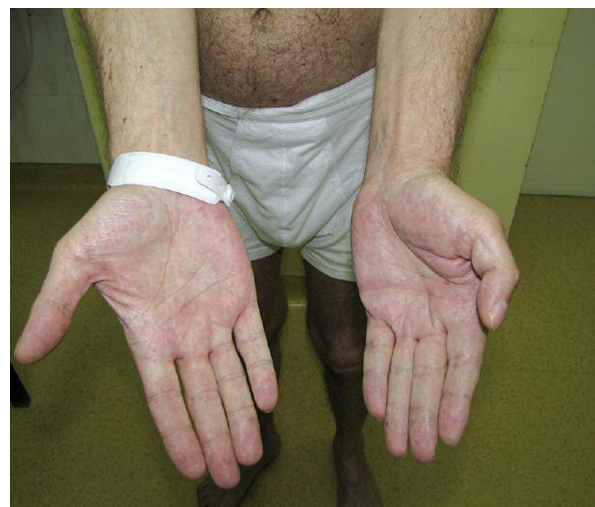

Fig. 5. Case 2. Left hand atrophy

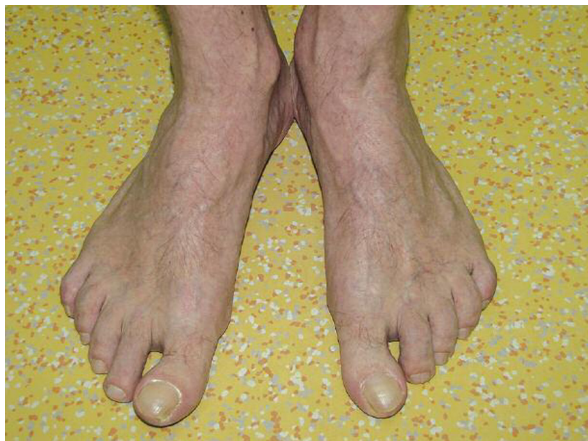

Fig. 6. Case 2. Left foot atrophy

but the patient reported subjective improvement on treatment.

Discussion

Hemiparkinsonism-hemiatrophy is a very rare (or unrecognized) neurological syndrome and to date only 68 cases have been reported in the literature (only single case reports or case series). The widest presentation of HPHA was published in 2007 by Wijemanne and Jankovic, who analysed the clinical spectrum of 30 patients who fulfilled the diagnostic criteria [2]. Buchman *et al.* [6] studied 15 patients with HPHA, presenting slow progression of the disorder and introducing clinical criteria for hemiatrophy and hemiparkinsonism. Giladi *et al.* [7] presented clinical and radiological correlates of 11 HPHA patients with or without brain atrophy. The clinical presentation of case reports and case series reported to date along with two reported Polish patients is presented in Table 1.

Parkinsonian symptoms in HPHA usually develop at an early age. The range of age at onset was from 15 to 63, but mean age of onset was 43.7 [2]. Left and right sides were equally represented [2,4]. The clinical spectrum varies from bradykinesia and rigidity (in some studies observed in all patients [2], in one study only in 19% [4]), to tremor (40% of patients [2] and 56% [4]), dystonia (70% [2] and 22% [4]) and also gait [4] or eye-movement abnormalities [8], falls [2], and freezing [2], especially asymmetric freezing of the affected side of the body [9]. Most HPHA patients developed a wide range of dystonia presentations: focal dystonia (e.g. leg or hand posturing dystonia), multifocal, hemidystonia, action-induced and early morning dysto-

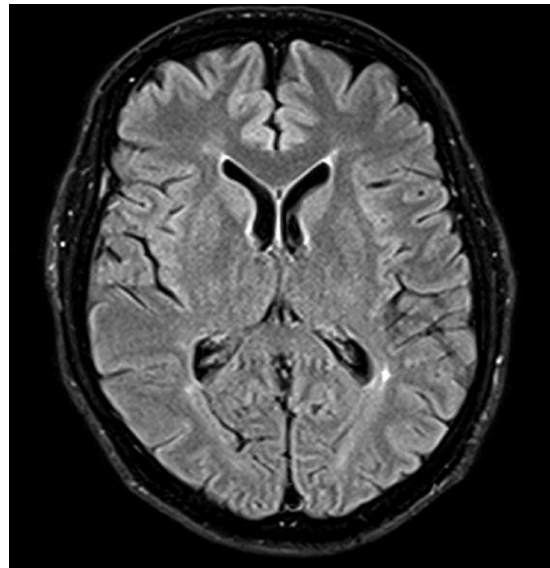


Fig. 7. Case 2. MRI scan shows mild cortical atrophy of frontal lobes, and bilateral small size white matter hyperintensities

nia [2], as was observed in our Case 1 as well. In 50% of HPHA patients [2] dystonia was noticed as the first symptom. Some patients had pyramidal signs: brisk tendon reflexes on the atrophic side or bilateral, but Babinski and Hoffman signs were noted only in a few cases [4]. The pyramidal signs suggests that atrophy and brain tissue injury in HPHA can involve not only extrapyramidal, but also pyramidal tracts [2].

In a majority of cases, atrophy of one body side was observed since early childhood and symptoms of parkinsonism occurred many years later, but there were reported patients with hemiatrophy diagnosed along with parkinsonism at the same time.

Morphological abnormalities in HPHA include not only atrophy, but also skeletal deformities (scoliosis and joint deformities) [2]. Atrophy was observed within the face, hands, legs and trunk. The more frequently involved areas were the upper limbs, followed by lower limbs and face, but one area of the body may be more affected by atrophy than the rest of the body on the same side [2]. The severity of atrophy varied from mild to severe [2,13]. Wijemanne and Jankovic suggest that hemiatrophy is the result of failure in patients' development, and not a later-life occurring phenomenon. Most of their patients manifested atrophy and had problems such as difficulties in correctly fitting shoes in their early life [2].

The MRI findings in patients with HPHA can be grouped into the following categories: focal atrophy or diffuse cerebral hemiatrophy; single or multiple focal

Table 1. The clinical spectrum of reported case series with hemiparkinsonism-hemiatrophy syndrome

	Number of patients	Age of onset (mean, range)	Dystonia (%)	Response to treatment (%)	Abnormal birth history (%)
Klawans, 1981 [1]	4	40.0	0%	0%	100%
Buchman <i>et al.</i> , 1988 [6]	1 5	43.7 (31-61)	67%	78%	50%
Giladi <i>et al.</i> , 1990 [7]	1 1	38.1 (18-54)	27%	70%	0
Przedborski <i>et al.</i> , 1994 [12]	6	49 (23-59)	83%	33%	0
Lang, 1995 [14]	1	27	present	good	present
Martinelli <i>et al.</i> , 1998 [4]	1	55	absent	good	absent
Marchioni <i>et al.</i> , 1999 [8]	1	45	absent	poor	absent
Jenkins <i>et al.</i> , 2002 [15]	1	19	present	not tried	absent
Pramstaller <i>et al.</i> , 2002 [5]	1	29	present	good	absent
Wijemanne & Jankovic, 2007 [2]	3 0	44.2 (15-63)	70%	80%	47%
Tessitore <i>et al.</i> , 2010 [3]	1	50	present	good	absent
Dziadkiewicz <i>et al.</i>	2	34 49	present absent	poor poor	absent absent

lesions in the basal ganglia; single or multiple focal lesions outside the basal ganglia; and normal scans [2]. Abnormalities were found in 30% of HPHA patients, but in most cases MRI scans were normal [2,4,10]. No correlations between clinical presentation, history of prenatal or birth-related head injury and MRI brain atrophy were found [2,10]. In MRI diffusion tensor imaging (DTI), low values of fractional anisotropy (FA) were found in both putaminal regions, which may suggest a possible lack of integrity within the myelin fibres. The evidence of lower values of FA also in the subthalamic nucleus suggests the involvement of these parts of the brain, where glutamatergic transmission is present. The evidence of normal FA and mean diffusivity (MD) values in all the nigral regions seems to rule out a major role of dopaminergic neurons in the pathogenesis of HPHA [11].

Positron emission tomography (PET) with [18F]-fluorodeoxyglucose (FDG) showed decreased glucose metabolism in caudate and lentiform nuclei or the frontal cortex, contralateral to the side of the body affected. [18F]-fluorodopa (FDP) PET scans have shown reduced uptake in the contralateral striatum in some HPHA patients; however, bilateral reduction in FDP uptake and no reduced uptake were also reported. [3]

The pathogenesis of HPHA is still unknown, but the wide range of clinical features, neuroimaging and

functional tests suggests that the aetiology may be heterogeneous. Klawans, who first described the HPHA syndrome in 1981, presented four male patients with evidence of hemiatrophy (due to early-life hemispheric injury) who developed hemiparkinsonism [1]. Wijemanne and Jankovic [2] reported that 47% of described patients suffered from prenatal, birth-related or neonatal injuries, febrile infection or major injury in childhood. There was no defined pathomechanism of injury or localization responsible for HPHA symptoms. In one study *parkin* mutations in one examined patient were found – the clinical spectrum was similar to other HPHA studies. The complementary metabolic and receptor pattern of PET ligands corresponded to that typically found in idiopathic Parkinson disease (PD), although tracer binding asymmetry was lacking [5]. As hemiatrophy is an early and non-progressive symptom, parkinsonism progresses over time, although it is not rapid as in idiopathic Parkinson disease. The cause of this progression remains unknown. One may speculate that it is age-related neuronal loss combined with an initially injured (e.g. perinatally) dopaminergic system, but the lesions are probably more widespread as a significant proportion of patients do not respond to levodopa and present with different forms of dystonia and pyramidal symptoms. To our knowledge there are no published postmortem data on HPHA.

The levodopa response in HPHA patients is variable. A poor levodopa response was reported by Klawans [1], but in the majority of cases, good or moderate results were observed [13], which is not in concordance with the findings of Pisani *et al.* suggesting that dopaminergic neurons are not involved in HPHA pathogenesis [2, 11]. Levodopa-induced fluctuations and dyskinesias were rarely reported, which may suggest that presynaptic nigro-striatal degeneration is not present or very mildly progressing in HPHA [2,4]. There are no studies or data on the correlation between DaTSCAN or MRI imaging and levodopa response in HPHA patients. Ablative surgery and deep brain stimulation were reported in some cases, but the results were inconclusive, probably due to heterogeneous underlying pathology [2].

Both presented patients fulfil the main HPHA criteria: asymmetric parkinsonism of early onset (before 50) and ipsilateral atrophy of one side of the body. Parkinsonian symptoms observed in our cases consisted of hypomimia, bradykinesia and rigidity with rest tremor in Case 1 and with no tremor in Case 2. In both cases dystonia was reported: in Case 1, severe and multifocal dystonia; in Case 2, the left hand presented dystonic posturing only (elbow flexion), resembling that typical for idiopathic Parkinson disease. Both had brisk tendon reflexes ipsilaterally to parkinsonian symptoms. Hemiatrophy was recognized within the face, and upper and lower limbs. On MRI scans, no evidence of cortical or basal ganglia asymmetric atrophy was found, but in Case 1 decreased signal of the globus pallidus was noticed. Regional cerebral blood flow SPECT was normal in Case no. 1 and global hypoperfusion (referred to cerebellar perfusion) was reported in Case 2, but this patient was also older. In both presented cases dopaminergic treatment was ineffective. Parkinsonian syndromes with asymmetrical presentation should be taken into account at differential diagnosis, especially idiopathic Parkinson disease, corticobasal syndrome (CBS) and multiple system atrophy (MSA), but in all of them the rate of progression is much faster and the clinical spectrum involves cerebellar and autonomic dysfunction (MSA), apraxia and the alien limb phenomenon along with myoclonus (CBS), and good responsiveness to levodopa and lack of dystonia at early stages (Parkinson disease). Patients with these types of parkinsonism are also older than patients with HPHA.

In conclusion, HPHA should be suspected in cases of early onset, slowly progressive, asymmetric parkinsonism combined with ipsilateral hemiatrophy (or contralateral cerebral hemiatrophy on MRI) and focal dys-

tonia. The supportive features include poor response to levodopa, positive history of perinatal injury and lack of dementia. HPHA seems to be a clinical presentation without definite pathology and possibly heterogeneous pathogenesis.

Disclosure

Authors report no conflict of interest.

References

1. Klawans H.L. Hemiparkinsonism as a late complication of hemiatrophy: a new syndrome. *Neurology* 1981; 31: 625-628.
2. Wijemanne S., Jankovic J. Hemiparkinsonism-hemiatrophy syndrome. *Neurology* 2007; 69: 1585-1594.
3. Tessitore A., Russo A., Cirillo M., et al. Hemiparkinsonism and hemiatrophy syndrome: A rare observation. *Clin Neurol Neurosurg* 2010; 112: 524-526.
4. Martinelli P., Scaglione C., Capocasa M., et al. Hemiparkinsonism-hemiatrophy: A new observation. *J Neurol* 1998; 245: 180-182.
5. Pramstaller P.P., Kunig G., Leenders K., et al. Parkin mutations in a patient with hemiparkinsonism-hemiatrophy: a clinical-genetic and PET study. *Neurology* 2002; 58: 808-810.
6. Buchman A.S., Goetz C.G., Klawans H.L. Hemiparkinsonism with hemiatrophy. *Neurology* 1988; 38: 527-530.
7. Giladi N., Burke R.E., Kostic V., et al. Hemiparkinsonism-hemiatrophy syndrome: clinical and neuroradiologic features. *Neurology* 1990; 40: 1731-1734.
8. Marchioni E. Hemiparkinsonism-hemiatrophy with brain hemihypoplasia. *Mov Disord* 1999; 14: 359-364.
9. Lee P.H. Asymmetric freezing of gait in hemiparkinsonism-hemiatrophy. *Neurology* 2004; 63: E7.
10. Costa B., Zanette G., Bertolasi L., et al. Hemiparkinsonism-hemiatrophy syndrome: neuroradiological and neurophysiological findings. *Eur Neurol* 1994; 34: 107-109.
11. Pisani V., Nicoletti A., Meschini A., et al. Putaminal, but not nigral alterations, characterize hemiparkinsonism-hemiatrophy syndrome: a case report. *Mov Disord* 2011; 26: 352-353.
12. Przedborski S., Giladi N., Takikawa S., et al. Metabolic topography of the hemiparkinsonism-hemiatrophy syndrome. *Neurology* 1994; 44: 1622-1628.
13. Jankovic J. Hemiparkinsonism and hemiatrophy. *Neurology* 1988; 38: 1815-1816.
14. Lang A.E. Hemiatrophy, juvenile-onset exertional alternating leg paresis, hypotonia, and hemidystonia and adult-onset hemiparkinsonism: the spectrum of hemiparkinsonism-hemiatrophy syndrome. *Mov Disord* 1995; 10: 489-495.
15. Jenkins M., Mendonca D., Parrent A., et al. Hemiparkinsonism-somatic hemiatrophy syndrome. *Can J Neurol Sci* 2002; 29: 184-187.