

Assessment of long-term results of intracranial aneurysm clipping by means of computed tomography angiography

Ocena skuteczności klipsowania tętniaków wewnątrzczaszkowych w terminie odległym za pomocą angiografii tomografii komputerowej

Przemysław Kunert¹, Marek Prokopienko¹, Magdalena Gola², Tomasz Dziedzic¹, Maciej Jaworski², Andrzej Marchel¹

¹Department of Neurosurgery, Medical University of Warsaw, Poland

²Second Department of Clinical Radiology, Medical University of Warsaw, Poland

Neurologia i Neurochirurgia Polska 2013; 47, 1: 18-26

DOI: 10.5114/ninp.2012.31549

Abstract

Background and purpose: The aim of this retrospective study was to assess the effectiveness of aneurysm clipping by computed tomography angiography (CTA) in a long-term follow-up.

Material and methods: The CTA examination was performed in 119 patients who had 143 aneurysms clipped. The examinations were performed 3 to 11 years (mean 6 years) after clipping using a GE Lightspeed PRO16 scanner.

Results: In all cases but one, good quality CTA images, suitable for evaluation of the arteries around the clip site, were obtained. Complete aneurysm closure without neck remnant or regrowth was confirmed in 137 (96%) aneurysms. In 4 (3%) cases, neck remnants were detected (2 on the anterior communicating artery [ACoM] and 2 on the middle cerebral artery [MCA]). A total clip slippage from the aneurysm dome was revealed in 1 case. One case of aneurysm re-rupture was noted, 11 years after clipping. The rebleeding was caused by ACoM aneurysm regrowth. Among these 6 patients with unsatisfactory clipping, 2 required further treatment and 4 remain under observation. Nineteen 'de novo' aneurysms in other locations were found in 14 (12%) patients. Summing up all of the pathological findings in the study group, there were 18 (15%) patients who needed further management including close surveillance or re-treatment.

Conclusions: Computed tomography angiography is a simple and reliable method of aneurysm clipping evaluation. The long-

Streszczenie

Wstęp i cel pracy: Celem niniejszej retrospektywnej pracy była ocena skuteczności klipsowania tętniaków wewnątrzczaszkowych w odległym terminie po operacji za pomocą angiografii tomografii komputerowej (angio-TK).

Materiał i metody: Angio-TK wykonano u 119 pacjentów ze 143 zaklipsowanymi tętniakami. Badania przeprowadzono w ciągu 3–11 lat od operacji (średnio 6 lat) aparatem CT GE Lightspeed PRO16.

Wyniki: U wszystkich pacjentów, poza jednym, uzyskano obrazy pozwalające na wiarygodną ocenę naczyń w pobliżu założonego klipsa. Spośród 143 zaklipsowanych tętniaków, w 137 (96%) przypadkach stwierdzono prawidłowe zamknięcie, bez cech odtwarzania się ani pozostałości tętniaka. Pozostałość szyi klipsowanego tętniaka (2 na tętnicy łączącej przedniej i 2 na tętnicy mózgu środkowej) stwierdzono w 4 przypadkach. W jednym przypadku uwidoczniło się całkowite zsuniecie się klipsa z tętniaka tętnicy łączącej przedniej. W okresie objętym analizą zanotowano jeden przypadek nawrotowego krwotoku podpajęczynówkowego po 11 latach od operacji. Powodem był odrost tętniaka tętnicy łączącej przedniej. Spośród 6 chorych z niezadowolającym zaklipsowaniem, 2 wymagało dalszego leczenia, a 4 – obserwacji. U 14 (12%) pacjentów wykryto 19 tętniaków *de novo* w innych lokalizacjach, z których 18 nie wymagało leczenia. Biorąc pod uwagę wszystkie nieprawidłowości naczyniowe w badanej grupie, 18 (15%) pacjentów wymagało dalszej obserwacji lub leczenia.

Correspondence address: Przemysław Kunert, Katedra i Klinika Neurochirurgii, Warszawski Uniwersytet Medyczny, ul. Banacha 1A, 02-097 Warszawa, fax +48 22 658 36 53, e-mail: pkunert@wp.pl

term follow-up CTA confirmed the permanent and complete obliteration of 96% of the aneurysms. The rate of unsatisfactory aneurysm closure was 4%, but only 1.4% needed re-treatment during a mean follow-up of 6 years. The annual risk of aneurysm re-rupture was 0.1%.

Key words: intracranial aneurysm, aneurysm clipping, computed tomography angiography.

Wnioski: W ocenie autorów angio-TK jest wygodnym i wiarygodnym sposobem kontroli po operacjach zaklipsowania tętniaka. Odległe badania angio-TK wykazały, że klipsowanie całkowicie i trwale wyłącza z krążenia 96% tętniaków. Odsetek niezadowolającego zaklipsowania wyniósł 4%, ale tylko 1,4% pacjentów wymagało dalszego leczenia w okresie obserwacji wynoszącym średnio 6 lat. Ryzyko ponownego krwotoku z zaklipsowanego tętniaka wyniosło 0,1% na rok.

Słowa kluczowe: tętniak wewnątrzczaszkowy, klipsowanie, angiografia TK.

Introduction

The gold standard for the detection of cerebral aneurysms and also for checking the accuracy of aneurysm clipping is digital subtraction angiography (DSA) [1]. However, due to its invasiveness, DSA has not been widely used as a follow-up examination to assess the long-term effectiveness of aneurysm clipping [2]. The introduction of computed tomography angiography (CTA) for detecting intracranial aneurysms has made it possible to limit the invasiveness of the diagnostics, compared to DSA. High sensitivity and specificity of CTA have recently been proven for detecting very small aneurysms [3,4] and as a useful diagnostic modality to check aneurysm occlusion after clipping [5,6]. Due to simplicity and availability, CTA is now widely used in the diagnosis of patients after subarachnoid haemorrhage (SAH), and the use of this method is encouraged to control the completeness of aneurysm clipping. A similar trend toward less invasive methods can be seen in interventional radiology, where the long-term results of coiling can be effectively evaluated with magnetic resonance angiography (MRA) instead of DSA [7].

Knowledge of remote results of aneurysm clipping is mandatory, due to the development of endovascular modalities. Several years ago, the neurosurgical community demanded from interventional radiologists a long-term evaluation of coiling effectiveness. Currently, this is well documented [7] and it should be balanced by an objective assessment of clipping durability. Thus, we initiated long-term follow-up examinations in patients after aneurysmal subarachnoid haemorrhage treated by clipping. The aim of the study was to evaluate the efficacy and durability of clipping by means of a CTA examination performed many years after surgery.

Material and methods

Patients were qualified for this retrospective study if at least three years had passed since the clipping of ruptured intracranial aneurysm. Exclusion criteria were severe general and neurological conditions at the time of discharge from hospital. Invitations for a follow-up CTA examination were sent to 208 patients who underwent surgery between 1998 and 2005. The clips used before 1998, made of a different alloy, caused significant artefacts in CTA scans that hindered adequate evaluation of the arteries around the clip site. In the study group, all but one aneurysm were clipped with Yasargil titanium clips.

One hundred and twenty patients responded to the invitation letter, of whom 2 patients were excluded from the study because of possible allergy to contrast medium. CTA was performed in 119 patients, including 118 invited patients and one patient who was admitted urgently with an aneurysm re-rupture. At the time of surgery, patients ranged in age from 18 to 72 years (mean 49 years). The patients were operated on by five neurosurgeons. The follow-up period ranged from 3 to 11 years (mean 6.4 years). Before treatment 99 (83%) patients had a single aneurysm and 20 (17%) had multiple aneurysms, including 15 with two, 4 with three and 1 with four aneurysms. A total of 119 patients had 145 aneurysms (119 ruptured and 26 unruptured), of which 143 were clipped, 1 was coiled and 1 unruptured aneurysm is being observed due to its small size (Table 1).

All the examinations were performed with a GE Lightspeed PRO16 scanner using the following scanning parameters: helical mode, 120 kV, smart mA (100-300 mA), pitch 0.938:1, slice thickness 0.625 mm. Intravenous contrast medium was administered in all of the cases (Iomeron 400, Bracco-Altana Pharma, 50-60 ml, speed 4 ml/s). Post-processing reconstructions were

Table 1. Patients' characteristics

Gender	
Male	33
Female	86
Age at presentation [years]; mean (range)	49 (18-72)
Follow-up duration [years]; mean (range)	6.4 (3-11)
Age at study entry [years]; mean (range)	55 (23-81)
Number of aneurysms	
Clipped	143
Coiled	1 (middle cerebral artery)
Observed	1 (middle cerebral artery)
Total	145
Number of aneurysms per patient	
One	99
Two	15
Three	4
Four	1
Location of clipped aneurysms	
Anterior cerebral artery	2 (1.4%)
Anterior communicating artery	38 (26.6%)
Pericallosal artery	3 (2.1%)
Internal carotid artery	43 (30.0%)
Middle cerebral artery	52 (36.4%)
Basilar artery	2 (1.4%)
Posterior inferior cerebellar artery	2 (1.4%)
Vertebral artery	1 (0.7%)

made on an Advantage Windows 4.3 workstation with dedicated 3D software for neuroimaging. The results of the CTA studies were evaluated independently by a team of two radiologists and a team of two neurosurgeons. In cases of disagreement, the results were interpreted jointly with the participation of the senior neurosurgeon (AM). The assessment of each CTA examination included analysis of 2D scans and 3D reconstructions.

Neither digital subtraction angiography nor CTA was performed routinely in the early period after clipping. We reviewed the descriptions of the surgical procedures to see if there had been any difficulties, for example, to see if neck remnants had been intentionally left.

Results

We did not observe any complications after intravenous administration of the contrast medium. In all but one patient, good quality CTA images were obtained, suitable for the evaluation of arteries around the clip site. In one case, significant artefacts around the clips were visible, but in spite of this, aneurysm regrowth was clearly visible, and so the patient was not excluded from the analysis. Of the 143 clipped aneurysms in 137 (96%) cases, complete aneurysm closure without residual neck or aneurysm regrowth and with normal filling of the arteries at the clip site were confirmed. Unsatisfactory clipping of 6 (4.2%) aneurysms included: clip dislocation with aneurysm renewal in 1 (0.7%), aneurysm regrowth with rebleeding in 1 (0.7%) and neck remnants in 4 (2.8%) cases. Two (1.4%) aneurysms required re-treatment and 4 (2.8%) neck remnants needed further surveillance. Four of the six unsatisfactory clipped aneurysms were located on AComA and two on MCA.

Clip slippage

In one case (0.7%) a total clip dislocation from the aneurysm dome was found (Fig. 1I). The aneurysm was located on AComA. For accurate interpretation, the follow-up CTA was compared with preoperative CTA and the surgery report was also analysed. In the preoperative study, the aneurysm looked the same. There was no inconsistency between preoperative CTA and the intraoperative image. There were no rebleeding episodes and no perceptible enlargement of the aneurysm during 3 years of follow-up. The aneurysm was successfully re-treated with endovascular implantation of a flow-diverter stent.

Aneurysm re-rupture

Only one (0.7%) case of recurrent SAH was noted during the period of interest. This patient underwent surgery for ruptured AComA aneurysm 11 years ago. The cause of rebleeding was aneurysm regrowth at the site of previous clipping (Fig. 1G-H). The recurrent SAH and source of rebleeding were established based on clinical symptoms, CT scan and CTA examination. The patient was operated on again. During the same procedure the aneurysm regrowth and unruptured 'de novo' MCA aneurysm were clipped and the patient was discharged from hospital in good condition. This one

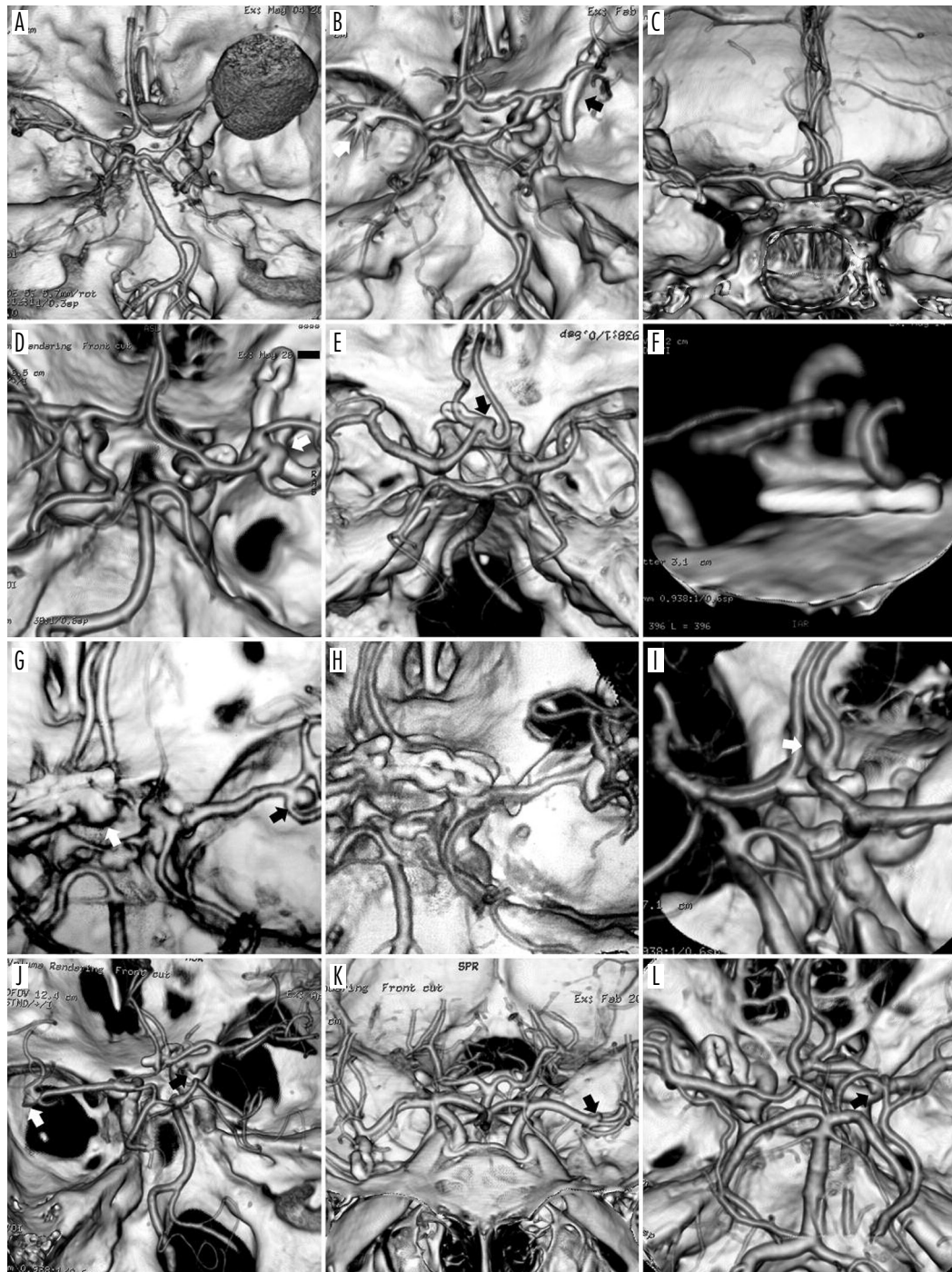


Fig. 1. A) Giant, ruptured aneurysm of the right MCA and unruptured aneurysm of the left MCA. B) The same patient. Follow-up CTA showed no evidence of residual aneurysm 3 years after clipping (black arrow). Elective coiling of the unruptured aneurysm of contralateral MCA was performed. Assessment of coiling effectiveness is not possible in CTA because of artefacts (white arrow). C) Satisfactory follow-up CTA after right MCA and left ICA aneurysms clipping. D) Neck remnant after right MCA aneurysm clipping (white arrow) and new, small aneurysm of the left ICA just above PComA arising. CTA was performed 4 years after surgery. E) Neck remnant after AComA aneurysm clipping (black arrow). This is the first follow-up CTA, 6 years after surgery. F) The same aneurysm in magnification. Slow regrowth of the aneurysm in the future is suspected; thus the patient requires further observation. G) A case of rebleeding 11 years after clipping. The cause of re-rupture was AComA aneurysm regrowth at the previous clip site (white arrow). 'De novo' aneurysm of the right MCA (black arrow). H) Early follow-up CTA after re-operation (clipping of renewed AComA and 'de novo' MCA aneurysms). The quality of both reconstructions is poor, because of artefacts from older clips. I) Clip slippage (white arrow) and AComA aneurysm renewal. J-L) Small 'de novo' aneurysms (arrows) in distant locations from previously clipped aneurysms

case of rebleeding gives an annual rate of re-rupture of 0.13% during 762 person-years and 0.1% during 931 aneurysm-years of follow-up.

Neck remnants

In 4 (2.8%) cases, neck remnants were detected. Two of them were located on AComA and two on MCA (Fig. 1D-F). However, we cannot be sure whether these findings were definitely remnants or regrowths, because early vascular imaging was not performed. On the other hand, based on an analysis of preoperative aneurysm shape and operative descriptions, we assume that small remnants could remain in these cases. This could be expected due to a complex anatomical configuration and the narrowing of the parental artery was avoided by means of incomplete neck clipping. The follow-up period was 4-9 years (mean 6 years) in this subgroup. None of these patients required re-treatment because of the small size of the remnants. Subsequent CTA after 1 year was carried out in each of them and no remnant enlarged. Further screening at annual intervals was recommended.

'De novo' aneurysms

Nineteen new aneurysms in other locations, not visible in the preoperative studies, were found in 14 (12%) patients (Fig. 1J-L). Eleven patients had single 'de novo' aneurysms, two patients had 2 and one patient had 4. In this subgroup, one 'de novo' aneurysm of the MCA was clipped taking the opportunity during surgery of re-ruptured AComA aneurysm (Fig. 1G-H). The remaining aneurysms are followed up with periodical CTA. The issue of 'de novo' aneurysms will be elaborated in a separate study.

Summing up all of the pathological findings in the study group, there were 18 (15%) patients who required further management including active observation or re-treatment (12 patients with 'de novo' aneurysm formation, 4 with unsatisfactory clipping and 2 with both; see Fig. 1D-G).

Infundibular origin of the posterior communicating artery (PCoMA) was noted in 9 cases (see Fig. 1F close to the clip site on the left side). These were not regarded as pathology that required subsequent screening tests. However, differentiation between 'de novo' aneurysm and infundibular origin of PCoMA was the only cause of disagreement between the radiology and neurosurgical teams. Five such cases were ultimately found to be infundibular.

Discussion

Durability of aneurysm clipping

In the past, the only examination for evaluation of the efficacy of aneurysm clipping was DSA. However, DSA has not been widely performed in long-term follow-up due to its invasiveness. Over the last two decades, more publications on this topic have appeared because of the need for comparison of the efficacy of two modalities: clipping and coiling [8-11]. In a series of DSA performed in the Barrow Neurological Institute (Phoenix, USA) at a mean of 4.4 years post surgery, the overall risk of regrowth of totally closed aneurysm was 1.5% and the annual risk of 'de novo' aneurysm formation was 1.8%. The overall risk of enlargement was 25% for small neck remnants and 75% for broad-based residua [8]. In a series of 136 patients with 166 clipped aneurysms, Akyüz *et al.* found no aneurysm regrowth, two 'de novo' aneurysms and one enlargement out of 5 residual aneurysms, at a mean of 3.9 years after surgery [9]. Tsutsumi *et al.* reported 3 aneurysm regrowths out of 125 completely clipped, during a mean follow-up of 9 years. The overall risk of aneurysm regrowth was 2.9% during this period and the risk of 'de novo' aneurysm formation was 0.89% per year [10]. In our series, permanent and complete obliteration of aneurysm was confirmed in 96% of cases.

Recurrent subarachnoid haemorrhage

The most important aspect of follow-up testing is the risk of recurrent SAH. The highest risk of post-procedural rebleeding is reported in the first year after treatment and based on ISAT and CARAT studies, and this is estimated to be 1.7-1.8% [12,13]. The CARAT investigators, who focused on events after 1-year follow-up, reported that the risk of rebleeding is very low for both coiled and clipped aneurysms. They noted no case of rebleeding (> 1 year after treatment) in 439 patients after clipping, during a mean follow-up of 6.1 years (annual risk – 0%) and only 1 case of rebleeding in 173 patients after coil embolisation during a mean follow-up of 5.2 years (annual risk – 0.1%) [12]. In the material of Schaafsma *et al.* the overall rate of rebleeding was 0.7% and 3% within the first 8 years after coiling and clipping, respectively [14]. Kakinuma *et al.* reported 7 rehaemorrhages (including 5 from 'de novo' and 2 from regrowth of clipped aneurysms) in 482 pa-

tients, at a mean interval of 7.3 years after clipping. Annual risk of subsequent SAH from both 'de novo' aneurysms and regrowths was 0.2% [15]. In our series, the overall and annual risk of aneurysm re-rupture were 0.7% and 0.1% respectively.

In the CARAT study, the degree of aneurysm occlusion was the most important factor influencing the risk of re-rupture [16]. They reported 19 post-procedural haemorrhages in a series of 1001 patients with coiled and clipped aneurysms, during a mean follow-up of 4 years. The overall risk of re-rupture was 1.1% for aneurysms completely occluded and 17.6% for remnants > 30% of the initial aneurysm volume.

Despite the low risk of subsequent haemorrhage, it is emphasised that this is still higher than in the general population. Some authors postulate closer surveillance of those patients including periodic performance of CTA or MRA, and DSA in cases where residual neck is known [15]. However, the benefit of routine long-term screening in every patient after clipping is questionable, in the light of possible complications from preventive DSA and re-treatment [17]. Moreover, most of the findings will probably never need treatment. In our opinion, the low risk of rehaemorrhage, reported by us and recent literature [18], warrants a more conservative approach. The use of periodic CTA is justified in cases where incomplete aneurysm occlusion is known or suspected and if risk factors for rebleeding and 'de novo' aneurysms exist, including hypertension, family history of aneurysms, autosomal-dominant polycystic kidney disease or a history of smoking or multiple aneurysm [8,19-21]. However, special attention should be given to patients who experienced SAH at a young age. The mean follow-up in most of the reported series does not exceed 10 years [8-10,14,16,21], whereas the majority of us probably remember patients with rebleeding > 10 years after clipping. It is noteworthy that in the series of Wermer *et al.* all three definite aneurysm regrowths were discovered in the second decade after SAH [21]. In the series of Nakase *et al.* the average time for the formation of recurrent aneurysms was 10.1 years after initial surgery [22]. Tsutsumi *et al.* reported an increasing risk of SAH in the second decade after clipping [23]. Therefore, imaging of the brain arteries in patients with long life expectancy performed at longer intervals (e.g. 10 and 20 years after clipping) may be more reasonable than performing it only in the first few years [10].

Clip slippage

In the era of new generation titanium clips, this phenomenon is extremely rare. However, in older series it was occasionally reported in control DSA or as a cause of rebleeding [24-27]. Possible causes of clip slippage may be different, mostly aneurysm- and clip-dependent [28].

Aneurysm remnants

Due to the fact that we did not perform early control CTA or DSA after clipping, we cannot definitely predicate whether those 4 (3%) remnants were only residual or regrowths. A slow enlargement of the neck remnants also cannot be excluded. However, analysis of the operation descriptions suggested that a part of the aneurysm could remain in these cases because of complex vascular anatomy and the risk of parental artery narrowing. In early postoperative angiograms a residual filling of the aneurysmal neck after clipping is visible in about 5% of the cases in the reported series [2,29] and those patients should be followed with closer surveillance.

Four of six aneurysms with unsatisfactory clipping were located on AComA. This represents 11% of all AComA aneurysms, and 2 remnants located on MCA represent 4% of all MCA aneurysms. The MCA and AComA locations are particular and clipping is still the preferred method for these aneurysms, because open surgery allows better control of the vascular anatomy and multiple corrections of the clip position are possible until final clip placement. However, sometimes leaving part of the neck, intentionally, is reasonable. Thus in such technically demanding aneurysms, early CTA or DSA is indicated for confirmation of its total obliteration or as a baseline study for subsequent examinations. According to our results, AComA and MCA aneurysms seem to be more prone to incomplete clipping and these locations require special supervision.

There is a technical problem of treatment of aneurysm remnants after clipping. The risk of rebleeding is influenced by the remnant size [16]. Small 'dog-eared' remnants are challenging to eliminate and therefore attempts of treatment only for 'radiological outcome' improvement would probably create a higher risk of complications when compared to the potential benefit. The remnants we found in our series do not need any treatment because of their small size, although they will be followed up with subsequent CTA. We intend to treat, after detection of progression, those remnants that will be technically possible to treat.

Summing up all of the pathological findings in our series, as many as 15% of the patients require further surveillance or treatment. Similarly, Wermer *et al.* reported different kinds of aneurysms ('de novo', remnants, regrowths, already known, etc.) in 112 (18%) patients in a series of 610 patients, after a mean follow-up of 8.9 years. However, they also proved that a significant number of those findings were already visible in retrospect. Nevertheless, they conclude that the development of intracranial aneurysms is more of a continuous process than a once-in-a-lifetime event [21]. We agree with this thesis; however, the high efficacy of clipping and the low risk of rebleeding argue for long-term screening only in a selected group rather than in all patients.

Infundibular dilatations

Infundibulum at the origin of the posterior communicating artery was not regarded as a significant pathology and further screening was not recommended to the patient. However, formation of 'de novo' aneurysm from the infundibulum is rarely reported and periodic imaging for dilatations of 3 mm or more may be reasonable [30]. On the other hand, the resolution of CTA allows the visualisation of the origin widening while the distal course of the small-calibre artery may not be visible. Then the infundibulum may be wrongly judged as an aneurysm formation [31], although in order to avoid doubt, the precise rendering and assessment of a CTA scan are usually sufficient [32].

Limitations of computed tomography angiography

A few comparative studies on CTA and DSA for the evaluation of aneurysm clipping have been published over the last decade. The sensitivity and specificity of CTA for detecting neck remnants were reported to be 60-100% and 83-100%, respectively [5,6,33-36]. Along with the development of new CT devices, high accuracy of CTA has recently been reported [5,6,37]. CTA is less time consuming and highly cost-effective, when compared to DSA [5,6]. Due to less invasiveness, its routine use after clipping is recommended by some authors [5,6,38]. However, different drawbacks of CTA should be mentioned. Technical difficulties, such as the acquisition of images too late, and clip or motion artefacts, may be a cause of limited image quality [5]. The accuracy of the image is influenced by the number of clips used. The more clips, the more artefacts there are and the worse is the quality of the CTA image [34]. Arte-

facts, if any, are usually insignificant if a titanium-alloy clip was used [37]. However, assessment of the nearest proximity to the clip (≤ 2 mm) may be doubtful as well [34,39]. In contrast, cobalt-alloy clips entail significant artefacts and the CTA image may not be reliable (Fig. 1G-H). However, even in such cases, special techniques make it possible to subtract them [37,40].

Based on clinical and phantom research by van der Schaaf *et al.*, the quality of image around the clip site is negatively influenced by many factors, including increasing pitch (particularly > 0.6), lower kilovoltage peak, cobalt-alloy clip and parallel clip direction to the scan plane. For minimising the artefacts they proved the superiority of the following settings: a pitch of 0.6, 140 kVp, 370 mgI/mL contrast medium [39].

However, the influence of the angle between the clip branches and the examination plane on the readability of images is still unclear. When the clip-gantry angle is close to 0 degrees, artefacts are significant in the axis of the clip, but laterally from its branches the image is adequate. Conversely, in oblique orientations of the clip (30-60 degrees), the image quality may generally be better, but artefacts appear laterally from the clip and can hamper the evaluation of the most important area [41,42].

For these reasons, DSA is still considered as the gold standard. Many authors recommend its use to confirm the pathology seen in CTA or if its image is doubtful [5,6,34,38]. The comparison of CTA and DSA was not the aim of our study. However, in our experience, high quality images were acquired in all cases of titanium clips, allowing trustworthy evaluation of the arterial patency and the completeness of aneurysm obliteration close to the clip. Moreover, we have used CTA for diagnosing patients with SAH and planned surgery without DSA for almost 10 years. It is our belief that the quality of CTA is sufficient for these purposes in most cases and the use of DSA may be limited to doubtful cases [43].

Limitations of our research

Our series contains only 58% of the patients invited to the study. Unfortunately, most long-term follow-up analyses encompass only a proportion of treated patients [2,10,11,15,21]. The unexplored groups include patients who died of various causes (possibly also due to rebleeding), severely disabled patients at discharge, and those who were not interested in invasive screening tests. Some series set age limitations, e.g. 18-70 years old [21]. Hence, such analyses, including ours, have limited reliability and may be liable to error. Despite these imper-

fections, which are difficult to avoid, the long-term analyses are useful because the potential preventive treatment is reasonable, especially in patients in good condition with long life expectancy.

Conclusions

Computed tomography angiography is a simple and reliable method of aneurysm clipping evaluation. Long-term follow-up CTA confirmed permanent and complete obliteration in 96% of aneurysms. The rate of unsatisfactory aneurysm closure was 4%, but only 1.4% needed re-treatment during a mean follow-up of 6 years. The annual risk of rebleeding due to aneurysm regrowth was 0.1%. The satisfactory durability of clipping justifies long-term screening only in patients with risk factors for rebleeding.

Disclosure

Authors report no conflict of interest.

References

- Wallace R.C., Karis J.P., Partovi S., et al. Noninvasive imaging of treated cerebral aneurysms, Part II: CT angiographic follow-up of surgically clipped aneurysms. *AJNR Am J Neuroradiol* 2007; 28: 1207-1212.
- Thornton J., Bashir Q., Aletich V.A., et al. What percentage of surgically clipped intracranial aneurysms have residual necks? *Neurosurgery* 2000; 46: 1294-1298.
- Villablanca J.P., Jahan R., Hooshi P., et al. Detection and characterization of very small cerebral aneurysms by using 2D and 3D helical CT angiography. *AJNR Am J Neuroradiol* 2002; 23: 1187-1198.
- Chen W., Wang J., Xin W., et al. Accuracy of 16-row multislice computed tomographic angiography for assessment of small cerebral aneurysms. *Neurosurgery* 2008; 62: 113-121.
- Dehdashti A.R., Binaghi S., Uske A., et al. Comparison of multislice computerized tomography angiography and digital subtraction angiography in the postoperative evaluation of patients with clipped aneurysms. *J Neurosurg* 2006; 104: 395-403.
- Chen W., Yang Y., Qiu J., et al. Sixteen-row multislice computerized tomography angiography in the postoperative evaluation of patients with intracranial aneurysms. *Br J Neurosurg* 2008; 22: 63-70.
- Serafin Z., Strzeńniewski P., Lasek W., et al. Methods and time schedule for follow-up of intracranial aneurysms treated with endovascular embolization: a systematic review. *Neurol Neurochir Pol* 2011; 45: 421-430.
- David C.A., Vishteh A.G., Spetzler R.F., et al. Late angiographic follow-up review of surgically treated aneurysms. *J Neurosurg* 1999; 91: 396-401.
- Akyüz M., Tuncer R., Yilmaz S., et al. Angiographic follow-up after surgical treatment of intracranial aneurysms. *Acta Neurochir (Wien)* 2004; 146: 245-250.
- Tsutsumi K., Ueki K., Morita A., et al. Risk of aneurysm recurrence in patients with clipped cerebral aneurysms: results of long-term follow-up angiography. *Stroke* 2001; 32: 1191-1194.
- Hayakawa M., Murayama Y., Duckwiler G.R., et al. Natural history of the neck remnant of a cerebral aneurysm treated with the Guglielmi detachable coil system. *J Neurosurg* 2000; 93: 561-568.
- CARAT Investigators. Rates of delayed rebleeding from intracranial aneurysms are low after surgical and endovascular treatment. *Stroke* 2006; 37: 1437-1442.
- ISAT: Molyneux A., Kerr R., Stratton I., et al. International subarachnoid aneurysm trial (ISAT) of neurosurgical clipping versus endovascular coiling in 2143 patients with ruptured intracranial aneurysms: a randomised trial. *Lancet* 2002; 360: 1267-1274.
- Schaafsma J.D., Sprengers M.E., van Rooij W.J., et al. Long-term recurrent subarachnoid hemorrhage after adequate coiling versus clipping of ruptured intracranial aneurysms. *Stroke* 2009; 40: 1758-1763.
- Kakinuma K., Ezuka I., Yamada H., et al. Long-term follow-up after treatment for cerebrovascular disease. Late follow-up review of clipped cerebral aneurysms. *Surgery for Cerebral Stroke* 2002; 30: 88-92.
- Johnston S.C., Dowd C.F., Higashida R.T., et al. CARAT Investigators. Predictors of rehemorrhage after treatment of ruptured intracranial aneurysms: the Cerebral Aneurysm Rupture After Treatment (CARAT) study. *Stroke* 2008; 39: 120-125.
- Wermer M.J., Buskens E., van der Schaaf I.C., et al. Yield of screening for new aneurysms after treatment for subarachnoid hemorrhage. *Neurology* 2004; 62: 369-375.
- Edner G., Almqvist H. The Stockholm 20-year follow-up of aneurysmal subarachnoid hemorrhage outcome. *Neurosurgery* 2007; 60: 1017-1023.
- Wermer M.J., Rinkel G.J., van Gijn J. Repeated screening for intracranial aneurysms in familial subarachnoid hemorrhage. *Stroke* 2003; 34: 2788-2791.
- Xu H.W., Yu S.Q., Mei C.L., et al. Screening for intracranial aneurysm in 355 patients with autosomal-dominant polycystic kidney disease. *Stroke* 2011; 42: 204-206.
- Wermer M.J., van der Schaaf I.C., Velthuis B.K., et al. ASTRA Study Group. Follow-up screening after subarachnoid haemorrhage: frequency and determinants of new aneurysms and enlargement of existing aneurysms. *Brain* 2005; 128: 2421-2429.
- Nakase H., Kamada Y., Aoki H., et al. Clinical study on recurrent intracranial aneurysms. *Cerebrovasc Dis* 2000; 10: 255-260.
- Tsutsumi K., Ueki K., Usui M., et al. Risk of subarachnoid hemorrhage after surgical treatment of unruptured cerebral aneurysms. *Stroke* 1999; 30: 1181-1184.
- Drake C.G., Allcock J.M. Postoperative angiography and the "slipped" clip. *J Neurosurg* 1973; 39: 683-689.
- Czochra M., Złomaniec J., Kamiński S., et al. Angiographic evaluation of the effectiveness of surgical treatment of intracranial aneurysm. *Neurol Neurochir Pol* 1980; 14: 639-644.
- Asgari S., Wanke I., Schoch B., et al. Recurrent hemorrhage after initially complete occlusion of intracranial aneurysms. *Neurosurg Rev* 2003; 26: 269-274.

27. Schmid-Elsaesser R., Steiger H.J. Aneurysm clip slippage. *J Neurosurg* 2000; 93: 371-373.
28. Carvi y Nievas M.N., Höllerhage H.G. Risk of intraoperative aneurysm clip slippage: a new experience with titanium clips. *J Neurosurg* 2000; 92: 478-480.
29. Acevedo J.C., Turjman F., Sindou M. Postoperative arteriography in surgery for intracranial aneurysm. Prospective study in a consecutive series of 267 operated aneurysms. *Neurochirurgie* 1997; 43: 275-284.
30. Fischer S., Hopf N., Henkes H. Evolution from an infundibulum of the posterior communicating artery to a saccular aneurysm. *Clin Neuroradiol* 2011; 21: 87-90.
31. Yasui T., Kishi H., Komiyama M., et al. The limitations of three-dimensional CT angiography (3D-CTA) in the diagnosis of cerebral aneurysms. *No Shinkei Geka* 2000; 28: 975-981.
32. Kubota T., Niwa J., Tanigawara T., et al. Differential diagnosis between aneurysm and infundibular dilatation in the IC-PC region with 3D-CTA. *No Shinkei Geka* 2000; 28: 31-39.
33. Sakuma I., Tomura N., Kinouchi H., et al. Postoperative three-dimensional CT angiography after cerebral aneurysm clipping with titanium clips: detection with single detector CT. Comparison with intra-arterial digital subtraction angiography. *Clin Radiol* 2006; 61: 505-512.
34. Gerardin E., Tollard E., Derrey S., et al. Usefulness of multislice computerized tomographic angiography in the postoperative evaluation of patients with clipped aneurysms. *Acta Neurochir (Wien)* 2010; 152: 793-802.
35. Uysal E., Ozel A., Erturk S.M., et al. Comparison of multislice computed tomography angiography and digital subtraction angiography in the detection of residual or recurrent aneurysm after surgical clipping with titanium clips. *Acta Neurochir (Wien)* 2009; 151: 131-135.
36. Teksam M., McKinney A., Cakir B., et al. Multi-slice computed tomography angiography in the detection of residual or recurrent cerebral aneurysms after surgical clipping. *Acta Radiol* 2004; 45: 571-576.
37. Zachenhofer I., Cejna M., Schuster A., et al. Image quality and artefact generation post-cerebral aneurysm clipping using a 64-row multislice computer tomography angiography (MSCTA) technology: A retrospective study and review of the literature. *Clin Neurol Neurosurg* 2010; 112: 386-391.
38. van Loon J.J., Yousry T.A., Fink U., et al. Postoperative spiral computed tomography and magnetic resonance angiography after aneurysm clipping with titanium clips. *Neurosurgery* 1997; 41: 851-856.
39. van der Schaaf I., van Leeuwen M., Vlassenbroek A., et al. Minimizing clip artifacts in multi CT angiography of clipped patients. *AJNR Am J Neuroradiol* 2006; 27: 60-66.
40. Watanabe Y., Kashiwagi N., Yamada N., et al. Subtraction 3D CT angiography with the orbital synchronized helical scan technique for the evaluation of postoperative cerebral aneurysms treated with cobalt-alloy clips. *AJNR Am J Neuroradiol* 2008; 29: 1071-1075.
41. Pechlivanis I., Koenen D., Engelhardt M., et al. Computed tomographic angiography in the evaluation of clip placement for intracranial aneurysm. *Acta Neurochir (Wien)* 2008; 150: 669-676.
42. Pechlivanis I., König M., Engelhardt M., et al. Evaluation of clip artefacts in three-dimensional computed tomography. *Cen Eur Neurosurg* 2009; 70: 9-14.
43. Kunert P., Janowski M., Marchel A. Angiography and aneurysms. *J Neurosurg* 2004; 100: 980-981.