

Spinal cheiro-oral syndrome: a common neurological entity in an unusual site

Rdzeniowy zespół twarzowo-palcowy: częsty zespół w nietypowej lokalizacji

Hung-Sheng Lin¹, Hsin-Ling Yin², Chi-Chui^{3,4}, Chun-Chung Lui⁵, Wei-Hsi Chen^{1,4,6}

¹Department of Neurology, Chang Gung Memorial Hospital – Kaohsiung Medical Center and College of Medicine, Chang Gung University, Kaohsiung, Taiwan

²Department of Pathology, Kaohsiung Medical University Hospital and College of Medicine, Kaohsiung Medical University, Kaohsiung, Taiwan

³Department of Neurosurgery, Paochien Hospital, Pingtung, Taiwan

⁴Graduate Institute of Science and Technology Law, National Kaohsiung First University of Science and Technology, Kaohsiung, Taiwan

⁵Department of Neuroradiology, Chang Gung Memorial Hospital – Kaohsiung Medical Center and College of Medicine, Chang Gung University, Kaohsiung, Taiwan

⁶Department of Neurology, Kaohsiung Medical University Hospital and College of Medicine, Kaohsiung Medical University, Kaohsiung, Taiwan

Neurologia i Neurochirurgia Polska 2011; 45, 6: 583-589

Abstract

Background and purpose: Cheiro-oral syndrome (COS) is an established neurological entity characterized by a sensory impairment confined to the mouth angle and ipsilateral finger(s)/hand. The current understanding of localization is a concomitant involvement of the spinothalamic and trigeminothalamic tract between the cortex and pons. The cervical spinal cord has not been mentioned in this situation yet, and this unusual location may heretofore increase the risk of misdiagnosis.

Material and methods: Six patients who presented with unilateral COS due to cervical cord disorder are reported.

Results: All patients were women and their age ranged between 42 and 70 years. Their neurological deficits included unilateral paraesthesiae restricted to cheiro-oral distribution, positive radicular sign, and mild change of tendon reflex. Cervical spinal stenosis at middle/lower cervical spine with variable magnitude of cord compression and intrinsic cord damage was found. A diagnostic dilemma obviously arises from the lack of tangible neurological signs or typical pattern of myelopathy, in addition to the previous concept of cerebral involvement. A benign course ensued in all reported patients.

Conclusions: Cheiro-oral syndrome can be an early neurological sign for cervical cord disorder; it further suggests that it is a strong neurological but weak localizing sign. A reciprocal

Streszczenie

Wstęp i cel pracy: Zespół twarzowo-palcowy (ZTP) jest znanym zespołem neurologicznym, który cechuje się niedoczułicą ograniczoną do kącika ust i palców ręki lub ręki po tej samej stronie. Bieżący stan wiedzy dotyczący lokalizacji uszkodzenia w tym zespole wskazuje na jednoczesne zajęcie dróg rdzeniowo-wzgórzowej i trójdzielno-wzgórzowej pomiędzy mostem i korą mózgową. W tym kontekście nie wymieniano dotąd uszkodzenia rdzenia kręgowego w odcinku szyjnym, a taka nietypowa lokalizacja uszkodzenia może zwiększyć ryzyko błędnego rozpoznania miejsca uszkodzenia.

Materiał i metody: W pracy przedstawiono dane dotyczące 6 pacjentek z jednostronnym ZTP spowodowanym występowaniem nieprawidłowości w obrębie rdzenia kręgowego.

Wyniki: Zakres wieku pacjentek wynosił od 42 do 70 lat. Objawy neurologiczne obejmowały jednostronne parestezje ograniczone do obszaru twarzy i ręki, objaw korzeniowy i niewielkie nieprawidłowości w zakresie odruchów głębokich. Stwierdzono występowanie zwężenia kanału kręgowego w środkowej lub dolnej części odcinka szyjnego z uciskiem rdzenia kręgowego i uszkodzeniem wewnątrz rdzenia kręgowego. Wątpliwości diagnostyczne wynikały z braku typowych objawów neurologicznych mielopatii i stwierdzenia lokalizacji zmian nieodpowiadającej wcześniejszym opiniom na temat

Correspondence address: Dr. Wei-Hsi Chen, Department of Neurology, Chang Gung Memorial Hospital – Kaohsiung Medical Center, 123 Tai Pei Road, Niao Sung District, Kaohsiung City 833, Taiwan, phone 886 7 7317123, e-mail: brainhemostasis@yahoo.com

Received: 20.02.2011; accepted: 7.07.2011

influence of multiple factors is considered to generate COS at the cervical cord. Therefore, an absence of brain pathology should lead to a thorough examination of the cervical cord in case of COS.

Key words: cheiro-oral syndrome, radicular sign, spinal cord, myelopathy, sensory, localization.

Introduction

Cheiro-oral syndrome (COS), first reported by Sir Siting in 1914 [1], is characterized by a subjective or an objective sensory impairment confined to the mouth angle and ipsilateral finger(s)/hand. It is an incomplete form of pure sensory syndrome, and differs from the ictal paraesthesia with cheiro-oral distribution in migraine. In contrast to the earlier concept that COS was a clinical marker of involvement of the thalamus or parietal cortex and signified a benign outcome [2,3], it is currently known to arise from a concomitant involvement of the spinothalamic and trigeminothalamic tract between the medulla oblongata and cortex [4-7] with various clinical presentations [4,7-10].

Herein, we report six COS patients in whom the location of the lesion is considered to be at the cervical spinal cord. This location was not mentioned before in the literature. This unusual site of location further implicates a weak localizing value for COS but raises the possibility of an extracerebral source in the clinical work-up.

Material and methods

A prospective study has been conducted to enrol patients who presented with COS and its variants since 1989. Cheiro-oral syndrome was strictly defined as a sensory impairment, subjective and/or objective, confined to the mouth corner and ipsilateral finger(s)/hand, without a detectable abnormality in mental, memory, motor or cerebellar function [4]. However, a mild change of tendon reflex or muscle tone without a consistent decrease of muscle strength, or a concurrent focal seizure or movement disorder, was not an exclusion criterion. Cheiro-oral syndrome variants were clinical entities presenting with restricted acral sensory deficit confined to any two or more

mózgowego pochodzenia zespołu. U wszystkich opisywanych pacjentek przebieg schorzenia był łagodny.

Wnioski: Zespół twarzowo-palcowy może być wczesnym objawem neurologicznym nieprawidłowości w obrębie rdzenia kręgowego. Stanowi istotny objaw neurologiczny, ale jego wartość lokalizacyjna jest niewielka. Powstawanie ZTP wskutek uszkodzenia rdzenia kręgowego wynika z wzajemnych oddziaływań wielu czynników. W razie braku uchwytnej patologii mózgu należy w przypadkach ZTP przeprowadzić szczegółowe badania rdzenia kręgowego w odcinku szyjnym.

Słowa kluczowe: zespół twarzowo-palcowy, objaw korzeniowy, rdzeń kręgowy, mielopatia, czuciowy, lokalizacja.

locations at the mouth angle, tongue or intra-oral cheek, hand/finger(s) or foot/toe(s), such as the cheiro-oral-buccal syndrome (hand/finger, mouth angle and buccum), cheiro-pedal syndrome (hand/finger and foot/toe), or cheiro-oral-pedal syndrome (hand/finger, mouth angle and foot/toe). The patient was not enrolled if COS or its variant was a residual sensory deficit of an antecedent stroke event, an aura or ictal symptom in migraine, a symptom of hyperventilation syndrome, pharmacotoxicity, infection or intoxication.

In each patient a detailed neurological examination was performed along with computerized tomography or magnetic resonance imaging (MRI), and somatosensory evoked potential (SSEP) to investigate the pathological location and underlying cause. If necessary, further appropriate tests would be performed and those procedures were fully mentioned in our previous reports [4,5,7-10].

Results

Between 1989 and 2007, there were 76 COS patients enrolled [4]. In 55 patients, corresponding lesions were identified, including ischaemic stroke, haemorrhagic stroke, brain neoplasm and vascular malformation. In another 21 patients, no consistent corresponding lesion was considered – only old brain infarctions in 14 patients, no structural lesion in brain or spinal cord in 1 patient, and variable magnitude of cervical spondylosis and cord changes in 6 patients, respectively.

In the latter 6 patients, their cheiro-oral paraesthesiae were exacerbated upon neck flexion/extension, that is, radicular sign, in contrast to another 15 patients with old brain infarctions or without a determined cause. A recovery of cheiro-oral paraesthesiae also ensued after aggressive physical therapy and life-style change. This characteristic relation prompted a consideration of spi-

nal origin of COS in these 6 patients. The term “spinal COS” was therefore used.

All patients with spinal COS were women and their age ranged between 42 and 70 years. They denied having migraine, reversible neurological or visual deficit, medical disease or trauma before, nor emotional change during paraesthesiae. Their clinical, neurological, neuroradiological, electrodiagnostic, and outcome findings are summarized in Table 1.

Antecedent symptoms

Besides cheiro-oral paraesthesia, all patients had had variable magnitude of intermittent soreness, tightness or numbness at neck, shoulder or upper limb before, and experienced exaggeration of acral paraesthesiae and, less frequently, perioral paraesthesia when the neck was turned or rotated on some occasions. An antecedent traumatic event or vigorous neck manipulation was substantially denied by all of them.

Sensory disorder of cheiro-oral paraesthesiae

Unilateral cheiro-oral paraesthesiae were left-sided in three patients and right-sided in another three. The paraesthesiae were of numb quality. The involvement of the ipsilateral thumb, index and middle finger was detected in 2 patients, and of the ipsilateral thumb only in another 4 patients. Pinprick pain was decreased in all patients whereas cotton fine touch was diminished in 3 patients. Vibratory sense, positional joint sensation, or cortical sensation did not change.

Radicular sign presenting as cheiro-oral paraesthesiae was detected in all patients. A mild paraesthesia at the upper neck and/or shoulder might sometimes occur in association with cheiro-oral paraesthesia upon neck flexion/extension. Except for hypaesthesia at the cheiro-oral region, there was no consistent sensory loss at other facial or body areas.

The severity of cheiro-oral paraesthesia was mild and did not significantly disturb daily activity.

Neurological signs

No patient showed any obvious change of muscle bulk or muscle tone. Mild motor signs, including arm dropping, arm deviation, Wartenberg's sign, finger escape sign, and abnormal opposing fingers, were not detected. Unilateral or focal brisk tendon reflex was detected in three patients, and mixed brisk and decreased tendon

reflex at different joints in another three patients. Hoffmann reflex was present in two patients whose tendon reflex was also brisk.

Neuroradiological findings

Head MRI study was performed in all patients on initial presentation and did not show an abnormal change between the cortex and medulla oblongata. A variable magnitude of vertebral and cord change was found in their spinal MRI, however (Fig. 1). Cord compression into bean-shaped and intrinsic cord damage was seen in three patients (Case 2, 4, 6), cord displacement with anterior flattening in one patient (Case 3), mild cord displacement, intrinsic cord damage without anterior flattening in one patient (Case 1), and intrinsic cord damage in one patient (Case 5). The cause was exclusively spondylotic stenosis. Cord compression was most severe at C3/C4 in one patient (Case 4), C4/C5 in two patients (Case 2, 3), and C5/C6 in three patients (Case 1, 5, 6).

Electrophysiology

Somatosensory evoked potential was normal in one patient. In another five patients, mild prolongation of latency or decrease of amplitude was detected at N9 and N13.

Outcome

There was no indication for surgery in any patient reported. They recovered from cheiro-oral paraesthesiae after physical and conservative treatment, including rest, non-steroidal anti-inflammatory drugs, and change of life style. Recovery of tendon reflex and Hoffmann reflex was subsequently detected in all patients. Spinal MRI was repeated in two patients but did not show any consistent change. Mild and transient cheiral or oral paraesthesiae still recurred occasionally in 4 patients after loading or lifting a heavy object. Cervicogenic soreness and/or tightness ameliorated but did not completely subside.

In all patients, blood antinuclear antibodies, rheumatoid factor, haematology, cyanocobalamin, and folate were within the reference range. On follow-up, neither showed a focal neurological deficit event compatible with multiple sclerosis.

Discussion

Although an isolated sensory disturbance at the fingertip/finger or face is not extremely rare in upper cer-

Table 1. Summary of clinical, neurological and neuroradiological findings in patients with spinal cheiro-oral syndrome

	Case 1	Case 2	Case 3	Case 4	Case 5	Case 6
Age, gender	48 years, female	70 years, female	42 years, female	57 years, female	55 years, female	50 years, female
Antecedent symptoms	Neck/shoulder soreness, tightness	Neck/shoulder/upper limb soreness tightness, numbness	Neck/shoulder soreness, tightness, fullness	Neck/shoulder/upper limb tightness, heaviness	Neck/shoulder/upper limb soreness, tightness, piercing	Neck/shoulder/upper limb soreness, tightness and numbness
Cheiro-oral symptoms	Left-sided, acute	Left-sided, acute	Right-sided, acute	Right-sided, acute	Right-side, acute	Left-sided, acute
Sensory symptoms ¹						
Decreased pinprick pain	Left mouth angle, homolateral thumb	Left mouth angle, homolateral thumb, index and middle finger	Right mouth angle, homolateral thumb	Right mouth angle, homolateral thumb	Right mouth angle, homolateral thumb	Left mouth angle homolateral thumb, index and middle finger
Decreased cotton fine touch	Not detected	Homolateral thumb, index and middle finger	Not detected	Homolateral thumb	Not detected	Homolateral thumb, index and middle finger
Radicular sign at cheiro-oral distribution	(+); neck flexion	(+); neck flexion and extension	(+); neck flexion	(+); neck flexion	(+); neck flexion	(+); neck flexion and extension
Neurological signs						
Motor soft signs ²	Absent	Absent	Absent	Absent	Absent	Absent
Tendon reflex ³	LW ↑	LB ↓; W, K and A ↑	RB ↓; K and W ↑	RB and W ↑	RW ↑	LB ↓; W and K ↑
Hoffmann reflex	Negative	Positive	Negative	Negative	Negative	Positive
MRI of the head	Normal	Normal	Normal	Normal	Normal	Normal
MRI of the cervical spinal cord	Cord displacement, intrinsic cord damage without anterior flattening	Bean-shaped cord compression and intrinsic cord damage	Cord displacement with anterior flattening	Bean-shaped cord compression and intrinsic cord damage	Intrinsic cord damage	Bean-shaped cord compression and intrinsic cord damage
Cord damage level ⁴	C4/C5	C4/C5	C3/C4	C5/C6	C5/C6	C5/C6
SSEP	Normal	N9,N13 latency prolonged, amplitude decreased; N9-N13 conduction time prolonged	N9,N13 latency prolonged, amplitude decreased; N9-N13 conduction time prolonged	N9,N13 latency prolonged, amplitude decreased; N9-N13 conduction time prolonged	N9,N13 latency prolonged, amplitude decreased; N9-N13 conduction time prolonged	N9,N13 latency prolonged, amplitude decreased; N9-N13 conduction time prolonged
Outcome	Recovery	Occasional perioral or acral numbness during lifting/loading	Recovery	Occasional acral numbness in lifting/loading	Occasional acral numbness in lifting/loading	Occasional perioral or acral numbness during lifting/loading

¹Cortical sensation, vibration, positional joint sensation were normal in all patients. ²Motor soft signs include arm dropping, arm deviation, Wartenberg's sign, finger escape sign, and abnormal opposing fingers. ³R – right, L – left, B – biceps reflex, W – brachioradialis reflex, K – knee reflex, A – ankle reflex. ⁴Level of the most severe stenosis. MRI – magnetic resonance imaging, SSEP – somatosensory evoked potentials

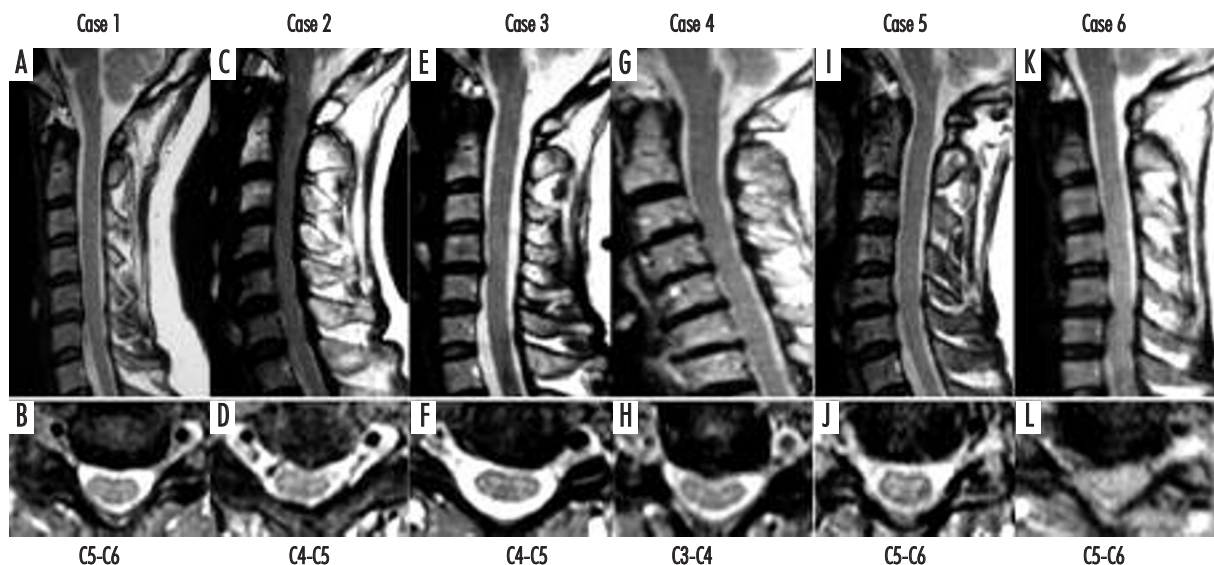


Fig. 1. Spinal MRI in sagittal and axial planes showing cervical cord in patients with spinal cheiro-oral syndrome. A bean-shaped cord compression (Case 2, 4, 6), intrinsic cord damage (Case 1, 2, 4, 5, 6), cord displacement with anterior flattening in one patient (Case 3), and mild cord displacement without anterior flattening in one patient (Case 1) were seen

vical cord lesions [11], a simultaneous paraesthesia of typical cheiro-oral distribution as in our patients has not been formally reported in cervical cord disorder before. Since the localization of COS is exclusively reported in the cerebral compartment [4], a proposal of spinal origin of COS in our series will bring out an inevitable critic despite a negative intracranial finding. Our condition is similar to Sasamori *et al.* [12], who honestly reported a transient COS in 28.6% of their patients in whom superficial temporal artery to middle cerebral artery anastomosis and indirect bypass were done in 2010, nearly one century after the first report. A mild and reversible sensory symptom, like COS, is always neglected, misinterpreted or under-reported in clinical practice. In addition, an accumulation of patient numbers may also recover a less common condition poorly known before. Therefore, underestimation of spinal origin of COS is not surprising and cannot be denied.

The traditional concept of the neuroanatomy of the trigeminothalamic tract challenges the diagnosis of spinal COS in our patients. There are two dilemmas. Firstly, the trigeminal sensory afferents enter into the trigeminal sensory tract at the pons and then ramify into ascending and descending fibres. Regarding the fibres which convey the pain, they initially descend into the cervical cord and then synapse with the spinal trigeminal nucleus at above the middle cervical level [13,14]. Then, these second-order afferents cross the midline, reach lamina IV and V of the grey matter of the cervical cord,

and then begin to ascend as the trigeminothalamic tract. On their way to the thalamus, they join with other crossed trigeminal sensory afferents at the pons to form the trigeminal lemniscus. The touch afferent of the perioral region is suggested to synapse at the pars oralis of the spinal trigeminal nucleus and then cross to the opposite site at the medullary level [14]. Accordingly, perioral paraesthesia is unlikely to occur in middle/lower cervical cord disorder, as in our patients, because the touch and pain afferents of the perioral region theoretically do not descend into this cervical level.

This predicament is cleared up when individual specificity with clinical variations is subsequently revealed, such as when a portion of corticofacial motor or oculomotor fibres descend deeply to the dorsolateral medulla oblongata and then return to the pons or midbrain. In fact, perioral paraesthesia has been reported in cases of upper [11,13] and also lower cervical cord lesions [15,16]. In an *ex vivo* study, the pars oralis afferents have already been identified to extend deeply into the lower cervical level [17]. Therefore, a distant extension of the trigeminal sensory fibres into the lower cervical cord is not a myth, but its scarcity properly clarifies the relatively low frequency of spinal COS in cervical cord disorder.

Secondly, the dilemma arises how the spinothalamic fibre and trigeminal sensory fibre co-express the cheiro-oral paraesthesia in cervical cord disorder. In order to produce an ipsilateral perioral and cheiral paraesthesia, these two afferent fibres must be involved at the same

location simultaneously. In view of the topography of these two afferent fibres in the cervical cord, they are close to each other at the dorsal horn of ipsilateral grey matter and also on their way to cross to the opposite side [14]. Therefore, spinal origin COS can be incited by involvement of the ipsilateral posterior or central grey matter at the cervical spinal cord regardless of responsible corresponding aetiology or cord change, as in our patients.

In addition to the topographic vulnerability, we also have to remember two other issues that may relate to spinal occurrence of COS. Firstly, an increase of sensory plasticity and a decrease of threshold in the enlarged receptive field of the finger(s)/hand have been identified in chronic spinal cord injury [14,15,18,19], such as compressive myelopathy [20], similar to cortical/subcortical injury [21]. Enlargement of the cheiral and perioral receptive field at the grey matter will predispose to cheiral-oral paraesthesia upon incitement in our patients. Secondly, vascular compromise [20], dentate tension [22], and stretch-associated stress and strain [23] have been found to cause remote spinal injury without conspicuous direct cord compression. This may explain the inconsistent cord change for COS in our series. Nevertheless, coincident reciprocal influences of individual neuroanatomy, functional neuronal change, and local dynamic response may generate this characteristic sensory syndrome at the cervical cord.

Radicular sign with cheiro-oral paraesthesia was provoked in our patients. The presumptive mechanism of radicular sign is mechanical stimulation of the root or regional neural structures by lengthening and deforming the affected area. In our patients, their radicular sign was consistently detected on neck manipulation, supporting the presence of injury at the root and regional structure in the cervical cord responsible for their cheiro-oral paraesthesia.

Our study is a clinical observational report of 6 COS patients in whom there is no consistent intracranial abnormality but the presence of radicular sign of cheiro-oral distribution, antecedent cervical spondylotic symptoms and variable magnitude of cervical stenosis and cord deformity. The underlying cause of cervical cord involvement is considered to be due to spondylotic myeloradiculopathy based on the clinical history and imaging findings. According to our findings, the neuroanatomical boundary of COS extends from the cortex to the cervical spinal cord. Unilateral COS is a strong neurological sign but a weak localizing predictor.

Conclusions

1. Cheiro-oral syndrome may be a clinical symptom of cervical cord disorder.
2. Cheiro-oral syndrome may occur due to damage of the cervical cord as well as due to brain involvement. Therefore, a thorough examination of the cervical cord is suggested in cases of COS without a consistent or corresponding intracranial lesion and especially with a positive radicular sign.
3. Cheiro-oral syndrome is a strong neurological sign but a weak localizing predictor, in contrast to the previous concept.

Acknowledgement

The authors thank Dr. Ming-Shun Chou (1948-2008), who kindly assisted in reviewing the neurological and neuroradiological data.

Disclosure

Authors report no conflict of interest.

References

1. Sitting O. Klinische Beiträge zur Lehre von der Lokalisation der sensiblen Rindenzentren. *Prager Med Wochenschr* 1914; 45: 548-550.
2. Strauss H. Über Sensibilitätsstörungen an Hand und Gesicht, Geschmacksstörungen und ihre lokalisatorische Bedeutung. *Monatsschrift für Psychiatrie und Neurologie* 1925; 58: 265-276.
3. Garcin R., Lapresle J. 2d personal observation of a sensory syndrome of the thalamic type with cheiro-oral topography caused by localized lesion of the thalamus. *Rev Neurol (Paris)* 1960; 103: 474-481.
4. Chen W.H. Cheiro-oral syndrome: a clinical analysis. *Yonsei Med J* 2009; 50: 777-783.
5. Chen W.H., Lan M.Y., Chang Y.Y., et al. Cortical cheiro-oral syndrome: a revisit of clinical significance and pathogenesis. *Clin Neurol Neurosurg* 2006; 108: 446-450.
6. Ngai W.K., Chang Y.Y., Liu J.S., et al. Cheiro-oral syndrome: identification of the lesion sites and a proposal for its clinical classification. *Kaohsiung J Med Sci* 1991; 7: 536-541.
7. Chen W.H., Li T.H., Chen T.H., et al. Crossed cheiro-oral syndrome. *Clin Neurol Neurosurg* 2008; 110: 1008-1011.
8. Chen W.H., Lan M.Y., Chang Y.Y., et al. Bilateral cheiro-oral syndrome. *Clin Neurol Neurosurg* 1997; 99: 239-243.
9. Chen W.H., Tseng Y.L., Lui C.C., et al. Episodic pain syndrome restricted cheiro-oral region associated with pontine lesion. *Brain Inj* 2005; 19: 949-953.

10. Chen W.H., Chang Y.Y., Yin H.L., et al. Bilateral cheiro-oral syndrome and traumatic subdural hematoma. *J Trauma* 1995; 38: 826-827.
11. Gurusinghe N.T. Clinical features of spinal compression. In: Critchley E., Eisen A. *Spinal Cord Disease: Basic Science, Diagnosis, and Management*. Springer, New York 1997, pp. 145-174.
12. Sasamori T., Kuroda S., Nakayama N., et al. Incidence and pathogenesis of transient cheiro-oral syndrome after surgical revascularization for moyamoya disease. *Neurosurgery* 2010; 67: 1054-1059.
13. Grieve G.P. *Common vertebral joint problem*. 2nd ed. Churchill Livingstone, London 1998.
14. Carpenter M.B., Sutin J. *Human Neuroanatomy*. 8 ed. Williams & Wilkins, London 1983.
15. Dutton C.B., Riley L.H. Jr. Cervical migraine. Not merely a pain in the neck. *Am J Med* 1969; 47: 141-148.
16. Chang H.S. Cervical central cord syndrome involving the spinal trigeminal nucleus: a case report. *Surg Neurol* 1995; 44: 236-239.
17. Devoize L., Doméjean S., Melin C., et al. Organization of projections from the spinal trigeminal subnucleus oralis to the spinal cord in the rat: a neuroanatomical substrate for reciprocal orofacial-cervical interactions. *Brain Res* 2010; 1343: 75-82.
18. Ding Y., Kastin A.J., Pan W. Neural plasticity after spinal cord injury. *Curr Pharm Des* 2005; 11: 1441-1450.
19. Darian-Smith C. Synaptic plasticity, neurogenesis, and functional recovery after spinal cord injury. *Neuroscientist* 2009; 15: 149-165.
20. Shedid D., Benzel E.C. Cervical spondylosis anatomy: pathophysiology and biomechanics. *Neurosurgery* 2007; 60 (1 Supp 1): S7-13.
21. Kaas J.H., Qi H.X., Burish M.J., et al. Cortical and subcortical plasticity in the brains of humans, primates, and rats after damage to sensory afferents in the dorsal columns of the spinal cord. *Exp Neurol* 2008; 209: 407-416.
22. Levine D.N. Pathogenesis of cervical spondylotic myelopathy. *J Neurol Neurosurg Psychiatry* 1997; 62: 334-340.
23. Henderson F.C., Geddes J.F., Vaccaro A.R., et al. Stretch-associated injury in cervical spondylotic myelopathy: new concept and review. *Neurosurgery* 2005; 56: 1101-1113.