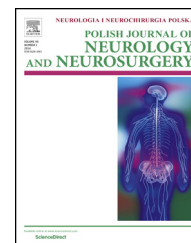


Available online at www.sciencedirect.com**ScienceDirect**journal homepage: <http://www.elsevier.com/locate/pjnns>**Review article****Standard neurophysiological studies and motor evoked potentials in evaluation of traumatic brachial plexus injuries – A brief review of the literature****Agnieszka Wiertel-Krawczuk^{*}, Juliusz Huber**

Department of Pathophysiology of Locomotor Organs, Poznań University of Medical Sciences, Poland

ARTICLE INFO**Article history:**

Received 9 February 2018

Accepted 9 May 2018

Available online 14 May 2018

Keywords:

Brachial plexus

Traumatic injury

Clinical neurophysiology

Motor evoked potentials

ABSTRACT

Purpose: Traumatic damage to the brachial plexus is associated with temporary or permanent motor and sensory dysfunction of the upper extremity. It may lead to the severe disability of the patient, often excluded from the daily life activity. The pathomechanism of brachial plexus injury usually results from damage detected in structures taking origin in the rupture, stretching or cervical roots avulsion from the spinal cord. Often the complexity of traumatic brachial plexus injury requires a multidisciplinary diagnostic process including clinical evaluation supplemented with clinical neurophysiology methods assessing the functional state of its structures. Their presentation is the primary goal of this paper.

Methods: The basis for the diagnosis of brachial plexus function is a clinical examination and neurophysiology studies: electroneurography (ENG), needle electromyography (EMG), somatosensory evoked potentials (SEPs) and motor evoked potentials (MEPs) assessing the function of individual brachial plexus elements.

Conclusions: The ENG and EMG studies clarify the level of brachial plexus damage, its type and severity, mainly using the Seddon clinical classification. In contrast to F-wave studies, the use of the MEPs in the evaluation of traumatic brachial plexus injury provides valuable information about the function of its proximal part. MEPs study may be an additional diagnostic in confirming the location and extent of the lesion, considering the pathomechanism of the damage. Clinical neurophysiology studies are the basis for determining the appropriate therapeutic program, including choice of conservative or reconstructive surgery which results are verified in prospective studies.

© 2018 Polish Neurological Society. Published by Elsevier Sp. z o.o. All rights reserved.

^{*} Corresponding author at: Department of Pathophysiology of Locomotor Organs, Poznań University of Medical Sciences, 28 Czerwca 1956r. No 135/147, 61-545 Poznań, Poland.

E-mail address: wiertelkrawczuk@ump.edu.pl (A. Wiertel-Krawczuk).<https://doi.org/10.1016/j.pjnns.2018.05.004>

0028-3843/© 2018 Polish Neurological Society. Published by Elsevier Sp. z o.o. All rights reserved.

1. Introduction

The brachial plexus is one of the most complex structures of the peripheral nervous system. Traumatic damage to the brachial plexus is a serious medical problem, both diagnostic and therapeutic. Sensitivity to injury is mainly due to its surface position and location between two highly mobile structures such as neck and shoulder [1]. Its damage is associated with temporary or permanent motor and sensory dysfunction of the upper extremity [2]. It leads to a severe disability of the patient, often excluding him from the day-life activity [3,4]. Multi-organ damage often coexisting with brachial plexus damage can delay its clinical diagnosis and initiation of the proper management [2]. Traumatic injury to the brachial plexus can be a consequence of sudden traction of the upper extremity, damage to the skeletal structures surrounding the brachial plexus as well as the head, neck and axillary level injuries. Brachial plexus injury often coexists with large arteries damage [3,5]. Lesion to the brachial plexus can be the result of direct traumas related to sports, accidents at work and as an effect of iatrogenic injuries (mastectomy, subclavian-carotid bypass, first rib resection) [2,3,6,7]. The significant increase in motorization contributes to the rise in traffic accidents and related severe multi-organs injuries, including those in peripheral and central nervous system. It is estimated that traumatic damage to the brachial plexus is a consequence of motor-bike accidents the most frequently. It usually affects young people in the 2nd–3rd decade of life, especially men [2,3,5]. The pathomechanism of brachial plexus injury often results from the effects of significant force and tissue overloading. It leads to damage to the brachial plexus structures in the rupture mechanism, stretching, and roots avulsion from the spinal cord in severe cases [3,8]. Traumatic injury to the brachial plexus may result from the mentioned – above pathomechanisms coexisting at the same time [5]. Most often it is related to the supraclavicular part, rarely to the middle or subclavian. Therefore, the injury mostly occurs in the roots or trunks than the divisions, cords or peripheral nerves. Upper brachial plexus damage appears when the neck and head are firmly moved away from the ipsilateral shoulder [3,5,9]. The result of this mechanism is a stretch, rupture or even C5–C7 root avulsion without damage to C7–C8 cervical roots. This type of injury takes place mostly in motorcycle accidents. The lower elements of brachial plexus (C8–T1) can be injured by violently abduction and traction of the ipsilateral arm. According to Moran et al. [3], about 70–75% of injuries concern the supraclavicular region, and 75% of these injuries include an injury to the entire plexus (C5–T1). Furthermore, 20–25% of injuries involve damage to the nerve roots of C5 through C7, and 2–35% of injuries have isolated supraclavicular injury patterns to C8 and T1. Panplexal injuries usually engage a C5–C6 rupture with a C7–T1 roots avulsion. The remaining 25% of plexus injuries are subclavicular. The complexity of brachial plexus damage is often difficult to diagnose. It should be remembered that during the passage of time there can appear degenerative changes in motor end-plates causing the muscular atrophy. Hence, proper diagnosis, conservative

treatment or surgical intervention may contribute to the efficient regeneration of damaged brachial plexus structures [3,5]. The result of brachial plexus injury depends on multiple factors, and it is closely related to neural plasticity process [10–12]. The basis for the diagnosis of brachial plexus is a clinical examination [2,5,13,14] as well as clinical neurophysiology studies (ENG – electroneurography, EMG – needle electromyography, SSEP – somatosensory evoked potentials, MEP – motor evoked potentials) assessing the function of individual brachial plexus elements. The above studies are aimed at determining the etiology of brachial plexus injury, clarifying its level (proximal or distal to the Dorsal Root Ganglion – DRG), type and severity of injury (mainly using the Sunderland clinical classification) [2,5]. The use of the MEP examination in traumatic brachial plexus injury provides valuable information about the function of its proximal part. MEP study may be additional in confirming the location and extent of the lesion, considering the pathomechanism of the damage (roots avulsion, rupture, stretch). Clinical neurophysiology studies assessing the functional state of brachial plexus structures are the basis for determining the appropriate therapeutic program, including conservative or surgical treatment. The presented work is addressed to clinicians and researchers dealing primarily with the neurophysiological evaluation of patients after brachial plexus damage.

2. Clinical examination

A detailed clinical study should include assessment of the motor activity of the shoulder girdle muscles and the upper extremity, assessment of muscle strength, their atrophy and assessment of dysesthesia. It should also include determination of the other possible disorders associated with brachial plexus injuries such as Horner's syndrome indicating the sympathetic ganglion damage at the T1 root level and hyperreflexia determining injury to the upper motor neuron [3,15].

The function of the median, ulnar and radial nerves is assessed by examining the activity of the fingers and wrist. Damage to the lower part of the brachial plexus (C8–T1) leads to paralysis and atrophy of the intrinsic muscles of the hand, disturbances of fingers adduction, abduction and flexion in the phalangeal joints as well as an abnormal sensation on the medial side of the hand. Isolated injury of the middle part of the brachial plexus (C7) is quite rare, usually accompanied by damage to both the upper and lower parts of the plexus. It results in paresis of the extensors muscles of the wrist and fingers as well as the triceps muscle dysfunction. Sensation disturbances of the shoulder girdle and lateral part of the arm, as well as the atrophy of the shoulder girdle muscles, indicate damage to the upper part of the brachial plexus (C5–C6). Impairment of the scapula adduction, disorders of external rotation and shoulder abduction as well as derangement of forearm supination and elbow flexion are observed [2,15]. Clinical symptoms of brachial plexus injury presented above require confirmation in neurophysiological tests. The diagnostic algorithm is summarized in Table 1.

Table 1 – The neurophysiological diagnostic algorithm and the percentage of cervical spinal roots domain in the formation of brachial plexus structures (according to Ferrante and Wilbourn).

	CMAP		SNAP		
	Nerve	Muscle/root domain	Nerve	% participation of trunks and cords in the formation of the nerve (sensory domain)	Root domain/% participation
Superior trunk	Musculocutaneous	BB/C5,6	Lateral cutaneous nerve of the forearm	100	C6/100
	Axillary	DP/C5,6	Median – D1	100	C6/100
	Radial	EDC/C7,8	D2	20	C7/80, C6/20
			D3	10	C7/70, C6/10
Middle trunk	Radial	EDC/C7,8 TB/C7	Median – D2	80	
			D3	70	C6/100
			Radial	40	
Inferior trunk	Median	APB/T1 > C8	Ulnar – D5	100	C8/100
	Ulnar	ADM, FDI/C8, T1	Medial cutaneous nerve of the forearm	100	T1/100
	Radial	EI/C8, T1	Median – D3	20	
Lateral cord	Musculocutaneous	BB	Lateral cutaneous nerve of the forearm	100	
			Median – D1	100	
			D2	100	
			D3	80	
Posterior cord	Axillary	DP	Radial	100	
	Radial	EI, EDC			
Medial cord	Median	APB	Ulnar – D5	100	
	Ulnar	ADM, FDI	Medial cutaneous nerve of the forearm	100	
			Median – D3	20	

CMAP – compound muscle action potentials, SNAP – sensory nerve action potentials, Muscles: DP – deltoid posterior, BB – biceps brachii, TB – triceps brachii, EDC – extensor digitorum communis, EIP – extensor indicis, APB – abductor pollicis brevis, ADM – abductor digiti minimi, FDI – first dorsal interosseous, D1–5 – first to fifth digit, C5–8 – fifth to eighth cervical root level, T1 – first thoracic root level.

3. Clinical neurophysiology

Clinical neurophysiology studies confirm the functional state of structures after damage to the brachial plexus. They specify the location of the lesion, quantify the degree of axonal loss, and they are used to assess the progress of nerve fiber regeneration [2]. Standard neurophysiological tests in the evaluation of brachial plexus function are ENG of the motor and sensory fibers (NCS – nerve conduction studies), needle EMG and SSEP [15].

3.1. Nerve conduction studies

An important factor affecting the functional status of the brachial plexus and thus the result of neurophysiological research is the time between the occurrence of the damage and the first examination. According to Mansukhani [15], the amplitudes of sensory potentials decrease after five days from the damage, reaching the lowest values after just 11 days. In the case of CMAP (compound muscle action potentials) amplitudes, their abnormalities may occur from 3 to 7 days after injury. The pathological changes in muscle function appear approximately three weeks after the injury. According to Gregory et al. [2] the first NCS examinations should be

carried out up to 3–4 weeks after the injury, as the Wallerian degeneration process will end. Motor potentials show abnormalities in their parameters faster than sensory potentials. Maintaining the correct CMAP amplitude with accompanying muscle weakness at least seven days after the injury suggest neuropraxia. The value of the CMAP amplitude correlates with the severity of nerve motor fiber damage. If the difference in amplitude between the symptomatic and asymptomatic side is about 50–75%, it indicates a moderate axons loss. If it exceeds 75% or it is not recorded this indicates severe damage, classified as axonotmesis or neurotmesis respectively. A gradual increase in CMAP amplitude in subsequent studies would mean the progressive reinnervation in the muscles which CMAP is recorded from. In standard neurophysiological studies, the evaluation of the proximal part of the upper extremity nerves is based on the analysis of the F wave parameters. However, this study has its limitations, mainly due to the multi-root domain that forms the nerve assessed in this study. In addition, F wave study should be performed only with reference to the long nerves. Hence, analysis of the proximal part of the short branches of brachial plexus shows limitations. The motor potentials induced by magnetic stimulation allow for the assessment of both long and short nerves, considering the stimulation from the Erb's point as

well as the cervical root levels. Sensory potential analysis can be helpful in differentiating the level of brachial plexus injury [1,17]. If the sensory nerve action potential (SNAP) is recorded, this suggests proximal damage to the sensory neuron located in the DRG. If the SNAP amplitude is reduced or the sensory potential has not been recorded, this suggests a postganglionic plexus damage. The interpretation of the level of damage based on the analysis of SNAP should be approached with caution because the lack of sensory potential does not only determine the postganglionic damage due to the possibility of co-morbidity also at the preganglionic level. SNAP is not useful for assessing the progress of regeneration of brachial plexus structures, because it does not reach normative values even if regeneration occurs [2,3,15]. In cases of complicated, mixed lesions, both pre- and postganglionic, the pathology of the motor fibers is more expressed than the sensory ones. A reduced SNAP value with a relatively lower CMAP value suggests more the preganglionic damage. It should be noted that despite the registered SNAP, the sensory disorder according to the dermatome will occur. According to Mansukhani [15], a greater emphasis on assessing the localization of brachial plexus injury in relation to the sensory ganglion is put on SNAP analysis. He suggests that even a low SNAP amplitude (according to the SNAP domain of the roots level) with the lack of CMAP recording, indicates the preganglionic nature of the lesion. Somatosensory evoked potentials (SSEP) recorded after the median or ulnar nerve stimulation are important to confirm the complete postganglionic brachial plexus injury. Hence, SSEP recorded at the Erb's point with the lack of SSEP recorded at the cervical spine and cranial levels verify the diagnosis. Considering the above results and close anatomical position of both dorsal and ventral roots in the spinal cord it may suggest a similar extent of motor root damage as the sensory ones [15]. Table 1 presents the diagnostic algorithm including the assessment of trunks, cords and the percentage of cervical spinal roots domain in the formation of brachial plexus structures according to Ferrante and Wilbourn [1,17].

The effectors innervated by the terminal branches of brachial plexus listed in Table 1 are the essential muscles in EMG study. However, in the diagnostic recommendations [1,2,15,16], other groups of effectors are also mentioned to diagnose individual levels of the brachial plexus damage.

3.2. Needle electromyography

In the EMG study, the denervation activity can be recorded within 10–14 days from the injury. However, it will appear more frequently in proximal muscles than in the distal ones. Spontaneous activity is a sign of partial or complete denervation. The presence of motor unit's recruitment during voluntary muscle contraction accompanied by few fibrillations at rest are better prognosis than the lack of motor unit action potentials (MUAPs) and recordings of many fibrillation [3]. The EMG study identifies the first signs of regeneration after nerve damage. Initially, MUAPs are polyphasic with low amplitude as an early sign of progressive reinnervation process in the muscle. The presence of these type of potentials during voluntary contraction is the basis of distinguishing between temporary and permanent denervation. Gradual nerve regeneration affects the change in MUAPs morphology, i.e., increase

in amplitude and polyphasia. The results of EMG study will not be entirely proper after the end of reinnervation process. The MUAPs size will be still increased as well as their recruitment during the maximum contraction which compensates for muscle weakness. The presence of denervation in the cervical paraspinal muscles, serratus anterior or rhomboid muscles indicates the proximal lesion of the brachial plexus at the level of the cervical roots [2,3].

3.3. Motor evoked potentials in brachial plexus injury diagnostic

Magnetic stimulation is one of the electrophysiological methods, allowing the assessment of the function of corticospinal pathways and structures forming the lower motoneuron. It is a less painful method than stimulation with an electrical stimulus, enabling stimulation through bone structures surrounding the nervous tissue and CMAP registration from specific effectors [18,19]. There are few scientific reports pointed the effectiveness of this method in the diagnosis of brachial plexus, especially in its traumatic injury. In these cases, the complexity of damage to nerve structures, often resulting from multilevel damage, its extent and severity may additionally affect the difficulty in refining the level of damage. Available literature data on the use of magnetic stimulation in the assessment of the proximal nerve part of the upper extremity refers mostly to neurological disorders. MEP was the most commonly used in the assessment of Motor Neuron Disease (MND), Neurogenic Thoracic Outlet Syndrome (NTOS), Chronic Inflammatory Demyelinating Polyneuropathy (CIDP), Multifocal Motor Neuropathy (MMN), Guillain-Barré syndrome (GBS) and others [18,19]. General principles of application of magnetic stimulation are comparable in many scientific works; the differences concern the type of diagnostic apparatus and magnetic coils, their shape, and diameter [20,21]. Magnetic nerve root stimulation is applied slightly laterally from the spinous process on an appropriate cervical level (C5–C8). Finding the best point of stimulation (hotspot) is about generating the MEP with the shortest stable latency and maximum amplitude (maximum muscle responses) in repeated three stimulations [18,19,22]. On this basis, it is possible to precisely calculate the peripheral motor conduction time (PMCT) reflecting excitement from the proximal part of the peripheral nerves to the muscle. Transcranial magnetic stimulation allows to activate the motor cortex (M1) and calculate the conduction time from the level of the cortical latency to a certain effector. Thus, the evaluation of the central conduction time (CMCT) by subtracting PCMT from cortical latency will determine conduction in corticospinal tract [22]. Magnetic stimulation of the proximal parts of the brachial plexus is an additional method that complements the standard electrical stimulation applied at the level of the wrist, elbow, arm, axilla and the Erb's point, about the long nerves such as the ulnar nerve or median nerve. Based on the parameters of evoked potentials from the axillary level or the elbow level in comparison with the potentials recorded from the cervical root level, segmental conduc-

tion time can be calculated. In the work of Öge et al. [19], the neck–axilla segment conduction time was evaluated by subtracting the latency of CMAP induced by electrical stimulation at the level of the axilla from the latency of maximum muscle response to cervical magnetic stimulation. Similarly, the range of reduction of the amplitude and potential area elicited by the formula was analyzed [amplitude of the CMAP elicited by electrical stimulation of axilla $\times 100$]. In the opinion of Öge et al. [19], magnetic stimulation of nerve roots in the distinction of two types of damage: axonal from segmental demyelination, provides important information regarding the continuity of nerve structures and segmental demyelination. In the assessment of the axonal type of lesion or conduction block confirmation, it is of limited use due to submaximal and not supramaximal excitation of spinal roots. However, according to the authors, the comparison the amplitude of evoked potentials induced by stimulation of the cervical roots with potentials recorded distally using electrical stimulation may be helpful in revealing a possible conduction block at this level. According to Matsumoto et al. [22], the stable latency of evoked potential induced by magnetic stimulation of the cervical roots was comparable with the latency values of potentials induced by electrical stimulation using a high-voltage stimulator [23–27]. Similarly, to the opinion of other authors, they indicate the validity of combining two research techniques such as magnetic stimulation of the cervical roots and a conventional electrical technique of peripheral stimulation. The CMAP area evoked by electrical stimulation from the Erb's point is almost identical to that recorded from the cervical level using magnetic stimulation. Focal lesions between the Erb's point and neuroforamina, i.e., at the level of the brachial plexus or the level of the spinal nerves distally to the neuroforamina, can be detected by analyzing the amplitude, area and latency values of CMAP. This technique is also effective in the diagnosis of the conduction block. If the conduction block is suspected in the axilla–Erb's point segment due to the reduction of the amplitude and CMAP area, the possibility of stimulation at the proximal point, i.e., at the cervical roots level, can confirm the diagnosis. If the CMAP size after stimulation from the cervical levels is almost identical to that in Erb's point, it excludes the suspicion of submaximal stimulation at the Erb's point level. In the paper of Veltsista et al. [18], magnetic stimulation was applied on three levels: elbow level, Erb's point, and cervical spinal root level. They compared the values of CMAP parameters caused by conventional electrical stimulation and magnetic stimulation. CMAP values recorded using both stimulation methods were comparable. In their opinion, the unique possibility of magnetic stimulation to produce not weakened electrical stimulus in the depth of tissue makes this method suitable for assessing conduction along nerve roots and brachial plexus. They showed that magnetic stimulation of the cervical root was better than stimulation at the Erb's point in achieving the optimal value of CMAP parameters for screening purposes in damage to the proximal part of the brachial plexus based on the assessment of ulnar nerve

function. They also pointed that particular attention should be paid to false positive results confirming damage in the proximal nerves segments, resulting from possible submaximal stimulation at the Erb's point and resulting from the fact that no stimulation from the cervical root level was performed.

4. Conclusions

Diagnostic electrophysiological criteria in the evaluation of brachial plexus injury include ENG and EMG needle test, which are one of the most useful neurophysiological methods used in confirming the severity, pathomechanism and the level of damage [15,28]. The electrodiagnostic test results which correlate with the functional state of the assessed nerve performed promptly by diagnostic standards are valuable in planning the choice of therapeutic procedures. Motor evoked potentials are an additional diagnostic method in the assessment of brachial plexus injuries. They allow the precise evaluation of the proximal part of the brachial plexus in contrast to the F-wave study which due to the multi-root domain and possible recording only from the long nerve branches has a limited application. In the opinion of the researchers, an essential aspect of electrodiagnostic tests is the assessment using the same techniques to the asymptomatic side, where the recorded CMAP parameters become reference values in the evaluation of pathology on the symptomatic side. Depending on the capabilities and equipment of the diagnostic laboratories, stimulation with magnetic or high-voltage electrical stimulators allows for objective analysis of the function in the proximal brachial plexus. The compilation of clinical as well as a full spectrum of neurophysiology studies provide crucial information on the functional status of the brachial plexus and allows determining the nature of the damage (according to Seddon classification of nerve damage), its location and severity. They are the basis for application of the proper therapeutic procedures [29]. In cases of traumatic brachial plexus injury, conservative treatment includes physiotherapy, orthotics, and analgesia therapy. The intraoperative assessment of brachial plexus structures is critical to confirm the preoperative diagnosis based on clinical examination [30]. Surgical treatment (depending on the severity and type of damage) may include neurolysis, nerve grafting or nerve transfer. Later also peripheral reconstructions such as arthrodesis, tendon transfer, free muscle transfer or amputations can be introduced [2,5,31,32].

Treatment of a patient with brachial plexus injury is complex and requires a multidisciplinary approach to obtain the most effective results [2]. Determining the proper algorithm of the electrodiagnostic procedure allows an objective assessment of the functional status of the brachial plexus and the progress of regeneration after conservative and surgical treatment in prospective studies [1].

Conflict of interest

None declared.

Acknowledgement and financial support

None declared.

REFERENCES

- [1] Ferrante MA. Electrodiagnostic assessment of the brachial plexus. *Neurol Clin* 2012;30:551-80.
- [2] Gregory J, Cowey A, Jones M, Pickard S, Ford D. The anatomy, investigations and management of adult brachial plexus injuries. *Orthop Trauma* 2009;3(6):420-32.
- [3] Moran SL, Steinmann SP, Shin AY. Adult brachial plexus injuries: mechanism, patterns of injury, and physical diagnosis. *Hand Clin* 2005;21:13-24.
- [4] Gray B. Quality of life following traumatic brachial plexus injury: a questionnaire study. *Int J Orthop Trauma Nurs* 2016;22:29-35.
- [5] Ghany AFA, Rabie NMO, El-Shazly AAR. Brachial plexus injury: diagnosis of nerve root avulsion using multislice CT myelography. *Egypt J Neurol Psychiatry Neurosurg* 2011;48(1):63-9.
- [6] Dengler NF, Antoniadis G, Grolik B, Wirtz CR, König R, Pedro MT. Mechanisms, treatment, and patient outcome of iatrogenic injury to the brachial plexus – a retrospective single-center study. *World Neurosurg* 2017;107:868-86.
- [7] Monteiro MJ, Altman K, Khandwala A. Injury to the brachial plexus in neck dissections. *Br J Oral Maxillofac Surg* 2010;48:197-8.
- [8] Kachramanoglou C, Carlstedt T, Klotzenburg M, Choi D. Long-term outcome of brachial plexus reimplantation after complete brachial plexus avulsion injury. *World Neurosurg* 2017;103:28-36.
- [9] Soldado F, Ghizoni M, Bertelli J. Injury mechanisms in supraclavicular stretch injuries of the brachial plexus. *Hand Surg Rehabil* 2016;35:51-4.
- [10] Mohanty ChB. Central plasticity in brachial plexus injury: a neural domino effect. *World Neurosurg* 2016;86:22-4.
- [11] Simon NG, Franz CK, Gupta N, Alden T, Kliot M. Central adaptation following brachial plexus injury. *World Neurosurg* 2016;85:325-32.
- [12] Khu KJ. Neuroplasticity and brachial plexus injury. *World Neurosurg* 2015;84(6):1509-10.
- [13] Rankine JJ. Adult traumatic brachial plexus injury. *Clin Radiol* 2004;59:767-74.
- [14] Mannan K, Carlstedt T. Injuries to the brachial plexus. *Surgery* 2006;24(12):409-14.
- [15] Mansukhani KA. Electrodiagnosis in traumatic brachial plexus injury. *Ann Indian Acad Neurol* 2013;16(1):19-25.
- [16] Bell SW, Brown MJC, Hems TJ. Refinement of myotome values in the upper limb: evidence from brachial plexus injuries. *Surgeon* 2017;15:1-6.
- [17] Ferrante MA, Wilbourn AJ. The utility of various sensory nerve conduction responses in assessing brachial plexopathies. *Muscle Nerve* 1995;18:879-89.
- [18] Veltsista D, Chroni E. Usefulness of cervical root magnetic stimulation in assessing proximal motor nerve conduction. *J Electromyogr Kinesiol* 2015;25:742-8.
- [19] Öge AE, Boyacıyan A, Gürvit H, Yazici J, Değirmenci M, Kantemir E. Magnetic nerve root stimulation in two types of brachial plexus injury: segmental demyelination and axonal degeneration. *Muscle Nerve* 1997;20:823-32.
- [20] Rossini PM, Burke D, Chen R, Cohen LG, Daskalakis Z, Di Iorio R, et al. Non-invasive electrical and magnetic stimulation of the brain, spinal cord, roots and peripheral nerves: basic principles and procedures for routine clinical and research application. An updated report from an I.F.C.N. Committee. *Clin Neurophysiol* 2015;126:1071-107.
- [21] Rossi S, Hallett M, Rossini PM, Pascual-Leone A, The Safety of TMS Consensus Group. Safety, ethical considerations, and application guidelines for transcranial magnetic stimulation in clinical practice and research. *Clin Neurophysiol* 2009;120(12):2008-39.
- [22] Matsumoto H, Hanajima R, Terao Y, Ugawa Y. Magnetic-motor-root stimulation: review. *Clin Neurophysiol* 2013;124:1055-67.
- [23] Lo YL, Tan SH. Motor root block in traumatic brachial plexopathy. *J Neurol Sci* 2004;227:91-4.
- [24] Arunachalam R, Osei-Lah A, Mills KR. Transcutaneous cervical root stimulation in the diagnosis of multifocal motor neuropathy with conduction block. *J Neurol Neurosurg Psychiatry* 2003;74:1329-31.
- [25] Abbruzzese G, Dall'Agata D, Morena M, Simonetti S, Spadavecchia L, Severi P, et al. Electrical stimulation of the tracts in cervical spondylosis. *J Neurol Neurosurg Psychiatry* 1988;51:796-802.
- [26] Abbruzzese G, Morena M, Caponnetto C, Trompetto M, Abbruzzese M, Favale E. Motor evoked potentials following cervical electrical stimulation in brachial plexus lesion. *J Neurol* 1993;241:63-7.
- [27] Ugawa Y, Rothwell JC, Day BL, Thompson PD, Marsden CD. Magnetic stimulation over the spinal enlargements. *J Neurol Neurosurg Psychiatry* 1989;52:1025-32.
- [28] Ciaramitaro P, Mondelli M, Rota E, Battiston B, Sard A, Pontini I, et al., Italian Network for Traumatic Neuropathies. Electrophysiological predictors of clinical outcome in traumatic neuropathies: a multicenter prospective study. *Neurol Res Int* 2016;4619631. <http://dx.doi.org/10.1155/2016/4619631>
- [29] Shurr DG, Blair WF. Treatment of the complete brachial plexus palsy. *Iowa Orthop J* 1984;4:65-8.
- [30] Burkholder LM, Houlden DA, Midha R, Weiss E, Vennetilli M. Neurogenic motor evoked potentials: role in brachial plexus surgery. *J Neurosurg* 2003;98:607-10.
- [31] Estrella EP, Montales TD. Functioning free muscle transfer for the restoration of elbow flexion in brachial plexus injury patients. *Injury* 2016;47:2525-33.
- [32] Sakellariou VI, Badilas NK, Stavropoulos NA, Mazis G, Kotoulas HK, Kyriakopoulos S, et al. Treatment options for brachial plexus injuries. *ISRN Orthop* 2014;314137. <http://dx.doi.org/10.1155/2014/314137>