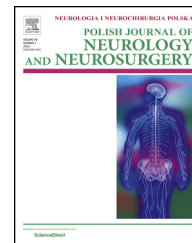


Available online at www.sciencedirect.com

ScienceDirect

journal homepage: <http://www.elsevier.com/locate/pjnns>

Review article

Bilateral carpal tunnel syndrome – A review



Pawel Dec, Andrzej Zyluk*

Department of General and Hand Surgery, Pomeranian Medical University in Szczecin, ul. Unii Lubelskiej 1, 71-252 Szczecin, Poland

ARTICLE INFO

Article history:

Received 27 July 2017

Accepted 25 September 2017

Available online 2 October 2017

Keywords:

Carpal tunnel syndrome

Bilateral manifestation

Central sensitization

ABSTRACT

Carpal tunnel syndrome (CTS) is the most common upper extremity compressive neuropathy, with a prevalence of 3%–5% in the general population, and 6% in the group of females over the age of 40. It occurs about five times more common in females, with 2 peaks observed, in the 6th and 8th decades of life. Bilateral manifestation is more common than unilateral (60%), but significantly more often begins or is more strongly expressed in the dominant hand. Possible anatomical abnormalities underlying the development of CTS account for about 5% of cases. More and more scientific data confirm the significant role of central nervous system processes (including central sensitization) in the development of carpal tunnel syndrome, and changes in central nervous system body somatotopic representation, resulting from prolonged median nerve pathology, are described in consistence with the brain plasticity concept. This central involvement of bilateral CTS may explain that a proportion of patients following surgery for one hand experience improvement also in the non-operated hand.

© 2017 Polish Neurological Society. Published by Elsevier Sp. z o.o. All rights reserved.

1. Introduction

Carpal tunnel syndrome (CTS) is the most common upper extremity compressive neuropathy, with a prevalence of 3%–5% in the general population, and 6% in the group of females over the age of 40 [1]. Women suffer 4–5 times more often than men. Age distribution is bimodal with peak morbidity at the age of between 50 and 59, and over 80 [2,3]. CTS can occur in one or both hands, although bilateral manifestation is much more frequent. Bilateral symptoms of CTS are reported to occur in 22%–87% of patients, with most studies citing a rate of approximately 60% [4].

The unilateral or bilateral compressive neuropathy of the median nerve in the carpal tunnel has been the subject of

much scientific research. The presence of these two forms of disease can be influenced by many factors, both peripheral and central, related to processes occurring within the central nervous system. The objective of this review was to determine several factors associated with bilateral manifestation of CTS: clinical characteristics of patients, possible involvement of central nervous system, causes of this manifestation and outcomes of surgery for bilateral CTS.

1.1. General clinical characteristics of patients with bilateral CTS

Bilateral CTS is approximately four times more common in females than in men, more commonly in people with body mass index over 29 and within the age range of 45–65 [5].

* Corresponding author.

E-mail addresses: pawel_dec@onet.pl (P. Dec), azyluk@hotmail.com (A. Zyluk).<http://dx.doi.org/10.1016/j.pjnns.2017.09.009>

0028-3843/© 2017 Polish Neurological Society. Published by Elsevier Sp. z o.o. All rights reserved.

The occurrence of CTS symptoms bilaterally correlates positively with the duration of the condition [6,7]. The condition is more common in the dominant hand of both right- and left-handed people [8,9]. Left-sidedness is associated with a 13-fold increase in the risk of left-side syndrome, whereas in right-handed individuals, the occurrence of right-side syndrome is five times more frequent [5]. Primary or more intensive manifestation of bilateral CTS in a majority of cases is in the dominant hand. Right-sided CTS occurs more frequently in young and female patients [5,10]. Earlier onset of symptoms on the dominant side and their increased severity are explained by the greater use of the dominant hand. The exception may be those who, as a child, learned to use a non-dominant hand in manual operations [8,11].

In nearly one-half patients with unilateral CTS, conduction abnormalities are found in contralateral median nerve electrophysiological studies despite absence of clinical signs. In most of them, the syndrome develops in the other hand in the following months or years [4,12]. Bagatur et al. analyzed a group of 131 patients after unilateral CTS surgery with a diagnosis of 66% of median nerve conduction abnormalities in the second (healthy) hand; in 73% of patients, clinical symptoms of the syndrome developed over time [7]. Electrophysiological studies have not confirmed asymmetry of nerve sensitivity thresholds with respect to the dominant hand, which could theoretically make the dominant hand more susceptible to agents causing disease symptoms [12,13].

1.2. “Sensitization” in the central nervous system (central sensitization)

The effect of unilateral peripheral nerve impairment on neurological manifestations on the opposite side is relatively well documented in experimental studies. Changes to the healthy nerve in the other limb are qualitatively similar to those found in the injured nerve limb, but are less severe and last less long. It is unclear whether this is a secondary phenomenon or a specific biological target, but the occurrence of such effects indicates the presence of complex signalling mechanisms that connect both sides of body, in particular signalling via the system of commissural interneurons that is present in the spinal cord and brainstem. More evidence is emerging indicating the role of central nervous system processes in CTS. Zanette et al. noted that one third of patients with carpal tunnel syndrome complains of symptoms in those parts of the hand outside the median nerve region, while another 1/3 report symptoms proximal to the carpal tunnel [14]. Tucker et al. reported bilateral widespread elevation of vibration thresholds in individuals with median nerve neuropathy, indicating more somatosensory disorders than isolated peripheral mononeuropathy [15].

Other authors have investigated sensitivity thresholds of patients with unilateral carpal tunnel syndrome and in healthy individuals, finding bilateral hypersensitization in patients with CTS. The authors explain this phenomenon by a process of central “sensitization” in the central nervous system. The degree of lowering the sensory threshold of touch in the healthy limb correlated significantly with the duration of symptoms and severity of pain [16]. In a similar study, decreased bilateral pain thresholds for thermal stimuli were observed in patients with unilateral CTS. Changing the

threshold of heat pain correlated negatively, whereas cold pain correlated positively regarding severity of pain and duration of symptoms. These disturbances were not accompanied by a change in ability to distinguish temperature changes [17]. The same authors observed a significantly weaker pinch-grip in both hands (as compared to the average in the population) in a group of women with unilateral CTS [18]. Schmid et al. evaluated the ability to distinguish between body sides by presentation of hands and feet symbols and specific Shepard–Metzler figures. In patients with unilateral CTS, impairment of hand image recognition was observed, with proper identification of foot images or spatial geometric figures [19]. A similar selective impairment of body part recognition was described in patients with diseases in which the role of central mechanisms is broadly accepted as Sudeck syndrome or limb amputation phantom pain.

1.3. Topographic reorganization of the body image in the central nervous system

Topographic reorganization of the body schema in the central nervous system within sensory and motor cerebral structures at the level of primary cortical centres observed in carpal tunnel syndrome may explain the limitation in the ability to identify the image of the afflicted site [19]. This phenomenon was studied with the help of functional magnetic resonance imaging (MRI), where asymmetrical distortion of body diagram in posterior areas of parietal cortex was observed in patients with unilateral CTS on the side opposite to afflicted limb.

There were no differences in the extent of these distortions with respect to the dominant hand [20]. Fornander et al. analyzed the effect of traumatic median nerve damage at carpal level on spatial activation of the primary cortical centres in functional MRI. Compared to the healthy control group, patients who had median nerve damage presented a more intensive activation of the cerebral cortex on the afflicted side. The increase in activity of primary cerebral cortical centres is associated with interhemispheric inhibition connected with afferent impulsation in the primary cortex on the opposite side [21]. In carpal tunnel syndrome, where paraesthesia is the dominant symptom, MRI observed pre- and postcentral gyri cortex thinning on the side opposite to the afflicted hand. This phenomenon does not occur in those forms of the syndrome where the dominant symptom is pain.

Thickness of the precentral gyrus is inversely proportional to the severity of paraesthesia. The dominance of paraesthesia in the clinical picture is also positively correlated with lower velocities of median nerve conduction [22]. In view of these observations, it is suggested that in the groups of patients with neuropathic compression of the median nerve with predominant pain and paraesthesia, the processes of conduction and transmission of pain and CNS sensation are carried out by slightly different mechanisms. Probably, the distortion of cortical representation by shifting nerve region by the median nerve is a brain defence response that allows sensory perception despite the absence or weakening of the peripheral impulsation due to nerve damage [23].

Similar somatotopic reorganizations are observed in the total absence of afferent impulsation at amputation, temporal pharmacological analgesia, or partial functional impairment,

as it is in carpal tunnel syndrome. Following magnetic electroencephalography (EEG), after separate electrical stimulation of the median nerve and fingers I, III and V, it was found that original abnormal afferent impulsation was capable of distorting cortical hand representation.

With the duration of compression and impaired impulsation, the topographic cortical representation of the area of the median nerve is occupied by representation of finger V, from which sensory stimuli are carried by the ulnar nerve and the radial nerve. In similar studies, overlapping, blurring and variable distances between cortical representations of fingers I–III in carpal tunnel syndrome were observed, compared to control groups [24]. An inversely proportional relationship was observed between shortening of the distance between the second and third finger in primary somatosensory cortex and intensification of paraesthesia in CTS [25]. Blurring and distortion of median nerve representation resulting from prolonged paraesthesia is part of the concept of cerebral cortex plasticity proposed by Hebb et al. [26].

1.4. Genetic factors

The more frequent occurrence of bilateral than unilateral CTS raises the question of whether or not the disease has its origin in hereditary genetic mechanisms. Most often, analysis of genealogy indicates an autosomal dominant transmission of bilateral syndrome, of variable expression and limited penetration [27–29]. The family history of bilateral CTS is characterized by early onset of symptoms and no gender differences in distribution. It has not been possible to identify any gene that can directly be related to this phenomenon [30–32]. Despite initial enthusiasm for molecular markers, the genetic significance of any of the collagen gene polymorphism variants (including COL1A1 and COL5A1), matrix metalloproteinases, interleukins (IL1beta, IL-2, IL-6 and IL-6 receptor) growth factors (including vascular endothelial growth factor – VEGF), which may theoretically account for disturbance of the connective tissue architecture within the carpal tunnel, has not been proved [2,33–35]. There is also no association of CTS with polymorphism of major histocompatibility factors [36]. Analysis of serum levels of TNF alpha cytokines, interleukins 1, 2 and 6, and primary derivative of arachidonic acid pathway, including prostaglandin PGE2, indicates a local ischaemia-reperfusion rather than an inflammation process in the pathophysiology of CTS [37].

1.5. Anatomical anomalies in carpal tunnel which may cause bilateral manifestation

CTS can be caused by additional structures located in the carpal tunnel. Some of them may be related to congenital anatomical anomalies, such as atypical variants of palmaris longus tendon (reversed, duplicated), bifid or trifid median nerve (high nerve division), persistent median artery, congenital pisohamate coalition, anastomosis between the recurrent branch of the median nerve and the deep branch of the ulnar nerve or anomalies of belly or tendon flexor digitorum superficialis. These changes, occurring on both sides, can cause bilateral CTS. Some of additional intracarpal masses are result of systemic diseases such as rheumatoid disease (granuloma), gout (deposits) or haemophilia (organized hae-

matomas) [38–40]. These forms should be separated from the purely idiopathic bilateral ones, as they are caused by relevant anatomical or pathological structures occupying space in both carpal tunnels. Data from the literature show that anatomical anomalies in the carpal tunnel causing the condition are reported only in fewer than 5% of patients [37].

1.6. The impact of the decompression of the carpal tunnel on the non-operated hand

There are limited studies evaluating the effect of unilateral median nerve decompression on the contralateral hand in bilateral carpal tunnel syndrome. Unno et al. assessed the results in a group of 69 patients with bilateral CTS who were operated due to more severe symptoms in one of hands. At 6 months follow-up, 63 patients (91%) declared cessation of nocturnal symptoms and 47 (75%) regression of paraesthesia in the non-operated hand. Only 4 patients (6%) did not notice any improvement in the other hand. No significant effect of gender, age, duration of symptoms or electrophysiological severity on this phenomenon was noted [41]. Yoon et al. observed for about 3 years a group of 20 patients with clinically and electrophysiologically confirmed bilateral CTS. During the study, 15 patients (75%) reported improvement on the side opposite to the operated one, five of whom considered the improvement significant [42]. In another study, 58% of patients with bilateral CTS reported improvement or regression of symptoms in the unoperated hand [43]. Results of these studies show that bilateral carpal tunnel syndrome may be more complex disorder than peripheral neuropathy and beneficial effect of unilateral carpal tunnel release on the other hand may be expected in a proportion of patients.

In summary, this review shows that bilateral carpal tunnel syndrome is not a simple peripheral mononeuropathy of both median nerves but complex disorder with possible involvement of central mechanisms, genetic factors and anatomic anomalies. The actual effect of these factors on the clinical profile of the disease and treatment outcomes is not clearly defined, but it seems likely to be significant, i.e. in aspect of beneficial effect of surgery for one wrist on the other one. Although the knowledge on this topic does not still translate into practice, in terms of changes in diagnosing and management of bilateral syndrome, this problem is undoubtedly worth of further investigation.

Conflict of interest

None declared.

Acknowledgement and financial support

None declared.

REFERENCES

- [1] Atroshi I, Gummesson C, Johnsson R, Ornstein E, Ranstam J, Rosen I. Prevalence of carpal tunnel syndrome in a general population. *JAMA* 1999;282:153–8.

- [2] Bland JD, Rudolfer SM. Clinical surveillance of carpal tunnel syndrome in two areas of the United Kingdom, 1991–2001. *J Neurol Neurosurg Psychiatry* 2003;74:1674–9.
- [3] Mondelli M, Giannini F, Giacchi M. Carpal tunnel syndrome incidence in a general population. *Neurology* 2002;580:289–94.
- [4] Padua L, Padua R, Nazzaro M, Tonali P. Incidence of bilateral symptoms in carpal tunnel syndrome. *J Hand Surg* 1998;23B:603–6.
- [5] Zambelis T, Tsivgoulis G, Karandreas N. Carpal tunnel syndrome: associations between risk factors and laterality. *Eur Neurol* 2010;63:43–7.
- [6] Szabo RM, Slater Jr RR, Farver TB, Stanton DB, Sharman WK. The value of diagnostic testing in carpal tunnel syndrome. *J Hand Surg* 1999;24A:704–14.
- [7] Bagatur AE, Zorer G. The carpal tunnel syndrome is a bilateral disorder. *J Bone Joint Surg* 2001;83B:655–8.
- [8] Reinstein L. Hand dominance in carpal tunnel syndrome. *Arch Phys Med Rehabil* 1981;62:202–203.
- [9] Shiri R, Varonen H, Heliövaara M, Viikari-Juntura E. Hand dominance in upper extremity musculoskeletal disorders. *J Rheumatol* 2007;34:1076–82.
- [10] Redmond MD, Rivner MH. False positive electrodiagnostic tests in carpal tunnel syndrome. *Muscle Nerve* 1988;11:511–8.
- [11] Kucera JD, Robins TG. Relationship of cumulative trauma disorders of the upper extremity to degree of hand preference. *J Occup Med* 1989;31(January (1)):17–22.
- [12] Tsuji Y, Noto Y, Shiga K, Yokota I, Nakagawa M, Mizuno T. Does hand dominance affect peripheral nerve excitability? *Clin Neurophysiol* 2016;127(April (4)):1921–2.
- [13] de la Llave-Rincón AI, Fernández-de-las-Peñas C, Laguarda-Val S, Alonso-Blanco C, Martínez-Perez A, Arendt-Nielsen L, et al. Increased pain sensitivity is not associated with electrodiagnostic findings in women with carpal tunnel syndrome. *Clin J Pain* 2011;27(November–December (9)):747–54.
- [14] Zanette G, Cacciatori C, Tamburin S. Central sensitization in carpal tunnel syndrome with extraterritorial spread of sensory symptoms. *Pain* 2010;148(February (2)):227–36.
- [15] Tucker AT, White PD, Kosek E, Pearson RM, Henderson M, Coldrick AR, et al. Comparison of vibration perception thresholds in individuals with diffuse upper limb pain and carpal tunnel syndrome. *Pain* 2007;127(February (3)):263–9.
- [16] Fernández-de-las-Peñas C, de la Llave-Rincón AI, Fernández-Carnero J, Cuadrado ML, Arendt-Nielsen L, Pareja JA. Bilateral widespread mechanical pain sensitivity in carpal tunnel syndrome: evidence of central processing in unilateral neuropathy. *Brain* 2009;132(June Pt 6):1472–9.
- [17] de la Llave-Rincón AI, Fernández-de-las-Peñas C, Fernández-Carnero J, Padua L, Arendt-Nielsen L, Pareja JA. Bilateral hand/wrist heat and cold hyperalgesia, but not hypoesthesia, in unilateral carpal tunnel syndrome. *Exp Brain Res* 2009;198(October (4)):455–63.
- [18] de la Llave-Rincón AI, Fernández-de-las-Peñas C, Pérez-de-Heredia-Torres M, Martínez-Perez A, Valenza MC, Pareja JA. Bilateral deficits in fine motor control and pinch grip force are not associated with electrodiagnostic findings in women with carpal tunnel syndrome. *Am J Phys Med Rehabil* 2011;90(June (6)):443–51.
- [19] Schmid AB, Coppiters MW. Left/right judgment of body parts is selectively impaired in patients with unilateral carpal tunnel syndrome. *Clin J Pain* 2012;28(September (7)):615–22.
- [20] Mellet E, Mazoyer B, Leroux G, Joliot M, Tzourio-Mazoyer N. Cortical asymmetries during hand laterality task vary with hand laterality: a fMRI study in 295 participants. *Front Hum Neurosci* 2016;December (10):628.
- [21] Fornander L, Nyman T, Hansson T, Brismar T, Engström M. Inter-hemispheric plasticity in patients with median nerve injury. *Neurosci Lett* 2016;August (628):59–66.
- [22] Maeda Y, Kettner N, Kim J, Kim H, Cina S, Malatesta C, et al. Primary somatosensory/motor cortical thickness distinguishes paresthesia-dominant from pain-dominant carpal tunnel syndrome. *Pain* 2016;157(May (5)):1085–93.
- [23] Tecchio F, Padua L, Aprile I, Rossini PM. Carpal tunnel syndrome modifies sensory hand cortical somatotopy: a MEG study. *Hum Brain Mapp* 2002;17(September (1)):28–36.
- [24] Dhond RP, Ruzich E, Witzel T, Maeda Y, Malatesta C, Morse LR, et al. Spatio-temporal mapping cortical neuroplasticity in carpal tunnel syndrome. *Brain* 2012;135(October Pt 10):3062–73.
- [25] Maeda Y, Kettner N, Holden J, Lee J, Kim J, Cina S, et al. Functional deficits in carpal tunnel syndrome reflect reorganization of primary somatosensory cortex. *Brain* 2014;137(June Pt 6):1741–52.
- [26] Hebb D. The organization of behaviour: a neuropsychological theory. Wiley; 1949.
- [27] Michaud LJ, Hays RM, Dudgeon BJ, Kropp RJ. Congenital carpal tunnel syndrome: case report of autosomal dominant inheritance and review of the literature. *Arch Phys Med Rehabil* 1990;71(May (6)):430–2.
- [28] Sparkes RS, Spence MA, Gottlieb NL, Gray RG, Crist M, Sparkes MC, et al. Genetic linkage analysis of the carpal tunnel syndrome. *Hum Hered* 1985;35(5):288–91.
- [29] Gray RG, Poppo MJ, Gottlieb NL. Primary familial bilateral carpal tunnel syndrome. *Ann Intern Med* 1979;91(July (1)):37–40.
- [30] Gossett JG, Chance PF. Is there a familial carpal tunnel syndrome? An evaluation and literature review. *Muscle Nerve* 1998;21(November (11)):1533–6.
- [31] Mochizuki Y, Ohkubo H, Motomura T. Familial bilateral carpal tunnel syndrome. *J Neurol Neurosurg Psychiatry* 1981;44(April (4)):367.
- [32] Senel S, Ceylaner G, Yuksel D, Erkek N, Karacan C. Familial primary carpal tunnel syndrome with possible skipped generation. *Eur J Pediatr* 2010;169(April (4)):453–5.
- [33] Fedorczyk JM, Barr AE, Rani S, Gao HG, Amin M, Amin S, et al. Exposure-dependent increases in IL-1beta, substance P, CTGF, and tendinosis in flexor digitorum tendons with upper extremity repetitive strain injury. *J Orthop Res* 2010;28(March (3)):298–307.
- [34] Burger MC, de Wet H, Collins M. Interleukin and growth factor gene variants and risk of carpal tunnel syndrome. *Gene* 2015;564(June (1)):67–72.
- [35] Burger MC, De Wet H, Collins M. Matrix metalloproteinase genes on chromosome 11q22 and risk of carpal tunnel syndrome. *Rheumatol Int* 2016;36(March (3)):413–9.
- [36] Vanwijck R, Boullenne C. HL-A and carpal tunnel syndrome. *Clin Rheumatol* 1986;5(September (3)):379–81.
- [37] Nakamichi K, Tachibana S. Unilateral carpal tunnel syndrome and space-occupying lesions. *J Hand Surg Br* 1993;18(December (6)):748–9.
- [38] Iyengar K, Manickavasagar T, Nadkarni J, Mansour P, Loh W. Bilateral recurrent wrist flexor tenosynovitis and rice body formation in a patient with sero-negative rheumatoid arthritis: a case report and review of literature. *Int J Surg Case Rep* 2011;2(7):208–11.
- [39] Tsai CY, Yu CL, Tsai ST. Bilateral carpal tunnel syndrome secondary to tophaceous compression of the median nerves. *Scand J Rheumatol* 1996;25(2):107–8.
- [40] Molitor PJ, Wimperis JZ. Acute carpal tunnel syndrome in haemophiliacs. *Br J Clin Pract* 1990;44(December (12)):675–6.
- [41] Unno F, Lucchina S, Bosson D, Fusetti C. Immediate and durable clinical improvement in the non-operated hand

-
- after contralateral surgery for patients with bilateral Carpal Tunnel Syndrome. *Hand (NY)* 2015;10(September (3)):381–7.
- [42] Yoon ES, Kwon HK, Lee HJ, Ahn DS. The outcome of the nonoperated contralateral hand in carpal tunnel syndrome. *Ann Plast Surg* 2001;47(July (1)):20–4.
- [43] Burton CL, Chesterton LS, Chen Y, van der Windt DA. Clinical course and prognostic factors in conservatively managed carpal tunnel syndrome: a systematic review. *Arch Phys Med Rehabil* 2016;97(May (5)):836–52.