

## Early stage adenoid cystic carcinoma of the posterior nasal septum: a rare manifestation

Asmaa Kouadir<sup>1</sup>, Khalid Hassouni<sup>1,2</sup>

Adenoid cystic carcinomas are rare malignant tumors that commonly arise from major and minor salivary glands and are characterized by slow growth, frequent local recurrences, and high incidence of distant metastasis, especially reported in patients with advanced stage tumors. Adenoid cystic carcinomas can rarely occur in other areas of the head and neck region, notably in the nasal cavity. Moreover, adenoid cystic carcinoma limited to the nasal septum is particularly unusual and has been the subject of a small number of published cases only. We discuss here a case of a 42 year-old woman diagnosed with early stage adenoid cystic carcinoma of the posterior nasal septum, treated solely with surgical resection via endoscopic approach. During five years of follow-up, no local recurrence or distant metastasis has been detected.

Biuletyn PTO NOWOTWORY 2018; 3, 1: 34–38

**Key words:** adenoid cystic carcinoma, nasal cavity, nasal septum

### Introduction

Adenoid cystic carcinomas (ACC), first described by Robin and Laboulbène in 1853, are rare and account for less than 1% of all head and neck malignancies. They commonly arise within salivary glands and are characterized by slow growth, low probability of lymphatic spread, frequent local recurrences, and high incidence of distant metastasis (DM), which is even reported in patients with early stage tumors [1–3]. In the sinonasal tract, ACC accounts for 10–25% of all head and neck ACCs [4]. However, in the nasal septum this tumor is exceedingly rare. Actually, to date only few cases of ACC arising from the nasal septum have been reported in the literature [5]. Here we discuss a new case of unusual presentation of ACC of the nasal septum.

### Case report

A 42 year-old Moroccan married woman with no past personal history of disease or surgery and non-contributory

family history, showed up at the Ear, Nose, & Throat (ENT) department with a complaint of occasional epistaxis associated with nasal obstruction, over one year period. Nasal endoscopy revealed well defined, polypoid mass in the posterior part of the left side of nasal cavity. Neck clinical examination revealed no abnormalities of cervical lymph nodes.

A biopsy of the lesion was performed and fragmented tissue biopsies were histologically investigated. Histopathological examination revealed a tumor proliferation composed of a double contingent of malignant cells. Actually, it was composed of epithelial and myoepithelial cells with moderate cytonuclear atypia and hyperchromatic nuclei, and clear cytoplasm. Tumor cells were arranged in tubular and cribriform architectural patterns (Fig. 1). The tubular lumens were filled with mucoid material. All these structures were supported by a thin fibrous stroma. In immunohistochemistry, myoepithelial cells expressed Smooth Muscle Actin (SMA)

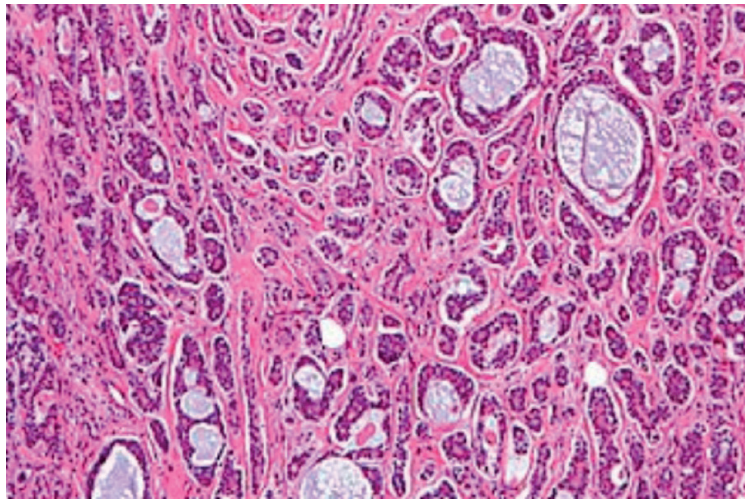
<sup>1</sup>Department of Radiotherapy, Hassan II University Hospital, Fez, Morocco

<sup>2</sup>Faculty of Medicine and Pharmacy of Fez, Sidi Mohamed Ben Abdellah University, Fez, Morocco

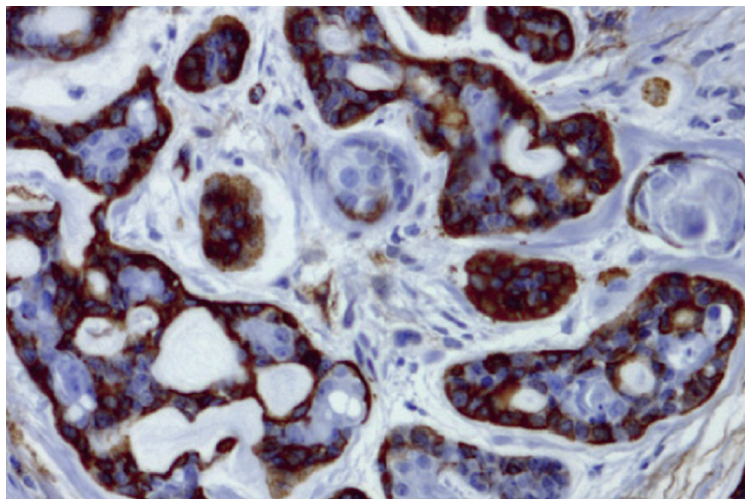
#### Artykuł w wersji pierwotnej:

Kouadir A, Hassouni K. Early stage adenoid cystic carcinoma of the posterior nasal septum: a rare manifestation. *NOWOTWORY J Oncol* 2018; 68: 33–37.

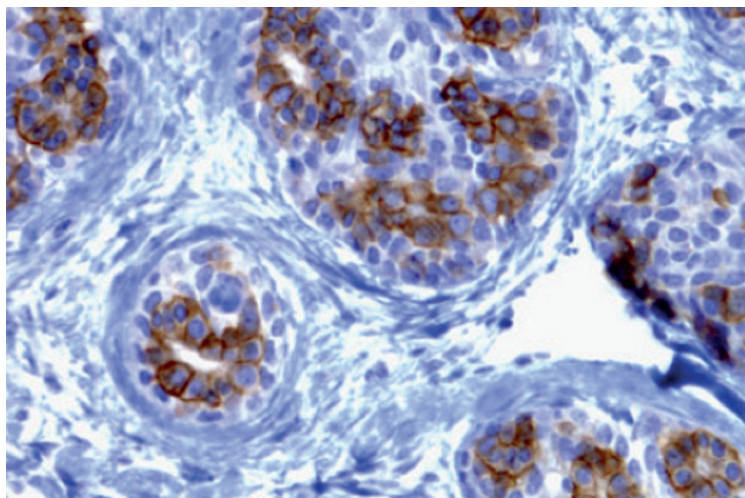
Należy cytować wersję pierwotną.



**Figure 1.** Picture showing adenoid cystic carcinoma exhibiting cribriform and tubular patterns (Hematoxylineosin staining  $\times 200$ )



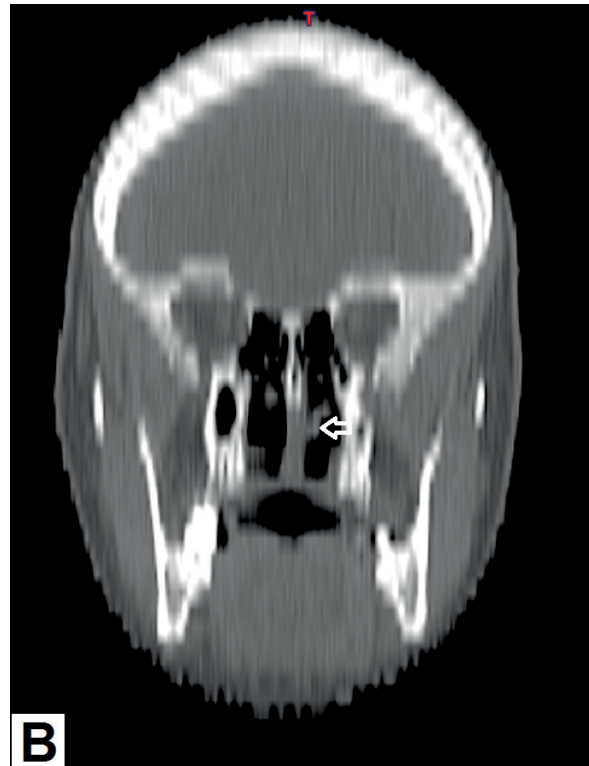
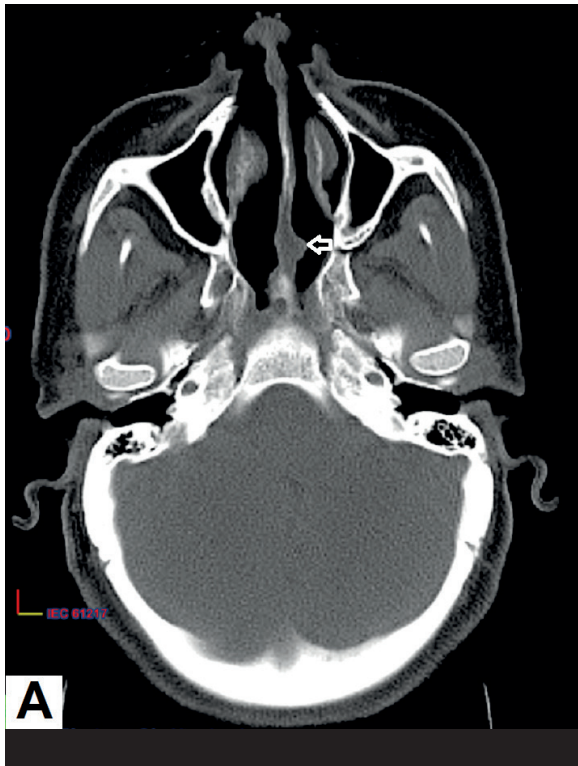
**Figure 2.** In immunohistochemistry, Adenoid cystic carcinoma showed an immunostaining with antibodies against smooth muscle actin ( $\times 400$ )



**Figure 3.** Adenoid cystic carcinoma showed an immunostaining with antibodies against CD117 ( $\times 400$ )

(Fig. 2), whereas epithelial cells were positively immunostained for c-Kit (CD117) (Fig. 3). Based on these data, the diagnosis of ACC has been established.

Computed tomography (CT) of the paranasal sinuses (PNS) subsequently performed, confirmed the findings of a  $17.1 \times 13.8$  mm soft tissue mass arising from the poste-



**Figure 4.** Axial (A) and frontal (B) CT images showing a soft-tissue mass arising from the posterior part of the left side of nasal septum (white arrow)

rior part of the nasal septum with no sign of locoregional invasion (Fig. 4). Computed tomography CT scan of the neck showed no lymph node involvement. The results of metastatic workup, including chest X-ray and abdominal ultrasound exam were negative. Thus, the tumor was classified as T1N0M0 corresponding to stage I of the staging of carcinoma of the nasal cavity, ethmoid and maxillary sinus according to the 7th edition of the American Joint Committee on Cancer (AJCC) Cancer Staging Manual.

The patient underwent an endoscopic resection which removed the tumor en-bloc along with adjacent bony septum and a cuff of cartilaginous septum. The surgery and the early post-operative period were uneventful. Histopathological examination of the operative specimen showed an ACC infiltrating the adjacent bone, whereas the cartilage was found free of tumor. On the other hand, there was no perineural invasion and negative surgical margins were confirmed.

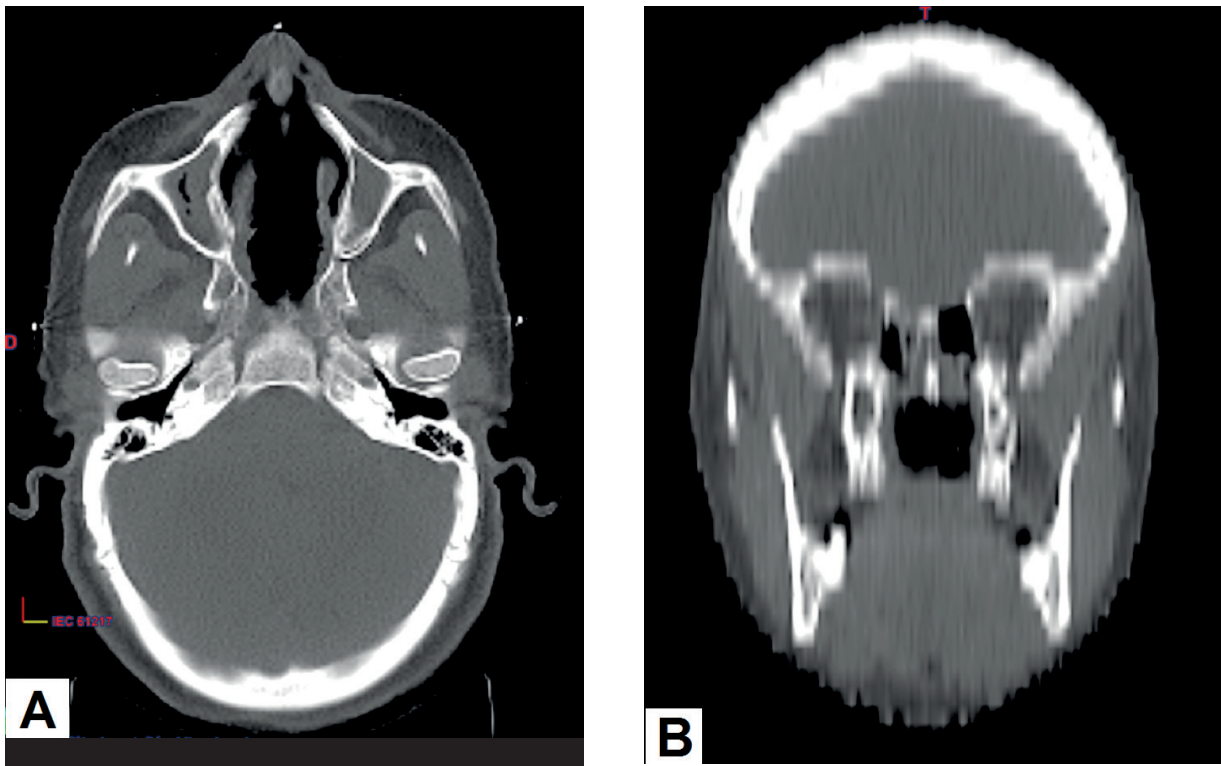
The case was discussed at multidisciplinary consultation meeting (RCP), and the RCP decision was to initiate adjuvant radiotherapy. Unfortunately, the patient has been lost sight of for nine months after surgery. When she showed up at our department, new clinical and radiological examinations (CT scans) were performed and showed no evidence of recurrence (Fig. 5). After discussion between radiation therapists, adjuvant radiotherapy was deemed to be non-beneficial after nine months from surgery. Thus, no adjuvant therapy

was performed and the patient was kept on a close follow-up schedule, with clinical examinations every three months, and CT scans of the PNS and the neck as well as the chest and the abdomen CT scans every year. Five years after surgery, the patient is still disease-free.

## Discussion

The incidence of malignant tumors of the nasal septum is very low, comprising 2.7–8.4% of nasal and paranasal malignant tumors [5]. Although ACC is the second most common cancer occurring in the sinonasal tract and usually invades the lateral wall of the nose, its location in the nasal septum remains exceedingly scarce, as it has been shown in two older clinical reports. Actually, among 43 malignant tumors of the nasal septum included in Young study, there has been only one case of ACC. The same remark was reported in Beatty et al. study, where one single case of ACC was found amongst 85 nasal septum carcinomas [6–9]. Furthermore, very few cases of ACC of the posterior nasal septum are encountered in the literature [7, 10, 11].

According to a recent meta-analysis, the median age of patients with ACC of the nasal cavity and paranasal sinuses was 50 years (range, 38 to 55 years) with slight predominance in females [12]. Due to the rarity of these tumors, there is little data on whether specific ethnic, geographic, exposure, or other factors predispose to the development of the disease [13].



**Figure 5.** Axial (A) and frontal (B) images from PNS CT scan performed 9 months after surgery showing no evidence of recurrence

The most common presentation of ACC is an asymptomatic slowly enlarging mass, often in the head and neck area [13]. However, ACC of the nasal cavity may manifest through obstruction, epistaxis, discharge and facial swelling [5, 7, 10]. Pain or paresthesia may also be reported and likely reflect the tumor's propensity for perineural infiltration [13]. Although advanced ACC arising from the sinonasal tract is believed to be common at initial evaluation, early detection of nasal septum ACC may be possible because symptoms may appear early in the disease [7], such was the case with our patient.

Regarding diagnostic imaging techniques, both imaging modalities (CT and MRI) are very valuable for evaluation of the tumor features as well as its extension. In fact, low grade ACC of the sinonasal tract may mimic the features of a simple polyp filling the nasal cavity and slightly remodeling the bones at both CT and MR imaging, whereas high grade ACC may manifest as a large irregular mass with bone destruction and irregular density and signal at both CT and MR imaging. Moreover, ACC is also well known for its predisposition to perineural spread along the cranial nerves that can extend into the skull base. Hence, MR imaging with intravenous contrast injection is mandatory, in order to map this perineural spread. On the other hand, the value of [ $^{18}\text{F}$ ] FDG-PET/CT in ACC is limited due to low metabolic activity and therefore low FDG uptake [14].

Histologically, ACCs exhibit varying proportions of three distinct growth patterns that are referred to as cribriform, tubular, and solid [13]. These tumors can be graded histologically according to Szanto et al. into three grades, based on the proportion of solid pattern: Grade 1 where solid pattern = 0%, Grade 2 where solid pattern < 30% and Grade 3 where solid pattern > 30% [15]. Patients with solid type ACC have the worst prognosis [7,13]. The cribriform pattern is the most common histologic subtype and all septal ACC previously reported was the cribriform pattern [5, 7, 10, 11]. In our case, only cribriform and tubular patterns were exhibited, thus the case was classified as grade 1 ACC. Furthermore, immunohistochemistry remains often necessary for ACC diagnosis. In fact, myoepithelial tumor cells that surround the pseudocysts stain positively for smooth muscle actin (SMA), S100, vimentin, and smooth muscle myosin heavy chain. Also, ACC cells are strongly positive for the receptor tyrosine kinase c-KIT (CD117) and myeloblastosis oncogene (MYB) regardless of grade [13].

In terms of treatment, ACC of the nasal cavity and paranasal sinuses poses numerous treatment challenges for many reasons, inter alia, its high propensity for local invasion to adjacent structures, making resection more difficult. However, surgery remains the mainstay of treatment of these tumors [12]. Recently, some authors deem that surgical resection of ACC of the sinonasal tract via endoscopic approach could be an effective mini-invasive method that

in well-selected patients could be satisfactorily applied, together with adjuvant therapies, giving good results, complete removal of a tumor and high surviving rate [3]. On the other hand, ACC is considered to be a radiosensitive but not radio-curable tumor. Hence, postoperative radiation therapy aims to treat residual microscopic disease, which is present in most patients [7]. Nevertheless, data obtained from the US National Cancer Institute's Surveillance, Epidemiology, and End Results (SEER) program by Ellington et al. show little to no clear benefit of adjuvant radiotherapy for ACC of head and neck [2]. Moreover, many ACC tumors do not benefit from systemic chemotherapy, as they have slow growth kinetics. However, several chemotherapy studies have been performed over the years. The results show consistently low response rates to cytotoxic chemotherapy for metastatic disease. Thus, to date, there is no accepted standard systemic chemotherapy for patients with ACC tumors. Regarding targeted therapies, the elucidation of the genetic basis of ACCs has identified novel candidate therapeutic targets inter alia, the MYB oncoprotein which is the most promising. However, targeted agents are early in development for ACC and care should be taken when using them off-trial [13].

Due to its rarity, there is some controversy over the clinical and histological factors that affect the survival of patients with ACC of the sinonasal tract. If the impact of the type and grade of tumor on survival is agreed by all authors, perineural invasion, efficacy of adjuvant treatment, and the site of origin were found to be significant prognostic factors by some authors, whereas others found that they had no impact on survival [2, 12, 13]. Actually, a recent meta-analysis of Amit et al. revealed that margin status and tumor site were significant predictors of outcome in patients with ACC of the nasal cavity and paranasal sinuses, whereas perineural invasion was not associated with prognosis. In addition, no added benefit of adjuvant treatment has been noticed [12].

Finally, due to the possibility of delayed recurrences and DM, long-term surveillance is currently required for patients with ACC [1, 2, 13].

## Conclusion

Adenoid cystic carcinomas of the nasal cavity are a rare clinical entity which continues to pose diagnostic and therapeutic challenges to physicians. They usually involve the lateral wall of the nose. Their involvement of the posterior nasal septum is extremely rare. Despite their rarity, they should

be taken into consideration in the differential diagnosis of a nasal tumor. Moreover, the most effective treatment modality and prognosis risk factors of these tumors are still under debate. Delayed recurrences and DM require long-term follow-up for patients with such tumors.

**Conflict of interest:** none declared

**Asmaa Kouadir, MD, PhD**

Hassan II University Hospital

Department of Radiotherapy

Avenue Hassan II, Fez, Morocco

e-mail: kouadirasmaa@gmail.com

Received: 2 Mar 2018

Accepted: 18 Apr 2018

## References

1. Bhayani MK, Yener M, El-Naggar A et al. Prognosis and risk factors for early-stage adenoid cystic carcinoma of the major salivary glands. *Cancer* 2012; 118: 2872–2878.
2. Ellington CL, Goodman M, Kono SA et al. Adenoid cystic carcinoma of the head and neck: Incidence and survival trends based on 1973–2007 surveillance, epidemiology, and end results data. *Cancer* 2012; 118: 4444–4451.
3. Wardas P, Tymowski M, Piotrowska-Seweryn A et al. Endoscopic approach to the resection of adenoid cystic carcinoma of paranasal sinuses and nasal cavity: case report and own experience. *Eur J Med Res* 2015; 20: 97. doi: 10.1186/s40001-015-0189-2.
4. Purushothaman PK, Ramakrishnan R, Sindhu P. Adenoid cystic carcinoma of nasal cavity: a rare presentation case report. *Int J Sci Res Publ* 2015; 5(2).
5. Tai SY, Chien CY, Tai CF et al. Nasal septum adenoid cystic carcinoma: A case report. *Kaohsiung J Med Sci* 2007; 23: 426–430.
6. Shirazi N, Bist SS, Selvi TN et al. Spectrum of sinonasal tumors: a 10-year experience at a tertiary care hospital in North India. *Oman Med J* 2015; 30: 435–440.
7. Akiyama K, Karaki M, Hosikawa H et al. A massive adenoid cystic carcinoma of nasal septum progressed into the skull base. *Auris Nasus Larynx* 2013; 40: 239–242.
8. Young JR. Malignant tumors of the nasal septum. *J Laryngol Otol* 1979; 93: 817–832.
9. Beatty CW, Pearson BW, Kern EB. Carcinoma of the nasal septum, experience with 85 cases. *Otolaryngol Head Neck Surg* 1982; 90: 90–94.
10. Schneiderman TA, Chaudhury SI. Adenoid cystic carcinoma of the nasal septum. *Otolaryngol Head Neck Surg* 2002; 127: 251–252.
11. Belaldavar BP, Batra R. Adenoid cystic carcinoma of the nasal septum: a rare case report. *J Sci Soc* 2013; 40: 39–40.
12. Amit M, Binenbaum Y, Sharma K et al. Adenoid cystic carcinoma of the nasal cavity and paranasal sinuses: a meta-analysis. *J Neurol Surg B Skull Base* 2013; 74: 118–125.
13. Dillon PM, Chakraborty S, Moskaluk CA et al. Adenoid cystic carcinoma: A review of recent advances, molecular targets, and clinical trials. *Head Neck* 2016; 38: 620–627.
14. Eggesbø HB. Imaging of sinonasal tumours. *Cancer Imaging* 2012; 12: 136–152.
15. Szanto PA, Luna MA, Tortoledo ME et al. Histologic grading of adenoid cystic carcinoma of the salivary glands. *Cancer* 1984; 54: 1062–1069.