

# Spontaneous rupture of unscarred uterus in the early second trimester: a case report of placenta percreta

Przerastające łożysko jako przyczyna samoistnego pęknięcia macicy we wczesnym drugim trymestrze u wieloródki bez wywiadu zabiegów na macicy

Pierzynski Piotr<sup>1</sup>, Laudanski Piotr<sup>2</sup>, Lemancewicz Adam<sup>2</sup>,  
Sulkowski Stanislaw<sup>3</sup>, Laudanski Tadeusz<sup>2</sup>

<sup>1</sup> Department of Reproductive Medicine and Gynaecological Endocrinology, Medical University of Białystok, Poland

<sup>2</sup> Department of Perinatology, Medical University of Białystok, Poland

<sup>3</sup> Department of General Pathomorphology, Medical University of Białystok, Poland

## Abstract

**Background:** Prevalence of uterine rupture at delivery has been recently estimated at less than 1 in 2500 deliveries. Spontaneous uterine rupture in the early mid-trimester (16 weeks gestation or less), is far less frequent. We report a case of uterine rupture due to placenta percreta in otherwise uncomplicated pregnancy.

**Case:** A 35-year-old, gravida 5, para 5, at 15wk 2d gestation (menstrual age) with negative history of uterine scarring suddenly developed symptoms of incipient hypovolemic shock while being hospitalized for imminent miscarriage. On exploratory laparotomy we found a midline uterine rupture infiltrated by the placenta. Supracervical hysterectomy was performed. Postoperative lab analysis confirmed the elevated serum AFP levels.

**Conclusion:** Abnormal placentation and subsequent uterine rupture should be taken into consideration also in women in the second trimester who have no history of uterine instrumentation.

Key words: **placenta percreta / uterine rupture / second trimester /**

## Streszczenie

Częstość występowania okołoporodowego pęknięcia macicy szacuje się na 1 na 2500 porodów, powikłanie to występuje zwykle po rozpoczęciu porodowej czynności skurczowej. Jedną z przyczyn tego nagłego stanu położniczego jest przerastanie łożyska, do czego predysponują wcześniej wykonywane zabiegi na macicy (na przykład łyżeczowanie). Samoistne pęknięcie macicy we wczesnym drugim trymestrze (poniżej 16 tygodnia) zdarza się natomiast wyjątkowo rzadko. Praca przedstawia przypadek samoistnego pęknięcia macicy z powodu przerastania łożyska u pacjentki bez wywiadu zabiegów na macicy.

## Corresponding author:

Piotr Pierzynski  
Department of Reproductive Medicine and Gynaecological Endocrinology  
M. Skłodowskiej-Curie 24a  
15-276 Białystok, Poland  
tel +48 85 7468453, fax +48 85 7468735  
e-mail: piotr.pierzynski@gmail.com

Otrzymano: 04.11.2011  
Zaakceptowano do druku: 15.07.2012

Pierzynski P, et al. Spontaneous rupture of unscarred uterus in the early second trimester: a case report of placenta percreta.

**Opis przypadku:** 35 letnia wieloródka bez wywiadu zabiegów na macicy w 16. tygodniu (15 tyg. 2 dni) piątej ciąży, zgłosiła ból narastający brzucha z towarzyszącymi objawami hipowolemii podczas pobytu w klinice z powodu zagrażającego poronienia. Podczas zabiegu laparotomii zwiadowczej stwierdzono pośrodkowe pęknięcie macicy nacieczone przez przerastające łożysko. Wykonano zabieg nadpochwowego wycięcia macicy. Pooperacyjne badania dodatkowe potwierdziły znacznie podwyższone poziomy alfa fetoproteiny (AFP)

**Wniosek:** Nieprawidłowo przebiegający rozwój łożyska i następne pęknięcie macicy powinny być brane pod uwagę jako jedna z przyczyn bólu i nagłej hipowolemii także u kobiet w drugim trymestrze ciąży bez wywiadu zabiegów na macicy.

Słowa kluczowe: łożysko przerośnięte / pęknięcie macicy / drugi trymestr ciąży /

Abnormal placentation, such as placenta increta, is a rare complication of pregnancy. It usually develops as placenta previa in the scarred uterus of patients with a history of uterine surgery [1]. Invasion of placental villi is also possible at a site of damaged decidua or the uterine wall [2]. Such an invasion affects the myometrial integrity, predisposing or even causing uterine rupture [3].

Spontaneous uterine rupture occurs most often in the third trimester at the time of labor-type uterine contractility [3]. The occurrence of spontaneous rupture of unscarred uterus in the early mid-trimester, 16 weeks gestation or earlier, is far less frequent. We found only two reports of such an early rupture related to abnormal placentation [4, 5]. In this case study, we report an early mid-trimester spontaneous rupture of unscarred uterus related to placenta percreta in otherwise uncomplicated pregnancy.

### Case report

A 36-year-old multipara at 16 weeks gestation (15 w 2 d) of her 5<sup>th</sup> pregnancy was referred to the Maternal-Fetal Medicine Department with complaint of lower abdominal pain for the last 2 days, suggestive of an imminent miscarriage. The patient had four previous healthy vaginal deliveries, free of complications (the last one 7 years previously). Fetal weights at birth were as follows: 3850g, 3950g, 4100 g, and 5150g. The patient had no relevant medical history and there were no complications in the current pregnancy.

On admission, patient blood pressure and heart rate were normal. On physical examination, there was lower abdominal discomfort on palpation. Vaginal examination showed a normal uterine cervix and no uterine bleeding. Ultrasound scan showed a viable fetus with normal anatomy consistent with menstrual age. Amniotic fluid index was 9.8cm. On the ultrasound scan, placenta was lying on the anterior uterine wall and had no apparent abnormalities. Serum creatinine, urea and aminotransferases (ALAT, ASAT) were within normal ranges. Full Blood Count, done a week before, was normal.

After receiving a standard treatment for imminent abortion, including drotaverine and sedatives, the patient reported notable decrease in the abdominal pain. In the 14<sup>th</sup> hour of hospital stay the pain started increasing, being more diffuse and spread over the whole abdomen. An hour later she fainted on the way to the bathroom. Blood pressure and pulse were then 80/40mmHg and 100bpm, respectively. On physical examination, the abdomen was distended and very tender on palpation, bowel sounds were decreased. There was apparent rebound tenderness and guarding.

No distinct mass was palpable. On pelvic examination uterine cervix was closed with uterine bleeding. Surgical consultation confirmed a diagnosis of acute abdomen. Abdominal ultrasound showed marked ascites, no amniotic fluid in the uterine cavity, and fetal demise. No source of bleeding was found.

Laboratory analyses showed slightly prolonged Prothrombin Time with an International Normalized Ratio of 1.30 and borderline APTT (Activated Partial Thromboplastin Time) of 23.3 sec. (normal range 24-25 sec.). Hemoglobin was 80g/L, Hematocrit was of 23.7%, red blood cell and white blood cell counts were of 2.54M/uL and 12.0k/uL, respectively. Blood glucose was elevated (151 mg/dL / 8.38 mmol /L) and the C-reactive protein was 10.8mg/L (normal range 0.0–10.0mg/L). Aminotransferases (ASAT and ALAT), and serum amylase were within normal limits.

Considering all the above, a diagnosis of acute abdomen, intraperitoneal bleeding, intrauterine fetal demise, and incipient hypovolemic shock was made along with a suspicion of uterine rupture.

The patient was immediately taken to the operating theatre. Under a general anesthesia, a midline laparotomy was performed. There was about 1500ml of blood with clots in the peritoneal cavity. The uterus was constricted and had a midline 5 cm-long rupture in the fundus (Figure 1). Placental tissue was protruding from the site of the rupture, suggesting this was the site of placental invasion (Figure 2).

Morphologically normal male fetus, consistent with 17 weeks gestation, was delivered through the rupture. After removing the fetus and draining blood and clots from the peritoneal cavity, teres ligaments and uterine arteries were clamped. A supracervical hysterectomy with preservation of the normal ovaries was performed with no complications. All other abdominal organs were normal. Blood loss was estimated at 3000ml. Six units of erythrocyte mass (2400mL) and one unit of FFP (Fresh Frozen Plasma) were transfused during and after the operation with no adverse reactions. After the operation, the patient received four doses of cephalosporin, 1.0g once a day, and metronidazole, 500mg three times a day. The postoperative hemoglobin was 126g/L and coagulopathy was within normal limits. Postoperative observation was uneventful and the patient was discharged 5 days after the surgery. There were no abnormal findings on post op consultation 6 weeks later.

The pathology report confirmed placental percreta (Figure 3). Microscopic examination showed placental invasion and focal degeneration of villi (necrosis, fibrosis, and calcification) which confirmed the diagnosis.

## Discussion

Placenta accreta, increta, and percreta are rare conditions of pregnancy that can be life-threatening, primarily due to massive hemorrhaging. Invasive placentation usually develops in scarred uteri and occasionally becomes evident as early as in the second trimester [5, 6]. Scarred status may include previous uterine surgery, cesarean section(s), uterine trauma, curettage, endometritis or the Asherman's syndrome [7, 8]. An independent, but coexisting risk factor for placental invasion is placenta previa [8]. Uterine scarring is the main factor predisposing to uterine rupture [9]. Spontaneous uterine rupture most often occurs in the third trimester, at the time of labor-type uterine contractility [2, 3, 11].

Unscarred uterus is least susceptible to rupture. Grand multiparity, uterine instrumentation and fetal malpresentation are predisposing factors for uterine rupture at the time of labor. In the report referring to prelabor uterine rupture, Schrinky and Benson found that 7 of 22 women (32%) with unscarred uterine rupture had a parity of greater than 4 [7]. Golan et al., reported that in 31% of cases of uterine rupture (19 of 61 cases), it occurred in women with a parity of more than 5 [12].

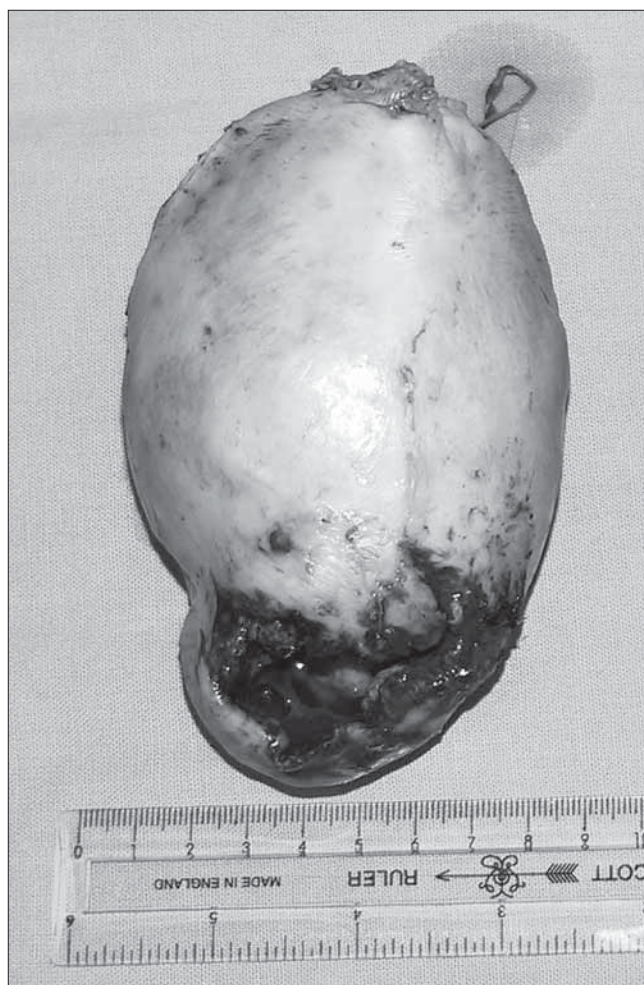Despite the apparent increase in the risk of uterine rupture associated with high parity, the influence of above cited risk factors would not be certain for second trimester pregnancies. A study by Gardeil et al., showed that the rate of unscarred uterine rupture during pregnancy was 1 per 30,764 deliveries (0.0033%). Only 2 cases of uterine rupture occurred among 39,529 multigravidas with no uterine scar [10].

Literature search brings several reports on the first and mid-trimester uterine ruptures, however occurring in patients with a history of uterine instrumentation [6, 9, 13-17]. The occurrence of early mid-trimester (16 gestational weeks or earlier), spontaneous rupture of an unscarred uterus is unique. To the best of our knowledge, only one report on spontaneous, second trimester rupture of unscarred uterus has been published up to date [18].

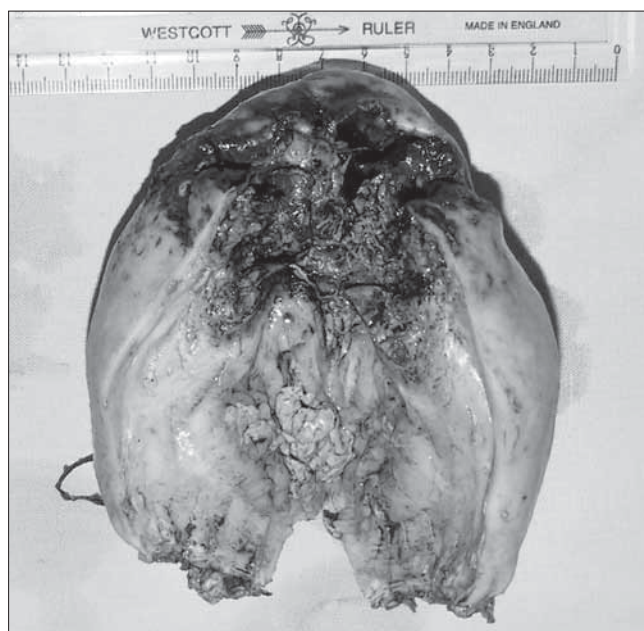In the presented case, we were able to observe the whole sequence of pathologic events related to the uterine rupture, starting from mild lower abdominal pain with a normal uterine ultrasound scan which was quickly progressing to uterine rupture, fetal demise and maternal hemorrhage and hypovolemia.

The diagnosis of spontaneous second trimester rupture of unscarred uterus is usually not considered first-line. Routine pregnancy follow-up, however, might provide some valuable data in patients with increased risk of invasive placentation. Laboratory parameters such as elevated serum alfa-fetoprotein (AFP) or creatinine kinase may be indicative [9, 19, 20]. Some authors advise performing maternal serum AFP testing in patients with low-lying placenta, history of cesarean section, or abnormal (in terms of placentation) result of an ultrasound scan [21]. Since AFP testing can be done in the second trimester as a part of a triple screen test, its abnormal elevation should also draw attention to placental pathology, especially in cases with a normal fetal karyotyping.

In imaging tests, serial transvaginal scans verifying the thickness of lower uterine wall might be of value in women with a history of cesarean section [22]. Suspicious color Doppler results, such as abnormal myometrial periplacental blood flow or the loss of the decidual clear zone between the placenta and myometrium [23, 24], can be verified on MRI (*Magnetic Resonance Imaging*) scan [25].

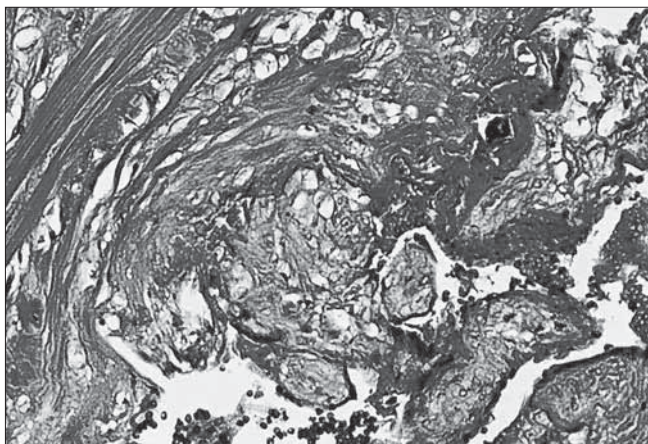


**Figure 1.** Uterine corpus after supracervical hysterectomy. Rupture was localized in the fundus with protruding regions of invading placenta. Fetus consistent with menstrual age was found delivered into the peritoneal cavity.



**Figure 2.** Uterine corpus after dissecting the anterior portion.

Pierzynski P, et al. Spontaneous rupture of unscarred uterus in the early second trimester: a case report of placenta percreta.



**Figure 3.** HE staining micrograph. Placental villi deeply invade and remodel the myometrium. The region normally occupied by decidua is replaced by connective tissue. Magnification 200x.

Finding of placental percreta encouraged us to measure AFP serum levels after the operation. The blood sampling for AFP was done six hours after the surgery and repeated on follow-up visit 6 weeks later. The results were 351.9ng/ml and 14.0ng/ml, respectively. The first, elevated result might confirm the abnormal placentation, considering the low probability of increasing the AFP values by the blood transfusions.

Among the potential reasons for acute abdomen in pregnancy, one should consider acute pathology of gastrointestinal tract such as a rupture of ulceration, ruptured appendicitis as well as other potential reasons as renal pathology. A possibility of placenta increta or percreta in cases of non scarred uteri, even in the second trimester, should also be taken into consideration.

## References

- Ofir K, Sheiner E, Levy A, [et al.]. Uterine rupture: risk factors and pregnancy outcome. *Am J Obstet Gynecol.* 2003, 189, 1042-1046.
- Dare F, Oboro V. A 15-year analysis of uterine rupture. *Int J Obstet Gynecol.* 2002, 79, 27-29.
- Smith J, Mertz H, Merrill D. Identifying risk factors for uterine rupture. *Clin Perinatol.* 2008, 1, 85-99.
- Blé R, Adjoussou S, Doukoure B, [et al.]. Placenta percreta: A rare etiology of spontaneous uterine perforation in the second trimester of pregnancy. *Gynecol Obstet Fertil.* 2011, 39, 11-14.
- Levrant S, Wingate M. Midtrimester uterine rupture. A case report. *J Reprod Med.* 1996, 41, 186-190.
- Endres L, Basnhart K. Spontaneous second trimester uterine rupture after classical cesarean. *Obstet Gynecol.* 2000, 96, 806-808.
- Schrinsky D, Benson R. Rupture of the pregnant uterus: a review. *Obstet Gynecol Surv.* 1978, 33, 217-232.
- Ulman-Wlodarz I, Nowosielski K, Poreba R, Poreba A. Placenta praevia increta with caesarean section scar invasion. *Ginekol Pol.* 2011, 82, 471-473.
- Abouafia Y, Lavie O, Granovsky Grisar S, [et al.]. Conservative surgical management of acute abdomen caused by placenta percreta in the second trimester. *Am J Obstet Gynecol.* 1994, 170, 1388-1389.
- Gardeil F, Daly S, Turner M. Uterine rupture in pregnancy reviewed. *Eur J Obstet Gynecol Reprod Biol.* 1994, 56, 107-110.
- Yap S, Kim E, Laros R. Maternal and neonatal outcomes after uterine rupture in labor. *Am J Obstet Gynecol.* 2001, 184, 1576-1581.
- Golan A, Sandbank O, Rubin A. Rupture of the pregnant uterus. *Obstet Gynecol.* 1980, 56, 549-554.
- Esmans A, Gerris J, Corthout E, [et al.]. Placenta percreta causing rupture of an unscarred uterus at the end of the first trimester of pregnancy: case report. *Hum Reprod.* 2004, 19, 2401-2403.
- Hlibczuk V. Spontaneous uterine rupture as an unusual cause of abdominal pain in the early second trimester of pregnancy. *J Emerg Med.* 2004, 27, 143-145.
- Norwitz E, Stern H, Grier H, Lee-Parriz A. Placenta percreta and uterine rupture associated with prior whole body radiation therapy. *Obstet Gynecol.* 2001, 98, 929-930.
- Pont M, Kouadio E, Fernandez M, [et al.]. Placenta percreta at first trimester of pregnancy. Diagnostic and decision-making difficulties: about a case and a review of the literature. *J Gynecol Obstet Biol Reprod (Paris).* 2010, 39, 498-495.
- Smith L, Mueller P. Abdominal pain and hemoperitoneum in the gravid patient: a case report of placenta percreta. *Am J Emerg Med.* 1996, 14, 45-47.
- LeMaire W, Louisy C, Dalessandri K, Muschenheim F. Placenta percreta with spontaneous rupture of an unscarred uterus in the second trimester. *Obstet Gynecol.* 2001, 98, 927-929.
- McDuffie R, Harkness L, McVay R, Haverkamp A. Midtrimester hemoperitoneum caused by placenta percreta in association with elevated maternal serum alpha-fetoprotein level. *Am J Obstet Gynecol.* 1994, 171, 565-566.
- Ophir E, Tendler R, Odeh M, [et al.]. Creatine kinase as a biochemical marker in diagnosis of placenta increta and percreta. *Am J Obstet Gynecol.* 1999, 180, 1039-1040.
- O'Brien J, Barton J, Donaldson E. The management of placenta percreta: conservative and operative strategies. *Am J Obstet Gynecol.* 1996, 175, 1632-1638.
- Finberg H, Williams J. Placenta accreta: prospective sonographic diagnosis in patients with placenta previa and prior cesarean section. *J Ultrasound Med.* 1992, 11, 333-343.
- Gotoh H, Masuzaki H, Yoshida A, [et al.]. Predicting incomplete uterine rupture with vaginal sonography during the late second trimester in women with prior cesarean. *Obstet Gynecol.* 2000, 95, 596-600.
- Lerner J, Deane S, Timor-Trisch J. Characterization of placenta accreta using transvaginal sonography and color Doppler imaging. *Ultrasound Obstet Gynecol.* 1995, 5, 198-201.
- Thorp J, Council R, Sandridge D, Wiest H. Antepartum diagnosis of placenta previa percreta by magnetic resonance imaging. *Obstet Gynecol.* 1992, 80, 506-508.