

P R A C E K A Z U I S T Y C Z N E
położnictwo

Diploid karyotype partial mole coexisting with live term fetus – Case report and review of the world literature

Zaśniad częściowy z diploidalnym kariotypem współistniejący z żywym donoszonym płodem – opis przypadku i przegląd literatury

Sak Muhammet Erdal¹, Soydinc Hatice Ender¹, Evsen Mehmet Siddik¹, Sak Sibel², Firat Uğur³

¹ Dicle University, School of Medicine, Department of Obstetrics and Gynecology, Diyarbakir, Turkey

² Diyarbakir Maternity and Children Hospital, Department of Obstetrics and Gynecology, Diyarbakir, Turkey

³ Dicle University, School of Medicine, Department of Pathology, Diyarbakir, Turkey

Abstract

A partial molar pregnancy of diploid karyotype coexisting with live term fetus is a rare entity. Most instances of partial mole are triploid and only a few cases of diploid partial moles with term delivery have been reported. Here, we report a case of partial mole concomitant with a 37-week live fetus. Postpartum karyotype of the placenta and the fetus revealed both as 46XX. Histological examination of the placenta showed a partial hydatidiform mole.

We discuss the diagnosis based on presenting clinical picture and proper management of signs and symptoms of partial molar pregnancy coexisting with live term fetus and diploid karyotype, coupled with a review of the literature.

Keywords: **hydatidiform mole / partial / pregnancy / human /**

Abstract

Częściowy zaśniad groniasty z diploidalnym kariotypem współistniejący z żywym donoszonym płodem występuje bardzo rzadko, donoszono tylko o kilku takich przypadkach. W większości częściowy zaśniad jest triploidalny. Opisujemy przypadek częściowego zaśniadu współistniejącego z 37 tygodniowym żywym płodem. Kariotyp łożyska po porodzie oraz płodu to 46XX. Badanie histopatologiczne łożyska wykazało częściowy zaśniad groniasty. Omawiamy diagnozę opartą o obraz kliniczny i odpowiednie postępowanie z objawami częściowego zaśniadu współistniejącego z żywą, donoszoną ciążą i diploidalnym kariotypem oraz przedstawiamy przegląd literatury.

Słowa kluczowe: **zaśniad groniasty / zaśniad częściowy / ciąża / człowiek /**

Corresponding Author:

Muhammet Erdal Sak
Department of Gynecology and Obstetrics, Dicle University School of Medicine,
21280 Diyarbakir, Turkey
Phone: +90 412 2488001/4137 ; Fax : +90 412 2488523
e-mail address: drmesak@yahoo.com

Otrzymano: **27.10.2011**
Zaakceptowano do druku: **20.09.2012**

Introduction

Hydatidiform mole coexisting with a fetus is a rare occurrence, and in the world literature, the incidence of hydatidiform mole ranges from 23 to 1299 cases per 100 000 pregnancies. Hydatidiform moles are categorized into complete and partial types that have distinct disease processes with characteristic cytogenetic, histological and clinical features [1]. Partial mole is defined as excessive trophoblastic proliferation with normal and hydropic villi and in the presence of a fetus or a fetal circulation with nucleated cells. Most such cases have a triploid karyotype. Generally, various fetal malformations are associated with partial moles but in some, there are normal full-term fetuses [1, 2].

Herein, we report a case of diploid karyotype partial mole pregnancy coexisting with a live fetus delivered at 37 weeks. A PubMed search undertaken for the period from 1975 to 2010 indicated that only a few such cases delivered at term have been reported.

Case Report

A 28-year-old woman, gravida 4, para 3, presented with vaginal bleeding and active uterine contractions at 37 weeks gestation. Her medical and family history were unremarkable. Ultrasonography (US) revealed a singleton breech presentation fetus with normal anatomy and appropriate amniotic fluid volume. An abnormally thickened, single, large multicystic placenta was also noticed. Based on these findings, a provisional diagnosis of hydatidiform mole coexisting with a live fetus was proposed.

Upon admission, serum concentration of β -human chorionic gonadotropin (β -hCG) was 94753.00 mIU/mL and the hematocrit level 36.3%. The remaining woman's physical examination and laboratory workup (blood pressure, serum transaminases, thyroid hormones, blood platelets and creatinine, with urinalysis) were normal. The baseline fetal heart rate was 140/min. and the fetus was found to be sensitive to nonstress test.

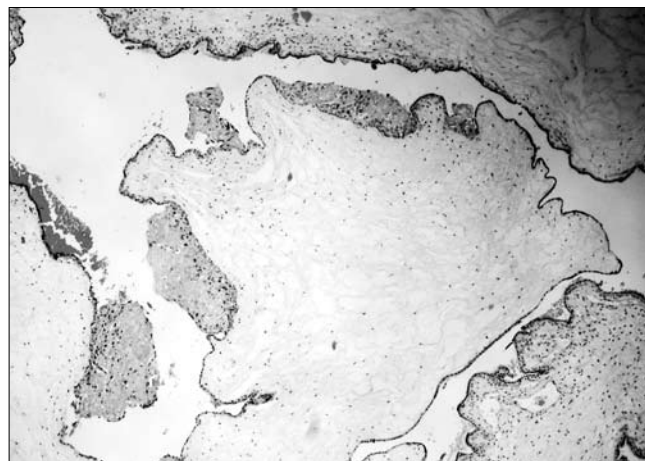


Figure 1. The partial mole showing large hydropic villi with irregular, scalloped outline and mild irregular focal trophoblastic proliferation (H&E staining, magnification 40 x).

On the day of hospitalization, uterine contractions increased. The patient and her spouse were counseled on the risks and implications of the diagnosis. A low transverse incision cesarean section was performed and a 2800 g, 48 cm long live female baby delivered with 1, 5 and 10 minute Apgar scores of 6, 7 and 9, respectively. The placenta was recovered manually. It was noted to be large and hydropic, with necrotic debris. The estimated blood loss was about 500 mL. Histopathological examination of the placenta showed a mixture of large, edematous, irregular villi combined with small normal-sized nonedematous. Trophoblastic hyperplasia of villous surfaces was limited and focally reminiscent of partial hydatidiform mole. (Figure 1).

Postpartum karyotype of the neonate and placenta revealed both as 46,XX. The postoperative course was uneventful. She was discharged on Day 3 after cesarean section.

Table 1. Clinical variables in 7 patients with a partial hydatidiform mole and a coexisting live term singleton fetus with diploid karyotype. NS – Not specified, GA – Gestational age (weeks), G/P – Gravidity/Parity.

Author(s)	Maternal Age (ys)	G/P	Presenting Symptoms	GA at diagnosis/delivery	Placental features and karyotype	Outcome	Persistence of disease and treatment
Jones and Lauersen, 1975 [5]	NS	NS	NS	40/40	Focal hydatidiform mole, normal karyotype	Normal fetus, 46, XX	NS
Wunderlich, 1975 [6]	NS	NS	Vaginal Bleeding	40/40	Focal hydatidiform mole, normal karyotype	Normal fetus	NS
Hartfield, 1983 [7]	NS	1/0	Vaginal Bleeding	38/38	Focal hydatidiform mole, normal karyotype	Normal fetus, 46, XY	No
Pool et al., 1989 [8]	20	1/0	Detected after delivery	38/38	Molar degeneration represented 25% of placenta, no chromosomal analysis made	3450 g, healthy male	No
Parveen et al., 2004 [9]	NS	NS	Vaginal Bleeding	38/38	Partial molar change, 46, XX	Normal fetus, 46, XX	No
Dhingra et al., 2009 [4]	28	1/0	Vaginal Bleeding	38/38	Large placenta, focal molar changes, 46, XX	2100 g, healthy female	No
Our presented case	28	4/3	Vaginal Bleeding,	37/37	Large placenta, focal molar changes, 46,XX	2800 g, 48 cm, healthy female	No

At follow-up, two weeks after discharge, her serum β -hCG concentration was found to be 5.46 mIU/mL, well within the normal limits.

Discussion

A complete hydatidiform mole consists of a diploid set of 46 chromosomes, all genetic material being of paternal origin, there is no fetal structure, and the risk for persistent gestational trophoblastic disease (12–20%) is higher than that of the partial mole (4%) [3]. Partial molar pregnancies result from the fertilization of an apparently normal ovum by two sperms, giving rise to a triploid karyotype (69, XXY): Molar pregnancy concomitant with normal live (term) fetus has been categorized into three types. The most common is a twin pregnancy with one normal fetus having a normal placenta and another complete mole, second type is a twin pregnancy with a normal fetus and placenta and another partial mole, and the third and of most uncommon occurrence is a singleton normal fetus with partial molar placenta [4]. A PubMed search for the years 1975-2010 revealed that only several similar cases with partial mole have been published [4-9]. (Table I).

Sometimes the diagnosis is established as late as postpartum. Compared with the risk in the general population of reproductive age, the risk for molar pregnancy is markedly increased in women older than 35 years of age and slightly increased in those younger than 20 years. However, most cases of molar pregnancies occur in women younger than 35 years of age because of the greater overall number of pregnancies in this age group [10], as in our case.

The most frequent clinical manifestations of molar pregnancy include vaginal bleeding, a disproportionately enlarged uterus, and pelvic pressure or pain. Partial molar pregnancies are characterized by a uterus that is relatively small or adequate for gestational age. Hydatidiform moles are commonly diagnosed during the first trimester of pregnancy with the symptom of abnormal bleeding. Preeclampsia in the first half of pregnancy may also be suggestive of hydatidiform mole. Unusually elevated serial serum β -hCG concentrations occurring together with an enlarged uterus and vaginal bleeding should prompt consideration of the diagnosis of hydatidiform mole [11]. The primary noninvasive means of achieving a diagnosis is US, for partial molar pregnancy related to the changed placental image, possible fetal malformation(s), growth restriction and oligohydramnios [11, 12, 13]. Cytogenetic analyses following amniocentesis or chorionic villus sampling are essential for the definite diagnosis [13, 14, 15]. After US examination of the fetal morphology and placenta and the evaluation of fetal karyotype, it is a reasonable approach to counsel the patient and discuss whether or not to terminate the pregnancy.

The antenatal management should be based on several factors:

1. determination of fetal karyotype;
2. determination of the proportion of normal to molar placenta and degree of placental degeneration;
3. the timely diagnosis of maternal complications such as preeclampsia, preterm labor, thyrotoxicosis and vaginal bleeding;
4. ultrasonographic examination of possible fetal malformations; and

5. screening for fetal anemia due to materno-fetal hemorrhage [13].

In pregnancies with a partial mole and coexisting fetus, complications such as preeclampsia, hyperthyroidism, and vaginal hemorrhage could occur. Optimal management strategies for such a pregnancy are unclear because of the rarity of these cases. In the present case, the woman was managed according to her clinical manifestations. This case exemplified different clinical features that are characterized in the literature. (Table II).

Therefore, if the patient wishes to continue with the pregnancy, she needs to understand the involved increased obstetric risks for complications such as preeclampsia, preterm premature rupture of membranes, preterm delivery, oligohydramnios, fetal distress, or even intrauterine death.

Table II. Differences between typical features of partial molar pregnancy with coexisting fetus and features noted in presented case.

Typical features	Our presented case
Diagnosis made by ultrasound	Diagnosis of partial molar pregnancy made at 37 weeks
Vaginal bleeding, including antepartum hemorrhage	Vaginal bleeding
Preeclampsia	Absent
Hyperthyroidism	Absent
Hyperemesis gravidarum	Absent
Placental findings - grapelike clusters	Degenerated hydatidiform villi and focal trophoblastic proliferation
Persistent gestational trophoblastic disease	Absent
Coexisting live fetus with triploidy	Diploid fetus with term delivery

References

1. Altieri A, Franceschi S, Ferlay J, [et al.]. Epidemiology and aetiology of gestational trophoblastic diseases. *Lancet Oncol.* 2003, 4, 670-678.
2. Bentley R. Pathology of gestational trophoblastic disease. *Clin Obstet Gynecol.* 2003, 46, 513-522.
3. Bristow R, Shumway J, Khouzami A, Witter F. Complete hydatidiform mole and surviving coexistent twin. *Obstet Gynecol Surv.* 1996, 51, 705-709.
4. Dhingra K, Gupta P, Saroha V, [et al.]. Partial hydatidiform mole with a full-term infant. *Indian J Pathol Microbiol.* 2009, 52, 590-591.
5. Jones W, Lauersen N. Hydatidiform mole with coexistent fetus. *Am J Obstet Gynecol.* 1975, 122, 267-272.
6. Wunderlich. M. Partial hydatidiform mole with a full-term infant. Case report. *Zentralbl Gynakol.* 1975, 97, 239-241.
7. Hartfield V. Ptyalism and partial hydatidiform mole associated with a normal term male fetus. *Aust N Z J Obstet Gynaecol.* 1983, 23, 53-56.
8. Pool R, Lebethe S, Lancaster E. Partial hydatidiform mole with a coexistent live full-term fetus. A case report. *S Afr Med J.* 1989, 75, 186-187.
9. Parveen Z, Bashir R, Jadoon T, Qayum J. Partial hydatidiform mole along with term gestation and alive baby. *J Ayub Med Coll Abbottabad.* 2004, 16, 84-85.
10. Altman A, Bentley B, Murray S, Bentley J. Maternal age-related rates of gestational trophoblastic disease. *Obstet Gynecol.* 2008, 112, 244-250.
11. Drummond S, Fritz E. Management of a partial molar pregnancy: a case study report. *J Perinat Neonatal Nurs.* 2009, 23, 115-123.
12. Steller M, Genest D, Bernstein M, [et al.]. Clinical features of multiple conception with partial or complete molar pregnancy and coexisting fetuses. *J Reprod Med.* 1994, 39, 147-154.
13. Guven E, Ozturk N, Devenci S, [et al.]. Partial molar pregnancy and coexisting fetus with diploid karyotype. *J Matern Fetal Neonatal Med.* 2007, 20, 175-181.
14. Vejerslev L. Clinical management and diagnostic possibilities in hydatidiform mole with coexistent fetus. *Obstet Gynecol Surv.* 1991, 46, 577-588.
15. Watson E, Hernandez E, Miyazawa K. Partial hydatidiform moles: a review. *Obstet Gynecol Surv.* 1987, 42, 540-544.