

Management of a large splenic cyst in pregnancy – a case report

Postępowanie w dużej torbieli śledziony w ciąży – opis przypadku

Dąbrowski Wojciech¹, Luterek Katarzyna², Szczepanik Andrzej¹,
Niedźwiedzka Beata³, Wielgoś Mirosław²

¹ Department of General and Hematological Surgery, Institute of Hematology and Transfusion Medicine, Warsaw Poland

² First Department of Obstetrics and Gynecology, Medical University of Warsaw, Poland

³ Medicover Outpatient Clinic, Warsaw, Poland

Abstract

Splenic cysts in pregnancy are an extremely rare disorder and to date only seven such cases have been reported in literature. The consensus for the management of pregnant patients with splenic cysts is therefore yet to be established. A 25-year old nullipara with a large (10 cm in diameter) splenic cyst located in the upper pole and the hilum was qualified for surgery in the second trimester of pregnancy. Open total splenectomy was performed because of the central location and large diameter of the cyst. No complications were reported. The pathology report demonstrated secondary cyst (pseudocyst). The remaining antepartum course was uneventful and the patient spontaneously delivered a healthy baby at 39 weeks of pregnancy.

We are of the opinion that splenic cysts should be operated on in the second trimester of pregnancy because of the risk of spontaneous rupture. Total splenectomy is a safe and effective procedure for centrally located large cysts.

Key words: **splenic neoplasm / pregnancy / splenectomy /**

Streszczenie

Torbiele śledziony u ciężarnych są niezwykle rzadko spostrzeganą jednostką chorobową, do chwili obecnej w literaturze opisano zaledwie siedem przypadków. Z tego względu nie opracowano konsensusu postępowania u ciężarnych z torbielami śledziony. Przedstawiono przypadek 25-letniej pierworódki z torbielą średnicy 10 cm, zajmującej górny biegun i wnękę śledziony, którą zakwalifikowano do leczenia operacyjnego w trzecim trymestrze ciąży.

Ze względu na centralną lokalizację torbieli wykonano całkowitą, otwartą splenektomię. W przebiegu śród- i pooperacyjnym nie stwierdzono żadnych powikłań. Badanie histopatologiczne ujawniło torbiel wtórną (rzekomą) śledziony. Pozostały przebieg ciąży był niepowikłany i pacjentka urodziła zdrowe dziecko siłami natury w 39 tygodniu ciąży.

W naszej opinii duże torbiele śledziony powinny być operowane w drugim trymestrze ciąży ze względu na ryzyko samodzielnego pęknięcia. W przypadku centralnej lokalizacji torbieli całkowita splenektomia jest bezpiecznym i skutecznym sposobem postępowania.

Key words: **nowotwór śledziony / ciąża / splenektomia /**

Corresponding Author:

Wojciech P. Dąbrowski

Department of General and Hematological Surgery, Institute of Hematology and Transfusion Medicine

14 Indira Gandhi Street; 02-776 Warsaw, Poland

tel. +48 22 3496271 fax +48 22 3496272

e-mail: wdwawa@poczta.onet.pl

Otrzymano: **20.01.2012**
Zaakceptowano do druku: **10.10.2012**

Introduction

Splenic cysts are an uncommon disorder of the spleen and up to date approximately one thousand cases have been described in the literature. Cysts are revealed in younger age, most frequently in women. As the clinical course is usually asymptomatic, they are mostly diagnosed as incidental findings in abdominal imaging for other indications. Splenic cysts in pregnant women are extremely rare and up to date only seven such cases have been reported in the literature [1-7].

We present the case of physiological pregnancy complicated by a giant symptomatic splenic cyst which was successfully treated with open splenectomy in the second trimester.

Case report

A 25-year old woman presented with left epigastric pain for several weeks and with no other complaints. There was no history of surgical procedures, trauma, major infections or trips to the tropical countries. An abdominal CT scan with contrast performed at a private clinic (no previous ultrasound examination) revealed a giant cyst of 9x9x10 cm located in the upper pole and hilum of the spleen. The examination also demonstrated a gestational sac in the uterus with a 6 mm crown-rump length (CRL) embryo (the patient had not been aware of her pregnancy). A gynecological consultation confirmed an early pregnancy. A spleen enlargement palpable 3 cm below the left costal arch was revealed in the physical examination with slight tenderness in the area.

Doppler ultrasonography detected a monolocular cyst in the upper pole of the spleen, extending to the hilum, measuring 93x83x100 mm with 402 ml of fluid. No symptoms of portal hypertension or portal vein thrombosis were recognized. Echinococcus-antibody titer test was negative (ELISA). CA 19-9 level within normal reference range excluded the possibility of epidermoid cyst. At gynecological consultation the patient was qualified for surgical treatment in the second trimester of pregnancy to avoid cyst rupture and hemorrhage that could prove life-threatening for both the mother and the fetus.

The procedure was performed in the 18th week of pregnancy under general anesthesia with sevoflurane and antispasmodic drotaverine as well as antithrombotic and antibiotic prophylaxis. We decided to perform an open splenectomy on account of the considerable size of the cyst, collision with the hilar vessels, as well as a high risk of post-operative bleeding related to the organ-saving procedure. The whole spleen was removed together with the cyst (organ mass 710 g). The operation time was 90 min; no intra-operative blood loss was observed. Specimen section revealed a thin-walled cyst with serous liquid and no apparent trabeculation. The pathology report confirmed the existence of a secondary cyst with no cellular epithelial lining. The postoperative course was uneventful.

The vital functions of the fetus, monitored with an ultrasound in the perioperative period, were normal. Doppler ultrasonography of the patient's portal system excluded thrombotic changes and she was discharged on the 4th postoperative day in good overall condition with indication for pneumococcus, meningococcus and Haemophilus influenzae type b vaccination in the post partum period.

In the first weeks following the splenectomy the patient was administered prophylactic doses of low molecular weight heparin. The remaining antepartum course was uneventful and at the

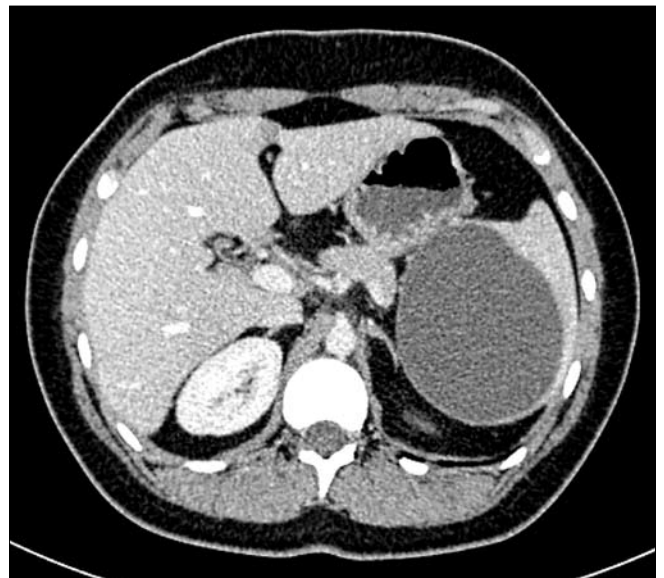
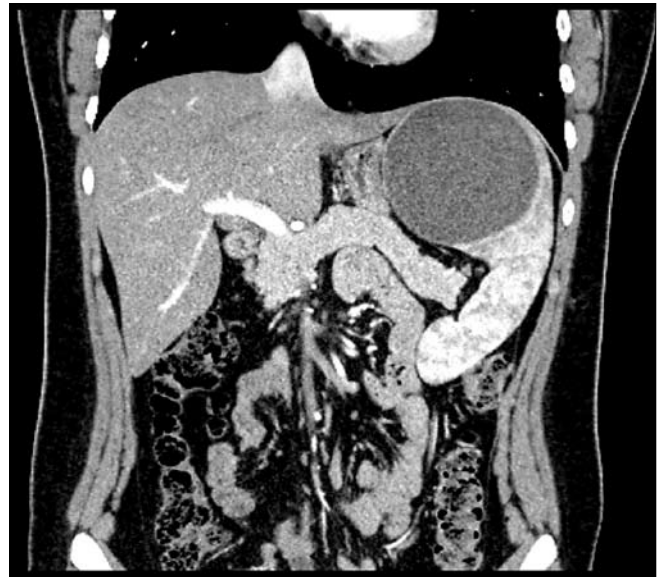

Figure 1a, 1b. CT scan showing a large splenic cyst.

thirty-ninth week of gestation the patient delivered spontaneously a healthy newborn (3800g; Apgar 10).

Discussion

Splenic cysts are commonly classified into two main categories, depending on the presence or absence of epithelial lining in the internal cyst of the wall: primary (true) which may be parasitic or non-parasitic and secondary (pseudocysts). The latter are usually post-traumatic. Pseudocysts are most frequent in women of reproductive age and usually develop after abdominal trauma [8]. In our case the pseudocyst was most likely related to a past trauma which the patient could not even recall. Most cysts present no clinical symptoms and if the symptoms do occur, they are usually slight and depend on the size of the cyst, location, speed of growth and relation to the adjacent organs. The symptoms include discomfort, pain (less frequently) and abdominal mass in the left epigastrium [9, 10]. Other reported symptoms are nausea, vomiting, weight loss, pain in the epigastrium and in the

left shoulder [11]. Pleural effusions may occur upon diaphragm compression.

Ultrasonography, CT and MRI are important tests for the diagnosis and preoperative classification of the cysts [12]. Apart from routine preoperative examination, serological tests for echinococcosis and CA 19-9 are also helpful [13]. CA 19-9 level within a normal reference range excludes epidermoid splenic cysts [14].

Indications for treatment depend on the size of the splenic cysts and the clinical symptoms. Cysts of less than 5 cm in diameter should be observed and monitored with ultrasound and CT as they may relapse spontaneously [15]. Until recently, percutaneous drainage with aspiration and application of tissue gel was used as an alternative treatment method but, due to high percentage of recurrence, septic complications and probability of colon perforation, this method has been significantly restricted [16]. In their report, Rotas et al., [6] confirmed the risk related to percutaneous cyst drainage in pregnancy. They observed re-accumulation of the cystic fluid after a threefold splenic cyst puncture. As result, an infection of the cyst fluid and sepsis developed and, eventually, the patient was subjected to laparoscopic cyst fenestration with omentopexy. Despite these procedures a splenic cyst was still observed in the control sonography.

Rapidly growing cysts of more than 5 cm in diameter should be treated surgically because of an elevated risk of severe complications such as rupture and intraperitoneal hemorrhage, hypovolemic shock, peritonitis, abscess formation or anaphylactic shock in the case of parasitic cysts [8]. Such complications during pregnancy are responsible for a 70% mortality rate of the fetus and are a serious hazard to the life of the mother [17]. Most cases of cyst ruptures were reported to occur in the third trimester of pregnancy as result of the pressure from the growing uterus. Up to date, splenectomy was the treatment of choice in all such cases [1-3]. With the advancement of minimally invasive surgery, laparoscopic and classical spleen parenchyma-saving procedures are recommended to avoid overwhelming post-splenectomy sepsis [10, 18]. Splenectomy is reserved for neoplastic cysts and conditions where spleen-saving procedures are technically impossible i.e. centrally located giant cyst which collides with the hilum vessels. Otherwise, partial splenectomy or laparoscopic fenestration with omentopexy is recommended. Partial resection of the spleen in pregnant women may seem controversial due to specific conditions in the abdominal cavity and the risk for both the mother and the fetus. The question remains whether partial splenectomy is a safe procedure for a pregnant woman due to the difficulty in securing hemostasis of the cut surface of splenic remnant. These, however, are purely theoretical considerations as no partial splenectomy in a pregnant woman had ever been performed. Total splenectomy was performed in 6 of the 8 cases described up to date in the literature; the other two cases were a fenestration with omentopexy and a cyst resection [1-7]. Surgical treatment of splenic cysts in pregnancy is performed to protect both the mother and the fetus against fatal consequences of sudden, unexpected intraabdominal bleeding. Fenestration-related risk is smaller but splenectomy with securing the vessels minimizes the hazard of severe postoperative complications.

Pregnant patients with splenic cysts of over 5cm in diameter should be qualified for surgical treatment because of the risk

of rupture and bleeding complications in the third trimester of pregnancy, as well as possible fatal consequences for the fetus. The choice of the procedure should take into account the size, nature and location of the cyst. Because of the exceptionally low number of reported clinical cases, the optimal management of splenic cysts in pregnancy is yet to be established. Generally, it is recommended to perform minimally invasive surgical procedures of partial parenchyma resection in experienced centers with applied strategies for secure hemostasis; but no such procedure have been performed in pregnant women. In the presented case a large cyst was located in the upper pole and hilum of the spleen, therefore, we assumed an open total splenectomy would be the optimal management in this case. The procedure was performed electively in the second trimester and proved to be safe and effective.

References

1. Bar-Zohar D, Sherer Y, Manor H, [et al.]. Epidermoid cyst of the spleen. *Harefuah*. 1996, 134, 182-185.
2. Can D, Oztekin O, Oztekin O, [et al.]. Hepatic and splenic hydatid cyst during pregnancy: a case report. *Arch Gynecol Obstet*. 2003, 268, 239-240.
3. Ceglowska A. The course of multipara's pregnancy, labour and puerperium with spleen's tumor. *Ginekol Pol*. 2003, 74, 629-632.
4. Elit L, Aylward B. Splenic cyst carcinoma presenting in pregnancy. *Am J Hematol*. 1989, 32, 57-60.
5. Menendez-Arzac R, Sanjuan H, Rebolledo G, [et al.]. Splenic hydatid cyst. Case report of a pregnant woman. *Rev Gastroenterol Mex*. 2002, 67, 195-198.
6. Rotas M, Ossowski R, Lutchman G, [et al.]. Pregnancy complicated with a giant splenic cyst: a case report and review of the literature. *Arch Gynecol Obstet*. 2007, 275, 301-305.
7. Friedman L, Raphael S. Nonparasitic cyst of the spleen: case report and review of the literature. Rare disorder, here associated with pregnancy, is cured by splenectomy. *R I Med J*. 1967, 50, 265-267.
8. Balzan S, Riedner C, Santos L, [et al.]. Posttraumatic splenic cysts and partial splenectomy: report of a case. *Surg Today*. 2001, 31, 262-265.
9. Cureshi M, Hafner C. Clinical manifestations of splenic cysts: study of 75 cases *Am Surg*. 1965, 31, 605-608.
10. Szczepanik A, Meissner A. Partial splenectomy in the management of nonparasitic splenic cysts. *World J Surg*. 2009, 33, 852-856.
11. Smith S, Scott D, Burdick J, [et al.]. Laparoscopic marsupialization and hemisplenectomy for splenic cysts. *J Laparoendosc Adv Surg Tech*. 2001, 11, 243-249.
12. Robertson F, Leander P, Ekberg O. Radiology of the spleen. *Eur Radiol*. 2001, 11, 80-89.
13. Trompetas V, Panagopoulos E, Priovolou-Papaevangelou M, Ramantanis G. Giant benign true cyst of the spleen with high serum level of CA 19-9. *Eur J Gastroenterol Hepatol*. 2002, 14, 85-88.
14. Cowles R, Yahanda A. Epidermoid cyst of the spleen. *Am J Surg*. 2000, 180, 227.
15. Wolters U, Keller W, Lorenz R, Pichlmaier H. Splenic cysts: indications for surgery and surgical procedures. *Langenbecks Arch Chir*. 1990, 375, 231-234.
16. Wu H, Kortbeek J. Management of splenic pseudocysts following trauma: a retrospective case series. *Am J Surg*. 2006, 191, 631-634.
17. Buchsbaum H. Splenic rupture in pregnancy: report of a case and review of the literature. *Obstet Gynecol Surv*. 1967, 22, 381-395.
18. Gianom D, Wildisen A, Hotz T, [et al.]. Open and laparoscopic treatment of nonparasitic splenic cyst. *Dig Surg*. 2003, 20, 74-78.