

Pregnancy-dependent changes in the vein width of the lower extremities in venous insufficiency

Zmiany szerokości naczyń kończyn dolnych w przebiegu ciąży powikłanej niewydolnością żylną

Ropacka-Lesiak Mariola¹, Kasperczak Jarosław², Bręborowicz Grzegorz H.¹

¹ Department of Perinatology and Gynecology, University of Medical Sciences, Poznań, Poland

² Surgery Ward, Regional Hospital, Kalisz, Poland

Abstract

Aim: to analyze the changes in the width of selected veins in the lower limbs during pregnancy and puerperium, with or without venous insufficiency (VI) diagnosed at the first trimester.

Material and methods: the group of 100 pregnant was divided into two subgroups with or without VI. The examination was performed, namely between 11-14th, 18-22nd, 28-32nd weeks of gestation and in 6th week of the puerperium. The sonographic examination included the measurement of the transverse diameter (TD) of the common femoral vein (CFV), the superficial femoral vein (SFV) and the popliteal vein (PV). The changes in the vessel width during pregnancy and puerperium were compared in both groups. Moreover, the changes of analyzed ultrasound parameters between the two groups in the 4 analyzed time periods were compared to the first trimester results.

Results: there was a statistically significant increase in the TD of CFV with the highest values in the third trimester and significantly higher in the puerperium compared to the first visit. TD in all analyzed stages of pregnancy in the group with VI was significantly higher. SFV and PV were not statistically different between the groups in any of the analyzed periods. Average TD of these vessels was higher in the third trimester, decreasing gradually during the postpartum period.

Conclusions: The average TD was highest in the third trimester, decreasing during the postpartum period. In VI group a full return of TD to the values observed in the first trimester was not observed in the puerperium.

Key words: **ultrasound / lower extremities / veins / pregnancy / venous insufficiency /**

Corresponding author:

Mariola Ropacka-Lesiak
Department of Perinatology and Gynecology, University of Medical Sciences
60-535 Poznań, Polna 33, Poland,
tel. +48601765336; fax 48 61 8419 646;
e-mail: mariolaropacka@poczta.onet.pl

Otrzymano: 20.06.2012
Zaakceptowano do druku: 20.11.2012

Ropacka-Lesiak M, et al. Pregnancy-dependent changes in the vein width of the lower extremities in venous insufficiency.

Streszczenie

Cel: analiza zmian szerokości wybranych żył kończyn dolnych w ciąży i połogu, z lub bez niewydolności żylniej (VI) rozpoznanej w pierwszym trymestrze ciąży.

Materiał i metodyka: Grupa 100 ciężarnych została podzielona na dwie podgrupy, z lub bez niewydolności żylniej. Badanie przeprowadzono pomiędzy 11-14, 18-22, 28-32 tygodniem ciąży oraz w 6 tygodniu połogu. Badanie ultrasonograficzne obejmowało pomiar wymiaru poprzecznego (TD) żyły udowej wspólnej (CFV), żyły udowej powierzchownej (SFV) i żyły podkolanowej (PV). Porównano zmiany szerokości naczyń podczas ciąży i połogu w obu grupach. Ponadto zmiany analizowanych parametrów ultrasonograficznych pomiędzy obu grupami w 4 analizowanych okresach czasu porównano do wartości w pierwszym trymestrze.

Wyniki: Stwierdzono istotny statystycznie wzrost szerokości wymiaru poprzecznego CFV z najwyższymi wartościami w trzecim trymestrze. Wartości obserwowane w okresie połogu były istotnie wyższe od obserwowanych w czasie pierwszej wizyty. TD we wszystkich analizowanych okresach ciąży, w grupie VI był znacznie wyższy. SFV i PV nie różniły się statystycznie pomiędzy grupami w żadnym z analizowanych okresów. Średnia wartość TD tych naczyń była wyższa w trzecim trymestrze, zmniejszając się stopniowo w okresie poporodowym.

Wnioski: średnia wartość TD była najwyższa w trzecim trymestrze ciąży, zmniejszając się w okresie poporodowym. W grupie z VI w okresie połogu nie obserwowano pełnego powrotu wartości TD do wartości obserwowanych w pierwszym trymestrze ciąży.

Słowa kluczowe: ultrasonografia / kończyny dolne / żyły / ciąża / niewydolność żylna /

Abbreviations

- CEAP** – Clinical severity, Etiology or cause, Anatomy, Pathophysiology – venous disease of the legs classification
- CFV** – common femoral vein
- DVT** – deep vein thrombosis
- L** – left side
- PV** – popliteal vein
- R** – right side
- SFV** – superficial femoral vein
- VI** – venous insufficiency

Introduction

Changes of blood flow during pregnancy are likely to play an important role in the pathophysiology of venous thromboembolic events in pregnancy and puerperium [1, 2, 3, 4]. The dilatation of the veins can cause endothelial damage, exposure of collagen fibers and activation of a cascade of coagulation factors leading to the formation of blood clots [5]. The observed changes during pregnancy appear to be reversible, at least partly, because some of the analyzed parameters return to the values observed in the early pregnancy. This applies mainly to the velocity of the blood flow in veins.

Approximately 70 to 80% of the varicose veins appear in the first trimester, when the role of mechanical factors is insignificant. Smooth muscles relaxation and loosening of collagen fibers, a phenomenon which corresponds to progesterone and estrogen level, can cause the development of varicose veins, venous thrombosis and venous insufficiency (VI) [6, 7]. Estrogens cause an increased synthesis of coagulation proteins which may result in venous thrombosis and its sequelae. The importance of the hormonal system supports the fact that in menopausal period the differences in the venous thrombosis incidence in men and women are faded [6, 7, 8].

In pregnancy there is also a substantial reduction of the venous return. It is intensified in 28-29 weeks of gestation and reaches the peak at 36 weeks of gestation. After 6 weeks of puerperium the normalization of venous return is observed [9].

Aim

The aim of the study was to analyze changes within the venous system of the lower extremities during pregnancy and puerperium among pregnant women with and without symptoms of venous insufficiency in the lower limbs, diagnosed during the first visit in the first trimester. The analysis was based on the vein widths in selected deep veins of the lower limbs.

Materials and methods

The study included 103 pregnant women consulted at the Clinic of Vascular Diseases between 2006 to 2009. Three patients were excluded due to deep vein thrombosis. The age of the patients ranged from 19 to 45 years. Venous system was evaluated according to the clinical CEAP classification (Table I) [10, 11, 12]. The participants were divided into two groups, depending on the presence or absence of venous insufficiency (VI) of the lower extremities during the first visit in the first trimester. Pregnant women with symptoms of venous insufficiency were enrolled into the study group (n = 50), whereas patients without signs of venous insufficiency comprised the control group (n = 50). The study was approved by the medical ethics review board and all patients gave their written informed consent.

The Doppler measurements of the venous system were performed four times, i.e. between 11-14, 18-22, 28-32 weeks gestation and at 6 weeks after the delivery. The measurements were performed using the General Electric Logiq 500 with linear transducer (7 to 12 MHz). In all pregnant women the physical examinations and color duplex Doppler imaging were performed in supine position with legs elevated about 15 degrees. The angle

of the sampling gate did not exceed 60 degrees. The following vessels were examined: common femoral vein (CFV), superficial femoral vein (SFV) and popliteal vein (PV). Blood flow in the superficial femoral vein was assessed 10 cm below the os of the deep femoral vein. The presence of the fresh thrombosis or post-thrombotic changes were the exclusion criteria.

Doppler examination included the measurement of the blood flow velocities and vein width in the analyzed vessels. The analysis of blood flow velocities was presented in another paper. Veins width changes in the course of the pregnancy and puerperium were compared in both groups. In addition, changes of these parameters in four analyzed time intervals were compared between the two groups as well.

The transverse diameter of the vein was described as the mean value and standard deviation. The concordance of the those parameters with normal distribution with Shapiro-Wilk test in the group without venous insufficiency was analyzed. T-Student test for independent variables was used for parameters consistent with the normal distribution to compare between the two groups (homogeneous variations - Leven test). When compliance with the normal distribution was not confirmed, nonparametric Mann-Whitney test was used. To compare in time, that means to compare values in the first, second, third trimester and the puerperium, in each group the test was performed separately according to the results of the test for compliance with the normal distribution. For parameters consistent with normal distribution an analysis of variation for repeated measures ANOVA with Tukey post hoc test was used. A nonparametric Friedman test with the multiple comparisons Dunn test was used when no evidence of compliance with the normal distribution was shown.

Results

The study included 100 pregnant women divided into two groups depending on the presence or absence of VI in the first trimester. The results of the analysis are presented in Tables II, III and IV.

Analysis of changes in the CFV width in pregnancy showed a significant increase in the transverse dimension of the vessel, with the highest value observed in the third trimester (Figure 1). Vessel width increased with the advanced of gestational age, and the differences between trimesters were statistically significant. Transverse diameter of the vessel in puerperium was significantly lower than that observed in the third trimester. However, it was higher than the transverse diameter from the first trimester. This means that the width of the vessel did not return to the baseline values observed during the first examination. These changes were found in both groups, with as well as without VI. In addition, all values differed statistically between the groups in all studied periods, and the width of the vessel was significantly wider in the group with VI. In the case of the left CFV, similar changes in the width of the vessel as in the right CFV were observed, both in terms of changes during pregnancy, and changes between the groups and statistical significance in the groups and between them (Figure 2).

Transverse diameter of the right SFV did not differ between the groups in each of the analyzed periods, whereas a significant increase in the transverse dimension was found, both in the second and third trimesters of pregnancy, and then a decrease in the width of the vessel in puerperium. The results differed

Table 1. Clinical classification of chronic venous insufficiency (CEAP scale) [10,11].

	Clinical classification (2) of chronic venous insufficiency
Grade 0	the absence of visible or obvious signs of venous disease
Grade 1	telangiectasias* or reticular veins extension**
Grade 2	varicose veins***
Grade 3	Edema
Grade 4	skin changes associated with venous disease (pigmentation, venous eczema, lipodermatosclerosis)
Grade 5	skin lesions as above and healed venous ulcers
Grade 6	skin lesions and active venous ulcers
*	intradermal venules extended up to 1 mm
**	undetectable, palpable, subcutaneous veins enlargement up to a diameter of 4 mm
***	palpable subcutaneous veins generally wider than 4 mm extension

significantly from those observed in the first trimester (Figure 3). A similar trend of changes was noted in the left SFV (Figure 4).

Analysis of the width of the PV showed that the transverse diameter of the vessel was significantly higher in the second and third trimester in both groups compared to the first measurement (Figure 5). In puerperium, a decrease in vessel size was observed, whereas it remained significantly higher than those reported in the first trimester in the group with VI. In the group without VI it did not differ from the values observed in the first trimester. There was no significant change between the two study groups in all studied stages of pregnancy. This means that the transverse diameter of the vein was reduced to the initial values during puerperium in the group without VI, whereas in patients with VI it remained higher than those reported in the first trimester. Evaluation of changes in the width of the left PV showed similar changes, as analyzed in the right PV. Dynamics of changes was the same as in the right lower limb. The analyzed values were not significantly different between the groups (Figure 6).

Discussion

In the literature, there are reports suggesting that changes in the veins occurring during pregnancy can cause permanent damage to the venous system [13, 14]. Analyzing the transverse diameter of this vessel, an increase in the width of the saphenous vein and small saphenous vein during pregnancy, from the first to the third trimesters, and then a decrease in the width were observed. In the present study a significant increase in the transverse dimension of the CFV was found, and the highest value was observed in the third trimester. The increase in the transverse dimension of the SFV and PV in both the second and third trimesters was also noted, and then the reduction of the vessel width in the puerperium.

Table II. Evaluation of transverse diameter changes of selected vessels in pregnancy.

		I trimester			II trimester			III trimester			Puerperium		
		VI (-)	VI (+)	P	VI (-)	V (+)I	p	VI (-)	VI (+)	P	VI (-)	VI (+)	p
CFV (mm)	R	12,4 +/- 3,2	19,4 +/- 3,0	0,0001	13,4 +/- 3,3	20,3 +/- 3,3	0,0001	14,4 +/- 3,6	21,0 +/- 3,5	0,0001	13,4 +/- 4,0	20,7 +/- 3,1	0,0001
	L	12,2 +/- 2,99	19,1 +/- 2,7	0,0001	13,5 +/- 3,2	20,7 +/- 3,0	0,0001	15,0 +/- 3,7	21,9 +/- 2,7	0,0001	13,3 +/- 4,0	21,0 +/- 3,0	0,0001
SFV (mm)	R	6,1 +/- 1,3	6,1 +/- 1,3	0,9589	6,4 +/- 1,3	6,5+ 1,3	0,8316	6,9 +/- 1,3	6,7 +/- 1,3	0,5489	6,3 +/- 1,3	6,5 +/- 1,3	0,7138
	L	6,0 +/- 1,3	5,9 +/- 1,0	0,6415	6,6 +/- 1,2	6,5+ 1,1	0,6770	7,0 +/- 1,1	6,9 +/- 1,1	0,5361	6,5 +/- 1,2	6,4 +/- 1,2	0,8337
PV (mm)	R	6,1 +/- 1,5	6,0 +/- 1,5	0,8873	6,4 +/- 1,5	6,4+ 1,5	0,8961	6,8 +/- 1,7	6,6 +/- 1,7	0,6797	6,4 +/- 1,6	6,5 +/- 1,6	0,5633
	L	6,0 +/- 1,4	6,2 +/- 1,4	0,3630	6,5 +/- 1,4	6,7 +/- 1,4	0,6090	7,0 +/- 1,4	7,0 +/- 1,4	0,8278	6,3 +/- 1,3	6,5 +/- 1,3	0,3626

Student's t test for independent variables

CFV – common femoral vein, SFV – superficial femoral vein, PV – popliteal vein, VI – venous insufficiency, R- right, L – left, p – level of statistical significance

The increase in the width of the veins in the legs during pregnancy was also observed by other authors [2,15,16], who pointed to the role of the growing pressure of the uterus, which may cause disturbances in venous return from the lower limbs. The increase in venous pressure and venous wall relaxation in pregnancy are the likely cause of changes in the vein width. The increase in sex hormone levels in pregnancy is the cause, already described by many other authors, of the relaxation of smooth venous muscle, which may result in an increase of venous wall distensibility [16]. Similar changes were observed in the vessels of the upper limbs. However, this effect in the legs can be compensated or masked by the increase in venous pressure. On the contrary, Eduard and colleagues did not observe any changes in the veins of the upper limbs, showing a significant increase in vascular wall tension veins in the legs [17].

Similar results with regard to the changes in the vein width were found by Macklon et al., [3] when analyzing a group of 24 pregnant women in uncomplicated pregnancy. The analysis was performed seven times in the course of the pregnancy and at 4 and 42 postpartum days. Authors studying the vein changes in the course of pregnancy and puerperium have demonstrated changes in the width of the studied vessels, i.e. the common femoral, superficial femoral and popliteal veins. Somewhat less pronounced, but similar changes were observed in the superficial femoral vein. Similar changes were observed in the popliteal vein. The present study showed similar changes. Although the values presented in this paper differ from those described by Macklon et al., the nature of the observed changes in the course of pregnancy was comparable.

Analyzing the width of the veins in the puerperium, the transverse diameter of all tested vessels was found to be smaller than that observed in the third trimester. However, it was larger

than the diameter measured in the first trimester. All changes in the vein width were statistically significant, except for the changes in the puerperium observed in the PV in the group without VI. This means that the width of the vessel did not return to the initial values observed during the first examination. Decrease of the transverse dimension of the veins in the puerperium was observed by Macklon et al. [3] as well. These changes did not occur in the left SFV, but statistical significance was found only for the CFV. Macklon et al. also showed significant extension of the left CFV versus the right one. Analyzing the results of the vein width, the greatest changes in our study were observed in the CFV, both the right and the left one. The same phenomenon was observed by Macklon et al. [3]. These data suggest that the CFV is the part of the tested venous system within which the strongest visible changes arising during pregnancy and puerperium are noticed. These changes can be co-responsible for the formation of deep venous thromboembolic events, which are mostly visible in the iliofemoral venous circulation during pregnancy [18, 19].

An increase in the transverse diameter, i.e. CFV, SFV, PV, was also observed by Cordts et al., [2] who examined the blood flow in the legs of six pregnant patients without signs of venous disease in their medical history. None of the patients showed any signs of venous insufficiency during pregnancy, despite the observed changes in the width of the vessel. Width of the vessels was increasing up to the third trimester, only to be markedly reduced after the delivery. The observed differences were statistically significant. Similar trends were observed in the other tested vessels. Many of the patients presented symptoms of edema of the lower limbs, but in none of them the varicose veins did actually appear during pregnancy. In addition, plethysmographic studies showed no features of venous insufficiency in all six patients.

Table III. Evaluation of transverse diameter changes of the tested vessels in the group without venous insufficiency compared to the first trimester.

Transverse diameter		I trimester	II trimester	III trimester	Puerperium	p	
CFV (mm)	R	12,4±3,19 7,6-19,0	13,4±3,41 7,9-20,0	14,4±3,65 8,1-22,0	13,4±4,04 7,4-24,0	I-II I-III I-P	0,0032* 0,0001* 0,0017*
	L	12,2±2,99 6,4-18,0	13,5±3,16 7,2-19,0	15,0±3,67 7,8-22,0	13,3±4,01 6,9-26,0	I-II I-III I-P	0,0013* 0,0001* 0,0090
SFV (mm)	R	6,1±1,3 4,1-8,8	6,4±1,3 4,9-9	6,9±1,3 5,1-9,5	6,3±1,3 4,9-9	I-II I-III I-P	0,0027* 0,0001* 0,0417*
	L	6,0±1,3 4-9	6,6±1,2 4,8-9	7,0±1,1 5-9,5	6,5±1,2 4,8-9,1	I-II I-III I-P	0,0011* 0,0001* 0,0099*
PV (mm)	R	6,1±1,52 4-10	6,4±1,51 4-11	6,8±1,74 4,5-13	6,4±1,60 4-11	I-II I-III I-P	0,0403* 0,0001* 0,1090**
	L	6,0±1,36 4-10	6,5±1,35 4-10	6,9±1,44 5-12	6,3±1,31 4,1-10	I-II I-III I-P	0,0010* 0,0001* 0,1632**

* Analysis of variance ANOVA with repeated post hoc Tukey's test;

** Friedman's nonparametric test with test of multiple comparisons of Dunn

CFV – common femoral vein, SFV – superficial femoral vein, PV – popliteal vein, VI – venous insufficiency, R – right, L – left, p – level of statistical significance, I – the first trimester, II – the second trimester, III – the third trimester, P – puerperium

Table IV. Evaluation of the transverse diameter changes of the tested vessels in the group with venous insufficiency compared to the first trimester.

Transverse diameter		I trimester	II trimester	III trimester	Puerperium	p	
CFV (mm)	R	19,4±3,04 13-26	20,3±3,32 14-27	21,0±3,46 15-27,5	20,7±3,10 14-27	I-II I-III I-P	0,0134* 0,0001* 0,0012*
	L	19,1±2,78 12-27	20,7±2,95 13-27	21,9±2,74 14-28	21,0±3,02 13-27	I-II I-III I-P	0,00001* 0,00001* 0,00001*
SFV (mm)	R	6,1±1,26 4-10	6,5±1,31 4,5-11	6,7±1,34 4,6-11	6,5±1,32 4-11	I-II I-III I-P	0,00001* 0,00001* 0,00001*
	L	5,9±1,04 4-8,1	6,5±1,11 4-9	6,9±1,11 4,6-9,1	6,4±1,17 4-9	I-II I-III I-P	0,00001* 0,00001* 0,00001*
PV (mm)	R	6,0±1,52 4-11	6,4±1,51 4,3-11	6,6±1,74 4,3-13	6,5±1,60 4,2-11	I-II I-III I-P	0,00001* 0,00001* 0,0001*
	L	6,2±1,36 4-10	6,7±1,35 4,6-11	7,0±1,44 5-11	6,5±1,31 5-9	I-II I-III I-P	0,00001* 0,00001* 0,0001*

* Analysis of variance ANOVA with repeated post hoc Tukey's test

CFV – common femoral vein, SFV – superficial femoral vein, PV – popliteal vein, VI – venous insufficiency, R – right, L – left, p – level of statistical significance, I – the first trimester, II – the second trimester, III – the third trimester, P – puerperium

(Next page) **Figure 1-6. Graphical Summary of Results:**

- ✦ Statistical significance between groups.
- Statistical significance in the group with the venous insufficiency in relation to the first trimester.
- ⊙ Statistical significance in the group with no relation to the venous insufficiency in the first trimester.

Ropacka-Lesiak M, et al. Pregnancy-dependent changes in the vein width of the lower extremities in venous insufficiency.

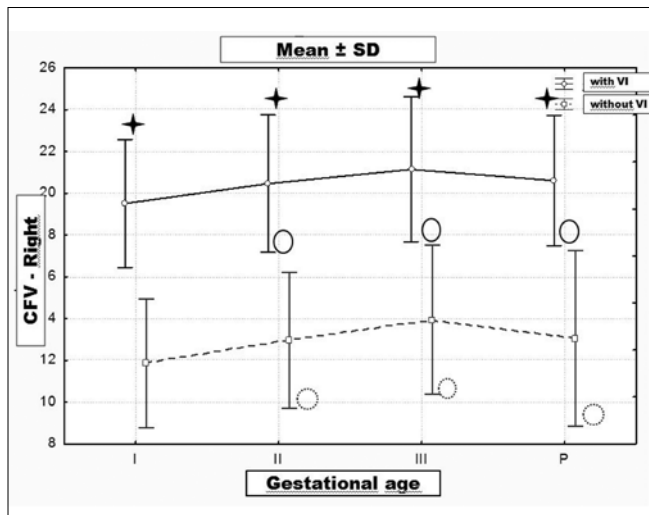


Figure 1. The width of the right common femoral vein in pregnancy and puerperium (mm).

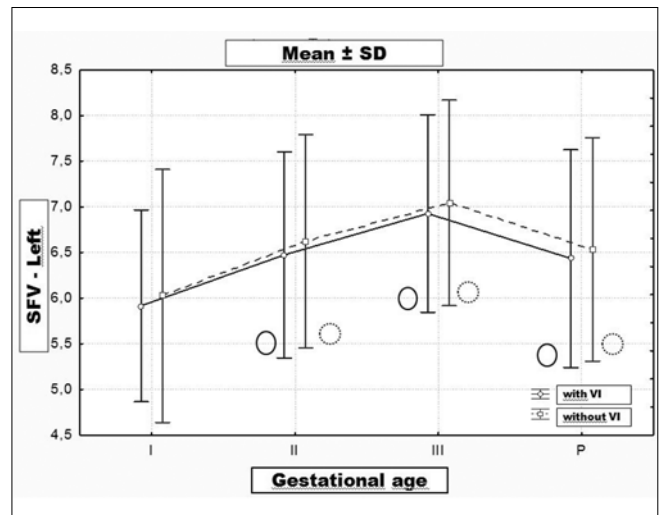


Figure 4. The width of the left superficial femoral vein in pregnancy and puerperium (mm).

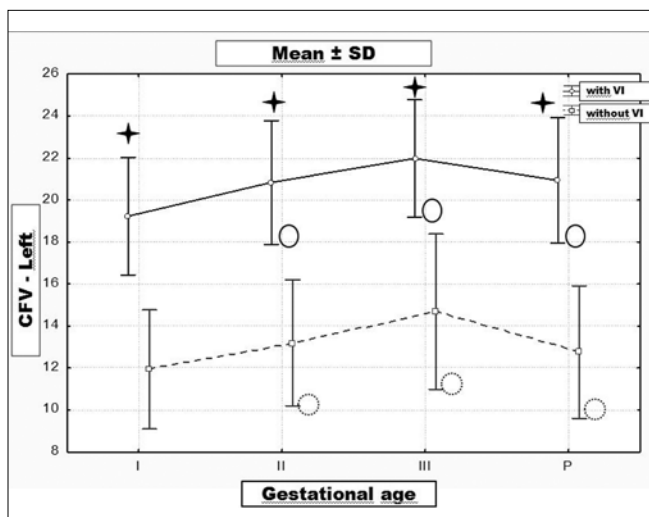


Figure 2. The width of the left common femoral vein in pregnancy and puerperium (mm).

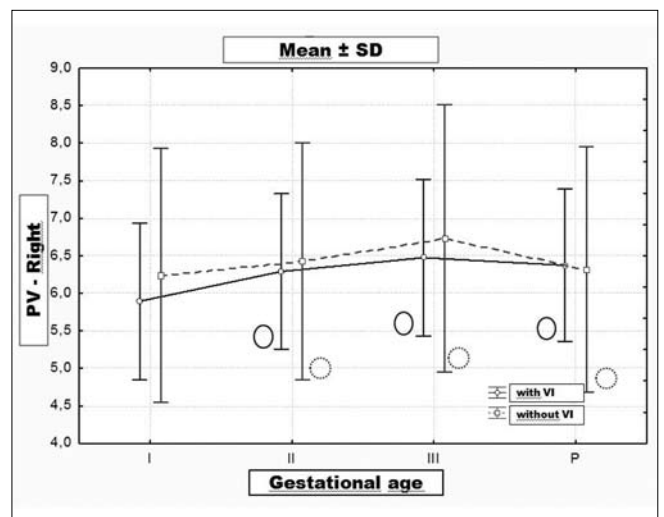


Figure 5. The width of the right popliteal vein in pregnancy and puerperium (mm).

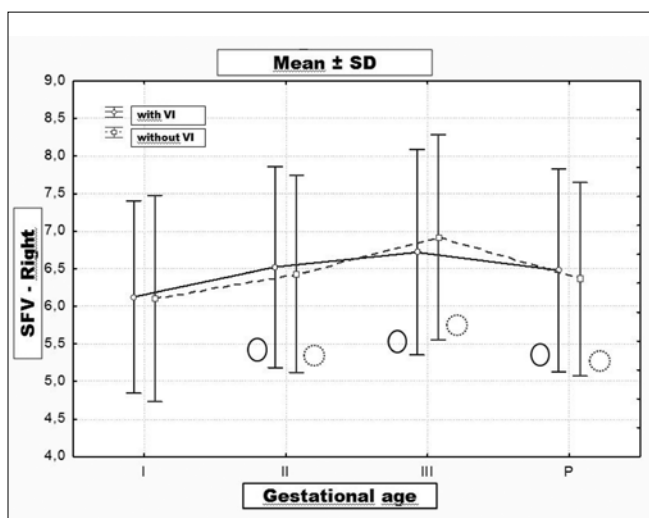

Figure 3. The width of the right superficial femoral vein in pregnancy and puerperium (mm).

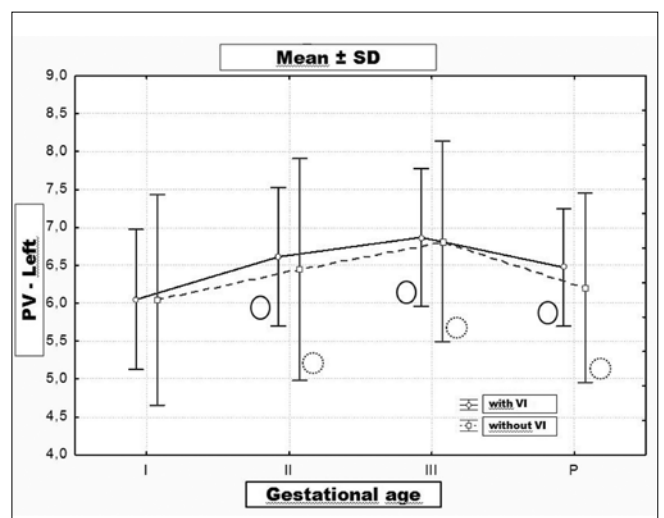


Figure 6. The width of the left popliteal vein in pregnancy and puerperium (mm).

However, the authors suggested that the increase in the vessels width, especially CFV and SFV, may suggest some degree of venous insufficiency. They may also result from an increase in flexibility or increased venous flow in late pregnancy. No venous reflux was found. The observed increase in the venous filling index (VFI- venous filling index) was probably the result of an increased blood flow, following an increased cardiac output. It seems that the increase in venous pressure alone is not responsible for the development of varicose veins. However, the sample size (6 patients) seems to be too small to draw satisfactory conclusions.

Sadick found that 30% of pregnant women present signs of telangiectasias and varicose veins already in the first trimester, 24% in the second and third trimesters, and 49% even after the birth [20]. Probably the hormonal factors such as estrogen and progesterone, and possibly other angioproliferative factors, are responsible for their development at this early stage of pregnancy. Dindelli et al. found that the relative risk of developing varicose changes in pregnancy depends on age being the lowest for women under 24 years of age, but increasing 4-fold after the age of 35 [21].

Changes in the venous vessels during pregnancy were also showed by Calderwood et al. [1]. Assessing the veins of the lower limbs in a group of 25 pregnant patients at 15, 28, 36, 39-41 weeks gestation, on day 2 and 6 weeks after the delivery, they found a progressive increase in the width of CFV in both legs, and a decrease at 6 weeks postpartum. The analyzed changes were similar in character to the right and left CFV and to the results presented in our study. Rabhi et al. demonstrated significant changes within the venous system during pregnancy [15]. Most of them were reversible and returned to the state before pregnancy during the puerperium. The observed extension of the saphenous vein and the reduction in blood volume of the calf vessels suggested that the increase in venous pressure may cause excessive extension of the veins and reduce their vulnerability. Compression of the inferior vena cava and an increase in the intraabdominal venous pressure are probably the two primary causes of increased venous pressure in the legs. Reduction of blood flow velocity on the one hand and blood rheological changes associated with increased levels of fibrinogen on the other hand, cause an increase in the red blood cell aggregation. These changes may cause increased echogenicity of the blood, which are physiological changes and should not be misinterpreted as a sign of venous thrombosis [15].

The observed changes in the venous system in our paper are consistent with the observations of other authors [3, 15, 22]. Changes in the vessel width and blood flow during pregnancy are likely to play an important role in the pathophysiology of the formation of a thromboembolic event during pregnancy and childbirth. This veins extension can cause damage of the vascular endothelium, as mentioned before, and an exposure of collagen fibers and the activation of a cascade of coagulation factors may lead to the formation of blood clots. The observed changes during pregnancy appear to be reversible, at least in part, because some of the analyzed parameters returned to values from the early pregnancy. However, the width of this tested vessel, and especially of CFV, remained higher than that from the first trimester of pregnancy. This suggests that 6 weeks is perhaps not long enough for a full return of pregnancy changes in the venous system to the

baseline. This observation appears to be extremely important in terms of the development of thromboembolism and has important implications for the length of the use of thromboprophylaxis. An increased risk clearly exists at least six weeks after childbirth, and perhaps longer. The risk of a thromboembolic event is even greater in the group with VI, where the return of blood vessel width to the initial values was not observed.

Conclusions

The average TD was highest in the third trimester, decreasing during the postpartum period. In VI group a full return of TD to the values observed in the first trimester was not observed in the puerperium.

References

1. Calderwood C, Jamieson R, Greer I. Gestational related changes in the deep venous system of the lower limb on light reflection rheography in pregnancy and the puerperium. *Clin Radiol.* 2007, 62, 1174-1179.
2. Cordts P, Gawley T. Anatomic and physiologic changes in lower extremity venous hemodynamics associated with pregnancy. *J Vasc Surg.* 1996, 24, 763-767.
3. Macklon N, Greer I, Bowman A. An ultrasound study of gestational and postural changes in the deep venous system of the leg in pregnancy. *Br J Obstet and Gynaecol.* 1997, 104, 191-197.
4. Nicolaidis A. Investition of chronic venous insufficiency. A consensus statement. *Circulation.* 2000, 102, 126-163.
5. Kasperczak J, Ropacka-Lesiak M, Musiał-Świder J, [i wsp.]. Analiza czynników ryzyka rozwoju niewydolności żyłnej oraz pojawiania się objawów klinicznych w czasie ciąży oraz porodu w grupie ciężarnych bez oraz z objawami niewydolności żyłnej kończyn. *Ginekol Pol.* 2012, 83, 183-188.
6. Kasperczak J, Ropacka-Lesiak M, Musiał-Świder J et al. Analysis of venous insufficiency risk factors and appearance of clinical symptoms during pregnancy and puerperium in a group of pregnant women with and without symptoms of venous insufficiency of the lower limbs. *Ginekol Pol.* 2012, 83, 183-188.
7. Krasowski G, Rybak Z. Niewydolność żylna kończyn dolnych w ciąży - fizjologia, czy patofizjologia? *Prz Flebol.* 2001, 9, 53-59.
8. Krasowski G. Niewydolność żył kończyn dolnych u kobiet w ciąży i porodu. Rozprawa doktorska. Wrocław: Akademia Medyczna, 2001.
9. Polak J, Wilkinson D. Ultrasonographic diagnosis of symptomatic deep venous thrombosis in pregnancy. *Am J Obstet Gynecol.* 1991, 89, 625-629.
10. Kasperczak J. Ocena układu żylnego kończyn dolnych w ciąży o przebiegu prawidłowym. Rozprawa doktorska. Poznań: Uniwersytet Medyczny, 2010.
11. Miller V. Vascular Control During Pregnancy. *Circ Res.* 2000, 87, 344-345.
12. Milek T, Milek T, Gólszewski J, [i wsp.]. Przewlekła niewydolność żylna kończyn dolnych u kobiet w ciąży wg klasyfikacji CEAP. *Med Dypł.* 2002, 11, 139-148.
13. Milek T, Gólszewski J, Kwiatkowski W, [i wsp.]. Niewydolność żylna kończyn dolnych według klasyfikacji CEAP u kobiet w ciąży. *Prz Flebol.* 2001, 9, 23-25.
14. Krasieński Z, Oszkiniś G, Kotwicka M, [i wsp.]. Ocena komórek mięśniowych gładkich z receptorami dla hormonów płciowych w żyłach prawidłowych i w żyłkach. *Prz Flebol.* 2005, 13, 61-66.
15. Krasieński Z, Dziedziuchowicz Ł, Krasieńska B, [i wsp.]. Czynniki ryzyka rozwoju żyłaków kończyn dolnych w wieku rozrodczym w Wielkopolsce. *Prze Flebol.* 2006, 14, 211-214.
16. Rabhi Y, Charras-Arthapignet Ch, Gris J, [et al.]. Lower Limb Vein Enlargement and Spontaneous Blood Flow Echogenicity Are Normal Sonographic Findings During Pregnancy. *J Clin Ultrasound ns Inc.* 2000, 28, 407-413.
17. Sakai K, Imaizumi T, Maeda H, [et al.]. Venous distensibility during pregnancy: Comparisons between normal pregnancy and preeclampsia. *Hypertension.* 1994, 24 461-467.
18. Edouard D, Panier B, London G, [et al.]. Venous and arterial behavior during normal pregnancy. *Am J Physiol.* 1998, 274, 1605-1612.
19. Lewandowski K, Zawilska K. Postępy w rozpoznawaniu i zapobieganiu żyłnej chorobie zakrzepowo-zatorowej w okresie ciąży i porodu. *Klin Perinatol Ginekol.* 1994, 11, 29-31.
20. Panella M, Rocchi M, Andreozzi G. Thrombophlebitis and Varicosis syndrome in pregnancy. *Clin Exp Obstet Gynecol.* 1997, 24, 33-35.
21. Sadick N. Predisposing factors of varicose and teleangiectatic leg veins. *J Dermatol Surg Oncol.* 1002, 18, 883-886.
22. Dindelli M, Parrazini F, Basellini A, [et al.]. Risk factors for varicose disease before and during pregnancy. *Angiology.* 1993, 5(44), 361-367.
23. Jamieson R, Greer I. Gestational related changes in the deep venous system of the Lower limb on light reflection rheography in pregnancy and the puerperium. *Clin Radiol.* 2007, 62, 1174-1179.