

Analysis of false negative results of subjective ultrasonography assessment of adnexal masses

Analiza wyników fałszywie ujemnych subiektywnej oceny ultrasonograficznej guzów jajnika

Moszynski Rafal, Szpurek Dariusz, Szubert Sebastian, Sajdak Stefan

Division of Gynecological Surgery, Department of Gynecology, Obstetrics and Gynecological Oncology,
Poznan University of Medical Sciences, Poland

Abstract

Objectives: Currently transvaginal ultrasonography is the most effective method for ovarian tumor malignancy prediction. The aim of the study was to estimate the risk of false negative results in subjective interpretation of the ultrasound examination of ovarian tumors according to menopausal status.

Material and methods: 318 women (210 pre and 108 post menopause) with adnexal masses were diagnosed preoperatively between 2004 and 2010. Subjective assessment of tumor characteristics was conducted by experienced ultrasound examiner. Tumors were divided into groups of: "certainly benign" (n=84), "probably benign" (n=116), "uncertain" (n=61), "probably malignant" (n=47), and "certainly malignant" (n=10). The percentage of false negative results was calculated among the first two groups according to menopausal status.

Results: There were 91 malignant and 227 benign adnexal masses diagnosed in histopathological evaluation. There was one false negative result of subjective interpretation of ultrasound findings in postmenopausal women – 1.6% (1/64). She was a 63-year-old woman with bilateral solid ovaries sized: 4.2x3.1cm and 4.6x2.5 cm in ultrasound evaluation, where serous adenocarcinoma was diagnosed. There were three false negative results in premenopausal women – 2.2% (3/136). The first was a 34-year-old woman with a cyst with the appearance of ground glass of 19 x11cm in size where endometrioid ovarian adenocarcinoma was diagnosed. The second woman was a 32-year-old with a bilocular cyst 8x4.5cm diagnosed with borderline mucinous tumor. The third patient was a 21-year-old woman with unilocular-solid cyst 4.2x3.2cm where histopathological examination revealed borderline serous tumor.

Conclusions: Subjective ultrasound evaluation of adnexal masses has high specificity but even in the group of tumors considered benign in premenopausal as well as postmenopausal women malignancy can be found. This occurs slightly more often before menopause.

Key words: **false negative results / ovarian cancer / subjective assessment / ultrasonography /**

Corresponding author:

Division of Gynecological Surgery, Department of Gynecology, Obstetrics and Gynecological Oncology,
Poznan University of Medical Sciences,
33. Polna St., 60-535 Poznan, Poland,
phone +48 61 8419490 fax +48 61 8419418
e-mail: rafalmoszynski@gmail.com

Otrzymano: 28.11.2012
Zaakceptowano do druku: 15.01.2013

Streszczenie

Cel pracy: Obecnie ultrasonografia przezpochwowa jest najbardziej efektywną metodą prognozowania złośliwości nowotworów jajnika. Celem pracy była ocena ryzyka wystąpienia wyników fałszywie ujemnych subiektywnej interpretacji badania ultrasonograficznego pacjentek z guzami jajnika w świetle ich statusu menopauzalnego.

Materiał i metody: Analizie poddano 318 kobiet (210 przed i 108 po menopauzie) z rozpoznanymi i leczonymi operacyjnie guzami jajnika w latach 2004 - 2010. Subiektywna ocena cech guza została wykonana przez doświadczoną ultrasonografistę. Guzy podzielono na grupy: „na pewno niezłośliwe” (n=84), „prawdopodobnie niezłośliwe” (n=116), „niepewne” (n=61), „prawdopodobnie złośliwe” (n=47) i „na pewno złośliwe” (n=10). Odsetek wyników fałszywie ujemnych oszacowano na podstawie dwóch pierwszych powyższych grup w zależności od statusu menopauzalnego badanych pacjentek.

Wyniki: W wyniku badania histopatologicznego rozpoznano 91 złośliwych i 227 niezłośliwych guzów jajnika. Wykazano jeden wynik fałszywie ujemny subiektywnej oceny ultrasonograficznej w grupie kobiet po menopauzie - 1,6% (1/64). Pacjentka miała 63 lata, w ocenie ultrasonograficznej obustronnie lite jajniki wielkości: 4,2x3,1 cm i 4,6x2,5 cm, u której rozpoznano gruczolakoraka surowiczego. Wykazano trzy wyniki fałszywie ujemne u kobiet przed menopauzą - 2,2% (3/136). Pierwsza pacjentka miała 34 lata, w usg zmianę sugerującą torbiel endometrialną, wielkości 19 x11cm, u której rozpoznano gruczolakoraka endometrialnego. Druga kobiet miała 32 lata, dwukomorową torbiel o wymiarach 8x4,5cm, u której rozpoznano guz słuźowy o granicznej złośliwości. Trzecia pacjentka miała 21 lat, torbiel jednokomorową 4,2x3,2cm z wyrosłami endofitycznymi oraz w badaniu histopatologicznym guz surowiczy o granicznej złośliwości.

Wnioski: Subiektywna ocena ultrasonograficzna guzów jajnika ma wysoką wartość prognostyczną, ale nawet w grupie nowotworów uznanych za „niezłośliwe” zarówno u kobiet przed jak i po menopauzie może zostać rozpoznany ostatecznie nowotwór złośliwy jajnika. Nieznacznie częściej sytuacja taka występuje u kobiet przed menopauzą.

Słowa kluczowe: **ocena subiektywna / rak jajnika / ultrasonografia /
/wynik fałszywie ujemny /**

Introduction

Ovarian cancer diagnosis and treatment is still a very important and clinically difficult problem in gynecological oncology. Although the symptoms are present, they are not typical, thus diagnosis usually comes at a later stage of the disease, assessed according to International Federation of Gynecology and Obstetrics (FIGO) classification as III or IV stage [1].

It is important to focus on early detection of ovarian cancer where the chances for effective treatment are higher. Correct evaluation of adnexal masses prior to surgery is essential for the optimal selection of therapeutic procedure. Patients operated on in gynecological oncology centers have the best chances of survival [2].

Currently transvaginal ultrasonography is the most effective method for malignancy prediction. Subjective assessment performed by an experienced examiner with a high quality ultrasonography device may correctly classify the majority of tumors as benign or malignant [3]. But it is also possible that tumors classified in ultrasonography as “certainly benign” or “probably benign” are finally diagnosed as malignant or borderline in histopathological examination. In these cases the results of ultrasound classification are false negative. It is interesting to explore how abundant the group of false negative results is, and how often tumors misclassified as benign are operated on in general gynecology units by means of laparoscopic approach. Due to hormonal and ovarian changes during the reproductive period, the influence of menopausal status on the subjective assessment of ovarian tumors is also interesting.

Objectives

The aim of the study was to estimate the risk of false negative results in subjective interpretation of the ultrasound appearance of ovarian tumors, and to review the false negative results obtained in recent years in our department.

Material and methods

The study included 318 women (210 pre and 108 post menopause) with adnexal masses diagnosed preoperatively with transvaginal and abdominal ultrasonography between 2004 and 2010 in the Division of Gynecological Surgery, Poznan University of Medical Sciences, Poland. Subjective assessment of tumor characteristics was carried out by an experienced ultrasound examiner according to IOTA group guidelines [4].

Based on IOTA group guidelines, the tumors examined in ultrasonography were divided according to subjective impression of examiner into five groups:

- 1) “certainly benign” (n=84),
- 2) “probably benign” (n=116),
- 3) “uncertain” (n=61),
- 4) “probably malignant” (n=47), and
- 5) “certainly malignant” (n=10) tumors.

All patients were operated on and the tumors were assessed in a postoperative histopathological examination.

If a tumor was classified as “certainly benign” or “probably benign” but histopathological examination revealed a malignant or borderline tumor the false negative result was noticed. The percentage of false negative results was also evaluated according

to menopausal status. Tumors assessed as “certainly malignant”, “probably malignant” or “uncertain” are treated as malignant tumors in our department, thus histopathologically proven benign tumors from these groups were regarded as false positive results. In addition to subjective assessment, the tumors were evaluated by the use of two ultrasonographic scales: somomorphological index (SM; with cut-off equal or above 8 points) [5], and Doppler scale (SD; with cut-off equal or above 4 points) which were developed in our division.

Results

There were 91 malignant (including 13 low malignancy potential) and 227 benign adnexal masses diagnosed in histopathological evaluation. The subjective evaluation of ultrasound findings performed in our study had very high prognostic values with sensitivity 95.6%, specificity 86.3% and accuracy 89.0%.

In the group of 108 postmenopausal women 64 ovarian tumors in ultrasonography examination were classified as either “certainly benign” (n=40) or “probably benign” (n=24). Among these tumors there was one false negative result of the subjective interpretation of ultrasound findings – 1.6% (1/64).

It was the case of a 63-year-old woman admitted to hospital because of reported postmenopausal bleeding. In palpation she had a slightly enlarged uterus strictly connected with both palpable ovaries. Uterus and adnexes were immovable in gynecological examination. Ultrasonography showed bilateral, slightly enlarged fully solid ovaries: 4.2 x 3.1 cm and 4.6 x 2.5 cm in size for left and right ovary respectively. The volumes of the ovaries were: 28 cm³ and 18 cm³ for left and right respectively. They were fully solid and for that reason were assigned 10 points in the morphological index (SM) [5]. Only a little fluid was present in the pouch of Douglas (3mm AP). There was only minimal peripheral vascularization assessed at 2 points in color score according to IOTA group [4] with pulsatility index PI=1.11 and resistance index RI=0.65. (Figure 1).

In the Doppler index (SD) these adnexal masses scored 1 point [6]. In subjective ultrasound assessment this ovarian mass was classified as “probably benign”. Because of the results of bimanual examination, elevated CA125=566 IU/l and elevated morphological index the woman was qualified for laparotomy. The ovaries were macroscopically changed, in infiltration with the uterus and also the greater omentum was infiltrated. Surgical staging was performed. Histopathological examination demonstrated partially serous and clear cell adenocarcinoma of both ovaries G2; the omentum was infiltrated and final stage of the disease was IIIb according FIGO classification.

In the group of 210 premenopausal women 136 ovarian tumors were classified in ultrasonographic examination as “certainly benign” (n=44) or “probably benign” (n=92). There were three false negative results in the group of premenopausal women – 2.2% (3/136).

The first patient was a 34-year-old woman admitted to the hospital because of a pelvic mass which in palpation reached the level of the umbilicus. In ultrasonography the tumor was an unilocular cyst of “ground glass” appearance and 19x11cm in perpendicular diameters. The volume of the cyst was 2078cm³. It had a smooth, thick capsule (4mm), no septation and elevated echogenicity. The tumor was unilocular and developed from

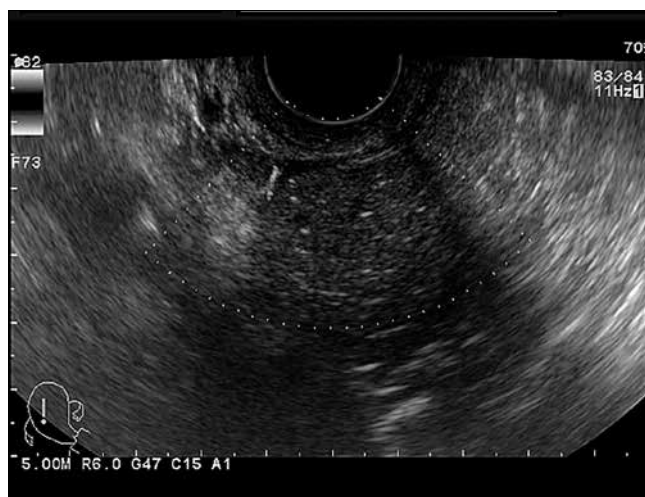


Figure 1. False negative result of ultrasonography in 63-year-old woman with serous adenocarcinoma.

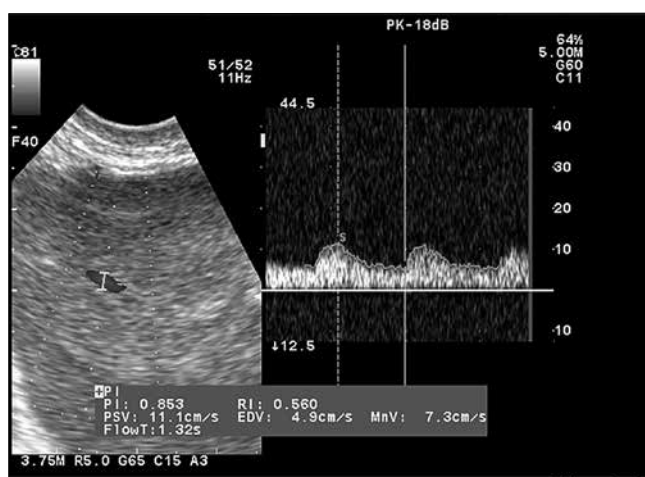


Figure 2. Doppler examination of 34-year-old woman with endometrioid ovarian adenocarcinoma.

the left ovary. The right ovary was visible and appeared to be unchanged. She had 8 mm of free fluid in the pouch of Douglas measured in sagittal plane. In subjective ultrasound assessment this tumor was classified as “probably benign”, suspected to be an endometrial cyst and after this examination the patient was qualified for laparoscopy. In morphological index (SM) assessment the analyzed tumor was not suspect and scored 7 points. However, in the Doppler index (SD) it got 4 points, which is above the cut-off because of an unexpected central, low resistance (PI=0.85; RI=0.56) vascularization. (Figure 2).

The vascularization was assessed at 3 points in color score according to IOTA group. CA125 serum level was 70.82 IU/l. We started the surgical procedure by laparoscopy but the patient was informed of the higher risk of conversion to laparotomy. During the procedure and suspicion of malignancy the laparoscopy was converted to open surgery. Postoperative histopathology demonstrated endometrioid ovarian adenocarcinoma G2 and infiltration to mesosalpinx, and the tumor was assessed as FIGO IIc. Surgical staging procedures were performed.

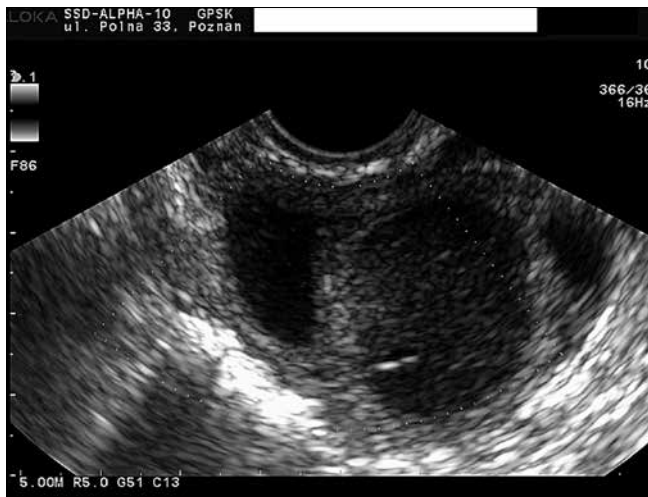

Figure 3. False negative result of ultrasonography in 32-year-old woman with borderline mucinous tumor.

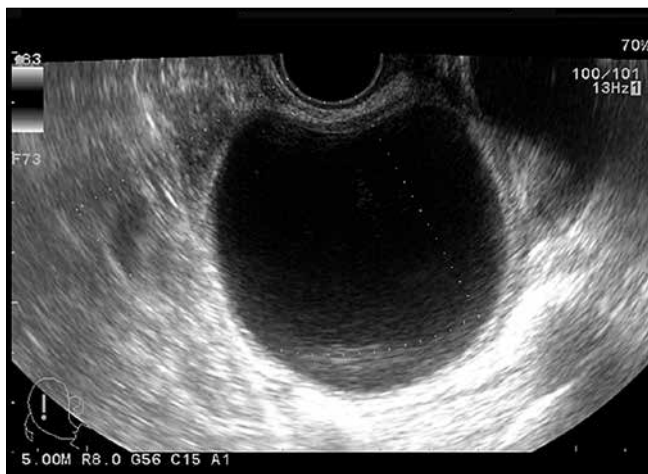

Figure 4. False negative result of ultrasonography in 21-year-old woman with borderline serous tumor.

The second false negative result in the group of premenopausal women was found in a 32-year-old woman admitted to hospital because of a pelvic mass palpable behind the uterus. In ultrasonography it was a bilocular cyst of low-level echogenic content with diameter 8x4.5 cm. Volume of the tumor was 113 cm³. It had a smooth, thick capsule (4 mm) and a thick septum (5 mm). The tumor was unilateral and 6 mm of free fluid was measured in the antero-posterior dimension in the pouch of Douglas. In subjective ultrasonographic assessment this tumor was classified as “probably benign”. In the morphological index (SM), however, it had elevated risk because it scored 9 points. In the Doppler index (SD) it was not suspect - 0 points, as it showed only one vessel in the septum, vascularization assessed at 2 points in color score according to IOTA group. (Figure 3).

Biochemical marker CA125 was at the level of 9.01 IU/l. She was qualified for laparoscopy. After closer analysis of the tumor in endoscopic examination and suspecting malignancy, the operation procedure was converted to open surgery for surgical staging. The final histopathology demonstrated borderline mucinous cystadenoma of the right ovary, FIGO Ia.

Another false negative result of subjective ultrasonography assessment was the case of a 21-year-old woman admitted to the hospital because of an ovarian cyst undetectable by palpation but found during routine sonographic examination. In our division, after exact ultrasonographic examination, a unilocular-solid cyst of anechoic content with diameter 4.2x3.2 cm was diagnosed. The volume of the cyst was 29 cm³. It had an irregular and thick capsule (3,5mm), no septation, no ascites and the tumor was unilateral. It had at least three small papillary projections with maximal size 1.5mm. In subjective assessment this cyst was classified as “probably benign”. In the morphological index (SM) it scored 5 points and in the Doppler index (SD) 0 points. Vascularization was assessed at 1 point in color score according to IOTA group.

In both our indices it was not suspicious regarding malignancy. The CA125 marker level was 29.2 IU/l. She was qualified for laparoscopy. During the endoscopic procedure the capsule of the cyst was ruptured. The final histopathology demonstrated borderline serous cystadenoma, but because of the iatrogenic damage to the capsule FIGO stage was set as Ic.

Discussion

The method of surgery chosen is very important in the management of ovarian tumors, and for benign tumors laparoscopy should be indicated. An intra operation histopathological examination is obligatory and it is important to inform the patient of the possibility of conversion from laparoscopy to open surgery. In cases of malignant tumors, in our opinion, laparotomy is better for oncologic sterility and full surgical staging. The type of hospital in which a patient is treated for primary operation is also very important. The best results are obtained in highly specialized gynecological oncology centers, when compared to general gynecology units [2]. An accurate test for differential diagnosis of ovarian tumors is essential in making the appropriate decision about the method of operation and the character of the hospital chosen to provide surgical care. Another important aspect of ovarian tumor management is the fact that in many cases, for example in functional cysts, unnecessary surgery may be avoided [7]. There is an opinion that transvaginal ultrasonography performed by an experienced sonographer has a very high prognostic accuracy in preoperative subjective classification of adnexal tumors [3]. Ultrasonography is very useful also in the assessment of the particular type of tumor and in some cases specific diagnosis is possible (e.g. endometrioma, dermoid cyst, hydro-, pyo- or hematosalpinx, paraovarian cyst, hemorrhagic corpus luteum cyst or myoma) based on “pattern recognition” of the gray-scale ultrasound image [8].

Subjective evaluation of ultrasound findings performed by an experienced ultrasound examiner according to IOTA group report has high prognostic values, with sensitivity 90% and specificity 93% [9]. In our study a kind of over diagnosis, slightly higher sensitivity (95.6%) and lower specificity (86.3%) is probably connected with qualification of all “uncertain” tumors into the group of malignant diseases.

Subjective ultrasound assessment of ovarian tumors was found to be superior to advanced mathematical models [10], risk of malignancy index (RMI) and risk of ovarian malignancy algorithm (ROMA) which is based on CA125 and HE4 levels assessment [11]. Our research confirmed this idea, because

Moszynski R, et al. *Analysis of false negative results of subjective ultrasonography assessment of adnexal masses.*

the level of false negative results is low. It is a really rare situation where a tumor seems to be a benign adnexal mass and presents itself, for example, as a bilocular cyst, and finally in histopathology a malignant or borderline tumor is diagnosed. It is a different, and more complicated, situation when tumors are already “difficult” in subjective ultrasonography assessment in grayscale for correct classification as malignant or benign [12]. In these cases the diagnostic process is more complex and clinical concerns are much greater. There are those of the opinion that creating morphological models and Doppler flow assessment may help in situations difficult for correct classification, but not all of these methods are specific enough or widely used at present.

However, even in the group of patients where ovarian mass in ultrasound seems to be “certainly” or “probably” benign, malignant tumor may be finally diagnosed in histopathology. In our group of patients there was no false negative result in tumors classified as “certainly benign”. In general, this group of tumors includes unilocular, anechoic cysts without solid elements, often called a “simple cyst”. Final diagnosis, if surgical treatment is performed, usually reveals a functional cyst or serous cystadenoma. In the papers of Modesitt et al. and Gramellini et al. it is confirmed that risk of malignancy in tumors classified as benign is extremely low and, for example, in simple cysts smaller than 10cm is close to zero [13, 14]. Granberg et al. showed that only 0.3% of unilocular, anechoic ovarian cysts are malignant [15]. In the opinion of the authors, these tumors have macroscopically visible papillary projections inside the capsule which are often not seen in ultrasonographic examination. However, the study of Granberg et al. was published over 20 years ago, when the resolution of ultrasonography devices was lower than at present. Currently, we seldom see small papillary projections (< 1 mm) on the internal wall of an ovarian tumor but they generally do not bring worries of malignancy as was the case of our patient. In the report of Timmerman et al. as high as 27.9% of benign ovarian tumors display internal papillarities less or equal to 3mm, in comparison to 2% of malignant ovarian tumors [16]. Thus, we classify a unilocular, anechoic cyst with small internal papillarities as “probably benign”.

In our study, all false negative results took place in the group of “probably benign” tumors evaluated in subjective ultrasound assessment. For the authors of this paper, these tumors are generally more complex than tumors from the previous group, however, they still give the impression of being benign ovarian tumors. For instance, we classify tumors of endometriotic cyst appearance to this group. Endometriomas are diagnosed with high accuracy by experienced examiners [17], however, in our study, a tumor of “endometrioma appearance” was the cause of inappropriate risk of assessing malignancy. The decision regarding laparoscopy in this case had to be revised and changed intraoperatively.

In our research, analysis was performed on two groups of patients, before and after menopause. We wanted to verify if hormonal ovarian activity is associated with risk of false negative results of preoperative ultrasound examination. The percentage of women incorrectly classified is 2.2% before menopause and is a little higher than in patients after menopause – 1.6%. This effect may be explained by the fact that more often subjective classification of tumors as benign is observed in women before menopause. But these values, in fact, are almost identical.

It is important to get more information about adnexal mass before surgery. Second-stage tests are very often indicated not only in the group of “difficult” tumors [9]. It may be a serum biomarker, morphological or Doppler ultrasonography index, any mathematical model or risk of malignancy calculator. In our group of patients, CA125 was assessed and in some cases it provided information that the tumor is more suspicious. In our group of postmenopausal women, CA125 also helped in verification of false negative results of ultrasonography. We also analyzed morphological and Doppler indices, as previously proposed in our center [5, 6]. They were also important for correct classification in preoperative assessment. In Doppler examination central vascularization was also assessed as the single most significant attribute in malignancy prediction. But second-stage tests are not always indicated there. After our analysis of this group of patients, we suggest using them also in the group of tumors assessed as “probably benign”. In paper presented by Smolen et al. there is a suggestion that a combination of ultrasound parameters and CA125 serum level in the predictive model improves diagnostic precision [18]. However, Valentin et al. have shown that adding the CA125 measurement to the ultrasonography assessment does not improve the accuracy of differential diagnosis of adnexal masses [19]. In the opinion of Valentin et al. logistic regression models similarly do not help in the group of adnexal masses which are difficult to correctly classify as malignant or benign. [20].

Conclusion

In conclusion, subjective ultrasound evaluation of adnexal masses has high specificity but even in the group of tumors considered benign in premenopausal as well as postmenopausal women, malignancy could be found. This occurs slightly more often in women before menopause. In this group other risk factors and additional tests should be evaluated before qualification for surgery.

Acknowledgements

Part of this article was presented as a poster for the 15th World Congress of Gynecological Endocrinology, Florence, March 7th - 10th, 2012

References

1. Goff B, Mandel L, Muntz H, Melancon C. Ovarian carcinoma diagnosis. *Cancer*. 2000, 89, 2068-2075.
2. du Bois A, Rochon J, Pfisterer J, Hoskins W. Variations in institutional infrastructure, physician specialization and experience, and outcome in ovarian cancer: a systematic review. *Gynecol Oncol*. 2009, 112, 422-436.
3. Timmerman D, Schwarzler P, Collins W, [et al.]. Subjective assessment of adnexal masses with the use of ultrasonography: an analysis of interobserver variability and experience. *Ultrasound Obstet Gynecol*. 1999, 13, 11-16.
4. Timmerman D, Valentin L, Bourne T, [et al.]. Terms, definitions and measurements to describe the sonographic features of adnexal tumors: a consensus opinion from the International Ovarian Tumor Analysis (IOTA) Group. *Ultrasound Obstet Gynecol*. 2000, 16, 500-505.
5. Szperek D, Moszynski R, Zietkowiak W, [et al.]. An ultrasonographic morphological index for prediction of ovarian tumor malignancy. *Eur J Gynaecol Oncol*. 2005, 26, 51-54.

Moszynski R, et al. Analysis of false negative results of subjective ultrasonography assessment of adnexal masses.

KOMUNIKAT

6. Szperek D, Moszynski R, Sajdak S. Clinical value of the ultrasound Doppler index in determination of ovarian tumor malignancy. *Eur J Gynaecol Oncol.* 2004, 25, 442-444.
7. Szczublewski P, Szperek D, Moszynski R, [et al.]. [Assessment of ultrasonography markers and CA125 usefulness in the diagnosis of ovarian cysts]. *Ginekol Pol.* 2008, 79, 856-861. Polish.
8. Sokalska A, Timmerman D, Testa A, [et al.]. Diagnostic accuracy of transvaginal ultrasound examination for assigning a specific diagnosis to adnexal masses. *Ultrasound Obstet Gynecol.* 2009, 34, 462-470.
9. Daemen A, Valentin L, Fruscio R, [et al.]. Improving the preoperative classification of adnexal masses as benign or malignant by second-stage tests. *Ultrasound Obstet Gynecol.* 2011, 37, 100-106.
10. Van Holsbeke C, Van Calster B, Testa A, [et al.]. Prospective internal validation of mathematical models to predict malignancy in adnexal masses: results from the international ovarian tumor analysis study. *Clin Cancer Res.* 2009, 15, 684-691.
11. Van Gorp T, Veldman J, Van Calster B, [et al.]. Subjective assessment by ultrasound is superior to the risk of malignancy index (RMI) or the risk of ovarian malignancy algorithm (ROMA) in discriminating benign from malignant adnexal masses. *Eur J Cancer.* 2012, 48, 1649-1656.
12. Valentin L, Ameye L, Jurkovic D, [et al.]. Which extrauterine pelvic masses are difficult to correctly classify as benign or malignant on the basis of ultrasound findings and is there a way of making a correct diagnosis? *Ultrasound Obstet Gynecol.* 2006, 27, 438-444.
13. Modesitt S, Pavlik E, Ueland F, [et al.]. Risk of malignancy in unilocular ovarian cystic tumors less than 10 centimeters in diameter. *Obstet Gynecol.* 2003, 102, 594-599.
14. Gramellini D, Fieni S, Sanapo L, [et al.]. Diagnostic accuracy of IOTA ultrasound morphology in the hands of less experienced sonographers. *Aust N Z J Obstet Gynaecol.* 2008, 48, 195-201.
15. Granberg S, Wikland M, Jansson I. Macroscopic characterization of ovarian tumors and the relation to the histological diagnosis: criteria to be used for ultrasound evaluation. *Gynecol Oncol.* 1989, 35, 139-144.
16. Timmerman D, Bourne T, Taylor A, [et al.]. A comparison of methods for preoperative discrimination between malignant and benign adnexal masses: the development of a new logistic regression model. *Am J Obstet Gynecol.* 1999, 181, 57-65.
17. Valentin L. Use of morphology to characterize and manage common adnexal masses. *Best Pract Res Clin Obstet Gynaecol.* 2004, 18, 71-89.
18. Smolen A, Stachowicz N, Czekierowski A, Kotarski J. [The estimation of the probability of tumor malignancy on the basis of test combination in the primary diagnosis of adnexal tumors]. *Ginekol Pol.* 2010, 81, 254-261. Polish.
19. Valentin L, Jurkovic D, Van Calster B, [et al.]. Adding a single CA 125 measurement to ultrasound imaging performed by an experienced examiner does not improve preoperative discrimination between benign and malignant adnexal masses. *Ultrasound Obstet Gynecol.* 2009, 34, 345-354.
20. Valentin L, Ameye L, Savelli L, [et al.]. Adnexal masses difficult to classify as benign or malignant using subjective assessment of gray-scale and Doppler ultrasound findings: logistic regression models do not help. *Ultrasound Obstet Gynecol.* 2011, 38, 456-465.



Polskie Towarzystwo Medycyny Perinatalnej

Uniwersytet Medyczny
im. Karola Marcinkowskiego w Poznaniu

VI KONGRES POLSKIEGO TOWARZYSTWA MEDYCYN PERINATALNEJ

MACIERZYŃSTWO NA POCZĄTKU XXI WIEKU

POZNAŃ 26-28 września 2013 r.



Główne tematy kongresu

- Quo vadis medicinae perinatalis?
- Ciężce cesarskie – wpływ na poziom opieki perinatalnej
- Otyłość a funkcje rozrodcze
- Endokrynologiczne aspekty porodu przedwczesnego
- Choroby o podłożu endokrynologicznym wiktające przebieg ciąży
- Późne wczesniactwo – gorący problem medycyny perinatalnej
- Operacje wewnątrzmaciczne
- Zakażenia w medycynie perinatalnej
- Problemy anestezjologiczne w położnictwie i neonatologii
- Sztuczna wentylacja – stan obecny i postępy
- Komórki macierzyste
- Zapobieganie i leczenie encefalopatii niedotleniowo-niedokrwiennej
- Późne i wczesne następstwa wczesniactwa
- System opieki perinatalnej w Polsce – postęp czy regresja?
- Wpływ używek na stan matki, płodu i dziecka

Szczegółowe informacje oraz
zgłoszenie uczestnictwa
www.ptmp.pl

SEKRETARIAT KONGRESU

Katedra i Klinika Perinatologii i Ginekologii
Katedra i Klinika Neonatologii
Uniwersytet Medyczny w Poznaniu
ul. Polna 33, 60-535 Poznań
tel.: (061) 65 99 283, (061) 65 99 270
faks: (061) 65 99 204
e-mail: sekretariat.kpig@gpsk.am.poznan.pl
<http://www.ptmp.pl>

Serdecznie zapraszamy

W imieniu Komitetu Organizacyjnego

Prof. dr hab.
Marta Szymankiewicz
Prezes Polskiego Towarzystwa Medycyny Perinatalnej

Prof. dr hab. Grzegorz H. Bręborowicz Prof. dr hab. Janusz Gadzinowski

Przewodniczący Komitetu Naukowego