

P R A C E O R Y G I N A L N E  
*ginekologia*

# Most of the patients with suburethral sling failure have tapes located outside the high-pressure zone of the urethra

Lokalizacja taśmy u pacjentek z niepowodzeniem leczenia wysiłkowego nietrzymania moczu za pomocą slingu podcewkowego

Michał Bogusiewicz<sup>1</sup>, Marta Monist<sup>1</sup>, Aleksandra Stankiewicz<sup>2</sup>, Magdalena Woźniak<sup>2</sup>,  
Andrzej Paweł Wiczorek<sup>2</sup>, Tomasz Rechberger<sup>1</sup>

<sup>1</sup> 2nd Department of Gynecology, Medical University of Lublin, Lublin, Poland

<sup>2</sup> Department of Pediatric Radiology University of Lublin, Lublin, Poland

## Abstract

**Objectives:** The high-pressure zone of the urethra (HPZ), which is crucial for the continence mechanism, extends between the point of the maximum urethral closure pressure and the urethral knee, and has been calculated to lie between 53% and 72% of the functional urethral length. According to recent studies the best results of suburethral slings are achieved when tapes are positioned under this zone. The aim of the study was to determine the location of tapes relative to the urethral length in patients seeking help due to recurrent stress urinary incontinence (SUI) following sling procedures.

**Material and methods:** The study group comprised 61 patients suffering from recurrent SUI following suburethral slings performed from 6 months to 5 years earlier. Forty-nine (80.3%) women were initially treated with a transobturator sling and 12 (19.7%) with a retropubic procedure. Twenty patients had the original sling performed at our department whereas the other 41 in other institutions. The position of the tapes was determined at the sagittal plane by 3-D transvaginal ultrasound using a linear transducer. The length of the urethra was measured from the bladder neck to the external urethral meatus following the urethral lumen, taking into account its curve. The position of the tapes relative to the percentage of the urethral length was calculated assuming the bladder neck as the proximal end of the urethra. The reference point was set at the midpoint on the tape.

**Results:** Only 13 (21.3%) patients had tapes positioned at 50%-75% of the urethral length. In 45 (73.8%) of women examined the tapes were found under proximal half of the urethra and in 3 (4.9%) distally to the 75% of the urethral length.

## Corresponding author:

Michał Bogusiewicz

2nd Department of Gynecology, Medical University of Lublin

Jaczewskiego 8, 20-954 Lublin, Poland

Phone: +48817244686; Fax: +48817244849

e-mail: [mbogusiewicz@yahoo.com](mailto:mbogusiewicz@yahoo.com)

Otrzymano: 18.12.2012

Zaakceptowano do druku: 10.04.2013

Michał Bogusiewicz et al. *Most of the patients with suburethral sling failure have tapes located outside the high-pressure zone of the urethra.*

**Conclusions:** *In most patients in whom slings procedures proved unsuccessful the tapes are located under the proximal half of the urethra, that is outside the HPZ. The position of a tape outside the HPZ may be considered as a cause of suburethral sling failure.*

Key words: **stress urinary incontinence / suburethral sling outcome / tape position / ultrasound /**

## Streszczenie

**Cel pracy:** *Badania ultrasonograficzne, oceniające położenie taśmy pod cewką moczową u pacjentek leczonych z powodu wysiłkowego nietrzymania moczu (WNM) za pomocą slingu podcewkowego wykazały, że najlepsze rezultaty obserwowane są w przypadku umiejscowienia taśmy pod odcinkiem cewki moczowej odpowiadającym strefie wysokiego ciśnienia (SWC). SWC rozciąga się pomiędzy punktem maksymalnego ciśnienia zamykającego cewkę moczową, a jej kolankiem i obejmuje odcinek pomiędzy 53% a 72% funkcjonalnej długości cewki moczowej. Celem pracy była ultrasonograficzna ocena położenia taśm podcewkowych u pacjentek z niepowodzeniami leczenia WNM.*

**Materiały i metody:** *Badaniem objęto 61 pacjentek po nieskutecznym leczeniu WNM za pomocą slingów podcewkowych. Zabiegi były wykonane od 6 miesięcy do 5 lat przed momentem badania ultrasonograficznego. Z dostępu przez otwory zasłonięte wykonano 49 zabiegów (80,3%), a 12 (19,7%) z dostępu załonowego. U 20 pacjentek wykonano zabiegi w II Klinice Ginekologii Uniwersytetu Medycznego w Lublinie, a 41 w innych ośrodkach. Położenie taśm oceniano za pomocą przezpochwowej ultrasonografii wykorzystując sondę liniową o częstotliwości 9-12 MHz. Po uzyskaniu trójwymiarowego obrazu mierzono długość cewki moczowej, w odniesieniu do której określano pozycję taśmy, przyjmując szyję pęcherza moczowego jako początek cewki.*

**Wyniki:** *Jedynie u 13 (21,3%) pacjentek taśmy były umiejscowione pomiędzy 50 a 75% długości cewki moczowej. U 45 (73,8%) pacjentek, taśmę uwidoczono pod proksymalną częścią cewki (poniżej 50% jej długości), a u 3 (4,9%) dystalnie do 75% długości cewki moczowej.*

**Wnioski:** *U większości pacjentek z niepowodzeniem leczenia WNM za pomocą slingów podcewkowych taśmy zlokalizowane są pod proksymalnym odcinkiem cewki moczowej, a więc poza SWC cewki. Dlatego rozważając przyczyny niepowodzenia zabiegów slingowych u pacjentek z nawrotem nietrzymania moczu należy brać pod uwagę nieprawidłowe położenie taśmy.*

Słowa kluczowe: **wysiłkowe nietrzymanie moczu / slingi podcewkowe / pozycja taśmy / badanie ultrasonograficzne /**

## Introduction

Urethral profile measurements and lateral urethrocystography have identified the section of the urethra, termed the high-pressure zone (HPZ) of the urethra, which is crucial for continence mechanism. It extends between the point of the maximum urethral closure pressure and the urethral knee, and has been calculated to lie between 53% and 72% of the functional urethral length, where the pubourethral ligaments attach. Placement of a tape close to the HPZ, that is under the middle section of the urethra, is currently the first-choice therapy for women with stress urinary incontinence (SUI) [1–3]. Ultrasound studies have shown that the best results of suburethral slings are achieved when tapes are positioned directly under the HPZ. Kociszewski et al. [4] showed that in the case of a tension-free vaginal tape (TVT) procedure the position of a tape between the 50% and 80% of the urethral length (measured from the bladder neck) ensures a cure rate exceeding 90%, whereas location outside this zone results in failure in more than one-third of patients. Another study carried out by the same authors revealed that tape location between 50% and 70% of the urethral length substantially increases the probability of the patient's being cured [5]. In line with these findings, it has been

shown that when a transobturator tape (TVT-O) is positioned under the proximal half of the urethra, the risk of procedure failure increases significantly [6,7].

Overall, these reports indicate that sling outcome is strongly related to tape location. Hence, we decided to evaluate the position of the tapes relative to the urethral length using 3-D transvaginal ultrasound in patients suffering from recurrent SUI after failed sling procedures.

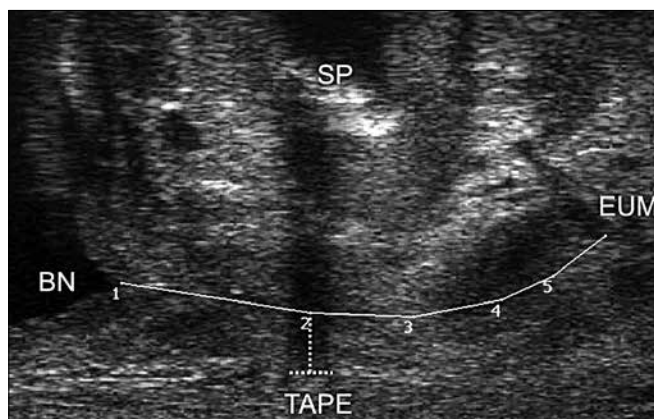
## Materials and methods

The study group comprised 61 patients admitted to the 2nd Department of Gynecology Medical University of Lublin, or attending the out-patient clinic owing to the failure of treatment with suburethral sling procedures. The patients underwent sling procedures between 2004 and 2010, that is from 6 months to 5 years earlier. In all the cases the recurrence of SUI was noted within six months after surgery. The age of the subjects ranged from 35 to 82 years (mean 60.0±9.9 years), BMI from 18.2 to 38.3 (mean 28.4±4.2) and parity from 0 to 5 (mean 2.4±1.1). All the women complained of SUI. The diagnosis was confirmed by physical examination and urodynamic studies. In 3 patients

Michał Bogusiewicz et al. Most of the patients with suburethral sling failure have tapes located outside the high-pressure zone of the urethra.

de novo urgency concomitant with permanent urine leakage developed shortly after the surgery. Forty-nine (80.3%) women were initially treated with a transobturator sling and 12 (19.7%) with a retropubic procedure. Twenty patients had the original sling performed at our department whereas, the other 41 in other institutions.

The position of the tapes was determined with a linear array of a biplane transducer, frequency range 9-12 MHz (type 8848, B-K Medical, Herlev, Denmark) using an ultrasound scanner ProFocus 2202 (B-K Medical, Herlev, Denmark). This equipment, as shown previously, makes it possible to obtain high-resolution 3-D images of the anterior compartment [8]. During examination the patient was recommended to have a comfortably full bladder and was placed in a dorsal lithotomy position. The transducer was inserted into the vagina in a neutral position with no compression on the urethral complex and surrounding structures. Three-dimensional acquisition was performed by the rotation of the transducer from the right side (9 o'clock position) to the left side (3 o'clock position) of the patient. 3-D volumes obtained were used for data analysis. The position of the tapes relative to the urethra was evaluated on the basis of the midsagittal view as shown in Figure 1.



**Figure 1.** Determination of the tape position by transvaginal ultrasound with a linear transducer. The tape position relative to the urethral length (UL) was calculated as a percentage of the UL measured from the bladder neck (BN) up to the external urethral meatus (EUM). The midpoint of the tape was set as the reference point.

The midsagittal plane is obtained when the lumen of the urethra was visualized along the entire length of the urethra, from the bladder neck to external urethral meatus. The reference point was set at the midpoint on the tape. The length of the urethra was measured from the bladder neck to the external urethral meatus following the urethral lumen, taking into account its curve. The position of the tapes relative to the percentage of the urethral length was calculated assuming the bladder neck as the proximal end of the urethra. Measurements were done independently by two investigators (M.B. and A.S.) and mean values were used for analysis. Test-retest reproducibility analysis and intraclass correlation coefficients of the parameters showed an excellent interobserver agreement  $r=0.96$ , (CI 95%, 0.85-1.08),  $r < 0.001$ .

The study was approved by the Ethical Committee of Medical University of Lublin (KE-0245/29/2008).

## Results

The tapes were easily visualized in all patients investigated. Typically, a tape was seen as a hyperechogenic area under the urethra. However, in some patients the tapes were poorly seen probably owing to the ingrowth of the connective tissue. In these cases acoustic shadow produced by the tape was helpful in the determination of tape location (Figure 2).

The median tape position was at 35.8 % of the urethral length. In 45 (73.8%) women the tapes were found under the proximal half of the urethra. Thirteen patients (21.3%) had the tapes positioned between the 50% and 75% of the urethral length, which corresponds to the high pressure zone of the urethra. In 3 (4.9%) patients the tape localized distally to the 75% of the urethral length.

In 2 out of 3 patients with de novo urgency tapes were found to lie near the bladder neck.

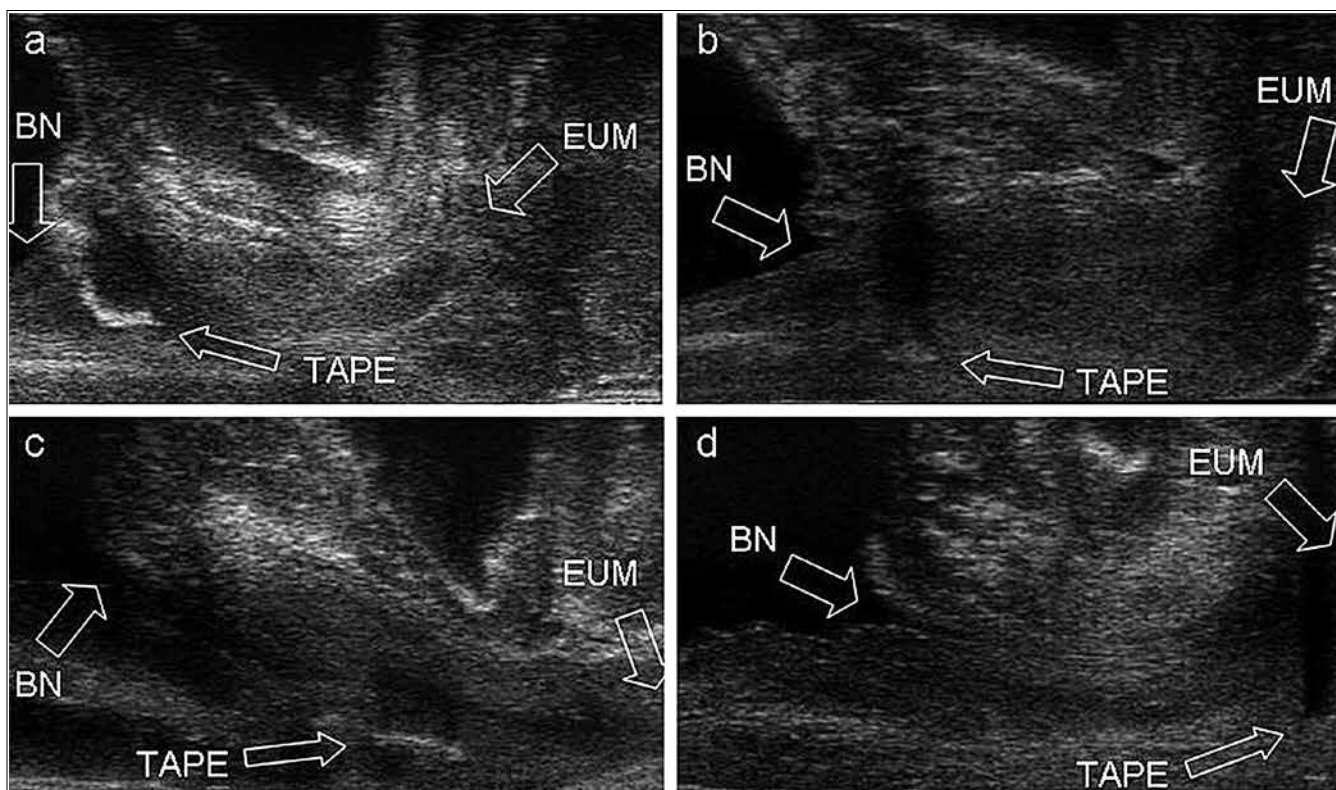
## Discussion

Despite a high cure rate of suburethral slings, approximately 10%-20% of patients remain refractory to this treatment [9-11]. Several reasons for sling failure, such as age, intrinsic sphincter deficiency, incontinence grade, concomitant or previous surgery and surgeon's experience, have been considered [12, 13, 14]. There is a growing body of evidence that failure of slings may be, to a large extent, related to an inadequate tape position [4, 7].

In this study we determined the positions of the tapes in patients with recurrent SUI following sling procedures. We found that in almost 80% of our patients tapes laid outside the high pressure zone of the urethra, mainly under its proximal half. Our observations support the idea that in many patients sling failure may be related to its proximal position. The exact mechanism of inadequate functioning of tapes in proximal location is not completely clear. According to the integral theory of urinary incontinence a tape is inserted to reinforce the weakened pubourethral ligaments, which, in turn enables the urethra to 'kink' during straining and restores continence [2]. This mechanism is crucial for a retropubic sling, whereas in the case of transobturator procedures urethral 'kinking' is observed only in 24-50% of cured patients [15-18]. The most probable anti-incontinence mechanism of transobturator sling is seen during ultrasound examination as a protrusion of the tape into the posterior wall of the urethra, with a transient narrowing of its lumen during straining, and is known as urethral encroachment by the tape. Thus, it may be only speculated that transobturator sling failure is related to other causes, such as restricted urethral mobility [18-19]. On the other hand, although tape position under the HPZ is likely to increase sling efficiency, it is clearly not necessary for successful treatment. Some studies did not show a relationship between tape position and treatment results [20, 21]. Ng et al. reported that among 31 women cured after TVT 67,7% had the TVT located under the middle one-third of the urethra, but 9.7% and 22.6% under the proximal one-third and distal one-third, respectively [22]. It has been suggested that continence may be restored even when a tape is located close to the bladder neck since a tape is likely to work as a traditional pubovaginal sling by suspending the bladder neck and proximal urethra [23].

Apart from negatively affecting the anti-incontinence action of the slings location of a tape close to the bladder neck may also predispose to de novo urgency. In 2 out of 3 patients who reported

Michał Bogusiewicz et al. Most of the patients with suburethral sling failure have tapes located outside the high-pressure zone of the urethra.



**Figure 2.** Different positions of the tapes in patients with suburethral sling failure.

- The tape located close to the bladder neck (BN), below the 25% of the urethral length. The failure of the transobturator sling in this patient was observed immediately after surgery. Moreover, de novo urgency developed within two months after surgery.
- The tape located under the proximal urethra between the 25% and 50% of the urethral length.
- The tape located between the 50% and 75% of the urethral length.
- The tape located close to the external urethral meatus (EUM), over the 75% of the urethral length. The tape itself is poorly seen probably owing to the ingrowth of the connective tissue. Acoustic shadow produced by the tape is helpful in the determination of the tape position.

de novo urgency, the tapes were found (as shown in Figure 2a.) under the bladder neck. A similar case was presented by Wang et al. [24]. The authors incised the tape, reapproximated and fixed under the midurethra. In our patients we decided to remove the 'old' tape and put a 'new' one by an outside-in transobturator route. Over one-year follow-up of this approach appears to be successful.

It is obvious that adequate tape positioning mainly depends on a proper surgical technique. However, the results of our previous study showed a significant variability of pelvis anatomy, which may substantially influence transobturator tape position. It is possible that in a subset of patients proximal tape positioning may occur despite the application of an appropriate surgical technique because of anatomical conditions [25]. To prevent tape displacement during final adjustment we introduced a modification consisting in the application of 2 additional sutures to the periurethral tissue 0.5 cm laterally on each side of the midurethra, and between 1.0 and 1.5 cm from the external urethral meatus, which fixate the tape at a proper position. According to our observations the fixation of the tape significantly increased the clinical efficacy of the transobturator sling, especially in patients with intrinsic sphincter deficiency [26].

Our study obviously has some limitations. The population investigated was relatively heterogeneous. Two thirds of our patients had the original slings performed outside our department. Thus, we had limited access to data regarding previous preoperative parameters, the technique used and the surgeon's experience. Obviously, we could not match a suitable control group to our patients. On the other hand, to the best of our knowledge, we have been able to analyze tape positions in the largest group of women with suburethral sling failure presented so far.

## Conclusion

The study showed that in most of the patients suffering from suburethral slings failure, the tapes are located under the proximal half of the urethra, outside its high-pressure zone. This factor should be considered as one of the reasons of suburethral sling failure.

## Acknowledgment

The study was supported by the Medical University of Lublin grant no 410

Michał Bogusiewicz et al. Most of the patients with suburethral sling failure have tapes located outside the high-pressure zone of the urethra.

## References

- Westby M, Asmussen M, Ulmsten U. Location of maximum intraurethral pressure related to urogenital diaphragm in the female subject as studied by simultaneous urethrocytometry and voiding urethrocytography. *Am J Obstet Gynecol.* 1982, 144, 408-412.
- Ulmsten U, Henriksson L, Johnson P, [et al.]. An ambulatory surgical procedure under local anesthesia for treatment of female urinary incontinence. *Int Urogynecol J.* 1996, 7, 81-86.
- Radziszewski P, Baranowski W, Nowak-Markwitz E, [et al.]. Expert panel recommendations on therapeutic and diagnostic management of urinary incontinence and overactive bladder in women. *Ginekol Pol.* 2010, 81, 789-793.
- Kociszewski J, Rautenberg O, Perucchini D, [et al.]. Tape Functionality: Sonographic tape characteristics and outcome after TVT incontinence surgery. *Neuroanal Urodynam.* 2008, 27, 485-490.
- Kociszewski J, Rautenberg O, Kuska A, [et al.]. Can we place tension-free vaginal tape where it should be? The one-third rule. *Ultrasound Obstet Gynecol.* 2012, 39, 210-214.
- Yang J, Yang S, Huang W. Correlation of morphological alterations and functional impairment of the tension-free vaginal tape obturator procedure. *J Urol.* 2009, 181, 211-218.
- Yang J, Yang S, Huang W, [et al.]. Correlation of tape location and tension with surgical outcome after transobturator suburethral tape procedures. *Ultrasound Obstet Gynecol.* 2012, 39, 458-465.
- Santoro G, Wiecek A, Stankiewicz A, [et al.]. High-resolution three-dimensional endovaginal ultrasonography in the assessment of pelvic floor anatomy: a preliminary study. *Int Urogynecol J Pelvic Floor Dysfunct.* 2009, 20, 1213-1222.
- Novara G, Ficarra V, Boscolo-Berto R, [et al.]. Tension-free midurethral slings in the treatment of female stress urinary incontinence: a systematic review and meta-analysis of randomized controlled trials of effectiveness. *Eur Urol.* 2007, 52, 663-678.
- Rechberger T, Futyma K, Miotta P, [et al.]. Changing trends in the surgical treatment of female stress urinary incontinence—twenty two years observation. *Ginekol Pol.* 2008, 79, 36-41.
- Rechberger T, Tomaszewski J, Adamiak A. Nietrzymanie moczu u kobiet – czy zawsze leczenie operacyjne? *Prz Menopauz.* 2005, 6, 45-49.
- Chen H, Yeh L, Chang W, [et al.]. Analysis of risk factors associated with surgical failure of inside-out transobturator vaginal tape for treating urodynamic stress incontinence. *Int Urogynecol J Pelvic Floor Dysfunct.* 2007, 18, 443-447.
- Cammu H, Van Den Abbeele E, [et al.]. Factors predictive of outcome in tension-free vaginal tape procedure for urinary stress incontinence in a teaching hospital. *Int Urogynecol J Pelvic Floor Dysfunct.* 2009, 20, 775-780.
- Paick J, Cho M, Oh S, [et al.]. Factors influencing the outcome of mid urethral sling procedures for female urinary incontinence. *J Urol.* 2007, 178, 985-989.
- Long C, Hsu C, Liu C, [et al.]. Clinical and ultrasonographic comparison of tension-free vaginal tape and transobturator tape procedure for the treatment of stress urinary incontinence. *J Minim Invasive Gynecol.* 2008, 15, 425-430.
- Long C, Hsu C, Lo T, [et al.]. Ultrasonographic assessment of tape location following tension-free vaginal tape and transobturator tape procedure. *Acta Obstet Gynecol Scand.* 2008, 87, 116-121.
- Foulot H, Uzan I, Chopin N, [et al.]. Monarc transobturator sling system for the treatment of female urinary stress incontinence: results of a postoperative transvaginal ultrasonography. *Int Urogynecol J Pelvic Floor Dysfunct.* 2007, 18, 857-867.
- Yang S, Huang W. Dynamic interaction involved in the tension-free vaginal tape obturator procedure. *J Urol.* 2008, 180, 2081-2087.
- Yang J, Yang S, Huang W. Correlation of morphological alterations and functional impairment of the tension-free vaginal tape obturator procedure. *J Urol.* 2009, 181, 211-218.
- de Tayrac R, Deffieux X, Resten A, [et al.]. A transvaginal ultrasound study comparing transobturator tape and tension-free vaginal tape after surgical treatment of female stress urinary incontinence. *Int Urogynecol J Pelvic Floor Dysfunct.* 2006, 17, 466-471.
- Dietz H, Mouritsen L, Ellis G, [et al.]. How important is TVT location? *Acta Obstet Gynecol Scand.* 2004, 83, 904-908.
- Ng C, Lee L, Han W. Use of three-dimensional ultrasound scan to assess the clinical importance of midurethral placement of the tension-free vaginal tape (TVT) for treatment of incontinence. *Int Urogynecol J.* 2005, 16, 220-225.
- Sarlos D, Kuronen M, Schaer G. How does tension-free vaginal tape correct stress incontinence? investigation by perineal ultrasound. *Int Urogynecol J Pelvic Floor Dysfunct.* 2003, 14, 395-398.
- Wang F, Song Y, Huang H. Which placement of the tension-free vaginal tape is more important for urinary continence: midurethral position or bladder neck? Consideration from a case report. *Int Urogynecol J Pelvic Floor Dysfunct.* 2009, 20, 1277-1279.
- Bogusiewicz M, Posińska-Bogusiewicz K, Drop A, [et al.]. Anatomical variation of bony pelvis from the viewpoint of transobturator sling placement for stress urinary incontinence. *Int Urogynecol J.* 2011, 22, 1005-1009.
- Rechberger T, Futyma K, Jankiewicz K, [et al.]. Tape fixation: an important surgical step to improve success rate of anti-incontinence surgery. *J Urol.* 2011, 18, 180-184.

KOMUNIKAT



International Society of Ultrasound  
in Obstetrics & Gynecology

Ultrasound Section of Polish Society of Gynecology

International Society of Ultrasound  
in Obstetrics & Gynecology – ISUOG

oraz

Sekcja USG PTG

zapraszają

w dniach **06-07.09.2013**

na Kurs

# Fetal malformation

prezentacja przypadków *live*,

tłumaczenia simultaniczne

Wykładowcy:

Członkowie ISUOG za całej Europy

Kierownik Kursu:

**Marek Dubiel (ISUOG – Polska)**

**Marek Pietryga (ISUOG – Polska)**

Miejsce obrad:

**Toruń**

Hotel Bulwar, ul. Bulwar Filadelfijski

Zgłoszenia

**www.regomed.pl**

tel. 663 064 000

Uczestnicy Kursu otrzymają certyfikat uczestnictwa  
International Society of Ultrasound  
in Obstetrics & Gynecology – ISUOG

oraz

30 punktów edukacyjnych USG PTG