

P R A C E K A Z U I S T Y C Z N E  
*ginekologia*

# Recurrent spontaneous ovarian hyperstimulation in a virgin girl

Nawracająca, spontaniczna hiperstymulacja jajników u dziewicy

Levent Şahin<sup>1</sup>, Ali Yavuzcan<sup>2</sup>

<sup>1</sup> Department of Obstetrics and Gynecology, Anadolu Hospital, Antalya, Turkey

<sup>2</sup> Department of Obstetrics and Gynecology, Bucak State Hospital, Burdur, Turkey

The authors have nothing to disclose.

## Abstract:

*Ovarian hyperstimulation syndrome (OHSS) develops due to the release of vasoactive mediators induced by excessively luteinized and enlarged ovaries. Most OHSS cases are iatrogenic subsequent to ovulation induction. We report the first case of recurrent OHSS developed during normal menstrual cycle in a virgin girl, diagnosed with ultrasonography and magnetic resonance imaging.*

Key words: **case reports / ovarian hyperstimulation syndrome / virginity /**

## Streszczenie

*Zespół hiperstymulacji jajników (OHSS) rozwija się w wyniku uwalniania czynników wazoaktywnych pod wpływem nadmiernie złuteinizowanych i powiększonych jajników. Większość przypadków OHSS rozwija się jatrogenie w wyniku indukcji jajczkowania. Opisujemy pierwszy przypadek nawracającego OHSS, który rozwinął się podczas normalnego cyklu miesięczkowego u dziewicy, zdiagnozowany ultrasonograficznie i przy pomocy rezonansu magnetycznego.*

Słowa kluczowe: **opis przypadku / zespół hiperstymulacji jajników /  
/ dziewictwo /**

## Correspondence to:

Ali Yavuzcan, Department of Obstetrics and Gynecology, Bucak State Hospital, Burdur  
15300 Bucak/BURDUR-TURKEY  
Tel: 0090 248 3251505  
Facsimile 0090 248 3251505  
Mobile : 00905326345431  
e-mail: draliyavuzcan@yahoo.com

Otrzymano: 15.05.2012  
Zaakceptowano do druku: 10.06.2013

## Introduction

Ovarian hyperstimulation syndrome (OHSS) develops due to the release of vasoactive mediators induced by excessively luteinized and enlarged ovaries. Historically, the mechanisms of ovarian hyperstimulation were explained either by exogenous follicle-stimulating hormone (FSH) during ovulation induction, or by stimulation of the FSH receptor by pregnancy-derived hCG [1]. Most OHSS cases are iatrogenic subsequent to ovulation induction. Spontaneous ovarian hyperstimulation were reported in normal pregnancy, hypothyroidism and polycystic ovary syndrome during pregnancy, and due to gonadotropin pituitary adenoma [2]. We report herein the first case of recurrent OHSS developed during normal menstrual cycle in a virgin girl, diagnosed with ultrasonography and magnetic resonance imaging.

## Case study

A 19-year-old virgin girl presented with the symptoms of abdominal pain and distention. Her medical and gynecological history were unremarkable: menarche occurred at the age of 11, and subsequent menses were regular. The abdomen was enlarged and had signs of ascites. The inspection of the vulvar area confirmed virginity. Chest X-ray showed blunting of costodiaphragmatic angle due to pleural effusion. Transabdominal ultrasonography showed massive ascites and innumerable bilateral ovarian multilocular cysts extending to the midabdomen (Fig. 1). The patient denied having taken any ovulation-inducing drugs. Abdominal magnetic resonance imaging (MRI) showed bilateral pleural effusions and massively enlarged multicystic structures of presumably bilateral ovarian origin, extending to the midabdomen (Fig. 2). Serum CA 125 antigen concentration was 53.30 U/mL (normal range: 1.7-32). Other cancer markers, such as AFP, CEA, CA 19-9, and CA 15-3 levels were within normal limits. Serum b-human chorionic gonadotropin (b-hCG) value was <1 mIU/mL. The estradiol (E2) concentration was 11880 pg/mL (normal range 4-180), and other hormones' levels were within the normal range. Pituitary MRI was normal. The symptoms were relieved with the menstruation. Oral contraceptive therapy was introduced.

The patient re-experienced similar but slightly milder symptoms after 4 months. Laboratory and ultrasonographic findings were similar. The E2 concentration was 10800 pg/mL at this time.

The third and most severe episode occurred two months after the second occurrence. The E2 concentration reached 21800 pg/mL, and there were electrolyte imbalance and increased kidney parameters present. Treatment included bed rest, close monitoring (blood pressure, pulse rate, urine output, hematocrit, electrolytes, coagulation profile), and fluid therapy. The patient was discharged after 25 days of hospitalization with complete resolution of the clinical picture and normalization of the laboratory parameters. Then, Zoladex was continued for a 6-months period for the prevention of ovarian cysts.

## Discussion

Ovarian hyperstimulation syndrome (OHSS) develops due to the release of vasoactive mediators induced by massively luteinized enlarged ovaries. Most cases are iatrogenic as related to ovulation induction. The underlying mechanisms of ovarian hyperstimulation were explained either by exogenous FSH

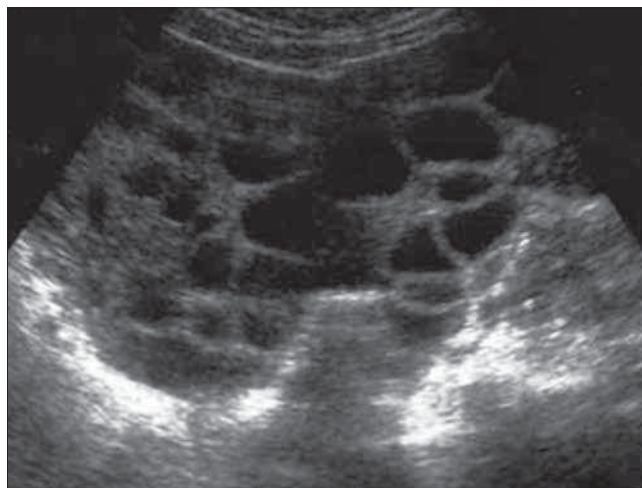


Figure 1. Transabdominal ultrasonographic image in a virgin girl.

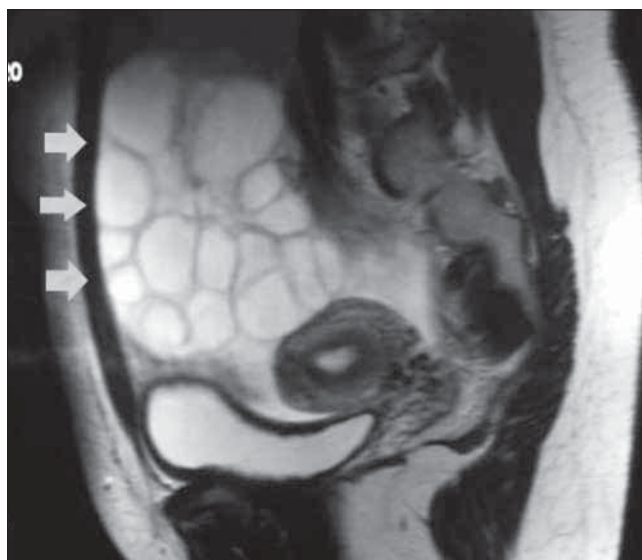


Figure 2. Cross-sectional abdominal magnetic resonance imaging of the patient.

provision in assisted reproductive technology, or stimulation of FSH receptor by pregnancy-derived hCG [1]. However, several genes and their respective protein products, including vascular endothelial growth factor, lactoferrin, and FSH receptors have been implicated in the pathogenesis of this disease [2].

Rare spontaneous ovarian hyperstimulation has been reported in normal pregnancy, polycystic ovary syndrome, and gonadotropin-producing adenoma. It was also associated with hypothyroidism in some cases [3, 4]. To our knowledge, there is no report of recurrent OHSS in a virgin in English literature.

Generally, imaging for the diagnosis, management, and monitoring of OHSS is performed by ultrasonography and color Doppler analysis. Other modalities, like computed tomography (CT) and MRI are seldomly used and are reserved for further evaluation of the pelvic mass. The main findings are multiple cystic enlargements of varied size in both ovaries, with the associated ascites. Unlike ovarian cystic neoplasms, such as

Levent Şahin, Ali Yavuzcan. *Recurrent spontaneous ovarian hyperstimulation in a virgin girl.*

mucinous or serous cystic tumors, in OHSS the ovarian stroma in the central part of the cysts gives a classic “wheel-spoke” appearance. Together with ascites, multiple cystic ovarian enlargements on CT and MRI should be considered characteristic findings of OHSS [5].

## Conclusions

The occurrence of spontaneous OHSS in a virgin girl is an extremely rare condition. Estradiol, pituitary MRI and thyroid function tests should always be carried out for differential diagnosis in the presence of giant multiple cystic ovaries. These measurements should allow early diagnosis of spontaneous OHSS.

## References

1. Borna S, Nasery A. Spontaneous ovarian hyperstimulation in a pregnant woman with hypothyroidism. *Fertil Steril.* 2007, 88, 705.e1-705.e3.
2. Kerkelä E, Skottman H, Friden B, [et al.]. Exclusion of coding-region mutations in luteinizing hormone and follicle-stimulating hormone receptor genes as the cause of ovarian hyperstimulation syndrome. *Fertil Steril.* 2007, 87, 603-606.
3. Cardoso C, Graça L, Dias T, [et al.]. Spontaneous ovarian hyperstimulation and primary hypothyroidism with a naturally conceived pregnancy. *Obstet Gynecol.* 1999, 93, 809-811.
4. Nappi R, Di Naro E, D'Aries A, Nappi L. Natural pregnancy in hypothyroid woman complicated by spontaneous ovarian hyperstimulation syndrome. *Am J Obstet Gynecol.* 1998, 178, 610-611.
5. Jung B, Kim H. Severe spontaneous ovarian hyperstimulation syndrome with MR findings. *J Comput Assist Tomogr.* 2001, 25, 215-217.