

P R A C E K A Z U I S T Y C Z N E
ginekologia

An atypical leiomyoadenomatoid tumor of the uterus – a case report and literature review

Atypowy guz gruczolakowaty macicy – opis przypadku i przegląd piśmiennictwa

Zuzanna Dobrosz¹, Piotr Paleń¹, Paweł Właszczuk¹, Rafał Stojko²

¹ Department of Histopathology, Medical University of Silesia, Katowice, Poland

² Department of Obstetrics and Gynecology, Medical University of Silesia, Katowice, Poland

Abstract

In this study, we describe morphological and immunohistochemical features of a mixed tumor (atypical leiomyoadenomatoid tumor – LMAT) localized in the body of the uterus.

Aim of study: LMAT-type tumors are very rare and only 5 cases have been described in the literature so far, therefore this case report seems particularly noteworthy.

Materials and methods: A 57-year-old patient was admitted to the Gynecology and Obstetrics Unit, Brothers of Mercy Hospital in Katowice for hysterectomy with bilateral salpingo-oophorectomy due to uterine myomata. The macroscopic examination of the surgical material revealed a polycystic tumor, 5 cm in diameter, with gelatinous contents and grey fibrous areas. The patient was discharged on postoperative day 4, in good general condition. A histological diagnosis of an atypical leiomyoadenomatoid tumor was established on the basis of the tissue material.

Key words: **atypia / leiomyoadenomatoid tumor / uterus /**

Streszczenie

Opisano morfologiczne i immunohistochemiczne cechy mieszanego guza (mięśniaka atypowego i guza gruczolakowatego) – atypical leiomyoadenomatoid tumor – LMAT zlokalizowanego w trzonie macicy.

Cel pracy: Guzy typu LMAT występują bardzo rzadko. Do tej pory w literaturze opisano 5 takich przypadków dlatego poniższy opis przypadku wart jest krótkiej analizy.

Corresponding author:

Zuzanna Dobrosz

Department of Histopathology, Medical University of Silesia, Medyków 14,
40-754 Katowice, Poland

phone: +48 32 25 25 080, fax: +48 32 25 25 080

e-mail: katpat2@slam.katowice.pl, dobrosz.zuza@vp.pl

Otrzymano: **12.12.2012**
Zaakceptowano do druku: **10.06.2013**

Zuzanna Dobrosz et al. An atypical leiomyoadenomatoid tumor of the uterus – a case report and literature review.

Materiał i metody: 57-letnia pacjentka została przyjęta do Oddziału Ginekologiczno-Położniczego Szpitala Zakonu Bonifratrów w Katowicach w celu usunięcia macicy z przydatkami z powodu mięśniaków. W materiale pooperacyjnym stwierdzono makroskopowo guz średnicy 5 cm o wielotorbielowatej strukturze z galaretowatą treścią oraz szarymi włóknistymi polami. Chora opuściła szpital w czwartej dobie po operacji, w stanie ogólnym dobrym. Na podstawie uzyskanego materiału tkankowego postawiono rozpoznanie histopatologiczne: atypical leiomyo-adenomatoid tumor.

Słowa kluczowe: **macica / atypia / LMAT /**

Introduction

Adenomatoid tumor (*mesothelioma benignum non papillare*) is a benign, mesothelium-derived neoplasm [1]. In men, it often arises in the epididymis and the spermatic cord, occasionally it is found in the vaginal coat of testes [2, 3]. In women, it is found in the Fallopian tubes and the uterine muscle as a small tumor, localized beneath the serous membrane, usually close to the horns of the uterus. Rare cases of this tumor in the ovarian hilus were described as well [4]. When these tumors occur in the uterus (particularly when localized intramuscularly), they are often accompanied by smooth muscles hyperplasia. Occasionally, adenomatous tumors contain necrotic areas that may indicate a beginning of a malignant process. When the smooth-muscle component of the tumor is significant in relation to the adenomatous component, and the tumor resembles a fragment of leiomyoma, it is called a *leiomyoadenomatoid tumor* (LMAT) [5]. Until now, only a few cases of this tumor localized in the uterine muscle have been described [5, 6, 7, 8].

Case report

A 57-year-old woman was admitted to hospital in March 2011 due to uterine myomas with history of pain in the hypogastric area. The ultrasound examination revealed the corpus of the uterus in anteflexion, with heterogeneous echogenicity, an intraparietal myoma, 5cm in diameter, the endometrium 5cm wide, normal adnexa. Medical history revealed the nodular goiter, colon polyps, arterial hypertension and crural varices.

Hysterectomy with bilateral adnexectomy was performed, the surgical material was sent for a histopathological examination. On the macroscopic examination, the uterus was 11 x 6 x 6 cm. In the posterior wall of the uterus, an intramuscular tumor of 5 cm in diameter was found. The tumor was polycystic, with gelatinous contents and grey fibrous areas. There were small cysts and polyps in the mucosa of the cervical canal.

The macroscopic examination revealed a uterine myoma and a small polyp of the mucosa of the cervical canal. 6 samples were taken from different regions of the tumor. The microscopic examination revealed hyperplastic bundles of smooth muscles mixed with cuboid and signet-ring-imitating cells, tube- and cyst-shaped structures lined with mesothelial cells. The smooth muscle cells were markedly polymorphic (enlarged nuclei, anisochromia and anisocytosis, polynuclear cells). (Figure 1).

Necrotic areas were not found. The number of cells in mitosis per 10 large fields of view was below 10. Therefore the smooth muscle component of the tumor was determined

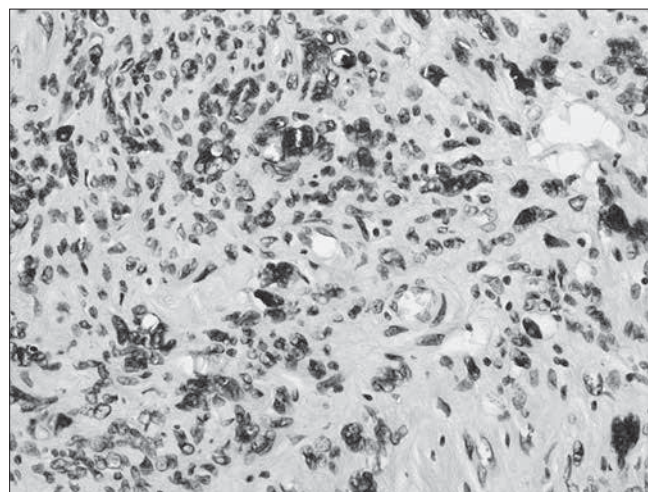


Figure 1. Polymorphic smooth muscle cells.

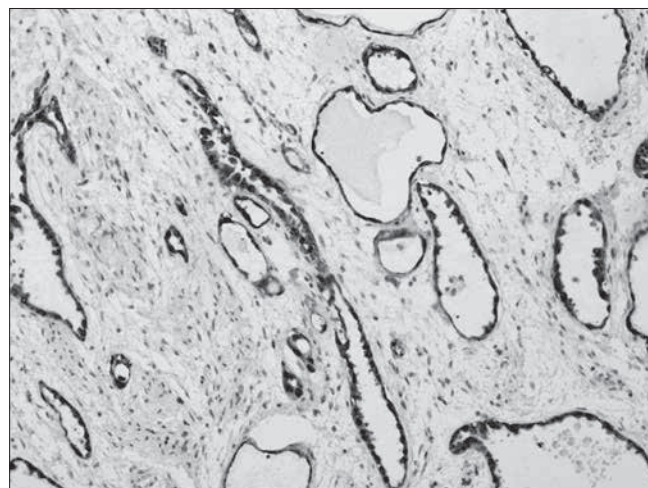


Figure 2. Calretinin positive response in adenomatous component

as an atypical (symplastic) myoma - *leiomyoma atypicum*, *leiomyoma symplasticum*, a tumor of fairly good prognosis and rare recurrences. To confirm the diagnosis, the following Immunohistochemical stains were performed: SMA, Vimentin, Aktin, Desmin - response (+) in smooth muscle cells, then Calretinin, CK-7 (+) in mesothelial cells. (Figure 2).

To rule out a possible vascular component, the following stains were made: CD-31, CD-34 (-) in mesothelial cells Ki-67 < 2%, CEA (-), CK-20 (-).

Discussion

Adenomatoid tumor was first described in 1925 when LW Strong reported a solitary lymphangioma of the Fallopian tube [9]. The mesothelial origin of this tumor was found by Masson and colleagues in 1942 [10]. His hypothesis was based on the observation of the microvilli on the surface of the epithelioid elements, similar to the microvilli observed on the surface of activated mesothelial cells. In 1953, Sundarasivaro suggested a Mullerian origin of this type of tumors – according to his theory, epithelioid structures forming pseudo-glandular structures and tumors localization implied that they were remnants of the Mullerian ducts [11]. On the other hand, other authors considered these tumors to be hematoma-type lesions (mesonephros remnants) [6]. Not until the immunohistochemical methods were introduced, were we allowed to exactly determine the origin of these tumors and to confirm Masson's hypothesis.

In the AT-type tumors, a unique phenomenon is observed: in the smooth muscle cells undergoing hyperplasia, the mitotic index (MI) is lower than in the surrounding smooth cells [12]. In our case, the MI was equally low in the tumor and in the surrounding uterine muscle.

The term 'leiomyoadenomatoid tumor' (LMAT) was first used by Epstein in 1992 for adenomatoid tumors with significant smooth muscle component. Some authors use the term *mesomyoma* [9].

Until now, only five case reports of LMAT have been published [5, 6, 7, 8, 13] – one of them localized in the epididymis, the remaining four in the wall of the uterus; one tumor was multifocal (with the focus in the right ovary), but none of them was described as an atypical LMAT. The case we present shows a biphasic nature of the lesion – mesothelial component is mixed with the smooth muscle component, it is distinctly delimited from the surrounding tissues – similarly as in the case described by Amerigo et al. [8]. The distinct delimitation of the tumor from the surrounding tissues and distinct atypia of the smooth muscle component seem to confirm the hypothesis that LMAT is an AT variant [14], originating from precursor cells that had undergone de-differentiation towards both the mesothelium and smooth muscle [13, 15], and is not, as some researchers maintain, a type of collision tumor [16], nor is it a uterine muscle hyperplasia, often accompanying the AT. The extra-uterine localization of LMATs (epididymis, ovary), where the smooth muscles are anatomically scarce, may imply a neoplastic derivation of smooth muscle in LMAT [8].

Differential diagnosis of LMATs should be based on immunohistochemical staining to exclude a possible vascular component – vascular leiomyoma [17], and possible adenocarcinoma component [18], due to signet ring cells which may be occasionally present in these tumors. Lack of atypical mitotic figures, negative staining for mucus (mucicarmine) as well as EMA (-) and CEA (-) confirm the LMAT diagnosis.

The prognosis in a LMAT is very good – it is a benign lesion. As far as an atypical LMAT is concerned, it is supposedly similar to that of an atypical leiomyoma [19].

References

1. Saminallat, MadhaSajjad, SajidHussain Shah. Adenomatoid tumour of Uterus. Case report. *Ann Pak Inst Med Sci*. 2008, 4, 240-241.
2. Kim J, Sung N, Chung D, [et al.]. Cystic adenomatoid tumour of the uterus. *Am J Roentgenol*. 2002, 179, 1068-1070.
3. Leaha C, Opris I, Mace P, [et al.]. Cystic adenomatoid tumour of the uterus. *Ann Pathol*. 2009, 29, 134-137.
4. Bolat F, Kocer N, Bal N, Kucukgoz U. Adenomatoid tumour of the female genital tract: Report of three cases. *Turk J Pathol*. 2007, 23, 98-102.
5. Hong R, Choi D, Choi S, [et al.]. Multicentric infarcted leiomyoadenomatoid tumour: a case report. *Int J Clin Exp Pathol*. 2009, 2, 99-103.
6. Erra S, Pastormerlo M, Gregori G, [et al.]. A case of leiomyoadenomatoid tumour of uterine serosa: speculations about differential diagnosis. *BMJ Case Reports*. 2009, May 25.
7. Kausch I, Galle J, Buttner H, [et al.]. Leiomyo-adenomatoid tumour of the epididymis. *J Urol*. 2002, 168, 636.
8. Amerigo J, Amerigo-Gongora M, Gimenez-Pizarro A, [et al.]. Leiomyo-adenomatoid tumour of the uterus: a distinct morphological entity. *Arch Gynecol Obstet*. 2010, 282, 451-454.
9. Strong L. Lymphangioma of the fallopian tube. *Am J Obst Gynaecol*. 1925, 10, 853-855.
10. Masson P, Riopelle J, Simard L. Le mesothelioma benin de la sphere genitale (in French). *Rev Canad Biol*. 1942, 1, 720-751.
11. Sundarasivaro D. The Mullerian vestiges and benign epithelial tumours of the epididymis. *J Pathol Bacteriol*. 1953, 66, 417-432.
12. Nogales F, Isaac M, Hardisson D, [et al.]. Adenomatoid tumours of the uterus; an analysis of 60 cases. *Int J Gynecol Pathol*. 2002, 21, 34-40.
13. Amre R, Constantino J, Lu S, Charney D. Pathologic quiz case: a 52-year-old woman with a uterine mass. Leiomyo-adenomatoid tumour of the uterus. *Arch Pathol Lab Med*. 2005, 129, 77-78.
14. Chmaj-Wierzchowska K, Buks J, Wierzchowski M, Szymanowski K, Opala T. Mięśniak komórkowy w więzadle szerokim macicy – opis sytuacji klinicznej i przegląd piśmiennictwa. *Ginekol Pol*. 2012; 83, 301-304.
15. Mazur M, Kraus F. Histogenesis of morphologic variations in tumours of the uterine wall. *Am J Surgpathol*. 1980, 4, 59-74.
16. Quigley J, Hart W. Adenomatoid tumours of the uterus. *Am J Clin Pathol*. 1981, 76, 627-635.
17. Bell D, Flotte T. Factor VIII related antigen in adenomatoid tumours: implications for histogenesis. *Cancer*. 1982, 50, 932-938.
18. Stephenson T, Mills P. Adenomatoid tumours: an immunohistochemical and ultrastructural appraisal of their histogenesis. *J Pathol*. 1986, 148, 327-335.
19. Dańska-Bidzińska A, Bakula-Zalewska E, Nasierowska-Guttmajer A, [et al.]. Smooth muscle tumor of uncertain malignant potential (STUMP) – clinico-pathomorphological analysis of the cases and literature review. *Ginekol Pol*. 2012, 83, 412-416.