

# Ocular manifestations in a newborn from a pregnancy complicated by an antiphospholipid syndrome – a case report

Objawy oczne u noworodka urodzonego z ciąży powikłanej zespołem antyfosfolipidowym – opis przypadku

Monika Modrzejewska<sup>1</sup>, Anna Michalak<sup>1</sup>, Olimpia Szmigiel<sup>2</sup>, Lidia Ostanek<sup>3</sup>,  
Elżbieta Ronin-Walknowska<sup>4</sup>, Wojciech Lubiński<sup>1</sup>

<sup>1</sup> Department of Ophthalmology, Pomeranian Medical University, Szczecin, Poland

<sup>2</sup> Chair of Obstetrics and Gynecology, Department of Feto-Maternal Medicine and Gynecology, Pomeranian Medical University, Police, Poland

<sup>3</sup> Department of Rheumatology, Pomeranian Medical University, Szczecin, Poland

<sup>4</sup> Chair of Obstetrics and Gynecology, Department of Feto-Maternal Medicine and Gynecology, Pomeranian Medical University (do 2009 r., Police, Poland)

## Abstract

*The paper presents a case of ophthalmologic manifestations, episcleritis and retinal branch vein thrombosis, in a neonate born to a mother with antiphospholipid syndrome (APS) in the course of systemic lupus erythematosus. Female neonate (birth weight 1150 g, Apgar scores 6, 7 and 7) was born with respiratory distress syndrome, moderate anemia and grades I and II intraventricular hemorrhage. Ophthalmic examination revealed an enormous pre-retinal hemorrhage with accompanying thrombotic changes typical of retinal vein in the fundus of the left eye.*

*Episcleritis was found in the anterior segment of the eye and later confirmed by ultrasound.*

*Laboratory tests showed increased levels of maternal antibodies aCL IgG, antyβ2GP1 IgG and antyβ2GP1 IgM.*

*No ANA, LA and SS-A/SS-B antibodies were detected. Increased concentrations of aCL IgG and a lengthening APTT were observed in newborn blood at first but the parameters normalized by 6 months of age.*

*Our observations allowed us to conclude that early examination of neonates born to mothers with antiphospholipid syndrome is essential as it allows fast identification of pathological retinal changes by means of assessing the presence of aPL antibodies.*

Key words: **antiphospholipid antibodies / connective tissue disorders / complications pregnancy / newborn / episcleritis / retinal branch vein thrombosis / thrombosis risk factors /**

## Corresponding author:

Monika Modrzejewska  
Department of Ophthalmology, Pomeranian Medical University,  
Powst. Wlkp. 72, 70 111 Szczecin, Poland  
phone: +48 91 4661284  
e-mail: monika\_modrzej@op.pl

Otrzymano: 05.10.2012  
Zaakceptowano do druku: 10.09.2013

Monika Modrzejewska, et al. *Ocular manifestations in a newborn from a pregnancy complicated by an antiphospholipid syndrome – a case report.*

## Streszczenie

Praca przedstawia przypadek wystąpienia zmian okulistycznych pod postacią zapalenia nadtwardówki i zakrzepicy żyłnej siatkówki oka u noworodka urodzonego przez matkę z zespołem antyfosfolipidowym (APS) w przebiegu tocznia rumieniowatego układowego.

Noworodek płci żeńskiej o masie ciała 1150g oceniany w skali Apgar na 6, 7, 7 punktów, urodzony z zespołem zaburzeń oddechowych, umiarkowaną niedokrwistością oraz z krwawieniem okołokomorowym I i II stopnia. W badaniu okulistycznym na dzień oka lewego stwierdzono znacznych rozmiarów przedsiatkówkowy wylew krwi z towarzyszącymi zmianami zakrzepowymi dla zakrzepu naczyń żylnych siatkówki. W przednim odcinku oka stwierdzono zapalenie nadtwardówki, co potwierdzono w badaniu ultrasonograficznym. W badaniach laboratoryjnych u matki wykazano podwyższenie miana przeciwciał aCL IgG, antyβ2GPI IgG i antyβ2GPI IgM. Nie stwierdzono obecności ANA, LA oraz przeciwciał SS-A/SS-B. We krwi noworodka obserwowano wzrost stężenia miana przeciwciał aCL IgG i wydłużenie czasu APTT – normalizacja tych parametrów nastąpiła w szóstym miesiącu życia dziecka.

Poczynione obserwacje wskazują iż u noworodka urodzonego z ciąży powikłanej zespołem antyfosfolipidowym, celem szybkiego rozpoznania chorobowych zmian w siatkówce wskazane jest wczesne badanie okulistyczne z oceną obecności przeciwciał aPL.

Słowa kluczowe: **przeciwciała antyfosfolipidowe / choroby tkanki łącznej / ciąża / powikłania / noworodek / zapalenie nadtwardówki / zakrzepica żylna siatkówki / czynniki ryzyka / zakrzepica /**

### Abbreviations:

ANA – antinuclear antibodies,  
aCL – anticardiolipin antibodies,  
aβ2GPI – anti-beta2glycoprotein I antibodies,  
LA – lupus anticoagulant,  
anti-dsDNA – anti-double stranded DNA antibodies,  
anti-ssDNA – anti-single stranded DNA antibodies,  
aPL – antiphospholipid antibodies,  
anti-Ro/SSA and anti-La antibodies – antibodies against extractable nuclear antigens,  
ET-1 – endothelin-1

## Introduction

Numerous studies have shown that pregnancy in women with connective tissue disorders, such as systemic lupus erythematosus (SLE) or SLE-related antiphospholipid syndrome (APS), can reactivate these diseases and increase the complications in several different organs [1-6]. The pathophysiological basis of connective tissue disorders is caused by a decrease or loss of tolerance for auto-antigens, and production of antibodies directed against them [1].

The most common ocular symptoms described in adults with systemic connective tissue disorders, including SLE, are: keratoconjunctivitis, episcleritis, pre-retinal hemorrhages, retinal vasculitis, retinal artery or vein occlusion with retinal edema, ischemia, hard exudates, and cotton-wool-spots [6, 7]. Among the immunological prothrombotic risk factors, the key indicator is the presence of aPL, especially aCL and aβ2GPI [1, 2]. The V Leiden factor and hypercoagulability also increase the risk of thromboembolic complications [6-10]. Ophthalmologic manifestations are caused not only by immunological agents but also by endothelial dysfunction, especially the increase of intraendothelial ET-1 [11].

Various authors have suggested the possibility of transplacental transfer of maternal antibodies, detected in blood samples of neonates born to mothers with SLE or APS. This phenomenon could cause immunological complications such as retinal thrombotic lesions [1-3, 6-12]. Literature review yielded no data in regards to ophthalmologic symptoms diagnosed in neonates from pregnancies complicated by maternal connective tissue disorders. To the best of our knowledge, this is the first report of recurrent episcleritis and retinal branch vein thrombosis in one-month old neonate.

## Case report

Female infant (birth weight 1150g, Apgar scores 6, 7 and 7) was born with respiratory distress syndrome, moderate anemia, grades I and II intraventricular hemorrhage. Manifestations of episcleritis and an enormous pre-retinal hemorrhage with accompanying thrombotic changes typical of retinal vein occlusion were observed in the left eye. (Figure 1).

Indirect ophthalmologic examination (eye-fundus visualization by Ret-Cam II method; Clarity Medical Systems) confirmed the above mentioned lesions and excluded retinopathy of prematurity (ROP). Additionally, a hyperechogenic region corresponding to the described changes was detected in B-mode ultrasonography (US-3300 EchoScan ultrasonic B – scan with 10-MHz sector probe equipment – Nidek Co. Japan) [13]. Local treatment was applied (reabsorbing and capillary stabilizing drops) and resulted in ocular improvement within a three-month period. (Figure 2).

Blood sample analysis, performed within the first month of neonatal life, revealed a higher titer of aCL IgG (33.3 GPL U/ml; norm <12.0), prolonged APTT (42.3 s; norm: 23.0-37.0 s), and a negative LA test. The titer of aCL IgM and aβ2GPI was within the range. Furthermore, examinations of serum showed a gradual

Monika Modrzejewska, et al. *Ocular manifestations in a newborn from a pregnancy complicated by an antiphospholipid syndrome – a case report.*

decrease in the marked antibody titers, which were undetected after six months.

The newborn's mother, 35 year-old nullipara, was referred to the Department of Feto-Maternal Medicine and Gynecology in the 31<sup>st</sup> week of gestation due to high arterial blood pressure and proteinemia. Her medical history revealed migraines, signs of the Reynaud's syndrome and intermittent joint pain with edema. Vein thrombosis of the lower limbs and recurrent pulmonary emboli were present in the family anamnesis. Laboratory tests showed elevated protein nitrogen (urea: 42 mmol/L), creatinine (99.9 µmol/L), LDH (878 U/L), transaminases (ALT 54 U/l, AST 52 U/l), D-dimers (31.1 nmol/L) and proteinemia (50-127.1 g/L). Blood plasma analysis revealed high titers of aCL IgG (>120 GPL U/ml; norm <12.0), aβ2GPI IgG (230 RU/ml; norm <20.0), and aβ2GPI IgM (27.4 RU/ml; norm <20). ANA, LA and SS-A/SS-B antibodies were not detected. Due to abnormality of lab tests and clinical symptoms, preeclampsia with the beginning of HELLP syndrome was suspected as APS. Owing to the ineffectiveness of the anti-hypertensive treatment, a cesarean delivery at 31 weeks of gestation was indicated.

## Discussion

Ocular manifestations in newborns delivered from pregnancy complicated by connective tissue disorders have not been described in the available literature so far. In the aforementioned case of the female newborn, the vascular retinal manifestation in the form of branch vein thrombosis and episcleritis was most likely caused by maternal primary APS. According to some authors, the presence of ocular symptoms in neonates can be associated with trans-placental aPL IgG transfer, which depends on the structure, titer and affinity of antibody, and the placement of antigens against whom circulating antibodies are directed [10]. Many observations suggest that the aPL antibodies (aCL and LA) are responsible for the ocular manifestations, especially the retinal vein thrombosis in APS. In these cases, aCL antibodies were detected in the sera of both the mother and the child. This finding confirmed earlier suggestions that aPL antibodies are not only the main risk factor of the retinal thrombosis in the eye, but also the evidence for trans-placental transfer and increased disease activity [1, 10, 14, 15]. Preeclampsia, intrauterine growth restriction (IUGR), asphyxia, presence of catheter, cardiac disease, prenatal trauma, genetic mutation of factor V (Leiden), prothrombin G 20210A mutation, methyltetrahydrofolate reductase MTHFR C677T and A1298C mutations, decreased levels of protein C and S, antithrombin III, sepsis, infections, polycythemia, dehydration, increased level of lipoprotein (a), maternal diabetes and drug abuse, besides the aCL circulated antibodies, are among different prothrombotic risk factors that were mentioned above [7-9, 14, 15]. Preterm delivery, respiratory insufficiency, anemia and grades I and II intraventricular hemorrhage, all of which were observed in the discussed case, might be the novel factors influencing the appearance of retinal lesions that have not been described in the medical literature so far.

In conclusion, early ophthalmologic screening with the detection of aPL antibodies is recommended to be performed in neonates born to mothers with connective tissue disorders.

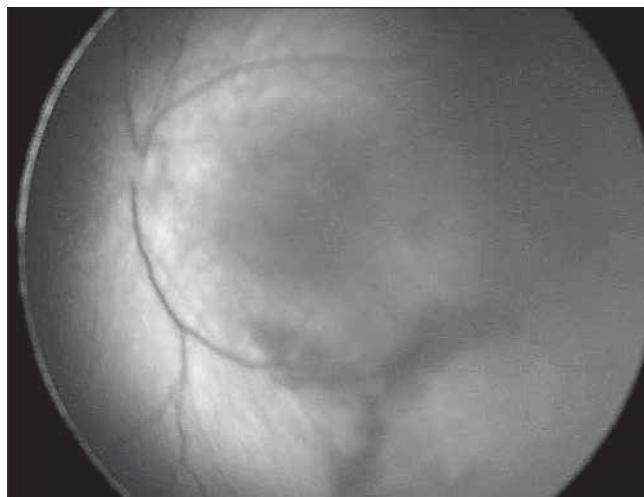


Figure 1. Thrombosis of the inferior temporal branch of the retinal vein.

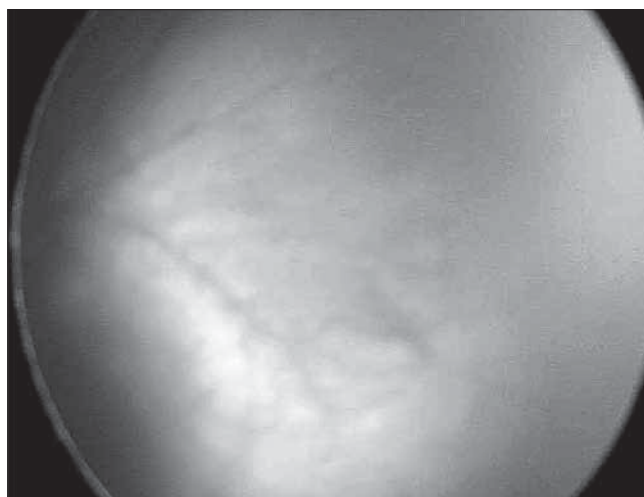


Figure 2. Stabilization of the retinal lesions after topical treatment.

The authors report no financial or other conflict of interest relevant to the subject of this article.

### Oświadczenie autorów:

1. Monika Modrzejewska 50% – autor koncepcji i założeń, wykonawca badania okulistycznego, autor analizy i interpretacji danych, główny udział w tworzeniu pracy – autor zgłaszający – odpowiedzialny za manuskrypt.
2. Anna Michalak 10% – współautor protokołu okulistycznego, wyszukiwanie literatury.
3. Olimpia Szmigiel 20% – współautor tekstu pracy, współautor protokołu położniczego, korekta i aktualizacja literatury.
4. Lidia Ostanek 10% – współautor protokołu reumatologicznego, korekta pracy ukierunkowana na APS, nadzór nad wykonaniem badań laboratoryjnych w kierunku APS.
5. Elżbieta Ronin-Walknowska 5% - korekta pracy ukierunkowana na położnictwo.
6. Wojciech Lubiński 5% - nadzór nad końcowym układem pracy.

Monika Modrzejewska, et al. *Ocular manifestations in a newborn from a pregnancy complicated by an antiphospholipid syndrome – a case report.*

KOMUNIKAT

Źródło finansowania: brak wkładu jakichkolwiek instytucji badawczych, stowarzyszeń i innych podmiotów w finansowanie tego doniesienia.

## References

1. Jopek A, Szczapa J. Newborn of mother with antiphospholipid syndrome. *Adv Neonatol.* 2006, 9, 40-44.
2. Ticani A, Bompane D, Danieli E, Doria A. Pregnancy, lupus and antiphospholipid syndrome (Hughes syndrome). *Lupus.* 2006, 15, 156-160.
3. Kornacka M, Bokinić R. Newborn from mother with antiphospholipid syndrome. *Pol Arch Int Med.* 2006, 5, 467-470.
4. Lorenc A, Seremak-Mrozinkiewicz A, Drews K, [et al.]. Opis przypadku nasilonego zespołu antyfosfolipidowego w przebiegu ciąży i porodu z podejrzeniem zespołu toczniopodobnego. *Ginekol Pol.* 2011, 82, 297-303.
5. Modrzejewska M, Ostanek L, Bobrowska-Snarska D, [et al.]. Ocular circulation in systemic lupus erythematosus. *Med Sci Monit.* 2009, 15, 11, CR573-578.
6. Sobocki R, Korporowicz D, Terpińska-Pakuła D. Ophthalmic sings in antiphospholipid syndrome. Patient description. *Acta Ophthalmol Pol.* 2004, 106, 661-663.
7. Boffa M, Lachassinne E. Infant perinatal thrombosis and antiphospholipid antibodies: a review. *Lupus.* 2007, 16, 634-641.
8. Soares Rolim A, Castro M, Santiago M. Neonatal antiphospholipid syndrome. *Lupus.* 2006, 15, 301-303.
9. Curry C, Bhullar S, Holmes J, [et al.]. Risk factors for perinatal arterial stroke: a study of 60 mother-child pairs. *Pediatr Neurol.* 2007, 37, 99-107.
10. Tuohy J, Harrison A. Prenatal transfer of anticardiolipin antibodies associated with fatal neonatal aortic thrombosis. *Aust N Z J Obstet Gynaecol.* 2005, 45, 175-176.
11. Yoshio T, Masuyama J, Mimori A, [et al.]. Endothelin-1 release from cultured cells induced by sera from patients with systemic lupus erythematosus. *Ann Rheum Dis.* 1995, 54, 361-365.
12. Boffa M, Auroseau M, Lachassinne E, [et al.]. European register of babies born to mothers with antiphospholipid syndrome. *Lupus.* 2004, 13, 713-717.
13. Modrzejewska M, Karczewicz D, Wilk G. Ultrasound diagnostics in pediatric ophthalmology. *Ultrasonography.* 2006, 26, 41-47.
14. Lynch J, Han ChJ, Nee L, Nelson K. Prothrombotic factors in children with stroke or porencephaly. *Pediatrics.* 2005, 116, 447-453.
15. Motta M, Lachassinne E, Boffa M, [et al.]. European registry of infants born to mothers with antiphospholipid syndrome: preliminary results. *Minerva Pediatr.* 2010, 62, 25-27.

Klinika Ginekologii Operacyjnej i Onkologicznej  
I Katedra Ginekologii i Położnictwa  
Uniwersytetu Medycznego w Łodzi

oraz

Centrum Medyczne „Być kobietą ...”

mają zaszczyt zaprosić na

Kursy uroginekologiczne

UTRASONOGRAFIA  
UROGINEKOLOGICZNA

(ang. PELVIC FLOOR SONOGRAPHY)

cz. I i II

NOWOCZESNA  
PESSAROTERAPIA29-30 listopada 2013 (pt. i sob.)  
Łódź

Zaproszony wykładowca z Niemiec:

Chefarzt dr med. J. Kociszewski

Ausbildungsklinik für rekonstruktive  
Beckenboden-Chirurgie; Qualifikation AGUB III,  
Schulungszentrum für urogynäkologische Sonographie,  
Zertifiziertes Kontinenzzentrum Hagen - Witten

Tematyka kursu:

- **usg miednicy mniejszej z wykorzystaniem głowicy przezochovej 2D:**
  - diagnostyka przed terapią zachowawczą i operacyjną
  - planowanie zabiegu z wykorzystaniem badania usg
  - diagnostyka po nieudanych zabiegach w zakresie przyczyn niepowodzeń i powikłań
  - **optymalizacja doboru operacji**
- **praktyczne aspekty nowoczesnej pessaroterapii** stosowanej tylko na dzień: indywidualny dobór rodzaju i rozmiaru

Szczegółowe informacje:

[www.uroginekologia.info.pl](http://www.uroginekologia.info.pl)

Zgłoszenia uczestnictwa:

[uroginekologia@gmail.com](mailto:uroginekologia@gmail.com)

(ograniczona liczba miejsc!)

W imieniu Komitetu Organizacyjnego:

prof. dr hab. med. J. Suzin

Koordynator:

dr n. med. Edyta Właziłak

tel. 0- 502 626 675

dr n. med. Grzegorz Surkont

tel. 0- 501 587 964