

Prenatal diagnosis of Langer-Giedion Syndrome confirmed by BACs-on-Beads technique

Prenatalna diagnoza zespołu Langer-Giediona metodą BACs-on-Beads

Krzysztof Piotrowski¹, Wojciech Halec², Jerzy Węgrzynowski², Aleksandra Pietrzyk¹, Małgorzata Henkelman¹, Stanisław Zajączek¹

¹ Unit of Cytogenetics, Department of Pathology, Pomeranian Medical University, Szczecin, Poland

² Department of Obstetrics and Gynecology "Zdroje", Szczecin, Poland

Abstract

Langer-Giedion Syndrome (LGS), with characteristic phenotypic features including craniofacial dysmorphic signs, postnatal growth retardation and skeletal abnormalities, mental impairment, urogenital malformations and heart defects, is caused by partial deletions of the long arm of chromosome 8.

We present a case of a female fetus with LGS. The diagnosis was molecularly proven with the BACs on Beads™ method at 32 weeks of gestation. To the best of our knowledge, prenatal recognition of that genetic defect had previously been made in only one case. Also, it has never been described before.

Słowa kluczowe: **LGS / prenatal diagnosis / molecular methods / BACs-on-Beads /**

Streszczenie

Zespół Langer-Giediona (LGS) jest spowodowany mikrodelecją w obrębie długiego ramienia chromosomu 8. Na różnorodny pourodzeniowy fenotyp zespołu składają się: charakterystyczne dysmorfie twarzy, zahamowanie wzrostu z deformacjami układu kostnego, dysfunkcją umysłową, zaburzenia układu moczowo-płciowego i wady serca.

Prezentujemy przypadek żeńskiego płodu z LGS, zdiagnozowanego prenatalnie w 32 tygodniu ciąży za pomocą metody cytogenetyki molekularnej BACS-on-Beads. W dostępnej nam literaturze znaleziono jedynie jeden przypadek zdiagnozowany prenatalnie, jednak po raz pierwszy opisujemy diagnostykę tego zespołu z zastosowaniem wymienionej metody.

Słowa kluczowe: **LGS / diagnostyka prenatalna / metody molekularne / BACs-on-Beads /**

Corresponding author:

Krzysztof Piotrowski,
Unit of Cytogenetics, Department of Pathology, Pomeranian Medical University, Szczecin, Poland,
ul. Polabska 4, 70-115 Szczecin.
Tel/fax 91 466 15 65, email: kjp@onet.pl

Otrzymano: **23.05.2013**
Zaakceptowano do druku: **15.09.2013**

Introduction

Langer-Giedion Syndrome (LGS), also called the tricho-rhino-phalangeal syndrome type II (TRPS2), occurs most frequently due to *de novo* mutations of adjacent genes syndrome resulting from a microdeletion at 8q24.1 that encompasses a set of genes, most importantly TRPS1 and EXT1 genes.^{1,2,3,4}

A typical TRPS II deletion phenotype is mainly a mixed consequence of TRPS1 and EXT1, and some other genes. The EXT1 gene deletion causes the characteristic exostoses.⁵ Moreover, the skeletal findings in Langer-Giedion syndrome have a wide clinical spectrum, including short stature, brachy- and clinodactyly, short: metacarpals, metatarsals or phalanges, cone-shaped epiphyses of the middle and proximal phalanges, eburnated epiphyses of distal phalanges, scoliosis, lordosis, hyperextensible joints, and syndactyly. Consequences of the lack of one of the genes encompass sparse scalp hair, medially thick and laterally thin eyebrows, bulbous tip of the nose, and long flat philtrum. TRPS1 allele also involve facial dysmorphism, including thin upper lip with vermilion border, protruding ears, deep-set eyes, or broad nasal bridge, as well as slow growth.^{6,7,8,9} Mental impairments, delayed speech development, conductive hearing loss are often observed. The latter symptoms do not occur in tricho- rhino- phalangeal syndrome types I and III. Other clinical manifestations of TRPS II that have been described include microcephaly, increased susceptibility to recurrent respiratory and urinary infections.^{1,10}

Postnatal diagnosis of LGS is difficult and is based on clinical as well as radiological findings, particularly confirmed by targeted genetic tests.¹¹

Prenatal USG in LGS may reveal multiple signs, among others a single umbilical artery, pulmonary stenosis with poststenotic dilatation, pericardial effusion, and short femoral bones. These signs may be also visible in many others syndromes and are not specific.¹² That is why misdiagnosis is probable. Up until now, there was only one case when LGS was detected by amniocyte karyotyping.¹²

Case report

A 32-year-old gravida, para 2, was referred to our unit at 32 weeks + 3 days of gestation. Hence, our first investigation towards fetal malformation was performed late. She reported Crohn's disease but without medication during pregnancy. The first child was unaffected.

During the first USG scan at 32 weeks of gestation we detected a fetus without microcephaly and with normal growth parameters. Upon closer inspection, we observed abdominal ascites, an unusual intra-abdominal cyst with fluid (23mm), localized above a structurally normal bladder. It was difficult to differentiate from an ovarian cyst, but hematometra was more probable because of its localization in the intermedia place of the pelvis. No other malformations were detected, but the face was not clearly visible because of oligohydramnios.

According to Polish law, termination of pregnancy after 23 weeks of gestation is forbidden. Nevertheless, amniotic fluid for genetic diagnosis as necessary for future intrauterine therapy is obtainable. We performed evacuation of the cyst and reduction of the ascitic fluid simultaneously. It was not possible to perform amniocentesis due to oligohydramnios. The collected fluid contained fetal cells, which were examined. From cell

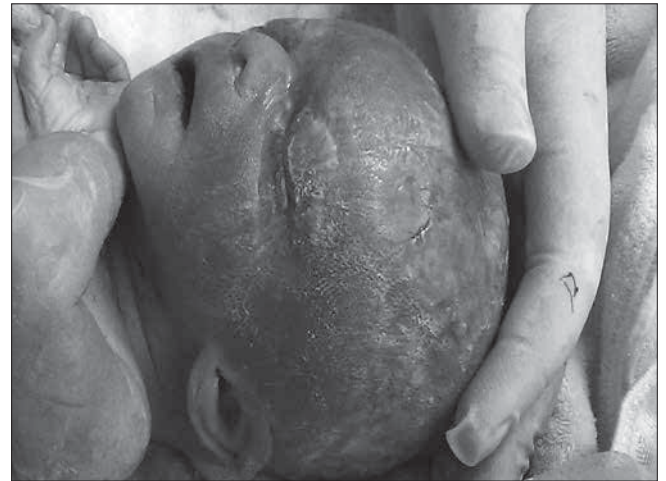

Figure 1. Characteristic facial features, improperly set and maximally rotated ears of the fetus.

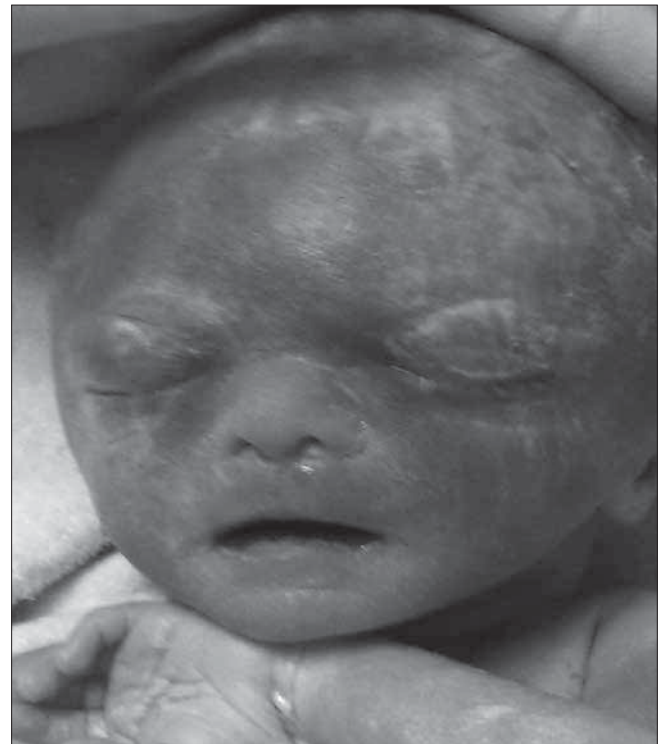

Figure 2. Characteristic facial features with ankyloblepharon of the fetus.

culture DNA was isolated by Qiagen -Mini Kit and tested by molecular karyotyping method BACs-on-Beads (BoBs). We detected deletion in the 8q24 region, characteristic of LGS. The gravida was observed continuously and during the next two weeks the cyst refilled to 50 mm and ascites increased also – we performed a secondary reduction of the cyst and ascites by evacuating 320 ml of the fluid. After another two weeks intrauterine fetal death was observed and we stimulated labor. Photo documentation was prepared and partial autopsy of the female fetus was performed. Fetal length was 43 cm, weight 2425g, and HC 29.5cm. We observed improperly set and

Piotrowski K. et al. Prenatal diagnosis of Langer-Giedion Syndrome confirmed by bacs-on-beads technique.

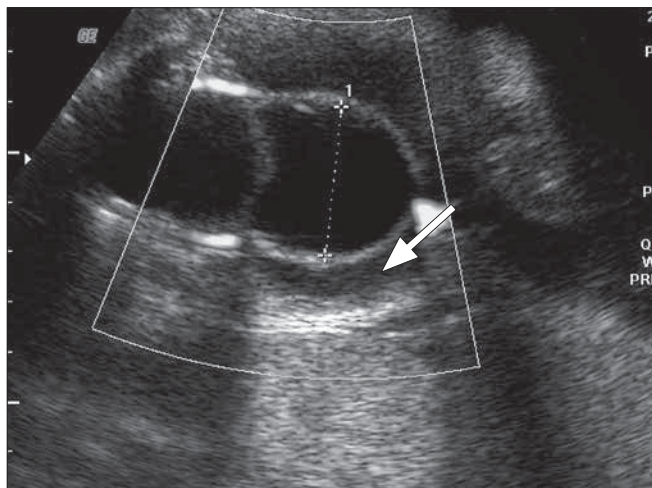


Figure 3. The cyst localized above a structurally normal bladder (arrow).

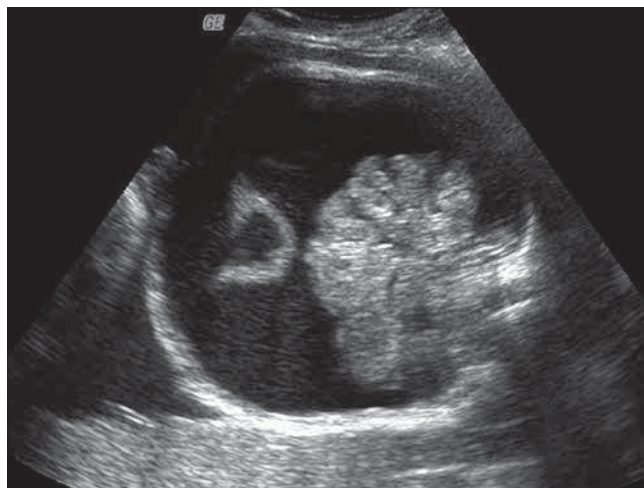

Figure 4. Large ascites of the fetus.

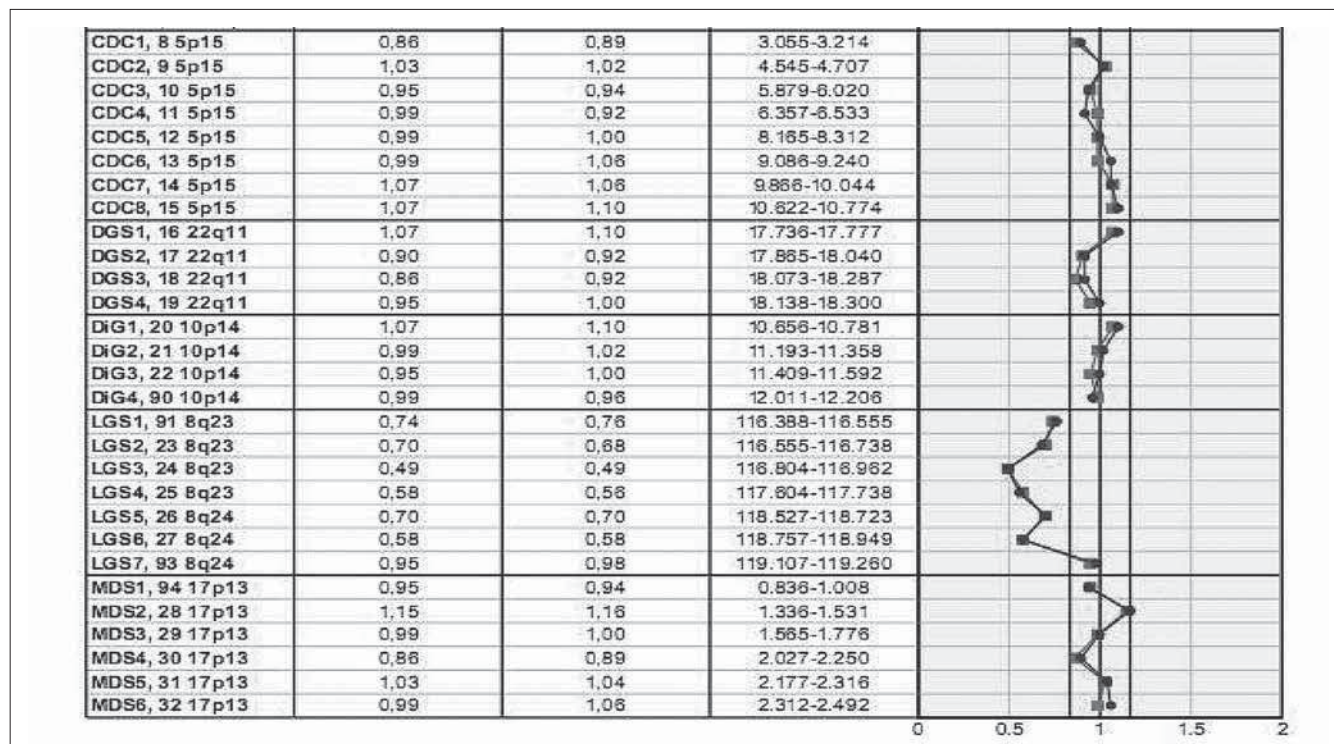


Figure 5. Part of the result of the BACS-on-Beads analysis showing loss of the four critical regions characteristic of LGS microdeletions.

maximally rotated ears, ankyloblepharon and other dysmorphic features. Long bone anomalies were not detected in previous USG or autopsy. We observed complete atresia of the vagina and the uterus was filled with clear fluid. The previously noted cyst was identified as the extended uterus with cleared fluid, whose fundus was placed above the umbilicus.

Discussion

All patients with LGS type II (TRPS II) described in the literature have *de novo* deletion at 8q24.1, with the shortest common region of deletion overlap in EXT1 and TRPS I genes

[1]. TRPS II differs from I and III by structural abnormality of chromosome 8 and crucial phenotype features in living children, whereas TRPS I and III are the results of the dominant gene point mutation.^{13,14}

Unlike TRPS I and III, cases of TRPS II are usually sporadic and most probably the risk of the syndrome in the following pregnancies is not significantly elevated.

EXT1 gene deletion causes the characteristic exostoses - these exostoses were not detected in our case.⁵ They probably develop later in life. We did not detect the main typical facial features of TRPS II, but maximally rotated ears and ankyloblepharon drew

Piotrowski K. et al. Prenatal diagnosis of Langer-Giedion Syndrome confirmed by bacs-on-beads technique.

our attention as untypical signs of TRPS II.⁸ Similarly, we did not find multiple skeletal pathologic signs that also are characteristic of TRPS II.^{10,15.}

The giant abdominal cyst was an important sign in fetal diagnosis as such cysts usually result from abnormal development of the caudal part of the mesonephric duct. Hydrometrocolpos is an accidental feature in living children with TRPS II, similarly to vaginal atresia. It is not known if this is a regular feature in fetuses with TRPS II. In our opinion, LGS should be listed among genetic syndromes with vaginal/uterine atresias.²⁰ Hydrometrocolpos resulting from vaginal atresia is extremely rare in female fetuses - 1:16000.^{16,17,18,19.} Our suspicion that the cyst was in fact hydrometrocolpos was confirmed by the autopsy.

LGS is such a rare microdeletion that its frequency in fetuses and live newborns remains unknown.²⁰ This syndrome is extremely difficult to diagnose by ultrasound because it does not have any specific ultrasound markers. Despite the fact that FISH verification is feasible, the choice of precisely targeted FISH is practically impossible. Only a diagnostic technique that verifies many possible microdeletions simultaneously gives a chance of identifying such rare anomalies. The new BoBs analysis is an example of a method which offers a possibility of simultaneous search for typical aneuploidies and detection of nine typical microdeletions, including 8q24.1, and the complete panel of all subtelomeric and near centromeric aberrations in the short and long arms of all chromosomes. The method enables the detection of many previously undiagnosed microaberrations in a single test. Furthermore, it is useful in analyzing miscarriages and specifying real frequency LGS, as well as in other similar syndromes in pregnancy.^{21,22,23,24.}

To the best of our knowledge, prenatal diagnosis of LGS with the use of the BACs-on-Beads technique has never been reported in the literature so far.

Oświadczenie autorów:

1. Krzysztof Piotrowski – autor koncepcji i założeń pracy, przygotowanie manuskryptu i piśmiennictwa – autor zgłaszający i odpowiedzialny za manuskrypt.
2. Wojciech Halec – zebranie materiału.
3. Jerzy Węgrzynowski – zebranie materiału.
4. Aleksandra Pietrzyk – współautor tekstu pracy i protokołu, korekta i aktualizacja literatury.
5. Małgorzata Henkelman – wykonanie badań laboratoryjnych, opracowanie wyników badań, przechowywanie dokumentacji.
6. Stanisław Zajączek – opracowanie koncepcji i założeń badań, ostateczna weryfikacja i akceptacja manuskryptu.

Źródło finansowania:

Praca nie była finansowana przez żadną instytucję naukowo-badawczą, stowarzyszenie ani inny podmiot, autorzy nie otrzymali żadnego grantu.

Konflikt interesów:

Autorzy nie zgłaszają konfliktu interesów oraz nie otrzymali żadnego wynagrodzenia związanego z powstawaniem pracy.

References

1. McBrien J, Crolla JA, Huang S, [et al.]. Further case of microdeletion of 8q24 with phenotype overlapping Langer-Giedion without TRPS1 deletion. *Am J Med Genet.* 2008, 146A, 1587-1592.
2. Ludecke HJ, Schmidt O, Mardmann J, [et al.]. Genes and chromosomal breakpoints in the Langer-Giedion syndrome region on human chromosome 8. *Hum Genet.* 1999, 105, 619-628.
3. Chen, W, Hou J, Wagner MJ, Wells DE. An integrated physical map covering 25 cM of human chromosome 8. *Genomics.* 1996, 32, 117-120.
4. Hilton MJ, Gutierrez L, Zhang L, [et al.]. An Integrated Physical Map of 8q22-q24: Use in Positional Cloning and Deletion Analysis of Langer-Giedion Syndrome. *Genomics.* 2001, 71, 192-199.
5. Ahn J, Ludecke H-J, Lindow S, [et al.]. Cloning of the putative tumor suppressor gene for hereditary multiple exostoses (EXT1). *Nat Genet.* 1995, 11, 137-143.
6. Momeni P, Glockner G, Schmidt, [et al.]. Mutations in a new gene, encoding a zinc-finger protein, cause tricho-rhino-phalangeal syndrome type I. *Nat Genet.* 2000, 24, 71-74.
7. Hilton MJ, Sawyer JM, Gutierrez L, [et al.]. Analysis of novel and recurrent mutations responsible for the tricho-rhino-phalangeal syndromes. *J Hum Genet.* 2002, 47, 103-106.
8. Vaccaro M, Guarnieri C, Blandino A. Trichorhinophalangeal syndrome. *J Am Acad Dermatol.* 2005, 53 (5), 858-860.
9. Wuyts W, Roland D, Ludecke HJ, [et al.]. Multiple exostoses, mental retardation, hypertrichosis, and brain abnormalities in a boy with a de novo 8q24 submicroscopic interstitial deletion. *Am J Med Genet.* 2002, 113, 326-332.
10. Michalek P, Doherty JT, Vesela MM. Anesthetic management of a child with Langer-Giedion (TRPS II) syndrome. *J Anesth.* 2009, 23, 456-459.
11. Ramos FJ, McDonald-McGinn DM, Emanuel BS, Zackai EH. Tricho-rhino-phalangeal syndrome type II (Langer-Giedion) with persistent cloaca and prune belly sequence in a girl with 8q interstitial deletion. *Am J Med Genet.* 1992, 44, 790-794.
12. Fairweather P. Postmortem findings at 36 weeks gestation in trichorhinophalangeal syndrome: a case report. *Pathology.* 2006, 38 (2), 170-172.
13. Ludecke H-J, Johnson C, Wagner MJ, [et al.]. Molecular definition of the shortest region of deletion overlap in the Langer-Giedion syndrome. *Am J Hum Genet.* 1991, 49, 1197-1206.
14. Ludecke H-J, Schaper J, Meinecke P, [et al.]. Genotypic and phenotypic spectrum in tricho-rhino-phalangeal syndrome types I and III. *Am J Hum Genet.* 2001, 68, 81-91.
15. Shanske AL, Patel A, Saukam S, [et al.]. Clinical and Molecular Characterization of a Patient with Langer-Giedion Syndrome and Mosaic del(8)(q22.3q24.13). *Am J Med Genet.* 2008, 146A, 3211-3216.
16. Female reproductive systems. In: Potters Pathology of The Fetus, Infant and Child. Ed. Enid Gilbert-Barness; *Mosby Elsevier.* 2007, 1375-1413.
17. Hydrocolpos. In: Structural Fetal Abnormalities The Total Picture. Ed. Roger C Sanders. Mosby: St.Louis. 2002, 147-149.
18. Dosedla E, Kacerovsky M, Calda P. Prenatal diagnosis of hydrometrocolpos in a Down Syndrome Fetus. *J Clin Ultrasound.* 2011, 39, 169-171.
19. Respondek-Liberska M, Krasoń A, Kaczmarek P, [et al.]. Fetal hydrometrocolpos: not only diagnostics but also therapeutic dilemmas. *Ultrasound Obstet Gynecol.* 1998, 11 (2), 155-156.
20. Nardmann J, Tranebjaerg L, Horsthemke B, Ludecke HJ. The tricho-rhino-phalangeal syndromes: frequency and parental origin of 8q deletions. *Hum Genet.* 1997, 99, 638-643.
21. Vilard F, G.Simoni, Aboura A, [et al.]. Prenatal BACs-on-Beads™: a new technology for rapid detection of aneuploidies and microdeletions in prenatal diagnosis. *Prenat Diagn.* 2011, 31, 500-508.
22. Piotrowski K, Henkelman M, Zajączek S. Will the New molecular karyotyping BACs-on-Beads technique replace the traditional cytogenetic prenatal diagnostics? Preliminary reports. *Ginekol Pol.* 2012, 83, 284-290.
23. Gross SJ, Bajaj K, Garry D, [et al.]. Rapid and novel prenatal molecular assay for detecting aneuploidies and microdeletion syndromes. *Prenat Diagn.* 2011, 31 (3), 259-266.
24. Vilard F, Simoni G, Gomes DM, [et al.]. Prenatal BACs-on-Beads™: the prospective experience of five prenatal diagnosis laboratories. *Prenat Diagn.* 2012, 32, 329-335.