

Anatomical and functional results of a modified sacral perineocolporectopexy for extreme forms of complex pelvic organs prolapse – own experience

Ocena wyników leczenia wypadania narządów dna miednicy metodą zmodyfikowanej perineokolporektopleksji. Doświadczenia własne

Tomasz Kościński¹, Zbigniew Friebe², Honorata Stadnik¹, Michał R. Drews¹

¹ Klinika Chirurgii Ogólnej, Endokrynologicznej i Onkologii Gastroenterologicznej UM w Poznaniu, Polska

² Klinika Ginekologii UM w Poznaniu, Polska

Abstract

Objectives: Anatomical and functional results of a modified sacral perineocolporectopexy for extreme forms of complex pelvic organs prolapse.

Material and methods: Between 2005 and 2010, 10 women aged 47-75 years were treated by abdomino-perineal implantation of polypropylene mesh for modified sacral perineocolporectopexy and subsequently followed-up. They were suffering from enterocele (9 pts), genital prolapse (8 pts), descending perineum (5 pts), rectal prolapse (4 pts), rectocele (3 pts). Five women were incontinent (mean Wexner: 9) and six had incomplete rectal evacuation. Defecography revealed enterocele III°(5 pts) and II°(4 pts). MR designed descending perineum in 5 pts (mean: 3,8cm).

Results: Permanent reconstruction of the pelvic floor and remission of organs prolapse was achieved at 12-months follow-up in all except 1 patient. There were 2 small vaginal erosions of the mesh and 1 haematoma within the pelvic floor.

Improvement at rectal emptying was found in 4 patients, feeling of pelvic heaviness in 6 patients, dyspareunia in 3 patients. Mean incontinence score decreased from 9 to 4.

Conclusions:

1. Modified sacral perineocolporectopexy is effective in the treatment of complex pelvic floor anatomical defects and organ prolapse.
2. Improvements in rectal emptying, pelvic feeling of heaviness and dyspareunia have been achieved.
3. The implant tolerance was good and the complications rate was low.

Key words: **rectal prolapse / pelvic floor reconstruction / use of prosthetic material / genital organ prolapse /**

Adres do korespondencji:

Honorata Stadnik
Klinika Chirurgii Ogólnej, Endokrynologicznej i Onkologii Gastroenterologicznej UM w Poznaniu
Przybyszewskiego 49, 60-355 Poznań, Polska
Tel.: +48 604797512
e-mail: honoratastadnik@wp.pl

Otrzymano: 02.09.2014
Zaakceptowano do druku: 15.11.2014

Tomasz Kościński et al. Anatomical and functional results of a modified sacral perineocolporectopexy for extreme forms of complex pelvic organs prolapse...

Streszczenie

Cel pracy: Ocena wyników leczenia wypadania narządów dna miednicy metodą zmodyfikowanej perineokolporektopexji.

Materiał i metody: W latach 2005–2010, 10 pacjentek w wieku od 45 do 75 lat zostało poddanych zabiegowi perineokolporektopexji z implantacją siatki polipropylenowej z dostępu brzuszno-kroczonego. U 9 pacjentek występowało enterocele, u 8 wypadanie narządów rodnych, w 5 przypadkach obniżenie dna miednicy, w 4 przypadkach wypadanie odbytnicy, a w 3 rektociele. Pięć kobiet skarżyło się na nietrzymanie stolca (śr Wexner: 9) a 6 na brak pełnego opróżnienia odbytnicy. Defekografia wykazała obecność enterocele III° u 5 pacjentek i II° u kolejnych 4 rezonans magnetyczny uwidoczniał obniżenie dna miednicy w 5 przypadkach (śr o 3,8cm).

Wyniki: U 9 pacjentek w 12-miesięcznej obserwacji osiągnięto trwałą rekonstrukcję dna miednicy i ustąpienie wypadania narządów. Odnotowano dwa przypadki erozji siatki przez pochwę oraz jeden krwiak w miednicy mniejszej. Poprawę opróżniania odbytnicy stwierdzono u 4 pacjentek, uczucia ciężkości w miednicy u 6, a dyspareunii u 3 kobiet. Średni współczynnik nietrzymania stolca obniżył się z 9 do 4.

Wnioski:

1. Zmodyfikowana krzyżowa perineokolporektopexja jest skutecznym leczeniem złożonych anatomicznie defektów dna miednicy oraz wypadania narządów.
2. Osiągnięto poprawę w zakresie opróżniania odbytnicy, uczucia ciężkości w miednicy i dyspareunii.
3. Zabieg cechował się dobrą tolerancją materiału protetycznego i niskim odsetkiem powikłań.

Słowa kluczowe: **wypadanie narządu rodniego / wypadanie odbytnicy /
/ rekonstrukcja dna miednicy / zastosowanie materiału protetycznego /**

Damage in fasciomuscular tissue of the pelvic floor is quite a frequent pathology discovered in women increasing in its severity with each successive birth. The most extreme cases of vast structural defects diagnosed together with prolapse of genitary organs and rectum, and pelvic floor atony call for complex reconstruction procedures.

Sometimes, defects in resistant fascial structures can be considerable in size. Prolonged progression of the condition leads to atrophy of valuable tissues that could be used with success in reconstructing surgeries. (Figure 1).

Traditional surgical methods usually comprised resection of prolapsing organs or wrapping the overstretched tissue [1]. These procedures may be responsible for the high rate of postoperative dyspareunia ranging from 19% to 41% [2-5]. Tension free methods of prosthetic materials implantation are believed to increase patients' tolerance and minimize side effects including relapses [6].

This pilot study was designed to prospectively evaluate the anatomic and functional outcome after total pelvic floor repairs done with polypropylene mesh implants.

Material and methods

The study focuses on the group of 10 patients treated in our institutions between 2005 and 2010 suffering from the most extreme pathologies of the pelvic floor including prolapse of genitary organs and rectum, enterocele, descending perineum, as well as rectocele.

The bioethical committee of Poznań University of Medical Sciences approved methods of the study. All the patients gave their informed consent. Mean age was 58 (range: 47-75) years. Mean parity rate was 2 (range: 1-4). One of the patients gave birth to her only child at the age of 44 years.

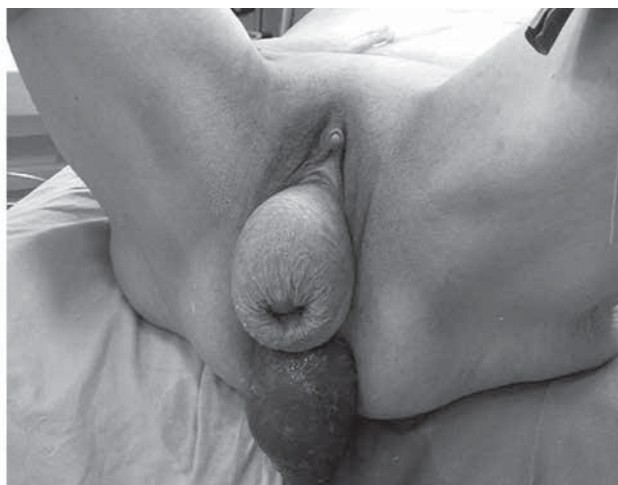

Figure 1. Genital and rectal prolapse.

Study protocol

Preoperative evaluation consisted of physical examination, magnetic resonance (MR) and defecography. MR has been used to measure the pelvic floor descent, and also revealed enterocele as well as the degree of pelvic organs prolapse.

Enterocele size was graded 0 to 4 degree at maximum straining. Stage 0 = no enterocele; stage 1st = enterocele above the puborectalis muscle level; stage 2nd = enterocele at the puborectalis muscle level; stage 3rd = enterocele down to the perineum level [7]. It was estimated by measuring its width in the anterior-posterior direction.

The size of rectocele measured in defecography from an extended line of the anal canal to the tip of the hernial sac: stage 1st = the depth less than 2cm; stage 2nd = the depth ranging from 2 to 4cm; stage 3rd = the depth more than 4cm [8].

Tomasz Kościński et al. *Anatomical and functional results of a modified sacral perineocolporectopexy for extreme forms of complex pelvic organs prolapse...*

On follow-up 12 months later, the patients underwent clinical examination, defecography and MR.

The bowel function and defecation habits questionnaire published by the Swedish Society of Colorectal Surgeons was adapted for this study [9]. The Wexner incontinence score was used to measure the degree of anal incontinence. Pelvic heaviness and dyspareunia were measured using a VAS scale graded from 0 to 10 [10].

All the patients were examined and operated by the same team of colorectal surgeons and a gynecologist, the authors of this study.

Study inclusion criteria were: excessive perineal descent (>3.5cm), enterocele stage 2nd or 3rd, rectocele (>3cm), external rectal prolapse, genital prolapse (POP-Q=IV°).

The clinical, defecographic and MR data of the complex pelvic pathologies found in different configurations in 10 treated patients are illustrated in Table 1. Enterocele was the most often diagnosed pathology. Excessive descent and atony of the pelvic floor were diagnosed in 5 of the patients. Different types of genital prolapse were present in 8 of the patients, while rectal prolapse occurred in 5 of the patients.

Four of the patients had previously undergone pelvic surgeries such as transanal rectal excision and abdominal rectosigmoid resection with sigmoidopexy, hysterectomies. In two of them anterior and posterior vagino and perineoplasties had been also performed.

The results of the treatment were statistically assessed using the Mann-Whitney U test.

Surgical procedure

All the patients were operated in lithotomic position. During laparotomy the pelvic floor peritoneum as well as the presacral space were opened wide. The mesorectum was bilaterally separated from the pelvic structures and the rectovaginal space was exposed down towards the perineal tissues. Any defects in the fascio-muscular structures were identified.

At the vaginal stage of the surgery the lower part of the rectovaginal space was opened. The size of defect in the Denonvilliers' fascia was determined and the medial borders of the puborectal muscles were located.

Nonabsorbable polypropylene materials were used for tension free reconstructions of fascio-muscular structures. The size of the mesh in each case was matched up (U or V shape) to the size of the defect in the pelvic fascia and its lower border was stitched to the perineal body and the anal levators, using Prolene 3-0 sutures. (Figure 2, Figure 3).

After lifting the pelvic floor and setting in the intermediate position, the upper ends of the mesh were sutured to presacral fascia and the periosteum at the S1-S2 level. Placed that way, the mesh patched the defect which caused the enterocele and rectocele. All the prolapsing pelvic organs were stitched to this scaffolding.

The laparotomy concluded with a separation of the grafted mesh from the small bowel by covering it with the mobilized pelvic floor peritoneum.

Three of the patients had concomitant hysterectomies, one had anal sphincter plication. Colonic diverticula were indications for left hemicolectomy in patient No. 9.

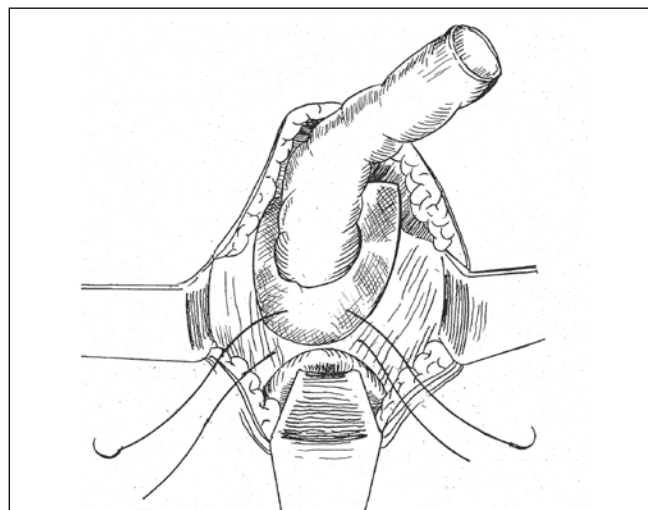


Figure 2. Tension free reconstruction of the defect in pelvic fascia using U-shape polypropylene mesh. Abdominal view.

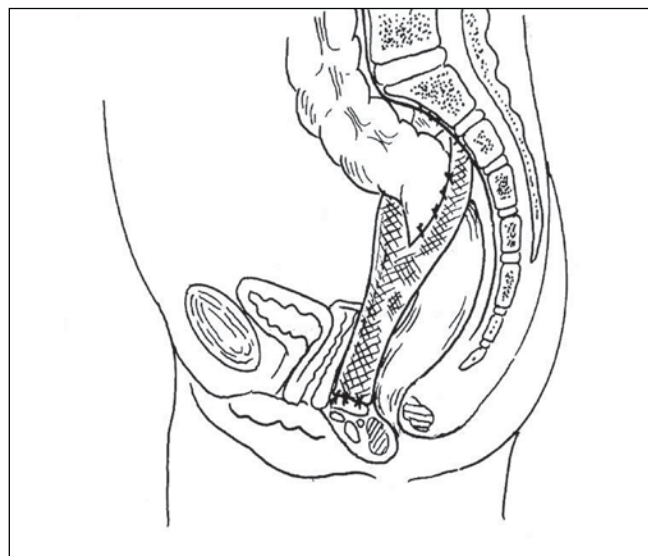


Figure 3. Perineocolporectopexy using polypropylene mesh.

The mean operating time was 126 (range: 82-180) minutes and there was no considerable blood loss during the surgery. Mean hospital stay was 8.2 (range: 6-14) days.

Results

There was no perioperative mortality or major complication. Only one patient (No 6) had a haematoma within the pelvic floor. She had 2 blood units transfused.

Permanent reconstruction of the pelvic floor fascias and remission of rectal and genital organ prolapse has been achieved in all the patients, except for one, whose vaginal stump has detached from the prosthetic material after 8 months (patient No 8). She was successfully reoperated. Patient No 5 has undergone two surgeries for abdominal hernia and urinary incontinence.

There were two cases of small erosion of the grafted material in the vaginal vestibule. The problem was fixed by cutting off the excessive part of the mesh.

Table I. Clinical, defecographic and magnetic resonance findings. Preoperatively and 12-month postoperatively.

Pts	Clinical findings		Defecography		MR		Surgery
			grade		grade		
	Preop	Postop	Preop	Postop	Preop	Postop	
1	En, Pv		En III	En 0	En III	En 0	PCRCP
2	En, DP	DP	En III	En 0	En III DP 4,5cm	En 0 DP 2cm	PCRCP
3	En, DP, PU	DP	En II	En 0	En II DP 3,5cm	En 0 DP 1cm	PCRCP, HY
4	PR, DP	DP			DP 3,5cm	DP 2cm	PCRCP
5	En, DP, PV, PR	DP	En III	En 0	En III DP 4cm	En 0 DP 2cm	PCRCP SP
6	En, Rec, PV	-	En II Rec 3cm	En 0, Rec 0	En II	En 0	PCRCP
7	En, PV, PR, Cys	-	En III	En 0	En III	En 0	PCRCP
8	En, PU, PV	PV	En II	En 0	En II	En 0	PCRCP HY
9	En, Rec, PU, PV, PR, DP	DP	En II Rec 4cm Col divertic	En 0 Rec 0	En 0 DP 3,5cm	En III DP 2cm	PCRCP HY LH
10	En Rec PV	-	En III Rec 4cm	En 0 Rec 0	En III	En 0	PCRCP

En – enterocele, Rec – rectocele, PV – prolapse of vagina, PR – rectal prolapse, PU – prolapse of uterus, DP – descending perineum, PCRCP – perineocolporectopexy
HY – hysterectomy SP – sphincteroplasty, LH – left hemicolectomy

Symptomatic results

Before the treatment, 5 patients reported rectal emptying difficulties, while 6 of them reported incomplete rectal evacuation. Mean weekly defecation frequency was 8 (Table II). Five of the patients complained of fecal incontinence. In 8 of the women, feeling of pelvic heaviness was an important symptom and 4 of sexually active patients complained of dyspareunia. Four of the patients were unable to distinguish intestinal gases from feces.

At the 12-month follow-up we found a significant decrease in the number of patients complaining of rectal emptying difficulties and the feeling of incomplete bowel evacuation. There was also a statistically significant improvement in defecation frequency per week, the feeling of pelvic heaviness and dyspareunia. Also the mean grades of pelvic heaviness and dyspareunia were improved.

Anatomic results

Before the operations, 9 of the patients had enterocele measured during defecography and MR. Six of them were diagnosed as 3rd degree. At the 12-month follow-up all the enteroceles were cured (Table 1). There was also no evidence of any rectocele in three patients.

A significant reduction of the perineal descent from 3.8 (range 3.5-4.5) cm to 1,8 (range 2.0-1.0) cm has been found at 12-month MR (p=0.018).

Discussion

Prolonged stretching of the fascio-ligamental pelvic structures and denervation of the muscles leads to pelvic floor laxity and descent [11, 12]. A rupture and thinning of the recto-vaginal septum develop enterocele and rectocele. Treatment of such complex anatomic defects and tissue laxity as well as descending and prolapsing pelvic floor organs is a challenge.

Table II. Intestinal and pelvic symptoms.

	Preoperatively n=10	12 month postoperatively n=10	p
Rectal emptying – difficulties	5	1	0.006
Mean defecation frequency per week	8±6	5±4	
Incomplete rectal evacuation	6	1	0.004
Digital support of vaginal wall	3	0	0.002
Fecal incontinence	5	4	0.723
Mean Wexner score	9	4	0.04
Inability to distinguish gas/feces	4	3	0.631
Pelvic heaviness	8	2	0.005
Mean grade	6.1	1.6	
Dyspareunia	4	1	0.586
Mean grade	4.2	3.0	

Data are No of patients
Mean defecation frequency ±standard deviation
P* <0,05 (using Mann-Whitney U test)

The introduction of prosthetic materials into pelvic floor repair surgery brings forth a new quality. However, the necessary condition for their implantation is good tissues tolerance in patients as well as a low rate of side-effects and complications. By replacing weak natural tissues and filling vast anatomical defects, properly implanted meshes give a tension-free effect.

Tomasz Kościński et al. *Anatomical and functional results of a modified sacral perineocolporectopexy for extreme forms of complex pelvic organs prolapse...*

The prosthetic material can also be used as a framework, to which the prolapsing organs of the pelvic floor can be attached.

Collopy and Barthram perform this type of surgery from two separate approaches: abdominal, to perform colporectopexy with polypropylene mesh; and vaginal, to perform anterior and posterior colporaphy [13]. They observed a prolapse of the lower part of vagina in 9 out of 89 patients who had undergone this type of surgery. Sullivan et al. stitch the lower part of a Marlex® mesh to perineal body with a Cobb-Radge needle, from vaginal vestibule side, without opening it [1]. However, these authors conclude that correction of the lower part of the rectovaginal septum may not be a sufficient solution in treating rectocele.

The authors of this paper described their own modified method of prosthetic material implantation. The assumption was that the key to a successful surgery result was to achieve a good access to the pelvic floor structures, in order to reveal all the defects and enable implantation of the mesh to viable anatomical parts. This was the reason behind abdomino-vaginal approach, which allowed firm attachment of the mesh to the perineal body structures, ilio-coccygeal fascia and the lower parts of anal levators.

In cases of implantation via vaginal approach described in the papers on this subject, the erosion rate ranged from 0 to 20% [13-18]. It seems imperative that rigorous haemostasis and maximum antiseptic surgical field be maintained in order to minimise that risk.

Small erosions of the mesh observed in 2 patients did not interfere with the overall good functional results of the surgeries. By reconstructing the defects in fascia and ligaments of the pelvic floor anatomically, we could cure symptoms of enterocele and rectocele. The anatomical positions of the pelvic floor at rest, as well as when pushing have been restored to their normal values.

The correction of pelvic organs static alleviated troubles in defecation. In our study, only two patients complained of persisting defecation problems and constant feeling of tenesmus. Other authors reported the total remission or significant improvement in bowel movements problems to range between 76% to 100% of patients [1, 13, 14, 19].

Through suspending the pelvic floor organs and repairing the defects in fasciomuscular structures, we have significantly improved the feeling of heaviness in the pelvis. Postoperative dyspareunia has been minimized in the present study, most likely due to the use of case-tailored tension-free polypropylene mesh implantation.

The results achieved in treatment of such extreme forms of complex pelvic floor pathologies are very promising. However, the authors of this paper are fully aware of the fact that those results have been obtained from a relatively small number of patients so far.

Conclusions

1. Modified abdomino-perineal implantation of polypropylene material for sacral perineocolporectopexy is effective in the treatment of complex pelvic floor anatomical defects and organ prolapse.
2. Significant improvement in rectal emptying, need for digital support, pelvic feeling of heaviness and dyspareunia have been achieved.
3. The implant tolerance was good and the complications rate was low.

Oświadczenie autorów:

1. Tomasz Kościński – autor koncepcji i założeń pracy, autor manuskryptu i piśmiennictwa.
2. Zbigniew Friebe – zbieranie i przygotowanie materiału.
3. Honorata Stadnik – współautor pracy, tłumacz manuskryptu – autor odpowiedzialny za manuskrypt.
4. Michał Drews – ostateczna weryfikacja i akceptacja manuskryptu.

Źródło finansowania:

Praca nie była finansowana przez żadną instytucję naukowo-badawczą, stowarzyszenie ani inny podmiot, autorzy nie otrzymali żadnego grantu.

Konflikt interesów:

Autorzy nie zgłaszają konfliktu interesów i nie otrzymali żadnego wynagrodzenia związanego z powstawaniem pracy.

References

1. Sullivan ES, Longaker CJ, Lee PYH. Total pelvic mesh repair. A ten year experience. *Dis Colon Rectum*. 2001, 44, 857-863.
2. Mellgren A, Johansson C, Dolk A. Enterocele demonstrated by defecography is associated with other pelvic disorders. *Int J Colorectal Dis*. 1994, 9, 121-124.
3. Kahn MA, Stanton SJ. Posterior colporaphy: its effects on bowel and sexual function. *Br J Obstet Gynecol*. 1997, 104, 82-86.
4. Francis W, Jeffcoate T. Dyspareunia following vaginal operations. *J Obstet Gynecol Br Commwlth*. 1961, 68, 1-10.
5. Lopez A, Anzen B, Bremmer S, [et al.]. Durability of success after rectocele repair. *Int Urogynecol J*. 2001, 12, 97-103.
6. Kościński T. Tension-free technique in the management of rectocele – preliminary report. *Proktologia*. 2006, 7, 118-124.
7. Osterberg A, Graf W, Kalborn U, Pahlman J. Evaluation of a questionnaire in the assessment of patients with fecal incontinence and constipation. *Scand J Gastroenterol*. 1996, 31, 575-580.
8. Altman D, Zetterström J, Lopez A, [et al.]. Functional and anatomic outcome after transvaginal rectocele repair using collagen mesh: A prospective study. *Dis Colon Rectum*. 2005, 48, 1233-1242.
9. Silvis R, Gooszen HG, von Essen A, [et al.]. Abdominal rectovaginopexy. Modified technique to treat constipation. *Dis Colon Rectum*. 1999, 42, 82-88.
10. Shorvon PJ, Matlugh S, Diamant NE. Defecography in normal volunteers: result and implications. *Gut*. 1989, 30, 1737-1749.
11. Snooks SJ, Swash M, Henry MM, Setchell M. Risk factors in childbirth causing damage to the pelvic floor innervation. *Int J Colorectal Dis*. 1986, 1, 20-24.
12. Sultan AH, Stanton SJ. Occult obstetric trauma and anal incontinence. *Eur J Gastroenterol Hepatol*. 1997, 9, 423-427.
13. Collopy BT, Barham KA. Abdominal colporectopexy with pelvic cul-de-sac closure. *Dis Colon Rectum*. 2002, 45, 522-529.
14. Lechoux JP, Lechoux D, Bataille P, Bars J. Transperineal repair of rectocele with prosthetic mesh. A prospective study. *Annals de Chirurgie*. 2004, 129, 211-217.
15. De Tayrac R, Picone O, Chauveaud-Lambling A, Fernandez H. A 2-year anatomical and functional assessment of transvaginal rectocele repair using a polypropylene mesh. *Int Urogynecology J*. 2006, 17, 100-105.
16. Escribano J, Furio MJ, Cuesta JA, [et al.]. Transvaginal mesh perineal repair of the rectovaginal septum in the treatment of rectocele and enterocele. Outcomes in 77 patients. *Cir Esp*. 2006, 79, 108-113.
17. De Vita D, Araco F, Gravante G, [et al.]. Vaginal reconstructive surgery for severe pelvic organ prolapses: a "uterinesparing" technique using polypropylene mesh. *Eur J Obstet Gynecol Reprod Biol*. 2008, 139, 245-251.
18. Elmer C, Altman D, Eugh ME, [et al.]. Nordic Transvaginal Mesh Group. Trocar-guided transvaginal mesh repair of pelvic organ prolapse. *Obstet Gynecol*. 2009, 113, 117-126.
19. Watson SJ, Loder PB, Halligan S, [et al.]. Transperineal repair of symptomatic rectocele with Marlex mesh: a clinical, physiological and radiologic assessment of treatment. *J Am Coll Surg*. 1996, 183, 257-261.