

Expression of caveolin-1 in peritumoral stroma is associated with histological grade in ovarian serous tumors

Ekspresja caveoliny-1 w tkance okołoguzowej jest związana ze stopniem różnicowania histopatologicznego w surowicznych guzach jajnika

Sevil Sayhan¹, Gulden Diniz¹, Tugba Karadeniz¹, Duygu Ayaz¹, Dudu Solakoglu Kahraman¹, Mehmet Gokcu², Hulya Tosun Yildirim³,

¹ Tepecik Education and Research Hospital, Pathology Laboratory

² Tepecik Education and Research Hospital, Gynecology and Obstetrics Clinic.

³ Dr. Behcet Uz Children's Hospital, Pathology Laboratory.

Abstract

Background: Previous studies have demonstrated that Caveolin-1 (Cav-1) can ambiguously behave as tumor suppressor or tumor promoter in different neoplasms, depending on cancer type. Some findings have also revealed that cell proliferation, migration and invasion were attenuated by the knockdown of Caveolin-1 expressions. However, the functional and prognostic significance of Caveolin-1 in most tumors remains to be fully elucidated.

Objectives: The aim of the study was to investigate a possible association between tissue Caveolin-1 expression and the clinicopathologic features of ovarian serous tumors.

Material and methods: Caveolin-1 expression was studied in a total of 82 formalin-fixed, paraffin-embedded specimens of ovarian serous tumors and its association with different clinicopathologic parameters was evaluated.

Results: The study included 36 (43.9%) benign, 12 (14.6%) borderline and 34 (41.5%) malignant serous tumors. Mean patient age was 43.9±14.4 years (17-72 years). Statistical analysis revealed that if the tumor becomes more aggressive and invasive, it losses the stromal Caveolin-1 expression ($p=0.001$). Also, parallel changes between stromal and perivascular Caveolin-1 expressions were observed.

Conclusions: Our findings demonstrated a link between Caveolin-1 expression and the aggressiveness of ovarian cancer. Therefore, it seems safe to suggest that Cav-1 may act as a differential diagnostic biomarker in ovarian serous tumors.

Key words: **Caveolin-1 / serous tumors / ovary /**

Adres do korespondencji:

Gulden Diniz, MD, PhD, Associate Prof.

Kibris Sehitleri Cad. 51/11 Alsancak. 35220. Izmir

Phone: +90.232.3625547

Fax: +90.232.3627144

e-mail: agdiniz@gmail.com

Otrzymano: 07.09.2014

Zaakceptowano do druku: 14.12.2014

Sevil Sayhan et al. Expression of caveolin-1 in peritumoral stroma is associated with histological grade in ovarian serous tumors.

Streszczenie

Wstęp: Wcześniejsze badania wykazały, że Caveolina-1 (Cav-1) może zachowywać się niejednoznacznie w zależności od rodzaju nowotworu, jako jego supresor lub promotor. Niektóre badania pokazały, że proliferacja komórek, migracja i inwazja były osłabiane przez obniżoną ekspresję Caveoliny-1. Jakkolwiek czynnościowe i prognostyczne znaczenie Caveoliny-1 w wielu guzach pozostaje w pełni do wyjaśnienia.

Cel pracy: Celem badania była ocena możliwych związków pomiędzy ekspresją Caveoliny-1 i cechami kliniczno-patologicznymi surowiczych guzów jajnika.

Materiał i metoda: Ekspresję Caveoliny-1 oceniono w 82 tkankach surowiczych guzów jajnika utrwalonych w formalinie i zatopionych w parafinie i skorelowano z różnymi cechami kliniczno-patologicznymi.

Wyniki: Do badania włączono 36 (43,9%) niezłośliwych, 12 (14,6%) granicznych i 34 (41,5%) złośliwych guzów surowiczych. Średnia wieku wynosiła 43,9±14,4 lat (17-72 lata). Analiza statystyczna wykazała, że im bardziej agresywny i inwazyjny był guz, tym bardziej tracił ekspresję Caveoliny-1 ($p=0,001$). Równolegle obserwowano zmiany ekspresji Caveoliny-1 w tkance łącznej i okotonaczyniowej.

Wnioski: Nasze badania pokazują związek pomiędzy ekspresją Caveoliny-1 i złośliwością raka jajnika. Wydaje się, że Caveolina-1 może pełnić rolę biomarkera w diagnostyce różnicowej surowiczych guzów jajnika.

Słowa kluczowe: **Caveolina-1 / guz surowiczy / jajnik /**

Introduction

Caveolae, specialized membrane microdomains, are flask-shaped invaginations of the plasma membrane and have three different coat proteins known as caveolins. Two of them (Caveolin1/cav-1 and Caveolin2/cav-2) are co-expressed widely in fully differentiated mesenchymal and endothelial normal tissues, as well as in many solid tumors, whereas Caveolin-3 (cav-3) is primarily expressed in muscle cells [1]. They were reported to be important regulators of cellular processes such as signal transduction and endocytosis, thus being involved in several biological and metabolic functions, including cell growth, apoptosis, and angiogenesis [2]. Previous studies revealed that Cav-1 levels in the epithelial cells of some carcinomas increase during tumor progression. Conversely, Cav-1 expression in the peritumoral stromal cells can decline in advanced and metastatic cancers [3]. Similar results were also obtained in sarcomas [4].

Serous tumors, derived from the ovarian surface epithelium, constitute about one-fourth of all ovarian neoplasms [5], with a wide morphologic spectrum, from benign serous tumors (serous cystadenoma) to malignant serous tumors (serous adenocarcinoma). Ovarian carcinoma (OC) is responsible for the greatest number of deaths due to malignancies of the female genital tract and is the fifth leading cause of cancer-related fatalities among women. The prognosis is relatively poor as ovarian cancer is disproportionately deadly, owing to lack of early detection methods and a reliable screening test. Thus, most cases are not diagnosed until they have reached advanced stages of the disease. More than 60% of the affected women have stage III or IV cancer, i.e. after it has already spread beyond the ovaries. The five-year survival rate for patients with early stage OC, when the cancer is still confined to the primary site, is 92.7%. The overall prognosis for ovarian carcinoma remains poor, being a direct result of its rapid growth rate and lack of early symptoms. The survival rate is approximately 35% and 28% at 5 and 10 years, respectively, but it has not improved much since the late 1970s [5-8].

Cav-1 has been shown to act as either a tumor suppressor or tumor promoter in different neoplasms. There were only a few

studies about ovarian carcinoma which reported Cav-1 to function as a putative tumor suppressor [9-11]. The aim of our study was to investigate the Cav-1 immunohistochemical expression in serous tumors of the ovary and to evaluate a possible relationship between Cav-1 expression and numerous prognostic findings such as stage of the disease, histological features, age, and the survival rate.

Material and methods

Surgical resection specimens of 82 patients diagnosed and treated at the Izmir Tepecik Education and Research Hospital between 2002 and 2013 were included in the study. The Hospital Education Planning Committee approved of the study. The staging system developed by the International Federation of Gynecology and Obstetrics (FIGO) was used to describe the extent of tumor spread [8]. According to this system, stage I diseases are limited to one or both ovaries. In stage II, there is pelvic extension or implants, but the tumor is still limited to the pelvis. Stage III signifies extension to the peritoneum or regional lymph nodes. There are distant metastases to the liver or outside the peritoneal cavity in stage IV of the disease.

For immunohistochemistry (IHC), hematoxylin and eosin (HE) staining was used to select appropriate paraffin blocks and to identify viable tumor areas. IHC was performed by the streptavidine biotin peroxidase method (Invitrogen, Camarillo, 85-9043). Serial 5- μ m sections were obtained and the slides were baked over-night at 60°C, dewaxed in xylene, and hydrated in distilled water through decreasing concentrations of alcohol. All slides were treated with heat-induced epitope retrieval in the microwave (in 10mM/L citrate buffer, pH 6.0, for 20 minutes, followed by cooling at room temperature for 20 minutes). Blocking of endogenous peroxidase and biotin was performed. An affinity purified monoclonal mouse antibody against Caveolin-1 (Novus Biologicals, Littleton, NB100-615) was used at a dilution of 1:200. The evaluation was blinded to any of the clinical features and staining patterns were classified as stromal, perivascular or epithelial (Figure 1).

Sevil Sayhan et al. Expression of caveolin-1 in peritumoral stroma is associated with histological grade in ovarian serous tumors.

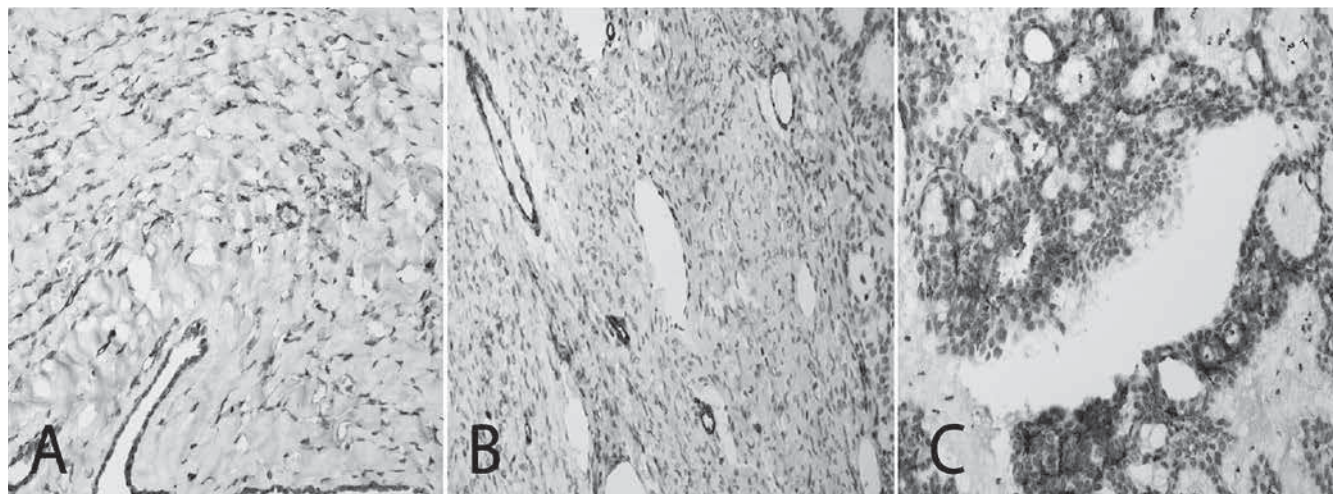


Figure 1. Immunohistochemical staining patterns with anti-Caveolin-1 antibody: (A) stromal cells, (B) perivascular and, (C) cytoplasm of tumor cells (DAB x 100).

Spearman Correlation analysis, Mann Whitney U test, Chi square test and Kaplan Meier Survival Analysis were performed for statistical analysis with SPSS 15.0. P-value of less than 0.05 was considered as statistically significant.

Results

Surgery and chemotherapy, alone or in combination, were applied in 82 patients in accordance with their individual features. There were 36 (43.9%) benign, 12 (14.6%) borderline, and 34 (41.5%) malignant serous tumors. All 12 cases with borderline serous tumor were classified as stage I of the disease, with 8 (66.6%) stage IA, 3 (25%) stage IB, and 1 (8.3%) stage IC tumors. Most cases (n=25, 73.5%) with serous carcinomas were stage IIIC of the disease.

Other cases with serous carcinomas were distributed as follows: 1 stage IC (2.9%), 1 stage IIB (2.9%), 4 stage IIIA (11.8%), 1 stage IIIB (2.9%), and 2 stage IV (5.9%). Mean age of the patients was 43.9±14.4 years (range: 17-72 years). Cases with serous carcinoma (52.4±9.5 years; 30-70 years) were older than subjects with both, borderline (35.9±13.4 years; 23-72 years) and benign serous (38.5±14.8 years; 17-62 years) tumors. All 12 cases with borderline tumors and 20 (58.8%) patients with serous carcinomas were alive, while 11 (32.4%) subjects with carcinoma were deceased. Three carcinoma cases were lost to follow-up. Mean overall survival of serous carcinomas was 15.3±11.9 (0-45) months and event-free survival was 11.4±9.9 months.

Increased stromal and perivascular Cav-1 expression was observed in 24 (66.7%) benign tumors (Figure 2), whereas decreased expression was determined in most malignant (n:29/85.3%) and borderline (n:9/75%) tumors. Statistical analysis revealed that if the tumor becomes more aggressive and invasive, it loses the stromal Cav-1 expression (p=0.001) (Figure 3).

Also, there were parallel changes between stromal and perivascular Cav-1 expressions (p<0.01), but a similar association was not determined for survival time (p=0.604). The Kaplan Meier Survival Analysis demonstrated the absence of statistical significant differentiation between overall survival of the affected cases with regard to the status of Cav-1 expressions (Figure 4).

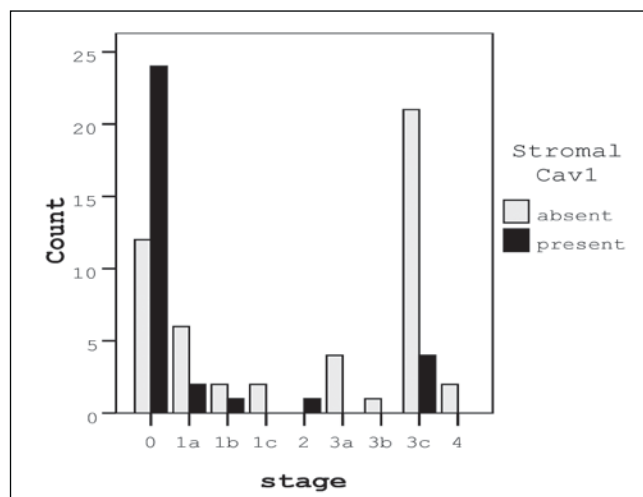


Figure 2. Stromal Cav-1 expression was decreased in tumors with late stage (p<0.01).

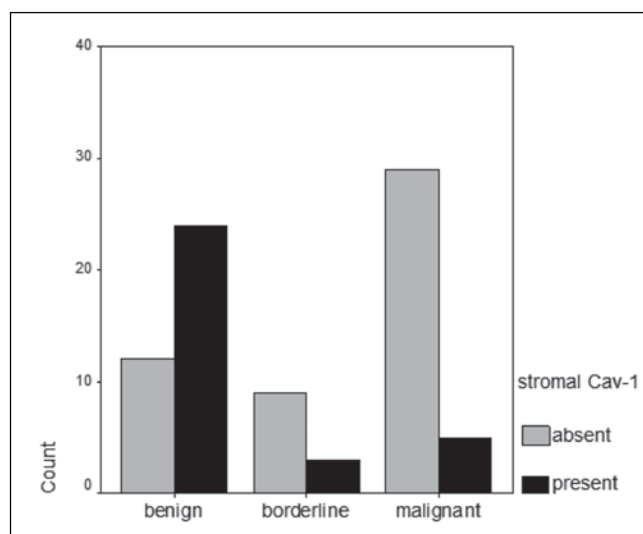


Figure 3. Stromal Cav-1 expression was increased in benign serous tumors and decreased in malignant or borderline tumors (p=0.001).

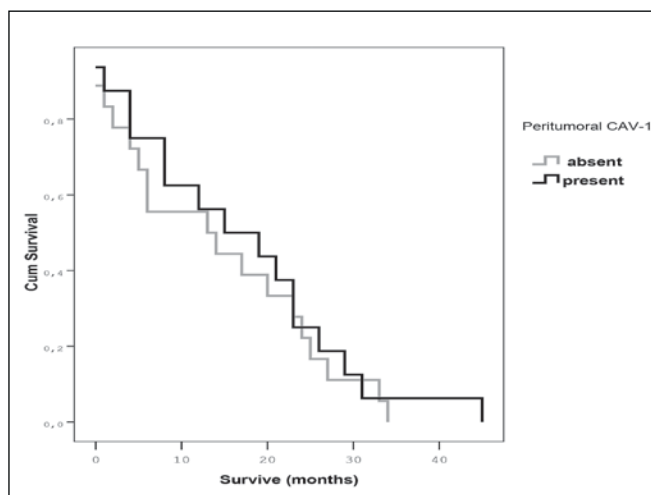
Sevil Sayhan et al. *Expression of caveolin-1 in peritumoral stroma is associated with histological grade in ovarian serous tumors.*

Figure 2. The survival curve according to the presence of peritumoral Cav-1 expression ($p=0.604$).

Discussion

A controversial role, both complex and multifaceted, of the Cav-1 protein has been documented in several neoplasms, including cell proliferation, tumor development and progression. In some cell types, Cav-1 interacts with multiple members of the EGF-R/RAS/ERK and PI3/AKT pathways to modify signaling activity [12]. Previous studies showed that Cav-1 facilitates both, ERK and AKT signaling in cancer cells from kidney, colon, prostate, epidermis, muscle, and brain, and is associated with promoting cell invasion, proliferation, angiogenesis and multi-drug resistance [12-16]. Similar association between Cav-1 expression and mutations of B-RAF in melanomas was also reported [17].

Most authors suggest that Cav-1-positive tumor cells serves as tumor promoters by these signaling pathways [3, 12-17]. In our study, we determined Cav-1 expression in a limited number of tumors. Therefore, we were not able to determine any statistically significant relationship between the presence of Cav-1 expression in tumor cells and tumor behavior.

The tumor microenvironment plays a crucial role in the initiation and progression of malignancies. It is now clear that cancer promotes increased micro-vessel density, recruits reactive stromal fibroblasts and different inflammatory cells, and releases peptide-signaling molecules and proteases [3, 18]. Cancer-associated fibroblasts (CAF) produce an altered extracellular matrix (ECM), which can induce epithelial-mesenchymal transition (EMT) or other types of behaviors associated with a more aggressive phenotype in the neighboring epithelial cells [3, 18]. The exact mechanisms of this relationship remain to be fully elucidated. However, the transforming growth factor β (TGF- β), which is involved in modulation of cell growth and tumorigenesis, seems to play a major role [3]. In many studies, reduced levels of Cav-1 in the extratumoral stroma have been reported [12-17]. Similarly, it was shown by the functional studies that down-regulation of stromal Cav-1 expression is likely to alter stromal influences on tumor epithelium, tumor angiogenesis, as well as cholesterol and androgen metabolism.

In order to determine the mechanisms of this process, Atala et al., used myofibroblasts which are often employed to study the relationship between cancer cells and tumor microenvironment [3]. Their results indicated that Cav-1 down-regulation in the stroma, which coincides with increased expression of some reactive markers, induces a number of gene alterations, including up-regulation of TGF- β 1 and down-regulation of some genes related with a pro-angiogenesis effect. They also showed that Cav-1 silencing stimulates proliferation and provokes oncogenic cell signaling in prostate stromal cells, coincident with increased levels of intracellular cholesterol and activation of steroidogenic enzymes. These stromal alterations result in increased tumor cell migration [3]. Our similar observation of decreased levels of Cav-1 expression in the peritumoral stroma, consistent with recent reports, was associated with a higher stage of serous tumors.

Tissue expression of Cav-1 used as a marker of cancer progression remains controversial. Definition of the expression status in peritumoral stromal cells has been accepted as a better parameter. In the majority of English-language reports, stromal Cav-1 appears to be down-regulated and the decreasing expression seems to play a negative role in cancer transformation. Many oncogenes such as SRC, RAS, BCR-ABL, transcriptionally down-regulate Cav-1 expression [1]. Recent studies have focused their attention on Cav-1 expression in the peritumoral stromal cells rather than in tumor cells, but their findings are also contradictory. For example, Goetz et al., suggest that there may be an important role for stromal Cav-1 in promoting tumor progression and metastasis [20]. However, in most other studies, loss of stromal Cav-1 expression in association with a high tumoral Cav-1 expression, has been reported to be closely related with poor outcome in different malignancies [1, 3, 12-14, 16, 18, 21, 22].

Similarly, we demonstrated that stromal expression of Cav-1 in ovarian serous tumors correlates with histological grade and stage. However, in survival analysis, Cav-1 expression was not an independent prognostic factor for patient outcome.

In this study, we evaluated the expression of Cav-1 in the serous tumors and determined that stromal and perivascular expression of Cav-1 is almost always present in benign serous tumors, while normal stromal Cav-1 expression is lost in the majority of borderline and malignant tumors. Although epithelial Cav-1 expression has been extensively studied in several carcinomas, there is little or no data on the expression and significance of Cav-1 in ovarian tumors [9-11]. Davidson et al., demonstrated that Cav-1 is often expressed in advanced stages of ovarian carcinoma, but does not appear to be a powerful predictor of disease outcome [9]. We observed that the expression status of Cav-1 in the peritumoral stroma was changed according to the tumor grade and stage. Our findings are consistent with the literature, but Cav-1 is not overexpressed in tumor cells and Cav-1 expression in the tumor cells was not a prognostic factor for the clinical outcome in our patient.

In conclusion, the results of our study demonstrate that altered expression of Cav-1 protein in the stroma of serous tumors may be a component in tumor dedifferentiation. Therefore, it may be suggested that Cav-1 may act as a marker in ovarian serous tumors, especially for differential diagnosis of the borderline and benign cases, but our findings need further investigation in larger series.

Sevil Sayhan et al. *Expression of caveolin-1 in peritumoral stroma is associated with histological grade in ovarian serous tumors.*

Authors' contribution:

1. Sevil Sayhan – concept, article draft.
2. Gulden Diniz – analysis and interpretation of data, article draft, corresponding author.
3. Tugba Karadeniz – interpretation of data, article draft.
4. Duygu Ayaz – interpretation of data, article draft.
5. Dudu Solakoglu Kahraman – interpretation of data, article draft.
6. Mehmet Gokcu – interpretation of data and collections of patient's features.
7. Hulya Tosun Yildirim – interpretation of data, article draft.

Authors' statement

- This is to certify, that the publication will not violate the copyrights of a third party, as understood according to the Act in the matter of copyright and related rights of 14 February 1994, Official Journal 2006, No. 90, Clause 63, with respect to the text, data, tables and illustrations (graphs, figures, photographs);
- there is no 'conflict of interests' which occurs when the author remains in a financial or personal relationship which unjustly affects his/her actions associated with the publication of the manuscript;
- any possible relationship(s) of the author(s) with the party/parties interested in the publication of the manuscript are revealed in the text of the article;
- the manuscript has not been published in or submitted to any other journal.

Source of financing: All authors.

17. Paskaš S, Janković J, Marečko I, [et al.]. Caveolin-1 expression in papillary thyroid carcinoma: correlation with clinicopathological parameters and BRAF mutation status. *Otolaryngol Head Neck Surg.* 2014, 150 (2), 201-209.
18. Tuxhorn JA, McAlhany SJ, Dang TD, [et al.]. Stromal cells promote angiogenesis and growth of human prostate tumors in a differential reactive stroma (DRS) xenograft model. *Cancer Res.* 2002, 62 (11), 3298-3307.
19. Faggi F, Mitola S, Sorci G, [et al.]. Phosphocaveolin-1 enforces tumor growth and chemoresistance in rhabdomyosarcoma. *PLoS One.* 2014, 9 (1), e84618. [doi: 10.1371/journal.pone.0084618].
20. Goetz JG, Minguet S, Navarro-Lérida I, [et al.]. Biomechanical remodeling of the microenvironment by stromal Caveolin-1 favors tumor invasion and metastasis. *Cell.* 2011, 146 (1), 148-163.
21. Witkiewicz AK, Dasgupta A, Sotgia F, [et al.]. An absence of stromal Caveolin-1 expression predicts early tumor recurrence and poor clinical outcome in human breast cancers. *Am J Pathol.* 2009, 174 (6), 2023-2034.
22. Wu KN, Queenan M, Brody JR, [et al.]. Loss of stromal Caveolin-1 expression in malignant melanoma metastases predicts poor survival. *Cell Cycle.* 2011, 10 (24), 4250-4255.

References

1. Senetta R, Stella G, Pozzi E, [et al.]. Caveolin-1 as a promoter of tumour spreading: when, how, where and why. *J Cell Mol Med.* 2013, 17 (3), 325-336. [doi: 10.1111/jcmm.12030].
2. Engelman JA, Zhang X, Galbiati F, [et al.]. Molecular genetics of the caveolin gene family: implications for human cancers, diabetes, Alzheimer disease, and muscular dystrophy. *Am J Hum Genet.* 1998, 63 (6), 1578-1587.
3. Ayala G, Morello M, Frolov A, [et al.]. Loss of Caveolin-1 in prostate cancer stroma correlates with reduced relapse-free survival and is functionally relevant to tumour progression. *J Pathol.* 2013, 231 (1), 77-87.
4. Sáinz-Jaspeado M, Martín-Liberal J, Lagares-Tena L, [et al.]. Caveolin-1 in sarcomas: friend or foe? *Oncotarget.* 2011, 2 (4), 305-312.
5. Vang R, Shih IeM, Kurman RJ. Ovarian low-grade and high-grade serous carcinoma: pathogenesis, clinicopathologic and molecular biologic features, and diagnostic problems. *Adv Anat Pathol.* 2009, 16 (5), 267-282.
6. Kurman RJ, Shih IeM. Pathogenesis of ovarian cancer: lessons from morphology and molecular biology and their clinical implications. *Int J Gynecol Pathol.* 2008, 27 (2), 151-160.
7. Carter J, Fowler J, Carlson J, [et al.]. Borderline and invasive epithelial ovarian tumors in young women. *Obstet Gynecol.* 1993, 82 (5), 752-756.
8. Rosai J. Ovary. In: Rosai and Ackerman's Surgical Pathology. (Eds). Rosai J 10. Ed. Philadelphia: Mosby Elsevier. 2011, Vol 2, 1553-1635.
9. Davidson B, Nesland JM, Goldberg I, [et al.]. Caveolin-1 expression in advanced-stage ovarian carcinoma: a clinicopathologic study. *Gynecol Oncol.* 2001, 81 (2), 166-171.
10. Davidson B, Goldberg I, Givant-Horwitz V, [et al.]. Caveolin-1 expression in ovarian carcinoma is MDR1 independent. *Am J Clin Pathol.* 2002, 117 (2), 225-234.
11. Wiechen K, Diatchenko L, Agoulinik A, [et al.]. Caveolin-1 is down-regulated in human ovarian carcinoma and acts as a candidate tumor suppressor gene. *Am J Pathol.* 2001, 159 (5), 1635-1643.
12. Campbell L, Gumbleton M, Griffiths DF. Caveolin-1 overexpression predicts poor disease-free survival of patients with clinically confined renal cell carcinoma. *Br J Cancer.* 2003, 89 (10), 1909-1913.
13. Basu Roy UK, Henkhaus RS, Loupakis F, [et al.]. Caveolin-1 is a novel regulator of K-RAS-dependent migration in colon carcinogenesis. *Int J Cancer.* 2013, 133 (1), 43-57.
14. Li L, Ren CH, Tahir SA, [et al.]. Caveolin-1 maintains activated Akt in prostate cancer cells through scaffolding domain binding site interactions with and inhibition of serine/threonine protein phosphatases PP1 and PP2A. *Mol Cell Biol.* 2003, 23, 9389-9404.
15. Rossi S, Poliani PL, Cominelli M, [et al.]. Caveolin-1 is a marker of poor differentiation in Rhabdomyosarcoma. *Eur J Cancer.* 2011, 47 (5), 761-772.
16. Quann K, Gonzales DM, Mercier I, [et al.]. Caveolin-1 is a negative regulator of tumor growth in glioblastoma and modulates chemosensitivity to temozolomide. *Cell Cycle.* 2013, 12 (10), 1510-1520.