

P R A C E K A Z U I S T Y C Z N E
położnictwo

Urgent embolization of hemorrhagic choriocarcinoma liver metastases – case report and review of the literature

Rak kosmówki: pilna embolizacja krwawiących przerzutów w wątrobie – opis przypadku i przegląd literatury

Agnieszka Lemańska¹, Paulina Banach¹, Katarzyna Stanisławska², Robert Juszkat², Marek Spaczyński^{1,3}, Ewa Nowak-Markwitz¹

¹ Klinika Onkologii Ginekologicznej, Ginekologiczno-Położniczy Szpital Kliniczny Uniwersytetu Medycznego w Poznaniu, Polska

² Katedra Radiologii Ogólnej i Zabiegowej, Uniwersytetu Medycznego w Poznaniu, Polska

³ Wydział Lekarski i Nauk o Zdrowiu, Uniwersytet Zielonogórski, Zielona Góra, Polska

Abstract

We present a rare case of 23-year-old patient with metastatic choriocarcinoma that presented life threatening abdominal bleeding from liver metastases shortly after initiation of treatment with chemotherapy and was treated by emergency embolization of the hepatic vessels. Although the bleeding was controlled, the patient succumbed to the disease on the 15th day after admission.

Conclusions: *Incontrollable hemorrhagic complications are the most common cause of death in choriocarcinoma metastatic patients. Angioembolization is an effective way of ceasing the bleeding and a potentially life saving measure.*

Key words: **gestational trophoblastic disease / Choriocarcinoma / embolization / liver metastases / hepatic metastases / hepatic artery embolization /**

Adres do korespondencji:

Agnieszka Lemańska
Klinika Onkologii Ginekologicznej UM
60-535 Poznań, ul. Polna 33, Polska
tel. +48 61 841 92 71
e-mail: agnieszka0lemanska@gmail.com

Otrzymano: 30.08.2014
Zaakceptowano do druku: 30.10.2014

Agnieszka Lemańska et al. Urgent embolization of hemorrhagic choriocarcinoma liver metastases – case report and review of the literature.

Streszczenie

Artykuł opisuje przypadek 23-letniej pacjentki z rozszanym rakiem kosmówki, u której wkrótce po rozpoczęciu chemioterapii wystąpił zagrażający życiu krwotok do jamy brzusznej z ognisk przerzutowych w wątrobie. Pacjentka została poddana pilnej embolizacji naczyń wątrobowych, dzięki czemu udało się opanować krwawienie, jednak zmarła 15. dnia po przyjęciu do szpitala z powodu zaawansowania procesu chorobowego.

Wnioski: Trudne do opanowania powikłania krwotoczne w rozszanym raku kosmówki są najczęstszą przyczyną zgonów w tej grupie pacjentek. Embolizacja naczyń jest skuteczną metodą leczenia potencjalnie śmiertelnych krwotoków w onkologii.

Słowa kluczowe: **przetrwiała choroba trofoblastyczna / rak kosmówki / embolizacja / embolizacja tętnicy wątrobowej / przerzuty w wątrobie /**

Abbreviations:

- IR** – interventional radiology
- HCG** – human chorionic gonadotropin
- Hb** – hemoglobin
- ALAT** – alanine transaminase
- ASAT** – aspartate transaminase
- GTN** – gestational trophoblastic neoplasia
- PT** – prothrombin time
- INR** – international normalized ratio
- PR** – prothrombin ratio
- aPTT** – activated partial thromboplastin time

Introduction

Choriocarcinoma is a very rare (1:50000 pregnancies) gynecological malignancy that can occur after molar pregnancy (50%), abortion (25%), term (20%) or ectopic pregnancy [1]. Although it can be effectively treated with chemotherapy, the presence of metastases puts the patients at risk of developing severe hemorrhage after starting the treatment due to necrosis.

Interventional radiology (IR) is a fast-developing branch of radiology that opened new treatment modalities for internal bleeding. One of the most recent IR applications are the procedures in oncology such as tumor embolization, chemoembolization and palliative treatment, e.g. vena cava superior syndrome angioplasty or implantation of vascular ports for long-term chemotherapy [2].

In this article we present a rare case of a young woman diagnosed with choriocarcinoma that presented life-threatening abdominal bleeding from liver metastases shortly after receiving the first course of chemotherapy and was treated by emergency embolization of the hepatic artery.

Case report

In January 2014 a 23-year-old woman was referred to the Department of Gynecologic Oncology due to choriocarcinoma suspicion. The patient was admitted in a critical state on the second day after exploratory laparotomy performed in a different hospital due to abdominal bleeding. During the surgery 3,5 liters of blood were evacuated from the peritoneal cavity but the source of the hemorrhage was not identified. Histopathological examination of the ovaries, that were removed

during the surgery, revealed poorly differentiated solid cancer (G3) and metastatic origin of the lesion. At admission to the Department of Gynecologic Oncology the patient was conscious and complained about strong abdominal pain. In July 2013 she delivered a healthy newborn at 38 weeks of gestation by cesarian section. Her past medical history was insignificant. Before the laparotomy the patient experienced hematemesis, abdominal pain and menometrorrhagia for two weeks. On physical examination the abdomen was distended and tender. The patient was pale and in a poor general condition. Ultrasound examination and computer-assisted tomography revealed spread neoplastic process with metastases to the lungs, liver, pancreas, spleen and adrenal glands but no ascites. Chest Xray revealed spread lesions indicating pulmonary embolism. Laboratory results showed anemia (Hb 4,20 mmol/l), low platelet count (PLT 67,0 G/l) and human chorionic gonadotropin (HCG) level of 83 338,00 mIU/mL. Liver enzymes and total bilirubin level were elevated (ALAT 81,30, ASAT 171,40, bilirubin 2,05 mg/dL) as were some of the indicators of coagulation panel (PT 18,3 s; INR 1,4; D-dimer 12 430,0 ng/mL). Fibrinogen level decreased to 1,6 g/l, PR and aPTT were within norm. These results suggested impairment of the liver function and disseminated intravascular coagulation.

Despite the critical state of the patient first cycle of chemotherapy was administered assuming that starting the treatment is the only chance for the patient's survival. She was qualified for EMA-CO regimen (etoposide, methotrexate and actinomycin D given on days 1 and 2, followed by cyclophosphamide and vincristine on day 8). Due to increasing symptoms of respiratory failure on the second day of chemotherapy the patient was admitted to the intensive care unit and intubated. In view of gradual deterioration of the anemia and great abdominal distension intraperitoneal bleeding from metastatic liver tumors was suspected after the administration of the first dosis of chemotherapy. The patient was transferred to the Department of Interventional Radiology where hemorrhage from metastatic lesions of the liver was confirmed on angiographic examination and the patient was qualified for embolization of the hepatic vessels. The patency of portal vein was confirmed in the computer-assisted tomography image.

Right femoral artery was punctured with Seldinger method and 5F vascular sheath was introduced (Balt, Monmorency, France). Then celiacus trunk was catheterized with a catheter 5F

Agnieszka Lemańska et al. *Urgent embolization of hemorrhagic choriocarcinoma liver metastases – case report and review of the literature.*

(Glidecath, Terumo, USA) and digital subtraction angiography was performed revealing massive metastatic lesions in both lobes of the liver (Figure 1).

Selective catheterization (Glidecath, Terumo, USA) of both hepatic arteries by was made and polyvinyl alcohol particles (300-500 micrometers) (Cook Medical, USA) were administered to embolize target vessels. Control angiography after embolization showed occlusion of the arteries supplying metastatic lesions and cessation of the intraperitoneal bleeding (Figure 2).

A temporal embolizer was used in order not to permanently impair the liver function. In that case, recanalization of the vessels is observed within two weeks. After the procedure, the patient returned to the Gynecologic Oncology Department to continue the treatment with chemotherapy in the intensive care unit. A few episodes of abundant pulmonary bleeding occurred. Due to coagulation failure and constant blood loss the patients was transfused in total 24 units of fresh frozen plasma, 9 units of platelets and 18 units of packed red blood cells. A decrease in HCG level (first to 17 825,00 mIU/ml and to 7 706,00 mIU/ml after 2 weeks) and moderate improvement of other laboratory parameters was observed but clinically the patient remained in a critical state and unconscious. Finally, the patient succumbed to the disease on the 15th day after admission.

Discussion

Chemotherapy is the main treatment method of choriocarcinoma. For low-risk disease, monotherapy with methotrexate or actinomycin D is usually applied. In more severe cases, polychemotherapy is required. The most popular first-line schemes are MAC (methotrexate, actinomycin, cyclophosphamide) and EMA-CO (etoposide, methotrexate, actinomycin D, cyclophosphamide, vincristine). Hysterectomy can be considered, especially in women with low-risk disease, to reduce the time of chemotherapy but for metastatic choriocarcinoma it was not proven to be beneficial. Surgical removal of single lung or liver metastases is recommended. Radiotherapy is applied to cure metastatic disease of the central nervous system [1]. Most common metastatic sites are the lungs (80%), vagina (30%), pelvis (20%), liver and brain. In a large group of 1676 patients at the Charing Cross Hospital liver involvement was observed in 2,7% of the patients, 65% of which the antecedent pregnancy was not molar. The presence of liver metastases is a poor prognostic factor and occurs in advanced stage of the disease [3].

As choriocarcinoma is very sensitive to chemotherapy, cure rates are high and for non-metastatic disease the 5-year survival reaches 100%. The introduction of EMA-CO chemotherapy in 1986 resulted in a significant increase in survival of the patients with liver metastases – from 17% to 55% [4]. Five-year overall survival of patients treated with this schedule, i.e. classified as high-risk gestational trophoblastic neoplasia, has been reported to vary between 75% and 90% [5-7] but the presence of liver metastases correlated with only 27% long-term survival and dropped to 10% when concomitant brain metastases were present [8].

However, it was observed that in most of the patients with adverse outcomes choriocarcinoma developed from non-molar pregnancies and therefore they were not scheduled for hCG follow-up and consequently presented with extensive disease

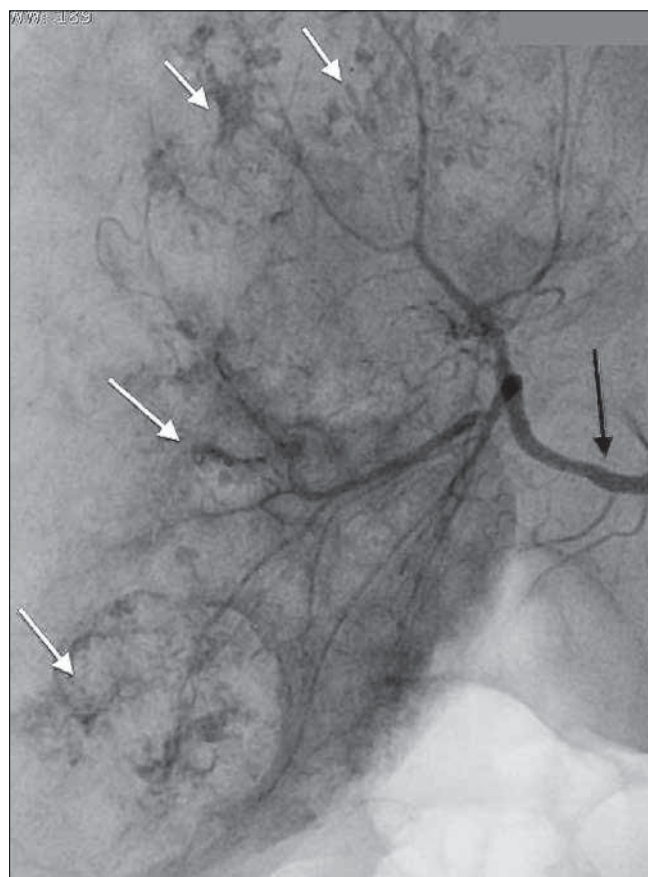


Figure 1. Angiography of the hepatic proper artery (black arrow) before embolization revealed plenty of hypervascularized areas of metastatic lesions (white arrows).

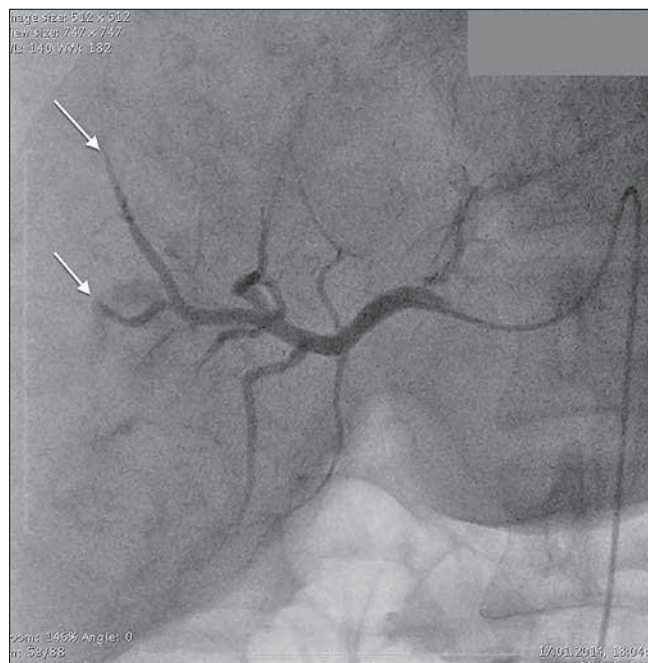


Figure 2. Angiography of the hepatic proper artery after embolization shows distal embolization of the hepatic artery branches (white arrows).

Table I. Choriocarcinoma modified WHO prognostic scoring system as adapted by FIGO [11].

Risk factor	Points			
	0	1	2	4
Age	<40	>40	-	-
Type of pregnancy	molar	abortion	full-term	-
Time lapse between the end of pregnancy and diagnosis (months)	<4	4-7	7-12	>12
hCG level	<10 ³	10 ³ -10 ⁴	10 ⁴ -10 ⁵	>10 ⁵
Size of the biggest tumour (cm)	<3	3-5	>5	-
Metastatic sites	lung	spleen, kidney	gastrointestinal tract	liver, brain
Number of metastases	0	1-4	5-8	>8
Previous chemotherapy	-	-	monochemotherapy	polychemotherapy
Our patient	TOTAL SCORE: 15			

and succumbed within 4 weeks of admission due to extensive hemorrhage or metabolic complications. When early deaths were excluded, survival increased to 68% [9].

Our patient was classified stage IV according to FIGO (distant metastases other than in lungs) and scored 15 points in the risk assessment scale used to indicate whether the patient should be given mono- or polychemotherapy where the score of 7 points or more is considered high risk (Table I), therefore she was administered chemotherapy with EMA-CO. The risk of developing massive hemorrhage from liver metastases is higher shortly after initiation of the treatment due to choriocarcinoma chemosensitivity and subsequent necrosis of the lesions. Lurain et al. reported 9 fatal cases of choriocarcinoma with hepatic metastases and in 7 of them identified liver hemorrhage as the cause of death [10].

Transcatheter embolization is an already established IR procedure in gynecology, e.g. uterine artery embolization is widely used in treatment of uterine fibromas [12]. What is more, endovascular treatment can be applied in emergency cases like massive bleedings. Hongsakul et al. report 5 cases of vaginal and 1 case of intra-peritoneal bleeding due to gestational trophoblastic disease treated by embolization of the uterine and/or hypogastric arteries achieving technical and clinical success in all cases [13].

Embolization of the hepatic artery has already been described in the treatment of liver bleeding due to primary hepatocellular carcinoma [14], as well as liver metastases other than gynecological [15], mainly from colorectal cancer. Hepatic metastatic lesions are supplied in blood by branches of the hepatic arteries whereas normal liver tissue is additionally supplied by the portal vein. This anatomical phenomenon let us to embolize arteries with the pathological vessels of the cancer tissue without or with very low risk of liver insufficiency as a complication of the procedure and makes it a safe and widely used therapeutic option. A study on 8 GTN patients with acute hemorrhagic complications described embolization of internal iliac arteries, uterine arteries and one case of hepatic artery embolization achieving 85,7% success rate [16].

Transcatheter embolization to supply hemorrhagic lesions of the liver is a safer and less invasive alternative to surgical

interventions such as packing or suturing, particularly because these patients are usually hemodynamically instable. It can be especially helpful when the lesions are multiple and the bleeding diffuse. Because of the highly vascular structure of the metastatic choriocarcinoma lesions and chemosensitivity of the tumor, after administration of chemotherapy they turn necrotic and tend to bleed extensively causing life-threatening hemorrhages that constitute a major clinical challenge. In such cases, emergency angioembolization is not only a life-saving measure but also a treatment modality that provides advantages such as avoidance of laparotomy, life-saving resection of the bleeding organ, general anesthesia. It can prove irreplaceable in case of diffuse bleeding. The presented case emphasizes the role of embolization to control hemorrhage and its usefulness in practically all fields of medicine.

Conclusions

To conclude, as choriocarcinoma can be effectively treated with chemotherapy, uncontrollable hemorrhagic complications are main clinical concern and the most common cause of death in metastatic patients. Angioembolization seems to be an optimal and effective way of ceasing the bleeding and a valuable alternative or complementary to surgery method of treatment in various medical specialties.

Oświadczenie autorów:

1. Agnieszka Lemańska – autor koncepcji i założeń pracy, przygotowanie manuskryptu i piśmiennictwa – zgłaszający i odpowiedzialny za manuskrypt.
2. Paulina Banach – współautor tekstu pracy, zebranie materiału, przygotowanie manuskryptu.
3. Katarzyna Stanisławska – zebranie współautor tekstu pracy, zebranie materiału, przygotowanie manuskryptu.
4. Robert Juszkat – korekta, nadzór merytoryczny.
5. Marek Spaczyński – ostateczna weryfikacja i akceptacja manuskryptu.
6. Ewa Nowak-Markwitz – korekta, ostateczna weryfikacja i akceptacja manuskryptu.

Agnieszka Lemańska et al. *Urgent embolization of hemorrhagic choriocarcinoma liver metastases – case report and review of the literature.*

KOMUNIKAT

Źródło finansowania:

badania statutowe Kliniki Onkologii Ginekologicznej UM w Poznaniu nr: 502-01-1110140-00257.

Konflikt interesów:

Autorzy nie zgłaszają konfliktu interesów oraz nie otrzymali żadnego wynagrodzenia związanego z powstawaniem pracy.

References

1. Spaczyński M, Nowak-Markwitz E, Kędzia W. *Praktyczna Onkologia Ginekologiczna – podręcznik dla lekarzy*. Poznań, 2012.
2. Alfidja A, Chabrot P, Cassagnes L, [et al.]. Vascular interventional procedures in oncology. *Bull Cancer*. 2007, 94 (2), 147-159.
3. Crawford RA, Newlands E, Rustin GJ, [et al.]. Gestational trophoblastic disease with liver metastases: The Charing Cross experience. *Br J Obstet Gynaecol*. 1997, 104, 105-109.
4. Barber EL, Schink JC, Lurain JR. Hepatic metastasis in gestational trophoblastic neoplasia: patient characteristics, prognostic factors, and outcomes. *J Reprod Med*. 2014, 59 (5-6), 199-203.
5. Kim SJ, Bae SN, Kim JH, [et al.]. Effects of multiagent chemotherapy and independent risk factors in the treatment of high-risk GTT—25 years experiences of KRI-TRD. *Int J Gynaecol Obstet*. 1998, 60 (Suppl 1), 85-96.
6. Bower M, Newlands ES, Holden L, [et al.]. EMA/CO for high-risk gestational trophoblastic tumours: results from a cohort of 272 patients. *J Clin Oncol*. 1997, 15, 2636-2643.
7. Turan T, Karacay O, Tulunay G, [et al.]. Results with EMA/CO (etoposide, methotrexate, actinomycin D, cyclophosphamide, vincristine) chemotherapy in gestational trophoblastic neoplasia. *Int J Gynecol Cancer*. 2006, 16, 1432-1438.
8. Seckl MJ, Sebire NJ, Berkowitz RS. Gestational trophoblastic disease. *Lancet*. 2010, 376, 717-729.
9. Ahamed E, Short D, North B, [et al.]. Survival of women with gestational trophoblastic neoplasia and liver metastases: is it improving? *J Reprod Med*. 2012, 57, 262-269.
10. Lurain JR, Brewer JL, Mazur MT, Torok EE. Fatal gestational trophoblastic disease: an analysis of treatment failures. *Am J Obstet Gynecol*. 1982, 144 (4), 391-395.
11. FIGO Committee on Gynecologic Oncology. Current FIGO staging for cancer of the vagina, fallopian tube, ovary, and gestational trophoblastic neoplasia. *Int J Gynaecol Obstet*. 2009, 105 (1), 3-4.
12. Woźniakowska E, Milart P, Paszkowski T, [et al.]. Uterine artery embolization—clinical problems. *Ginekol Pol*. 2013, 84 (12), 1051-1054.
13. Hongsakul K, Songjamrat A, Rookkapan S. Transarterial embolization for the treatment of massive bleeding in gynecologic and obstetric emergencies: a single center experience. *Emerg Radiol*. 2014, 21 (4), 333-339.
14. Shin BS, Park MH, Jeon GS. Outcome and prognostic factors of spontaneous ruptured hepatocellular carcinoma treated with transarterial embolization. *Acta Radiol*. 2011, 52 (3), 331-335.
15. Campbell DR, Mason WF, Flemming BK, Fraser DB. Therapeutic embolization of the hepatic artery. *J Can Assoc Radiol*. 1985, 36 (3), 212-215.
16. Keenanasseril A, Suri V, Prasad GR, [et al.]. Management of massive hemorrhage in patients with gestational trophoblastic neoplasia by angiographic embolization: a safer alternative. *J Reprod Med*. 2011, 56 (5-6), 235-240.

Young women

Międzynarodowa
Konferencja
Naukowaw ginekologii, endokrynologii,
psychiatrii i prawie14–16 stycznia 2016
Szczyrk, Hotel KLIMCZOK

Interdyscyplinarny program oparty o aktualne i najbardziej interesujące zagadnienia ginekologii Young Women. Panele z obszaru ginekologii, endokrynologii, prawa i psychiatrii.

W gronie wykładowców eksperci i specjaliści w poszczególnych dziedzinach, z Polski i zagranicy.

Na uczestników czeka wiele niespodzianek, które uatrakcyjnią zimowy pobyt w Szczyrku.

SESJE TEMATYCZNE

- Zespoły hyperandrogenne
- Endometrioza
- Endokrynologia Young Women
- Debata: Krwawienia Young Women
- Ciąża Young Women
- Anti-aging – nowa czy stara gałąź medycyny?
- Zabiegi plastyczne i rekonstrukcyjne Young Women
- Onkologia – rak szyjki macicy
- Antykoncepcja Young Women
- Debata: USG
- Zaburzenia żywienia
- Skulturowość w życiu codziennym lekarza praktyka
- Aspekty prawne w ginekologii Young Women
- Problemy urologiczne Young Women
- Sesja prac oryginalnych

PATRONATwięcej informacji: www.grupamedica.pl