

Placental examination with dye injections in post-delivery chorionicity assessment in dichorionic triplet pregnancy

Technika iniekcji naczyniowej w poporodowej ocenie kosmówkowości w trojaczej ciąży dwukosmówkowej

Michał Lipa¹, Dorota A. Bomba-Opoń¹, Iwona Szymusik¹, Katarzyna Kosińska-Kaczyńska¹, Robert Brawura Biskupski Samaha¹, Piotr Węgrzyn², Mirosław Wielgoś¹

¹ I Katedra i Klinika Położnictwa i Ginekologii, Warszawski Uniwersytet Medyczny, Warszawa, Polska

² Klinika Położnictwa i Perinatologii Warszawski Uniwersytet Medyczny, Warszawa, Polska

Abstract

The incidence of spontaneous triplet pregnancy is approximately 1 in 7000 deliveries. Due to the fact that every presentation of a triplet and higher order pregnancy is associated with high rate of morbidity and preterm delivery, chorionicity and amnionity remain significant predictive factors which determine specific management throughout the pregnancy. Ultrasound chorionicity assessment in triplet pregnancies is more complex than in twins, and in many cases it remains unknown.

We present a case report of a 24-year-old primipara in a spontaneous dichorionic triplet pregnancy, qualified for a cesarean section at 33 weeks of gestation, with subsequent placental examination with dye injections and post-delivery chorionicity assessment.

Key words: **mono chorionic twins / chorionicity / triplet pregnancy/ placenta / examination /**

Streszczenie

Ciąże trojacze występują z częstością 1 na 7000 urodzeń. W związku z tym, że każdy typ ciąży mnogiej, w tym trojaczej, koreluje z wysoką śmiertelnością i odsetkiem porodów przedwczesnych, kosmówkowość i owodniowość pozostają ważnymi czynnikami prognostycznymi determinującymi postępowanie w trakcie ciąży. Ultrasonograficzna ocena kosmówkowości w ciążach trojacznych jest bardziej złożona niż w bliźniaczych i w wielu przypadkach pozostaje nieznana.

Prezentujemy przypadek dwukosmówkowej ciąży trojaczej u 24-letniej pierwotki rozwiązanej drogą cięcia cesarskiego w 33 tygodniu ciąży wraz z oceną kosmówkowości na podstawie poporodowego badania łożysk z wykorzystaniem techniki iniekcji naczyniowych.

Słowa kluczowe: **bliźnięta jednokosmówkowe / kosmówkowość / ciąża trojacza / badanie łożyska /**

Adres do korespondencji:

Dorota A. Bomba-Opoń
I Katedra i Klinika Położnictwa i Ginekologii, Warszawski Uniwersytet Medyczny
Plac Starynkiewicza 1/3, 05-080 Warszawa, Polska
Tel./fax.: + 48 22 583 03 01
e-mail: dbomba@wum.edu.pl

Otrzymano: 28.08.2015
Zaakceptowano do druku: 05.10.2015

Introduction

The incidence of spontaneous triplet pregnancy is about 1 in 6500-7000 deliveries (ranging from 6500 to 10000) [1]. Despite significant advances in the field of perinatology and neonatology, triplet pregnancies remain to be at a 90% risk of preterm delivery and severe prematurity, impaired long-term neurodevelopment, and high morbidity [2]. Due to the fact that every triplet gestation is at higher risk as compared to twins, chorionicity and amnionicity remain significant predictive factors of varying perinatal outcomes. There are three main presentations of triplets: trichorionic (three fetuses with three distinct placentas; TCT), dichorionic (monochorionic twins coexist with a single fetus with a separate placenta; DCT), and monochorionic (three fetuses share a common chorionic plate; MCT) [3]. According to Spencer et al., mean gestational age of the fetuses at delivery is lower if more triplets share the same placenta. MCT and DCT are associated with higher rates of adverse pregnancy outcomes as compared to TCT, mainly due to the risk of intrauterine demise, discordant growth of the fetuses as the result of unequal placental territory share, or imbalanced blood flow in inter-twin anastomoses [4]. Precise assessment of the chorionicity in triplet pregnancies is more complex as compared to twins. In monochorionic and trichorionic triplets, chorionicity evaluation remains clear as fetuses share a common placenta or are attached to three separate ones. On the other hand, identification of the monochorionic pair in dichorionic triplet pregnancy may not be precisely performed. We present a case report of a post-delivery placental examination with dye injections and chorionicity assessment in a spontaneous dichorionic triplet pregnancy.

Case report

A 24-year-old primipara in a spontaneous triplet pregnancy, complicated by pregnancy induced hypertension (PIH) and hypothyroidism, was referred to the Twin Pregnancy Out-Patient Clinic at 16 weeks of gestation with suspicion of a dichorionic triamniotic triplet pregnancy. Although the primary diagnosis was confirmed in post-delivery examination, chorionicity of the triplets remained unclear throughout the pregnancy. Cervical pessary, intravaginal progesterone and steroids were administered due to high risk of preterm delivery. Prenatal ultrasound surveillance included serial biometric measurements of the fetuses, amniotic fluid volumes assessment and Doppler waveforms analysis of umbilical artery (UA), ductus venosus (DV), and middle cerebral artery (MCA). According to ultrasound examination at 31+4 weeks, the estimated fetal weights (EFW) corresponded to 10.9, 65.6 and 10.0 percentiles. The patient was scheduled for an elective caesarean section at 33 weeks of gestation due to brain sparing in the fetus with the lowest estimated weight (CPR= 1.08 <5th percentile); cerebroplacental ratio). Three viable premature female newborns were delivered in discordant general condition: 1380 grams and Apgar score of 7/9 points (newborn I), 1670 grams and Apgar score of 8/9 (newborn II), and 1210 grams and Apgar score of 5/5 (newborn III) at 1 and 5 minutes. Due to prematurity-related complications, the newborns were transferred to a neonatal intensive care unit (NICU).

During the caesarean section, each of the umbilical cords was clamped to mark the delivery order. After the delivery, the placentas were stored for a subsequent examination. Umbilical vessels were catheterized and injected with dyes to analyze the

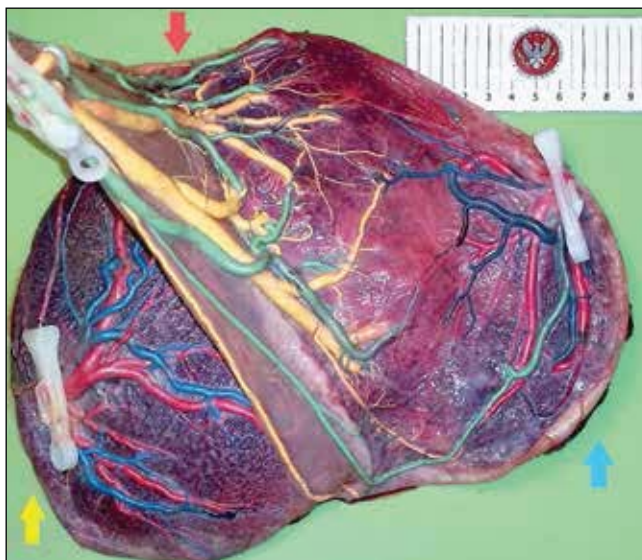

Figure 1. Complete placental mass after post-delivery examination with dye injections. Arteries catheterized and injected with blue and green, veins with red and yellow dye. Arrows indicating every fetus' placenta (fetus II = yellow; fetus I = red; fetus III = blue).

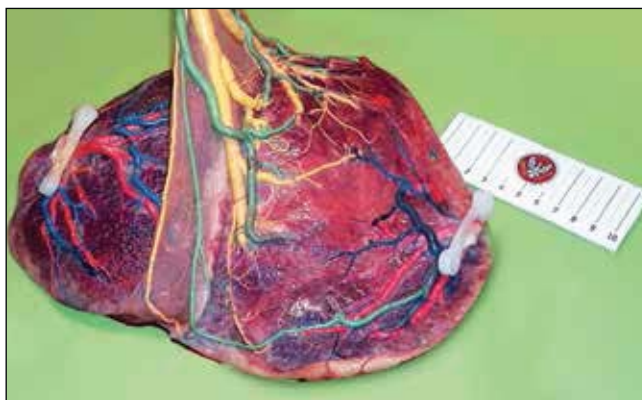


Figure 2. Velamentous cord insertion of the newborn I located in the central part of the placental mass.

vascular structure (veins were injected with red and yellow dye, and arteries were injected with blue and green). In the process of digital analysis, the placental angio-architecture including inter-twin anastomoses, was determined. The placental territory was calculated and the results were correlated with neonatal data.

The post-delivery examination revealed that all three placentas were fused together, and detached spontaneously. The total weight of the placentas was 940 grams. The cord insertions were: velamentous, marginal and marginal, respectively to the delivery order. Each umbilical cord consisted of two umbilical arteries and a single umbilical vein. The post-delivery examination with dye injections revealed monochorionicity of fetus I and fetus III, and a separate chorionic plate of fetus II (Figure 1). Monochorionic twins were delivered in discordant general condition (7-9 and 5-5 points according to Apgar scale) and birth weight (1380 vs. 1210 grams; discordance 13.7%). Computer analysis with adjusted scale revealed monochorionic placental territory share of

Michał Lipa et al. Placental examination with dye injections in post-delivery chorionicity assessment in dichorionic triplet pregnancy.

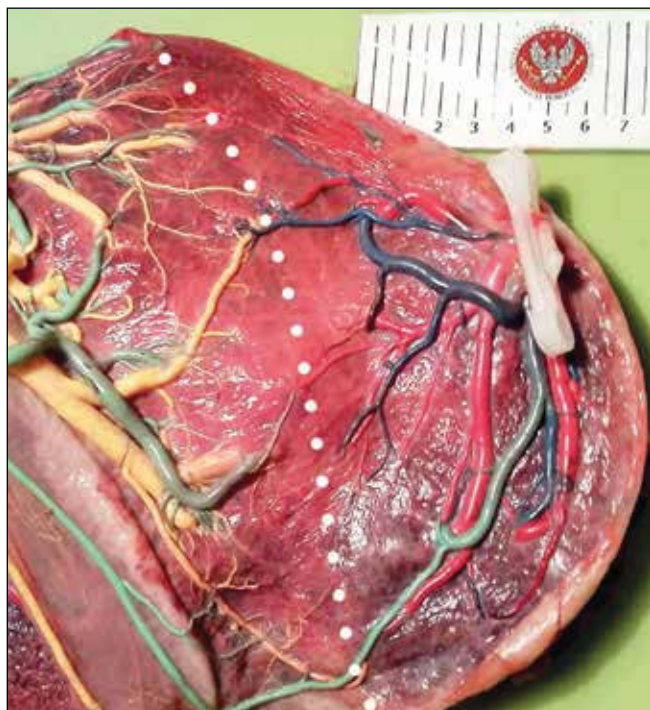

Figure 3. Intertwin anastomoses in monochorionic plate (white spots indicating vascular equator between I and III fetus; colors corresponding to specific type of anastomoses: AA = blue-green; AV = blue-yellow, red-green; VV = red-yellow anastomoses).

49.7 % (I) vs. 50.3% (III). The first fetus had an atypical velamentous cord insertion located in the central part of the fused placentas and the second monochorionic twin had a marginal cord insertion. Issues associated with ultrasound chorionicity assessment throughout pregnancy could have originated from the volume and location of the velamentous cord insertion of newborn I (Figure 2). Dye injection revealed inter-twin anastomoses: 1 arterio-arterial (AA), 9 arterio-venous (AV), and 2 veno-venous (VV) (Figure 3). Postnatal serum morphology parameters of the monochorionic fetuses were: WBC 9.0×10^3 u/l, RBC 4.48×10^6 u/l, HGB 18.7 g/dl, HCT 54.3% (fetus I) and WBC 6.7×10^3 u/l, RBC 3.85×10^6 u/l, HGB 15.9 g/dl, 46.4% (fetus III). Both twins developed respiratory distress syndrome (RDS) and sepsis after the delivery. The fetus attached to a separate chorionic plate was characterized by the highest birth weight (1680 grams) and the best perinatal outcome (transient respiratory dysfunction). The morphology parameters were: WBC 13.3×10^3 u/l, RBC 5.04×10^6 u/l, HGB 18.8 g/dl, HCT 55.3%. After 6 weeks, all infants were discharged from the NICU and currently remain under care of a pediatric out-patient clinic.

Discussion

In the era of assisted reproductive technique (ART), the number of multiple pregnancies has increased by over 400% [5]. That unexpected growth is the reason why significant amount of attention has been given to *in vitro* fertilization (IVF) procedures in infertility treatment centers, as multiple pregnancies remain one of the undesired complications. Some authors report that triplet pregnancies require 4-times higher costs than singletons and almost 75% of triplets require admission to neonatal intensive

care units (NICUs) [6]. More strict policy regarding the number of the transferred embryos and the dosage of drugs administered for induction of the ovulation may have resulted in a decreased incidence of triplet gestations reported in the latest studies [7]. Although most of triplet and higher order pregnancies are attributed to ART, about 15-30% of triplets may be associated with more advanced maternal age at the time of spontaneous conception [8]. Moreover, ART increases the risk of monochorionicity about 7-8 times in multiple pregnancies [9].

Chorionicity and amnionicity are significant predictive factors in triplet pregnancies. Precise ultrasound evaluation implies specific management in the prenatal surveillance, as each presentation is associated with distinct perinatal outcomes. A retrospective analysis undertaken by Chaveeva et al., revealed that miscarriage and preterm delivery rates were lower in the TCT group as compared to the DCT group managed expectantly (3% and 35% vs. 9% and 45%, respectively) [10]. On the other hand, a cohort study performed by Kawaguchi et al., showed no significant differences in perinatal death rates between TCT and DCT [11]. Nonetheless, TCT is associated with lower risk of an adverse pregnancy outcome as compared to DCT [9]. Unfortunately, specificity of the chorionicity assessment decreases throughout the pregnancy. In cases with incomplete evaluation in the early first trimester, the precise diagnosis may not be possible in pregnancy. A multicenter study of triplet pregnancy outcomes by Morikawa et al., revealed that chorionicity remained unknown in almost 27% of triplet pregnancies (87 out of 320) [12]. Due to the fact that chorionicity assessment in triplet pregnancy is infinitely more complex than in twins, we were encouraged to perform a post-delivery placental examination with dye injections to confirm the primary diagnosis and determine the placental type for each fetus.

The presence of inter-twin anastomoses in every monochorionic pregnancy may be associated with imbalanced blood flow between the fetuses and remain the origin of the twin-to-twin transfusion syndrome (TTTS) or selective intrauterine growth restriction (sIUGR). Although TTTS and sIUGR are widely known from monochorionic twin pregnancies, both may affect monochorionic triplets as well. TTTS affects about 9% of monochorionic twins, whereas selective intrauterine growth restriction (sIUGR), defined as birth weight discordance of >25%, may affect up to 12.5- 36% of the gestations [13]. On the other hand, the incidence of these phenomena in monochorionic triplets remains unknown. According to various studies, placental territory share and the characteristics of inter-twin vascular anastomoses (type and diameter) determine the morbidity, intrauterine growth, and long-term neurodevelopment of the fetuses. In twins with significant discordance in placental sharing, the diameter of anastomoses and blood exchange are increasing to reduce the impact on the birthweight discordance [14]. In our case, dye injections in the post-delivery examination revealed a separate placenta of fetus II (1670 grams and in the best general condition) and monochorionicity of fetuses I and III with 1 arterio-arterial (AA), 9 arterio-venous (AV) and 2 veno-venous (VV) inter-twin anastomoses. The territories in the monochorionic placenta were similar (49.7% vs. 50.3%) and the discordance in birth weights was approximately 13.7% (1380 vs. 1210 grams). Moreover, identification of the monochorionic pair potentially may have one more clinical aspect, i.e. the analysis of serum hemoglobin concentrations

Michał Lipa et al. Placental examination with dye injections in post-delivery chorionicity assessment in dichorionic triplet pregnancy.

and the exclusion of the twin-anemia-polycythemia syndrome (TAPS), which affects the circulatory systems of monochorionic twins without amniotic fluid discordance [15]. In our case, the difference between postnatal serum hemoglobin concentrations in monochorionic pair was 2.8 g/dl (18.7 vs. 15.9 g/dl), and did not fulfill the TAPS criteria.

Conclusions

Placental examination with dye injections may be a useful technique for postnatal chorionicity assessment in multiple pregnancies, especially in triplets and high-order multiples.

Oświadczenie autorów:

1. Michał Lipa – autor koncepcji i założeń pracy, przygotowanie manuskryptu i piśmiennictwa.
2. Dorota A. Bomba-Opoń – zebranie materiału, analiza wyników, przygotowanie manuskryptu – autor zgłaszający i odpowiedzialny za manuskrypt.
3. Iwona Szymusik – współautor tekstu pracy, korekta i aktualizacja literatury.
4. Katarzyna Kosińska-Kaczyńska – współautor tekstu pracy, korekta i aktualizacja literatury.
5. Robert Brawura Biskupski Samaha – wykonanie badań laboratoryjnych, opracowanie wyników badań.
6. Piotr Węgrzyn – opracowanie koncepcji i założeń badań.
7. Mirosław Wielgoś – ostateczna weryfikacja i akceptacja manuskryptu.

Źródło finansowania: Praca nie była finansowana przez żadną instytucję naukowo-badawczą, stowarzyszenie ani inny podmiot, autorzy nie otrzymali żadnego grantu.

Konflikt interesów: Autorzy nie zgłaszają konfliktu interesów oraz nie otrzymali żadnego wynagrodzenia związanego z powstawaniem pracy.

References

1. Radwan P, Radwan M, Kobielska L, [et al.]. Live birth of monochorionic triamniotic triplets after in vitro fertilization and blastocyst transfer: case report and review of the literature. *Ginekol. Pol.* 2014, 85, 154-157.
2. Blumenfeld Z, Abdallah W, Sela-Guttmann O, [et al.]. Triplet gestation – prevention, risks & management dilemmas. *Open Women's Health J.* 2008, 2, 11-21.
3. Lamb DJ, Vink JM, Middeldorp CM, [et al.]. Effects of Chorionicity and Zygosity on Triplet Birth Weight. *Twin Research and Human Genetics.* 2012, 15 (2), 149-157.
4. Spencer JV, Ingardia CJ, Nold CJ, [et al.]. Perinatal and Neonatal Outcomes of Triplet Gestations Based on Placental Chorionicity. *Amer J Perinatol.* 2009, 26 (8), 587-590.
5. Martin JA, Hamilton BE, Sutton PD, [et al.]. Births: final data for 2002. *Natl Vital Stat Rep.* 2003, 52, 1-102.
6. Ettner SL, Christiansen CL, Callahan TL, [et al.]. How low birth weight and gestational age contribute to increased inpatient costs for multiple births. *Inquiry.* 1997, 98 (34), 325-339.
7. Blickstein I, Keith LG. The decreased rates of triplet births: Temporal trends and biologic speculations. *Am J Obstet Gynecol.* 2005, 193, 327-331.
8. Engmann L, Maconochie N, Tan SL, [et al.]. Trends in the incidence of births and multiple births and the factors that determine the probability of multiple birth after IVF treatment. *Hum Reprod.* 2001, 16, 598-605.
9. Bajoria R, Ward SB, Adegbite AL. Comparative study of perinatal outcome of dichorionic and trichorionic iatrogenic triplets. *Am J Obstet Gynecol.* 2006, 194, 415-24.
10. Chaveeva P, Kosinski P, Puglia D, [et al.]. Trichorionic and Dichorionic Triplet Pregnancies at 10-14 Weeks: Outcome after Embryo Reduction Compared to Expectant Management. *Fetal Diagn Ther.* 2013, 34, 199-205.
11. Kawaguchi H, Ishii K, Yamamoto R, [et al.]. Perinatal death of triplet pregnancies by chorionicity. *Am J Obstet Gynecol.* 2013, 209, 36.e1-7.
12. Morikawa M, Cho K, Yamada T, [et al.]. Clinical features and short-term outcomes of triplet pregnancies in Japan. *Int J Gynaecol Obstet.* 2013, 121, 86-90.
13. Ortlieb E, Lopriore E, Deprest J, [et al.]. The pregnancy and long-term neurodevelopmental outcome of monochorionic diamniotic twin gestations: a multicenter prospective cohort study from the first trimester onward. *Am J Obstet Gynecol.* 2009, 200 (494), 491-498.
14. Lopriore E, Pasmán SA, Klumper FJ. Placental characteristics in growth-discordant monochorionic twins: a matched case-control study. *Placenta.* 2012, 33 (3), 171-174.
15. Slaghekke F, Kist WJ, Oepkes D, [et al.]. Twin Anemia-Polycythemia Sequence: Diagnostic Criteria, Classification, Perinatal Management and Outcome. *Fetal Diagn Ther.* 2010, 27, 181-190.

Polish Gynaecology

Ginekologia Polska

Warunki prenumeraty

Uprzejmie informujemy, iż członkowie Polskiego Towarzystwa Ginekologicznego będą otrzymywali „Ginekologię Polską” po wcześniejszym opłaceniu składki członkowskiej w odpowiednim Oddziale PTG.

Wysyłka Ginekologii Polskiej do członków PTG jest dokonywana na podstawie list dostarczonych z poszczególnych oddziałów PTG do Redakcji „Ginekologii Polskiej”.

Uprzejmie prosimy wszystkich zainteresowanych o zaktualizowanie danych adresowych w swoich Oddziałach PTG.

Koszt rocznej prenumeraty (krajowa i zagraniczna) dla osób nie będących członkami PTG i instytucji na 2015 rok wynosi: 180,00 PLN. +VAT.

Zamówienie wraz z kserokopią dowodu wpłaty prosimy przesyłać na adres:

Redakcja „Ginekologii Polskiej”
Małgorzata Skowrońska
60-535 Poznań, ul. Polna 33

fax.: +61 84-19-690
tel.: 571 28 79 79

e-mail: ginpol@onet.eu

www.ginekologiapolska.pl

Wpłaty należy dokonywać na konto:
ING Bank Śląski
14 1050 1953 1000 0023 1354 3718

Instrukcja dla autorów w języku polskim i angielskim znajduje się na stronie:

www.ginekologiapolska.pl

Redakcja