

Successful autotransplantation of cryopreserved ovarian tissue with recovery of the ovarian function

Udany przeszczep tkanki jajnikowej poddanej kriokonserwacji wraz z powrotem czynności hormonalnej jajnika

Paweł Radwan^{1,2}, Adam Abramik¹, Jacek Wilczyński³, Michał Radwan^{1,4}

¹ Gameta Hospital – Lodz, Poland

² Biogeno - Regional Science-Technology Centre (RS-TC) Checiny- Kielce, Poland

³ Department of Gynecology & Oncological Gynecology, Polish Mother's Health Center Research Institute, Lodz, Poland

⁴ Gameta – Gdynia Fertility Center, Gdynia, Poland

Abstract

Objectives: The aim of the study was autotransplantation of cryopreserved ovarian tissue to a patient suffering from premature ovarian failure caused by aggressive oncological therapy.

Material and methods: A 28-year-old woman, GII PI, was diagnosed with invasive adenocarcinoma of the cervix at 18 weeks of gestation. At 31 weeks of gestation, a cesarean section was performed, resulting in the delivery of a healthy male newborn, followed by simultaneous, radical hysterectomy with bilateral salpingo-oophorectomy and lymphadenectomy. Half of each ovary was cryopreserved. The patient was scheduled for radiochemotherapy, supplemented with brachytherapy. After the intervention, the patient experienced menopausal symptoms. The basal hormonal levels were: estradiol – 2 pg/ml, FSH – 96.52 IU/ml, LH – 37.55 IU/ml, AMH – 0.03 ng/ml. Thirteen months after surgery, the peritoneal pocket was formed on the anterior abdominal wall during laparoscopy and heterotrophic autotransplantation of the frozen-thawed ovarian tissue was performed, replacing 59% of the tissue.

Results: Nine weeks after transplantation, symptom resolution, an increase in estradiol (53 pg/ml), and a decrease in FSH (64.89 IU/ml) and LH (33.39 IU/ml) levels were noted. Twenty-four weeks after transplantation, high estradiol levels (269 pg/ml), normal level of FSH (5.92 IU/ml) and LH (4.09 IU/ml), and an increase in AMH (0.37 ng/ml) were observed. Follicular development in the transplanted ovarian tissue was confirmed.

Conclusions: Cryopreservation and transplantation of ovarian tissue allowed to restore the ovarian function. It could offer an alternative physiological solution to treating premature ovarian failure caused by oncological therapy.

Key words: **ovarian tissue cryopreservation / fertility preservation /
freezing ovarian tissue / premature ovarian failure /
premature ovarian insufficiency / menopause /**

Corresponding author:

Paweł Radwan
Gameta Hospital – Lodz
Poland, 90-419 Rzgów, Rudzka 34/36
Tel. 48 42 645 77 77; fax. 48 42 645 75 00
e-mail: pradwan@gameta.pl

Otrzymano: 25.01.2016
Zaakceptowano do druku: 05.02.2016

Paweł Radwan et al. Successful autotransplantation of cryopreserved ovarian tissue with recovery of the ovarian function.

Streszczenie

Cel pracy: Celem pracy był autologiczny przeszczep tkanki jajnikowej poddanej kriokonserwacji u pacjentki z przedwczesnym wygaśnięciem czynności jajników po agresywnej terapii onkologicznej.

Materiał i metody: W 18 tygodniu ciąży u 28 letniej ciężarnej (C2P1) rozpoznano inwazyjną postać gruczolowego raka szyjki macicy. W 31 tygodniu przeprowadzono elektywne cięcie cesarskie, podczas którego urodził się noworodek płci męskiej (1780g Apgar 8/10). Następnie wykonano radykalne wycięcie macicy techniką „nerve-sparing” z przydatkami, węzłami chłonnyymi biodrowymi i około aortalnymi dolnymi. Jajniki poddano kriokonserwacji techniką powolnego zamrażania. Pacjentka przeszła cykl radiochemioterapii z następczą brachyterapią. Przedwczesne wygaśnięcie czynności jajników potwierdzono pomiarem hormonów płciowych: estradiol – 2 pg/ml, FSH – 96,52 IU/ml, LH – 37,55 IU/ml, AMH – 0,03 ng/ml. Trzydzieści miesięcy po zabiegu chirurgicznym w powłokach brzusznych laparoskopowo wytworzono zachyłek otrzewnowy, w którym umieszczono rozmrożoną tkankę jajnikową

Wyniki: Dziewięć tygodni po transplantacji uzyskano remisję objawów wypadowych, wzrost stężenia estradiolu (53 pg/ml), spadek FSH (64,89 IU/ml) i LH (33,39 IU/ml). Dwadzieścia cztery tygodnie po zabiegu zaobserwowano wysokie stężenia estradiolu (269 pg/ml), fizjologiczne stężenia FSH (5,92 IU/ml), LH (4,09 IU/ml) oraz wzrost stężenia AMH (0,37 ng/ml). Podczas badania ultrasonograficznego w przeszczepionej tkance jajnika uwidoczniiono pęcherzyk dominujący

Wnioski: Przeszczep tkanki jajnikowej spowodował powrót czynność hormonalnej jajnika. Transplantacja tkanki jajnikowej może posłużyć, jako alternatywne leczenie przedwczesnej menopauzy spowodowanej agresywnym leczeniem onkologicznym.

Słowa kluczowe: **przeszczep tkanki jajnikowej / zachowanie płodności / mrożenie tkanki jajnikowej / przedwczesne wygaśnięcie czynności jajników / menopauza /**

Introduction

Aggressive treatment is often the only way to ensure the survival of oncology patients. One of the complications following therapy is a complete loss of ovarian function in women of reproductive age. Women undergoing surgical treatment, chemotherapy, and radiotherapy are very likely to experience premature ovarian failure (POF), even though they are still in the reproductive age and some of them are nulliparous [1]. Nowadays, effective treatment has greatly increased the chances of survival. An oncological procedure is considered successful if the quality of patient life has been preserved, including reproductive or at least hormonal function of the ovaries [2]. Cryopreservation and autotransplantation of the ovarian tissue could be a potentially beneficial strategy to preserve reproductive function and hormonal activity in these cases [3]. We present the first case of successful heterotrophic autotransplantation of cryopreserved ovarian tissue carried out at the Gameta Hospital.

Material and methods

Patient

A 28-year-old woman, GII PI, was diagnosed with invasive villoglandular papillary adenocarcinoma of the cervix at 18 weeks of gestation. At 21 weeks of gestation, when the patient was for the first time hospitalized at the Department of Gynecology & Oncological Gynecology, Polish Mother's Health Center Research Institute, magnetic resonance imaging (MRI) showed an exophytic cervical lesion protruding from the anterior cervical labia into the vagina. The dimensions of the lesion were 54x42x29 mm, consistent with FIGO stage IB2. However, the majority of the tumor mass was located outside the cervix, with

only 1 cm stromal involvement, so radical hysterectomy was not excluded as the management option. Moreover, the parametria were not involved and no distant metastases to the liver or the lungs were observed, either. MRI showed enlarged pelvic lymph nodes, suggestive of metastases. The patient wished to maintain her pregnancy. At 31 weeks of gestation classic elective cesarean section was performed. A healthy male newborn (weight 1780g, Apgar score 8 points) was delivered. Next, both ovaries were removed. Each ovary was cut into two halves and rinsed in G-MOPS Plus (Vitrolife, Sweden). The two halves (50% of each ovary) were put into a 50 ml sterile transport tube containing an IVF medium (G-MOPS Plus, Vitrolife, Sweden) and transported on ice to the IVF laboratory at the Gameta Hospital for cryopreservation. Simultaneous radical 'nerve-sparing' Piver II hysterectomy and salpingectomy followed. Bilateral iliac and obturator lymphadenectomy was performed. Due to the presence of nodal metastases, confirmed pathologically during surgery, lower para-aortic lymphadenectomy was additionally performed.

The final pathological examination revealed pT1BN1 mucinous adenocarcinoma, without parametrial or vaginal involvement. However, the presence of tumor metastases was confirmed in one pelvic lymph node from each side. Para-aortic nodes were free of cancer. Four weeks after surgery, the patient was scheduled for intensity-modulated radiation therapy (IMRT) (22 fractions 2Gy each), combined with weekly cisplatin of 40 mg/m². Teleradiotherapy was supplemented on afterloading high-dose rate (HDR) brachytherapy. There were no complications of radiotherapy, however, lymphocele was detected on the right-side.

Pawel Radwan et al. Successful autotransplantation of cryopreserved ovarian tissue with recovery of the ovarian function.

Freezing procedures of the ovarian tissue

The cortex was dissected and cut into 18 square pieces – 5 mm -5 mm, 1-2 mm of thickness (Photo 1). One sample was removed for an additional histology examination prior to cryopreservation in order to exclude the presence of cancer micro-metastases. The tissue was transferred to 30 ml of 0.1 mol/l sucrose and 1.5 mol/l ethylene glycol in phosphate-buffered saline supplemented with 10 mg/ml HSA, and equilibrated for 30 min. at 1°C on a tilting table. The fragments of the cortex were stored in 1.8 ml cryovials (Nunc, USA), each containing 1 ml of the cryoprotectant, and cryopreserved using a controlled-rate freezing system (Freez Control; Cryologic, Australia) [4]. The following program was used: 2°C/min. to -9°C, 5 min. of soaking, then manual seeding for the induction of ice crystal nucleation, 0.3°C/min to -40°C, and a 'free fall' of the temperature to -140°C. Next, the samples were plunged into liquid nitrogen at -196°C [5].

Protocol validation and safety – xenotransplantation of the patient's frozen-thawed ovarian tissue into an immunodeficient mouse

Two frozen-thawed ovarian cortical pieces were transported to the Laboratory of Reproductive Biology, Juliane Marie Center for Children, Women and Reproduction, University Hospital of Copenhagen, Denmark. An immunodeficient mouse (strain: Bom NMRI-nu, M&B A/S, Denmark) was ovariectomized. One week after ovariectomy, two frozen-thawed ovarian cortical pieces isolated from our patient were grafted. Two small pockets were created on each side of the back of the mouse using a pair of scissors. Without further manipulation, the tissue was left in the mouse for a period of 6 weeks, after which time the mouse was killed and the human tissue was recovered. Each tissue fragment was fixed in Bouin's solution and prepared for histology. Sections containing the ovarian tissue were reviewed to evaluate the number of the follicles present. The transplanted pieces of the ovarian tissue contained viable primordial follicles after a culture period of 6 weeks (Photo 2-4).

Laparoscopic autotransplantation of the ovarian tissue

Thirteen months after surgery, the patient was free of recurrence and prepared for ovarian autotransplantation. During that period, the patient reported menopausal symptoms and requested transplantation. Local Ethics Committee authorized the study (RNN/638/KD). An interdisciplinary team, consisting of a reproductive endocrinologist, gynecologist and oncological gynecologist, approved of the treatment. Due to the presence of a 6-7cm lymphocele, the patient was scheduled for laparoscopic removal of the lymphatic cyst, with simultaneous transplantation of the ovarian tissue subperitoneally, inside the anterior abdominal wall in Gameta Hospital

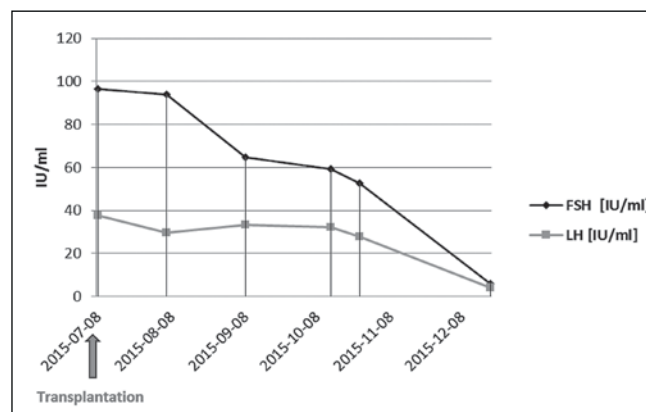


Figure 1. Dynamics of FSH and LH concentrations after transplantation of the cryopreserved ovarian tissue.

The peritoneal pocket was formed on the right side of the anterior abdominal wall. Ten strips (59% of the frozen tissue) were removed from liquid nitrogen (LN2) and thawed rapidly in a 37°C water bath. Subsequently, the pieces were transferred to 10ml of 0.75 mol/ml ethylene glycol and 0.25 mol/l sucrose in PBS (10 min) and then to 10 ml of 0.25 mol/l sucrose in PBS (10 min). All thawed tissues were immediately transferred into the peritoneal pocket within 10 minutes (Photo 6). The peritoneal pocket containing the ovarian tissue was closed using laparoscopic clips.

Results

Follow up post transplantation

On the day of the transplantation (July 8, 2015), the ovarian function was monitored by hormonal assay. The hormone levels were: estradiol – 2 pg/ml, FSH – 96.52 IU/ml, LH – 37.55 IU/ml, AMH – 0.03 ng/ml. The first signs of restoration of the ovarian function, namely resolution of the menopausal symptoms, an increase of estradiol (53 pg/ml), and a decrease of FSH (64.89 IU/ml) and LH (33.39 IU/ml) levels were observed 9 weeks after transplantation. Finally, 24 weeks after intervention, we noticed high estradiol levels (269 pg/ml) and normal FSH (5.92 IU/ml) and LH (4.09 IU/ml) levels (Table I; Figure 1). At the same time, ultrasound test revealed follicular development at the site of graft transplantation (Photo 7). The AMH level was 0.37 ng/ml.

Discussion

Our paper presents the results obtained after heterotopic human ovarian autotransplantation. The procedure continues to be regarded as experimental. The rest of our patients is still under oncological treatment or surveillance.

Table I. Changes of FSH, LH, estradiol and AMH profiles following the ovarian transplantation procedure.

	Transplantation 08.07.2015	06.08.2015	08.09.2015	14.10.2015	26.10.2015	20.12.2015
FSH [IU/ml]	96.52	93.95	64.89	59.41	52.83	5.9
LH [IU/ml]	37.55	29.6	33.39	32.13	27.86	4.03
Estradiol [pg/ml]	2	0	53	54	40	269
AMH [ng/ml]	0.03	0.05	0.11	0.11	0.1	0.37

Paweł Radwan et al. Successful autotransplantation of cryopreserved ovarian tissue with recovery of the ovarian function.

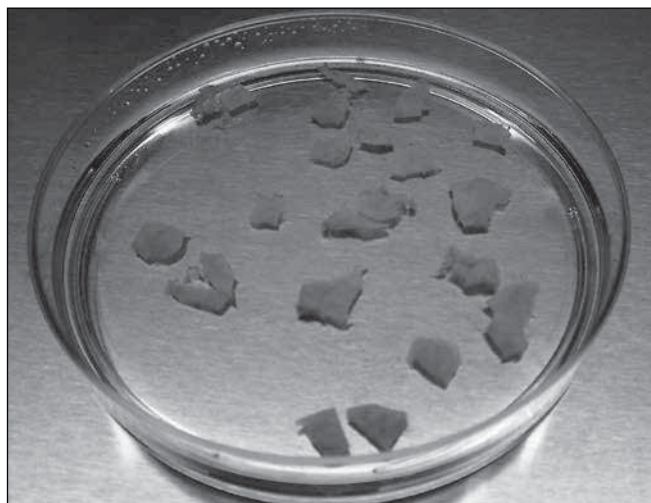


Photo 1. Dissected pieces of the ovarian cortex before cryopreservation.

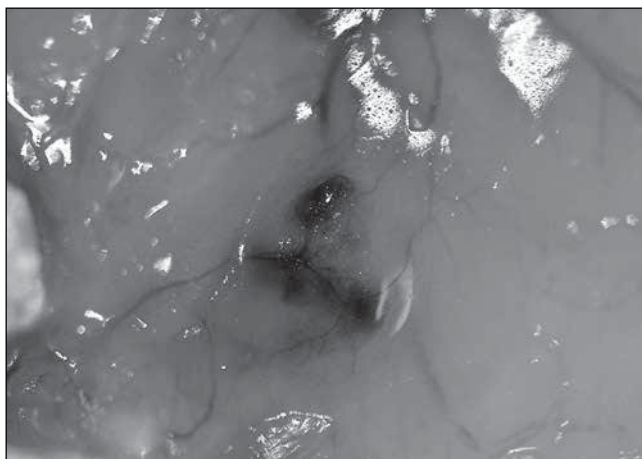

Photo 3. Pieces of frozen-thawed human ovarian cortex transplanted under the skin of the oophorectomized mouse. Macroscopically visible vascularization was observed after 6 weeks.

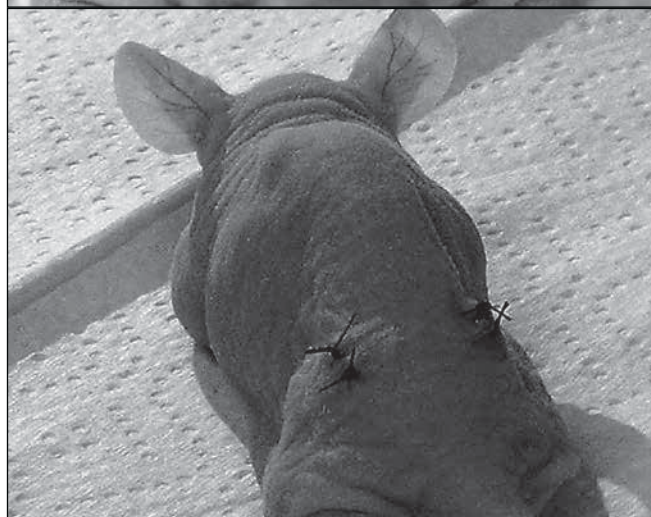
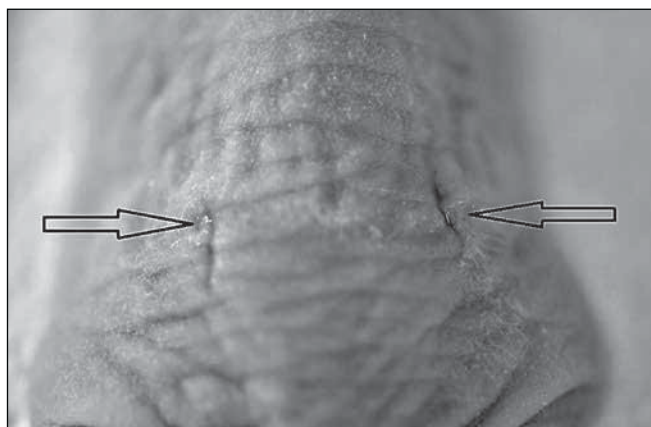


Photo 2 a, b. Two small pockets created on each side of the back of the mouse. The tissues were transplanted and left in the mouse for a period of 6 weeks.

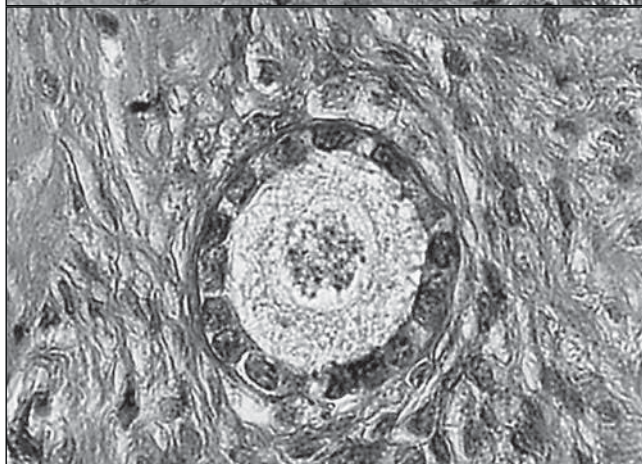
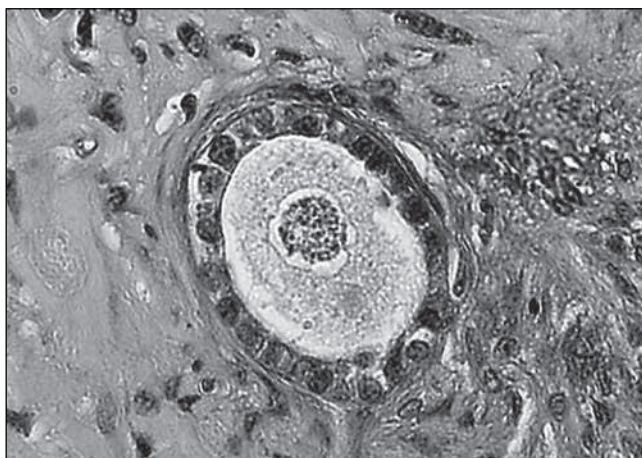


Photo 4 a, b. Pieces of the frozen-thawed human ovarian cortex transplanted under the skin of an oophorectomized mouse after 6 weeks histology showed healthy primordial follicles.

After radical panhysterectomy, the menopausal effects can be treated with hormonal replacement therapy (HRT). The available evidence for cervical cancer demonstrates no excessive risk of recurrence [4]. HRT is known to have a beneficial effect on menopause-related complications. Andersen et al., described cases of patients who benefited from long-term function of

grafted tissue. In their most recent paper, they postulate that this procedure may expand a woman's hormonal lifespan [5]. In 2012, Poirot et al., was the first to use frozen-thawed ovarian tissue for pubertal induction in a patient after bone marrow transplant [6]. In such cases, the frozen tissue should rather be used in the future to preserve fertility in these patients [7].

Paweł Radwan et al. Successful autotransplantation of cryopreserved ovarian tissue with recovery of the ovarian function.

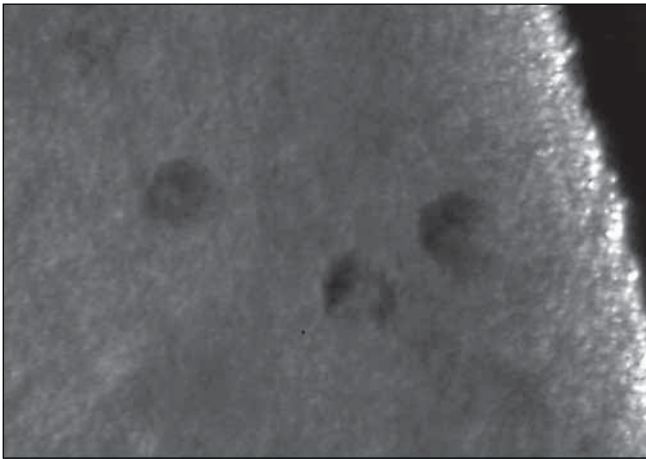


Photo 5. Frozen-thawed ovarian cortex of the patient stained with Neutral Red representing viable human follicles within the cortical tissue.

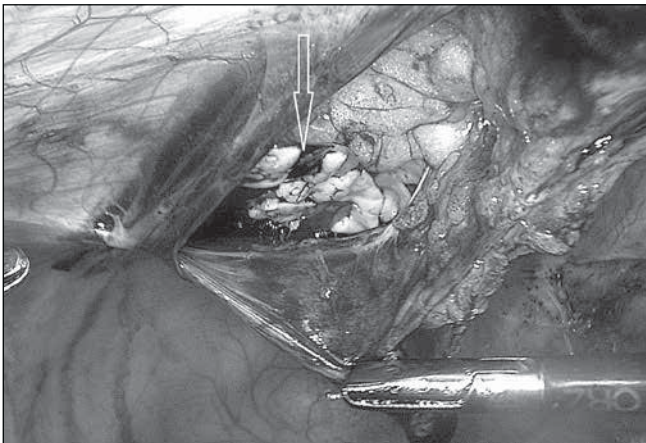


Photo 6. Laparoscopic autotransplantation of the ovarian tissue into the peritoneal pocket on the right side of the anterior abdominal wall.

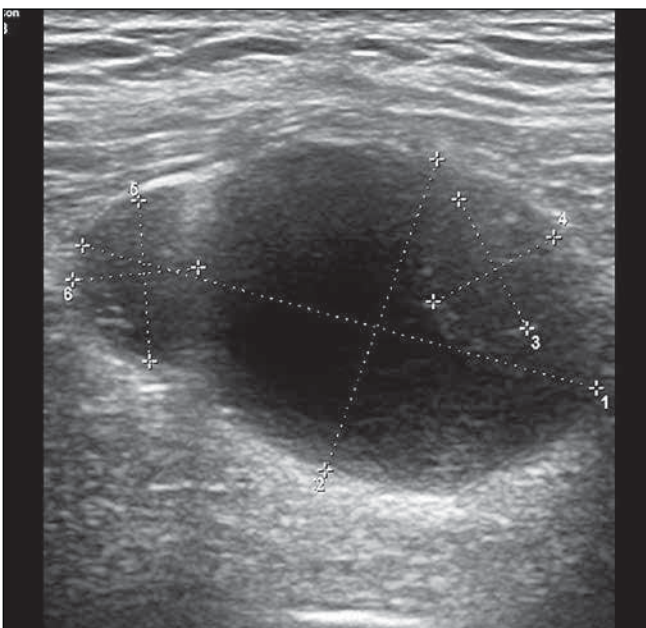


Photo 7. The leading follicle and antral follicles developed from the transplanted frozen-thawed ovarian tissue.

Cryopreservation of the ovarian tissue requires validation of the procedures, special skills and equipment, as well as trained staff. In order to ensure safety and efficiency of our program, we decided to validate the procedure using mouse models. Xenotransplantation of human ovarian tissue has been proposed as the 'gold standard' to control the quality of the procedure [8, 9]. After 6 weeks in the mouse, revascularization of the grafts, with 'healthy' primordial follicles and no signs of malignant disease, was observed.

There are two primary significant mechanisms which provoke follicle loss in the ovaries during the procedure, namely ischemia and the cryopreservation procedure [10]. Hence, it must be stressed that transport should occur as fast as possible [6]. In this case, the transport procedure from the operating theatre to the laboratory took less than one hour. Andersen et al., recommend to start cryopreservation within 5 hours after the procedure. However, in some cases this period could be prolonged even to 24 hours [11]. In such case, the patient can have the ovary removed in the local hospital, far away from a reproductive laboratory.

Ovarian tissue can be grafted subcutaneously, into the remaining ovary or inside the peritoneal pocket [12, 13]. In this case, the patient was scheduled for laparoscopy due to an iatrogenic lymphocele. At the same time, we could use ovarian tissue re-implantation. Aggressive surgery and radiochemotherapy completely changed the anatomical and functional conditions in the pelvis. The only rational solution was to create a peritoneal pocket, corresponding to the anterior abdominal wall. It was crucial not to use bi- or monopolar energy during the dissection.

In this case study, the ovarian function was restored within seven months after the procedure. FSH levels remained menopausal for a period of 24 weeks after transplantation until high levels of estradiol started to decline FSH to physiological levels. In other studies, the period between 16-42 weeks was required for the development of the pre-ovulatory follicle, with no strict correlation between age, quantity of the transferred or the number of follicles in the graft [8, 14]. Duration of the ovarian function varies from 7 months to more than 10 years [12]. Duration of the graft function depends on many factors, especially the number of immature oocytes which survived ischemia, freezing-thawing procedure, and the revascularization process [7, 10].

Safety and indications for the procedure remain the critical issues of ovarian autotransplantation. The risk of metastases continues to exist, especially in hematological diseases. Hence, more studies developing reliable, fast tests or improving the safety of ovarian tissue autotransplantation are needed [15, 16].

In the last decade, significant advances have been made in ovarian tissue cryopreservation, autotransplantation, and fertility preservation. This is an exciting new treatment, which could become an alternative physiological solution to prevent premature ovarian failure. However, extensive research is required before it can become a standard procedure in women with iatrogenic menopause.

Conclusions

The analysis of the first ovarian tissue transplantation showed that this procedure allowed restoration of the ovarian function, demonstrated by lack of menopausal symptoms, normalization of hormonal serum levels and follicle development.

Paweł Radwan et al. Successful autotransplantation of cryopreserved ovarian tissue with recovery of the ovarian function.

Frozen-thawed ovarian tissue transplantation could be an alternative physiological solution for treating iatrogenic menopause.

Acknowledgments:

We would like to thank prof. Claus Yding Andersen for his expert advice and encouragement throughout this project, as well as Dr Stine Gry Kristensen for validation of the laboratory procedure with xenotransplantation.

Oświadczenie autorów:

1. Paweł Radwan – conception of the study, laboratory procedures, tissue transplantation, following up the patent, drafting the article.
2. Adam Abramik – laboratory procedures, revising article.
3. Jacek Wilczyński – surgical procedures, tissue transplantation, revising article.
4. Michał Radwan – surgical procedures, tissue transplantation.

Źródło finansowania: Praca nie była finansowana przez żadną instytucję naukowo-badawczą, stowarzyszenie ani inny podmiot, autorzy nie otrzymali żadnego grantu.

Konflikt interesów: Autorzy nie zgłaszają konfliktu interesów oraz nie otrzymali żadnego wynagrodzenia związanego z powstawaniem pracy.

References

1. Stachowiak G, Zajac A, Wilczyński J. Premature ovarian failure. *Przegląd Menopauzalny*. 2012, 16 (2), 93.
2. Basta P, Streb J, Szczygiel K. Fertility-sparing treatment in female genital cancer and breast cancer. *Ginekol Pol*. 2015, 86 (6), 473-476.
3. Jakimiuk AJ, Fritz A. Ovarian tissue cryopreservation as a perspective for fertility preservation. *Endokrynologia Polska*. 2005, 56 (6), 998-1001.
4. O'Donnell RL, Clement KM, Edmondson RJ. Hormone replacement therapy after treatment for a gynaecological malignancy. *Curr Opin Obstet Gynecol*. 2016, 28 (1), 32-41.
5. Andersen CY, Kristensen SG. Novel use of the ovarian follicular pool to postpone menopause and delay osteoporosis. *Reprod Biomed Online*. 2015, 31 (2), 128-131.
6. Poirot C, Abirached F, Prades M, [et al.]. Induction of puberty by autograft of cryopreserved ovarian tissue. *Lancet*. 2012, 379 (9815), 588.
7. Wallace WH, Kelsey TW, Anderson RA. Ovarian cryopreservation: experimental or established and a cure for the menopause? *Reprod Biomed Online*. 2012, 25 (2), 93-95.
8. Rosendahl M, Schmidt KT, Ernst E, Rasmussen PE, Loft A, Byskov AG, Andersen AN, Andersen CY. Cryopreservation of ovarian tissue for a decade in Denmark: a view of the technique. *Reprod Biomed Online*. 2011, 22 (2), 162-171.
9. Jafarabadi M, Abdollahi M, Salehnia M. Assessment of vitrification outcome by xenotransplantation of ovarian cortex pieces in gamma-irradiated mice: morphological and molecular analyses of apoptosis. *J Assist Reprod Genet*. 2015, 32 (2), 195-205.
10. Xie S, Zhang X, Chen W, [et al.]. Developmental Status: Impact of Short-Term Ischemia on Follicular Survival of Whole Ovarian Transplantation in a Rabbit Model. *PLoS one*. 2015, 10 (8), e0135049.
11. Isachenko V, Isachenko E, Keck G, [et al.]. First live birth in Germany after re-transplantation of cryopreserved ovarian tissue: original device for initiation of ice formation. *Clin Lab*. 2012, 58 (9-10), 933-938.
12. Jensen AK, Kristensen SG, Macklon KT, [et al.]. Outcomes of transplantations of cryopreserved ovarian tissue to 41 women in Denmark. *Hum Reprod*. 2015, 30 (12), 2838-2845.
13. Jakimiuk AJ, Grzybowski W. Ovarian tissue preservation, present and clinical perspectives. *Gynecol Endocrinol*. 2007, 23 (2), :87-93.
14. Fabbri R, Pasquinielli G, Magnani V, [et al.]. Autotransplantation of cryopreserved ovarian tissue in oncological patients: recovery of ovarian function. *Future oncology* (London, England). 2014, 10 (4), 549-561.
15. Peek R, Bastings L, Westphal JR, [et al.]. A preliminary study on a new model system to evaluate tumour-detection and tumour-purging protocols in ovarian cortex tissue intended for fertility preservation. *Hum Reprod*. 2015, 30 (4), 870-876.
16. Rodriguez-Iglesias B, Novella-Maestre E, Herraiz S, [et al.]. New methods to improve the safety assessment of cryopreserved ovarian tissue for fertility preservation in breast cancer patients. *Fertil Steril*. 2015, 104 (6), 1493-1502.e1492

Polish Gynaecology

Ginekologia Polska

Warunki prenumeraty

Uprzejmie informujemy, iż członkowie Polskiego Towarzystwa Ginekologicznego będą otrzymywali „Ginekologię Polską” po wcześniejszym opłaceniu składki członkowskiej w odpowiednim Oddziale PTG.

Wysyłka Ginekologii Polskiej do członków PTG jest dokonywana na podstawie list dostarczonych z poszczególnych oddziałów PTG do Redakcji „Ginekologii Polskiej”.

Uprzejmie prosimy wszystkich zainteresowanych o zaktualizowanie danych adresowych w swoich Oddziałach PTG.

Koszt rocznej prenumeraty (krajowa i zagraniczna) dla osób nie będących członkami PTG i instytucji na 2015 rok wynosi: 180,00 PLN. +VAT.

Zamówienie wraz z kserokopią dowodu wpłaty prosimy przesyłać na adres:

Redakcja „Ginekologii Polskiej”
Małgorzata Skowrońska
60-535 Poznań, ul. Polna 33

fax.: +61 84-19-690
tel.: 571 28 79 79

e-mail: ginpol@onet.eu

www.ginekologiapolska.pl

Wpłaty należy dokonywać na konto:
ING Bank Śląski
14 1050 1953 1000 0023 1354 3718

Instrukcja dla autorów w języku polskim i angielskim znajduje się na stronie:

www.ginekologiapolska.pl

Redakcja