

The incidence of cervical intraepithelial neoplasia in a population of pregnant women with an abnormal cytology

Dominik Pruski^{1, 2}, Blanka Malkowska-Walczak², Aleksandra Paluszkiewicz¹, Witold Kędzia^{1, 2}

¹Division of Gynecology, Department of Perinatology and Gynecology, Gynecology and Obstetrics Clinical Hospital, Karol Marcinkowski University of Medical Sciences, Poznan, Poland

²Laboratory of Pathophysiology of Uterine Cervix, Gynecology and Obstetrics Clinical Hospital, Karol Marcinkowski University of Medical Sciences, Poznan, Poland

ABSTRACT

Objectives: To assess the incidence of cervical intraepithelial neoplasia — SIL and cervical cancer in a population of pregnant women with an abnormal cytology.

Material and methods: In pregnant women with abnormal cytology results according to The Bethesda System, a verifying diagnostics was carried out, including colposcopy and cervical biopsy.

Results: The most common histological and oncologic diagnosis in the whole study group of pregnant women were HGSIL changes, covering cervical intraepithelial neoplasia of medium and high grade — CIN 2 and CIN 3.

Conclusions: HGSIL changes are the most common oncological pathology in a population of pregnant women with an abnormal cytology. Precise risk identification of HGSIL changes with the use of molecular tests can significantly reduce the number of surgical procedures in a population of pregnant patients with a cytological diagnosis of ASCUS and LSIL.

Key words: cervical intraepithelial neoplasia, pregnancy, HGSIL

Ginekologia Polska 2017; 88, 1: 20–23

INTRODUCTION

Cervical intraepithelial neoplasia and cervical cancer are the most common cytological diagnosis in a population of pregnant women, being a worldwide health problem in the population [1]. In the United States from 2% to 7% of pregnant patients are diagnosed with an abnormal cytological result [2, 3]. The most important risk factor for cervical cancer and cervical intraepithelial neoplasia — CIN is a persistent infection with oncogenic types of human papillomavirus — HPV. Despite the decrease of morbidity and mortality due to cervical cancer in Poland in the last decade — following the introduction of the Ministerial Programme for Prevention of Cervical Cancer, cancer and CIN changes are one of the most recognized pathology of cancer in the population of pregnant patients [4, 5].

Verification of an abnormal Pap smear in the population of pregnant patients is a difficult issue since it is hard to specify algorithms and guidelines. Colposcopic images in pregnancy are very difficult to interpret, and thus implying a great risk of human error, due to a high level of examination's subjectivity [6, 7]. The doctor — a gynecologist often reflects on the legitimacy of performing a full diagnosis of the treatment — a cervical biopsy and the risk of complications of properly developing pregnancy in patients with questionable cytological diagnosis, assessed by The Bethesda System.

The following statistical analysis of the incidence of cervical intraepithelial neoplasia and cervical cancer in specific diagnoses of an abnormal Pap smear can significantly facilitate the development of additional algorithms, which will be characterized by a higher sensitivity and specificity

Corresponding author:

Dominik Pruski
Gynecology and Obstetrics Clinical Hospital
Karol Marcinkowski University of Medical Sciences
Polna St. 33, 60–535 Poznan, Poland
e-mail: dominik.pruski@oxytop.pl

to detect this type of pathology, and will be more accepted by a pregnant patient.

The aim of the study was the incidence of cervical intraepithelial neoplasia — LGSIL (low-grade squamous intraepithelial lesion) and HGSIL (high grade squamous intraepithelial lesion) and cervical cancer in a population of pregnant women with an abnormal pap smear.

MATERIAL AND METHODS

Statistical analysis included 184 pregnant patients at the age of 18 to 47, who reported to the Laboratory of Pathophysiology of Uterine Cervix in Gynaecology and Obstetrics Clinical Hospital of Karol Marcinkowski University of Medical Sciences, due to an abnormal Pap test assessed according to the Bethesda system in 2007–2015.

In all patients, the diagnostics was performed involving colposcopy and cervical biopsy. The above diagnostic treatment was carried out in Gynaecology and Obstetrics Clinical Hospital of the University of Medical Sciences. After the procedure, the patient remained under 24 hour observation in the hospital. The indication for cervical biopsy in pregnant patients were abnormal cytological diagnosis implying oncological pathology according to the Bethesda system. Abnormal cytological diagnoses included: ASC-US, LSIL, ASC-H, HSIL, AGC, and cancer respectively.

All patients qualified for the study were adults. Each patient gave a written consent for the study. Regardless of the histopathological result all the patients were informed of the need for strict cytological-colposcopic control every 3 months throughout the pregnancy and the year after giving birth, in the Laboratory of Pathophysiology Cervical Gynaecology and Obstetrics at the Clinical Hospital of the University of Medical Sciences. In case of an abnormal cytology, a suspicious colposcopic image or histopathological diagnosis of precancerous changes or cancer, further diagnostic and therapeutic procedure was carried out.

Statistical analysis was performed using GraphPad InStat version 3.10. Fisher's exact test was used to compare the incidence of specific histopathological diagnoses by age groups and the statistical significance was assumed at $p < 0.05$.

RESULTS

The most common histological and oncologic diagnosis in the whole study group of pregnant women were HGSIL changes, covering cervical intraepithelial neoplasia of medium and high grade — CIN 2 and CIN 3, which accounted for 38% (69/184). Pathology of LGSIL type defining low-grade cervical intraepithelial neoplasia has been estimated at 15% (28/184). In more than 47% (86/184) of patients tested with abnormal cytology there was no cervical pathology of cervical intraepithelial neoplasia and cancer — NILM (no intraepithelial lesion or malignancy) (Fig. 1). Only one patient was

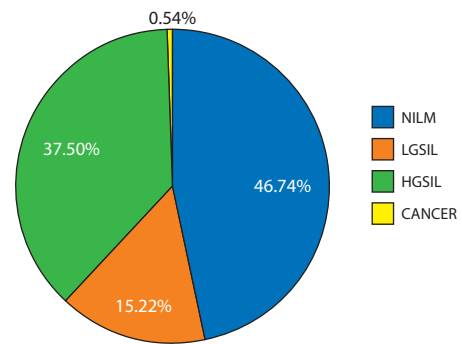


Figure 1. Percentage proportions of all histopathological diagnoses in the population of pregnant patients aged from 18 to 47 (n = 184)

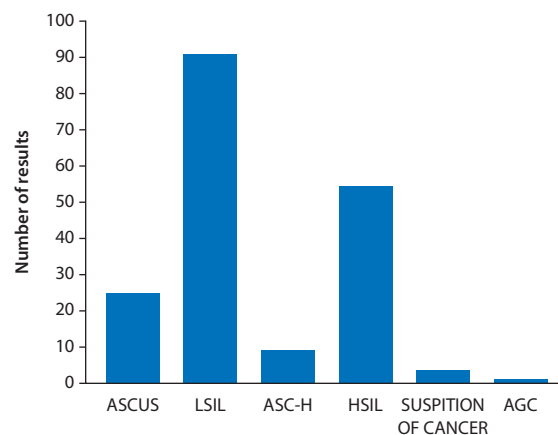


Figure 2. The number of individual abnormal cytologic diagnoses in the general population of pregnant patients

diagnosed with adenocarcinoma of the cervix, in whom surgical conization was performed during pregnancy. The patient gave birth to a healthy baby by a caesarean section.

The most common abnormal cytological diagnosis in the whole group of pregnant patients was diagnosis of LSIL and HSIL, which respectively accounted for 50% and 30% (Fig. 2).

In case of an abnormal cytology classified as HSIL, ASC-H and cytologically suspected cancer there is more than 62% risk of histopathological changes of HGSIL type (Fig. 3).

In case of an abnormal Pap smear, assessed as ASCUS and LSIL, the probability of not finding changes as precancerous and cancer is over 80% (Fig. 3).

The entire population of pregnant patients with abnormal cytology (n = 184) was divided into three age groups:

- less than 25 years old (n = 41),
- between 26 and 35 years old (n = 121),
- over 36 years old (n = 22).

In the group of patients under 25, LGSIL and HGSIL diagnoses accounted for 22% and 24% respectively. However, in the age group of 26 to 35, LGSIL HGSIL diagnoses accounted for 12% and 42% respectively. In the group of

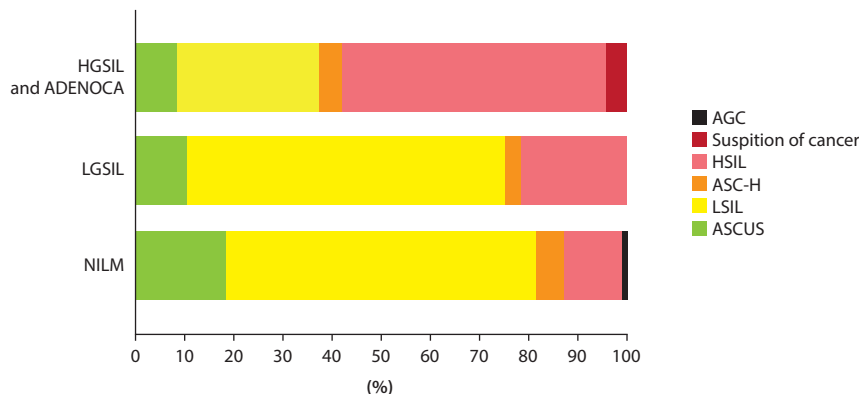


Figure 3. Percentage proportion of individual abnormal cytological diagnoses in pregnant patients with histopathologic diagnosis of HGSIL and adenocarcinoma, LGSIL or negative for intraepithelial lesion or malignancy — NILM

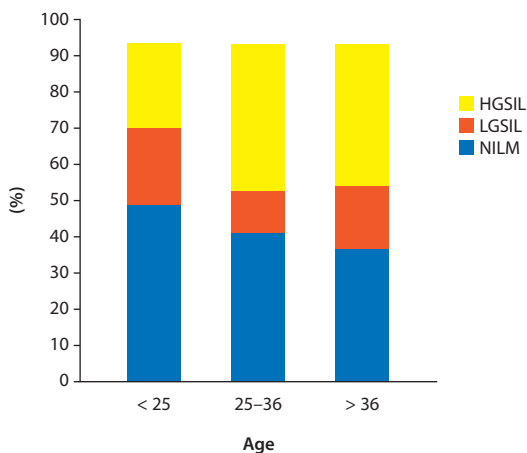


Figure 4. The incidence of histopathologic diagnoses in certain age groups

the eldest patients histopathological diagnosis of LGSIL accounted for 18%, and HGSIL diagnosis together with one case of adenocarcinoma accounted for 42% (Fig. 4). A statistically significant difference ($p = 0.0459$) was observed in the frequency of HGSIL type changes in patients aged less than 25, and a group of patients aged 26 to 35.

DISCUSSION

This retrospective analysis confirms a significant drop in the incidence of cervical cancer in a population of pregnant patients in all age groups in the Wielkopolska Region in 2007–2015. The most common oncologic diagnosis in the study population of pregnant women are HGSIL type changes covering cervical intraepithelial neoplasia of medium and high grade (Fig. 1). The above analysis clearly confirms the increase in the incidence of HGSIL type changes together with the increasing age of pregnant women, which is particularly observed and statistically significant between the group of patients under 25 and 26 to 35 years old. Similar

conclusions can be found in the 2007 Frega and associates, where the highest CIN incidence has been observed in the age group of 18 to 35 years old [8].

According to the work of Al-Halal of 2012, the incidence of cervical intraepithelial neoplasia — CIN covers from 1.3 to 2.7 of cases per 1.000 pregnant women [9]. According to the worldwide literature, HGSIL type changes undergo spontaneous regression during confinement depending on the publication from 48 to 70% [10, 11].

For many years, doctors have been looking for newer more sensitive and specific diagnostic tools to detect cervical cancer and cervical intraepithelial neoplasia. In times of significant decrease of cervical morbidity and mortality, to maintain the trend in the incidence and mortality of cervical cancer in Poland and to identify the most important risk factor for developing this type of cervical pathology — which is a persistent infection with oncogenic HPV types, we are witnesses of major changes in the preventive programs in Western European countries and in the US, and in a moment also in Poland. In the near future, a molecular test identifying a genetic DNA material or mRNA transcripts of highly oncogenic types of human papillomavirus can replace cytological programs to prevent cervical cancer patients including both non-pregnant and pregnant patients [12].

Precise identification of the risk of HGSIL type (CIN 2, CIN 3) changes and distinguishing them from LGSIL type (CIN 1) changes, using molecular diagnostics might help to decrease surgical procedures in the population of pregnant women, cytologically diagnosed with ASCUS and LSIL.

The development of recent years is an application of tests for mRNA transcripts of oncogenes E6 / E7 — highly oncogenic types of human papillomavirus, which allow the identification of patients with persistent viral infection, in whom the process of incorporation of viral DNA into the genetic material of epithelium’s cells has begun. This diagnosis is characterized by a very high sensitivity and

specificity of 98% and 85% respectively and a high level of objectivity and study reproducibility in a population of not pregnant patients [13]. The method of obtaining material for molecular diagnostics is a non-invasive method, which does not affect the pregnancy.

In summary, the above retrospective analysis clearly indicates the necessity to complement the diagnosis of molecular test that detects highly oncogenic types of human papillomavirus, which allows for more precise identification of groups at risk of HGSIL type in the population of pregnant patients with abnormal cytology of ASCUS or LSIL

CONCLUSIONS

HGSIL changes including cervical intraepithelial neoplasia of medium and high grade were the most common oncological pathology in the population of pregnant women with an abnormal cytology. Precise identification of the risk of incidence of HGSIL type changes using molecular diagnostic tests can significantly reduce the number of surgical procedures in the population of pregnant patients with a cytologic diagnosis of ASCUS.

REFERENCES

1. Insinga RP, Glass AG, Rush BB. Diagnoses and outcomes in cervical cancer screening: a population-based study. *Am. J. Obstet. Gynecol.* 2004; 191(1): 105–113, doi: 10.1016/j.ajog.2004.01.043, indexed in Pubmed: 15295350.
2. Douvier S, Fillipuzzi L, Sagot P. [Management of cervical intra-epithelial neoplasm during pregnancy]. *Gynecol Obstet Fertil.* 2003; 31(10): 851–855, indexed in Pubmed: 14642944.
3. Morimura Y, Fujimori K, Soeda S, et al. Cervical cytology during pregnancy — comparison with non-pregnant women and management of pregnant women with abnormal cytology. *Fukushima J Med Sci.* 2002; 48(1): 27–37, doi: 10.5387/fms.48.27, indexed in Pubmed: 12365596.
4. Dyzman-Sroka A, Trojanowski M, Kubiak A, et al. Nowotwory złośliwe w Wielkopolsce w 2012 roku. In: *Wielkopolski Rejestr Nowotworów. Biuletyn* 11. Wielkopolskie Centrum Onkologii, Poznań 2014.
5. Wojciechowska U, Didkowska J. Zachorowania i zgony na nowotwory złośliwe w Polsce, Krajowy Rejestr Nowotworów, Centrum Onkologii – Instytut im. M. Skłodowskiej-Curie, <http://onkologia.org.pl/raporty> z dnia 25/11/2014.
6. Pisharodi LR, Jovanoska S. Spectrum of cytologic changes in pregnancy. A review of 100 abnormal cervicovaginal smears, with emphasis on diagnostic pitfalls. *Acta Cytol.* 1995; 39(5): 905–908, doi: 10.1136/bmj.2.6193.753, indexed in Pubmed: 7571968.
7. Michael CW, Esfahani FM. Pregnancy-related changes: a retrospective review of 278 cervical smears. *Diagn. Cytopathol.* 1997; 17(2): 99–107, doi: 10.1002/(sici)1097-0339(199708)17:2<99::aid-dc4>3.3.co;2-6, indexed in Pubmed: 9258616.
8. Xavier-Júnior JC, Duflot RM, do Vale DB, et al. High-grade squamous intraepithelial lesions in pregnant and non-pregnant women. *Eur. J. Obstet. Gynecol. Reprod. Biol.* 2014; 175: 103–106, doi: 10.1016/j.ejogrb.2014.01.018, indexed in Pubmed: 24522115.
9. Al-Halal H, Kezouh A, Abenhaim H. Incidence and obstetrical outcomes of cervical intraepithelial neoplasia and cervical cancer in pregnancy. *Archives of Gynecology and Obstetrics.* 2012; 287(2): 245–250, doi: 10.1007/s00404-012-2475-3.
10. Al-Halal H, Kezouh A, Abenhaim HA. Incidence and obstetrical outcomes of cervical intraepithelial neoplasia and cervical cancer in pregnancy: a population-based study on 8.8 million births. *Arch. Gynecol. Obstet.* 2013; 287(2): 245–250, doi: 10.1007/s00404-012-2475-3, indexed in Pubmed: 23053308.
11. Ahdoot D, Van Nostrand KM, Nguyen NJ, et al. The effect of route of delivery on regression of abnormal cervical cytologic findings in the postpartum period. *Am. J. Obstet. Gynecol.* 1998; 178(6): 1116–1120, doi: 10.1016/s0002-9378(98)70310-2, indexed in Pubmed: 9662288.
12. Paraskeva E, Koliopoulos G, Kalantaridou S, et al. Management and evolution of cervical intraepithelial neoplasia during pregnancy and postpartum. *Eur. J. Obstet. Gynecol. Reprod. Biol.* 2002; 104(1): 67–69, doi: 10.1016/s0301-2115(02)00058-1, indexed in Pubmed: 12128266.
13. Reid JL, Wright TC, Stoler MH, et al. Human papillomavirus oncogenic mRNA testing for cervical cancer screening: baseline and longitudinal results from the CLEAR study. *Am. J. Clin. Pathol.* 2015; 144(3): 473–483, doi: 10.1309/AJCPHVD7MIP3FYVV, indexed in Pubmed: 26276778.
14. Andersson E, Kärrberg C, Rådberg T, et al. Type-specific human papillomavirus E6/E7 mRNA detection by real-time PCR improves identification of cervical neoplasia. *J. Clin. Microbiol.* 2011; 49(11): 3794–3799, doi: 10.1128/JCM.00549-11, indexed in Pubmed: 21940473.