

# Successful complex management of a congenital diaphragmatic hernia – a case report

## Skuteczne kompleksowe leczenie wrodzonej przepukliny przeponowej – opis przypadku

Kociszewska-Najman Bożena<sup>1</sup>, Rawicz Marcin<sup>2</sup>, Pietrzak Bronisława<sup>3</sup>, Szymusik Iwona<sup>3</sup>, Yaseen Sadeq<sup>4</sup>, Olszyńska-Bazała Bernadetta<sup>1</sup>, Biejat Agnieszka<sup>5</sup>, Węgrzyn Piotr<sup>3</sup>, Wielgoś Mirosław<sup>3</sup>

<sup>1</sup> Neonatology Ward, 1<sup>st</sup> Department of Obstetrics and Gynecology, Medical University of Warsaw, Poland

<sup>2</sup> 1<sup>st</sup> Department of Paediatric Anaesthesiology and Intensive Care, Medical University of Warsaw, Poland

<sup>3</sup> 1<sup>st</sup> Department of Obstetrics and Gynecology, Medical University of Warsaw, Poland

<sup>4</sup> Department of Paediatric Surgery, Medical University of Warsaw, Poland

<sup>5</sup> Department of Paediatric Radiology, Medical University of Warsaw, Poland

### Abstract

*Congenital diaphragmatic hernia is a very serious congenital defect associated with high mortality rate. The syndrome is characterized by migration of abdominal viscera to thoracic cavity, a variable degree of pulmonary hypoplasia associated with pulmonary hypertension caused by alteration of pulmonary vessels diameter, increased muscularisation of pulmonary arteries and decreased compliance of the lungs resulting in increased afterload of the right ventricle, decreased cardiac output and impaired oxygenation.*

*We describe a case of congenital diaphragmatic hernia with migration of the stomach, the small and the large bowels and the left hepatic lobe into the left pleural space, diagnosed by ultrasound in utero at 24 weeks of gestation. The child was initially placed on high-frequency oscillation and nitric oxide and required vigorous inotropic support. The defect was repaired after stabilization of the cardiac output and gas exchange. The patient made successful recovery.*

Key words: **congenital diaphragmatic hernia (CDH) / nitric oxide / high frequency oscillation (HFO) / pulmonary hypoplasia /**

### Streszczenie

*Wrodzona przepuklina przeponowa jest jedną z najcięższych wad u noworodków, obarczoną wysoką śmiertelnością z powodu niewydolności krążeniowo-oddechowej bezpośrednio po porodzie. Przyczyną takiego stanu rzeczy jest hipoplazja płuc z nierównomiernym ich rozwojem i ciężkie nadciśnienie płucne, prowadzące do niskiego rzutu serca i zaburzeń wymiany gazowej.*

### Corresponding author:

Bożena Kociszewska-Najman  
Neonatology Ward, 1<sup>st</sup> Department of Obstetrics and Gynecology, Medical University of Warsaw,  
Starynkiewicza Square 1/3; 02-015 Warsaw, Poland  
tel./fax: +48 22 5021202  
e-mail: bnajman@wp.pl; iwo.md@interia.pl

Otrzymano: 08.08.2011  
Zaakceptowano do druku: 25.09.2011

Kociszewska-Najman B, et al.

Przedstawiono opis przypadku przepukliny przeponowej rozpoznanej w 24. tygodniu ciąży, w której do klatki piersiowej przesunięciu uległy: żołądek, jelito cienkie i grube oraz fragment lewego płata wątroby. Opisano skuteczne kompleksowe leczenie przepukliny przeponowej w oddziale intensywnej terapii z wykorzystaniem wentylacji oscylacyjnej, leczenia inotropowego, tlenu azotu oraz odroczonego leczenia chirurgicznego do czasu ustabilizowania wydolności krążeniowo-oddechowej pacjenta. Dokonano przeglądu piśmiennictwa ukazującego właściwe postępowanie w przypadkach tej wady wrodzonej.

Słowa kluczowe: **wrodzona przepuklina przeponowa / tlenek azotu / wentylacja oscylacyjna (HFO) / hipoplazja płuc /**

## Introduction

Congenital diaphragmatic hernia, rare, but very severe congenital defect, occurs in 1:2000-1:3000 of pregnancies [1, 2].

The syndrome is characterized by migration of abdominal viscera to the thorax, a variable degree of pulmonary hypoplasia associated with pulmonary hypertension caused by alteration of pulmonary vessels diameter, increased muscularisation of pulmonary arteries and decreased compliance of the lungs resulting in increased afterload of the right ventricle, decreased cardiac output and impaired oxygenation.

The herniation of viscera in severe congenital diaphragmatic hernia is believed to occur during the pseudoglandular stage of lung development. Lung compression results in pulmonary hypoplasia that is most severe on the ipsilateral side, although both lungs may be abnormal. Pulmonary hypoplasia is associated with fewer bronchial generations, alveoli, and arterial generations resulting in reduction of gas exchange area. Ventilation of the lungs of different volumes and compliance leads to uneven distribution of the respiratory gases, overinflation and emphysema of the hypoplastic lung, and hypoventilation of the non-affected lung, additionally compressed by shifted mediastinum. Abnormal morphology of the vascular bed, resulting in decreased overall number of the vessels and their thickening, leads to increased afterload of the right ventricle and abnormal adaptation to the extrauterine life.

Infants usually present with severe hypoxic respiratory distress and low cardiac output immediately after birth, although appearance of the symptoms may be delayed, especially in less severe cases. At birth, acute respiratory failure with severe hypoxia and low cardiac output is observed, with its severity depending on a stage of pathology [3]. Pulmonary capillary blood flow is decreased due to impaired circulation and decreased number of alveolar units.

The diagnosis of congenital diaphragmatic hernia places the patient in the highest-risk group; therefore pregnancy and delivery should be cared for in a tertiary referral centre.

## Case report

The paper presents a case of congenital diaphragmatic hernia (CDH), diagnosed and managed in a tertiary referral centre.

Left-side CDH with migration of the stomach and both the small and large bowels into the thoracic cavity was diagnosed prenatally at 24 weeks of gestation. The lung-head ratio (LHR) was rated 0.98. Diagnostic cordocentesis revealed normal foetal karyotype (46XX). At 26 weeks of gestation, ultrasound revealed severe left CDH with pulmonary hypoplasia and LHR=1.2; the stomach and the bowels were above the diaphragm.

Additionally, there was dextrocardia, unobstructed drainage of the pulmonary veins from the right lung to the left atrium, left lung was not visible, and there was normal function of both ventricles. At 27 weeks the left lobe of the liver was found to be above the diaphragm. The LHR at 20 weeks was 1.9; amniotic fluid index (AFI) was 22. At 36 weeks LHR was 1.9 and AFI was 25. (Figure 1).

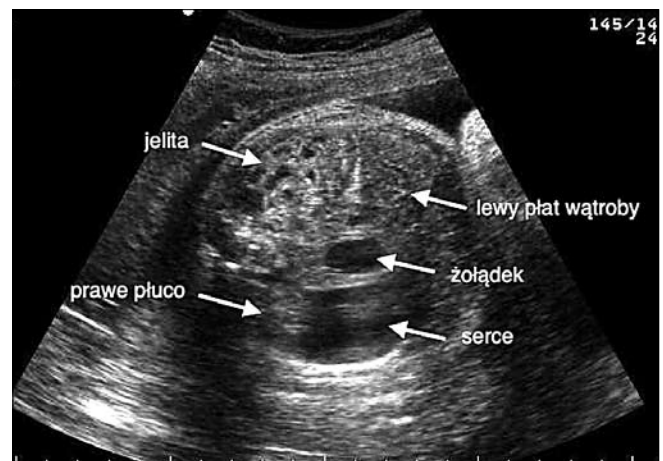

Figure 1. Sonographic cross-section of foetal thorax at 36 weeks gestation.

Elective caesarean section was performed at 39 weeks of gestation and a female newborn was delivered (Apgar 7, birth weight 2720 g, height 45cm, head circumference 35 cm, chest circumference 31.5cm) and was immediately intubated and placed on mechanical ventilation with 100% O<sub>2</sub>. An orogastric tube was inserted to decompress the stomach. Umbilical venous blood gas analysis was pH=7.09; pCO<sub>2</sub>=87.9; pO<sub>2</sub>=44.6; BE=-6.3. Auscultation revealed breath sounds on the right side only, heart rate was 120-130/min. (Figure 2).

The child was transferred to the Neonatal Intensive Care Unit and placed on SIMV with FiO<sub>2</sub>=1.0; f=70/min.; PIP=40mmHg; PEEP=5.5mmHg; arterial oxygenation was 97%. The baby was cardiovascularly stable; heart rate was 140-150/min and arterial blood pressure – 59/43mmHg (mean 49mmHg).

Over next few hours, condition of the child deteriorated, arterial oxygenation and cardiac output decreased, and child became acidotic. SIMV was replaced with high frequency oscillation (SensorMedics 3000, Ohio, USA) with distending pressure 15cm H<sub>2</sub>O, frequency 9Hz amplitude 38% and FiO<sub>2</sub> 0.8.

## Successful complex management of a congenital diaphragmatic hernia – a case report.

15ppm of nitric oxide was added to the inspiratory gas flow. The child required vigorous inotropic support (dopamine, dobutamine and adrenaline) and fluid resuscitation.

Over first five days of treatment the condition of the child became more stable, inotropic support and inspiratory oxygen concentration were reduced, and the house criteria for surgical intervention were fulfilled. During surgery, herniated viscera were removed from the pleural cavity and the diaphragmatic defect was repaired. Removed viscera were temporary placed in the external polyvinyl SILO bag. Left lung was small, hypoplastic and poorly expanding. (Figure 3).

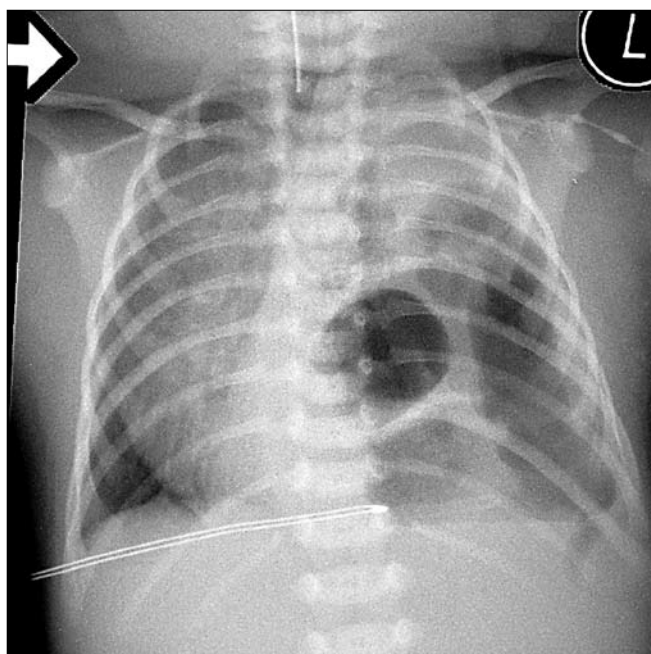


Figure 2. Chest x-ray immediately after birth.

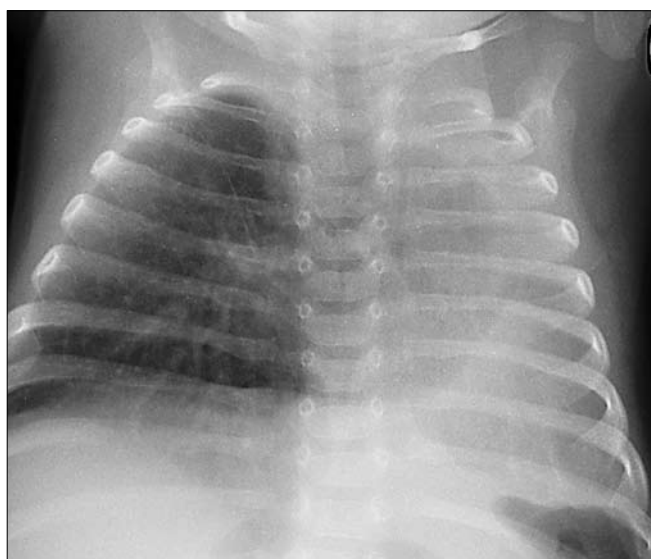


Figure 3. Chest x-ray of the neonate after surgery – day 5 of life.

After the surgery the HFO and nitric oxide were continued; oxygen concentration and mean airway pressure were gradually reduced. The capacity of the SILO bag was reduced daily, and its contents were pushed back to the peritoneal cavity allowing for complete closure of the abdomen on the 12th day of life. Five days later HFO was discontinued and the child was placed back on SIMV and subsequently weaned from mechanical ventilation and extubated. Unfortunately, over next five days the condition of the child deteriorated due to complete atelectasis of the left lung; the child was re-intubated, and emergency bronchoscopy was performed, revealing marked stenosis of the left main bronchus, just behind bifurcation of the trachea. Ventilation of the lung was not possible and after another two weeks of SIMV the child was extubated and placed on nCPAP; after another two days she was completely weaned from respiratory support and discharged home after 56 days of treatment without neurologic deficit or major pathology in the brain ultrasound. Before discharging, chest CT scan confirmed extreme hypoplasia of the left lung, relative emphysema of the right lung and cardiac silhouette shifted to the left.

The child was re-examined after reaching the fifth month of life. Due to marked gastro-oesophageal reflux she was underweight (body weight <3 centile). She was successfully treated with oral omeprazole (1mg/kg/24 hours) for eight weeks and eventually reached her normal weight. Physiotherapy and respiratory revalidation have been continued. At present, the general condition of the baby is good, somatic and psychomotor development are normal, she is free of upper respiratory tract infections.

## Discussion

Despite great progress in the perinatal medicine, and a possibility of early recognition, congenital diaphragmatic hernia is still associated with high mortality rate (up to 50%) [4, 5, 6, 7]. The postero-lateral Bochdalek diaphragmatic hernia is the most common (85-90%) and anterior Morgagni's hernia is the rarest presentation (2-5%) [2, 8]. CDH may be suspected at 10-11 weeks of gestation but usually is diagnosed around 20 weeks of gestation [9].

Early diagnosis is associated with poor outcome, since only severe cases can be recognised in the first trimester of the pregnancy. On the other hand, early recognition of the CDH may open a possibility of foetal interventions and/or allow planning perinatal management of a child [10, 11].

Foetal ultrasound assessment of the hypoplastic lung is rarely accurate; it rather describes the risk, not the size of a lung. The presence of part of the liver above the diaphragm is usually associated with severe pulmonary hypoplasia and postnatal pulmonary hypertension with survival rate less than 40%. [12]. It is worth to mention that the liver was found in the chest in the described case.

It is believed that prenatal lung-head ratio and liver position inconsistently predict outcome for CDH, LHR below 0.6 and/or the presence of the liver above the diaphragm are associated with high mortality rate [13, 14].

Clinical presentation after birth includes severe respiratory failure, need for ventilatory support and cardiovascular collapse. Surgery should to be performed only in stable patients and such approach decreases morbidity and mortality.



The following criteria for attempting the surgery should be observed [15]:

- stable circulatory function (possible moderate-dose inotropic support),
- 24 h without pulmonary hypertension crisis,
- oxygen index <30 or SaO<sub>2</sub> above 90 at FiO<sub>2</sub> <0.5,
- diuresis >1ml/kg/h.

Some of the patients who cannot be stabilised preoperatively may fulfil criteria for required extracorporeal membrane oxygenation (ECMO), which is rarely needed in cases where the liver is located below the diaphragm and prenatal LHR is >1.5 [15].

Although treatment of the CDH always requires multidisciplinary approach, adequate respiratory therapy which includes low volume positive pressure ventilation or high frequency oscillation and pulmonary vasodilatation, is key factor. In most cases because of different lung volume and compliance, HFO is optimal, because it allows to maintain constant oxygen flow and continuous distending pressure with ventilation with very small volumes below dead space; carbon dioxide is removed by continuous gas flow and vibrations of the chest. Severe hypoxia and pulmonary hypertension, confirmed by echocardiography, may require nitric oxide treatment [16]. Nitric oxide dilates pulmonary vessels selectively because it is bound by haemoglobin before it reaches systemic circulation [17]; therefore its use is not associated with marked systemic side effects. Randomized studies showed that early administration of nitric oxide (up to 48 hours after birth) for hypoxic respiratory failure in infancy improves oxygenation and decreases morbidity [18].

Surgical treatment of CDH is usually a one-stage procedure during which the viscera are moved back into peritoneal cavity, diaphragmatic defect is repaired and the abdomen is closed. Disproportion between the volume of the viscera, in most cases only the bowels (additionally distended due to prolonged mechanical ventilation), and the capacity of the peritoneal cavity may require their temporary placement in an external bag (for 4-5 days). The gradual reduction of a bag size allows for smooth adaptation of internal organs to new anatomical situation without causing abdominal compartment syndrome. Children with CDH who are in stable condition may be operated with use of an endoscope. The method is believed to be safe even in complicated cases. Its main advantages are accessibility, minimal trauma, good surgical effect and quick recovery [19, 20].

One of the most frequent post-surgical complications noted in children in subsequent months of life, resulting from diaphragm dysfunction, is gastro-oesophageal reflux (GER), which may lead to esophagitis. Gastro-oesophageal reflux is diagnosed in 47% of formed CDH cases among them appr. 8% may require surgical intervention [21].

Long-term sequels of CDH are respiratory tract pathologies, mostly bronchiolitis or pneumonia. Extreme pulmonary hypoplasia on the side of the hernia may lead to lung cirrhosis and its complete dysfunction. The GER was also found in the described case, but, fortunately, increased respiratory morbidity was not observed.

In conclusion, management of prenatally diagnosed congenital diaphragmatic hernia should be carried out in tertiary referral centres only, since they offer multidisciplinary, highly

specialised care of the newborn immediately after delivery. High frequency oscillation, nitric oxide, proper surgical strategy and adequate postoperative care decrease mortality and morbidity and improves prognosis of further somatic and psychomotor development of a child.

## References

1. Hedrick H. Management of prenatally diagnosed congenital diaphragmatic hernia. *Semin Fetal Neonatal Med.* 2010, 15, 21-27.
2. Lau S, Kim S, Ledbetter D, Healey P. Fraternal twins with Morgagni hernias. *J Pediatr Surg.* 2005, 40, 725-727.
3. Mohseni-Bod H, Bohn D. Pulmonary hypertension in congenital diaphragmatic hernia. *Semin Pediatr Surg.* 2007, 16, 126-133.
4. Peetsold M, Heijl H, Kneepkens C, [et al.]. The long-term follow-up of patients with congenital diaphragmatic hernia: a broad spectrum of morbidity. *Pediatr Surg Int.* 2009, 25, 1-17.
5. Kuluz M, Smith P, Mears S, [et al.]. Preliminary observations of the use of high-frequency jet ventilation as rescue therapy in infants with congenital diaphragmatic hernia. *J Pediatr Surg.* 2010, 45, 698-702.
6. Chukwu J, Iro C, Donoghue V, [et al.]. Congenital diaphragmatic hernia: neonatal outcomes following referral to paediatric surgical centre. *Ir Med J.* 2009, 102, 260-261.
7. Chao P, Huang C, Liu M, [et al.]. Congenital diaphragmatic hernia in the neonatal period: review of 21 years' experience. *Pediatr Neonatol.* 2010, 51, 97-102.
8. Fredly S, Aksnes G, Viddal K, [et al.]. The outcome in newborns with congenital diaphragmatic hernia in a Norwegian region. *Acta Paediatr.* 2009, 98, 107-111.
9. Conforti A, Losty P. Perinatal management of congenital diaphragmatic hernia. *Early Hum Dev.* 2006, 82, 283-287.
10. Deprest J, Nicolaidis K, Gratacos E. Fetal surgery for congenital diaphragmatic hernia is back from never gone. *Fetal Diagn Ther.* 2011, 29, 6-17.
11. Węgrzyn P, Weigl W, Szmysik I, [et al.]. Premature labor after fetal endoscopic tracheal occlusion for congenital diaphragmatic hernia: post-procedure management problems. *Ultrasound Obstet Gynecol.* 2010, 36, 124-125.
12. Albanese C, Lopoo J, Goldstein R, [et al.]. Fetal liver position and perinatal outcome for congenital diaphragmatic hernia. *Prenat Diagn.* 1998, 18, 1138-142.
13. Knox E, Lissauer D, Khan K, Kilby M. Prenatal detection of pulmonary hypoplasia in fetuses with congenital diaphragmatic hernia: a systematic review and meta-analysis of diagnostic studies. *J Matern Fetal Neonatal Med.* 2010, 23, 579-588.
14. Smith N, Jesudason E, Losty P. Congenital diaphragmatic hernia. *Paediatr Respir Rev.* 2002, 3, 339-348.
15. Reiss I, Schaible T, van den Hout L, [et al.]. Standardized postnatal management of infants with congenital diaphragmatic hernia in Europe: the CDH EURO Consortium consensus. *Neonatology.* 2010, 98, 354-364.
16. Waag K, Luff S, Zan K, [et al.]. Congenital diaphragmatic hernia: a modern day approach. *Semin Pediatr Surg.* 2008, 17, 244-254.
17. Porta N, Steinhorn R. Inhaled NO in the experimental setting. *Early Hum Dev.* 2008, 84, 717-723.
18. Gonzales A, Fabres J, D'Apemont I, [et al.]. Randomized controlled trial of early compared with delayed use of inhaled nitric oxide in newborns with a moderate respiratory failure and pulmonary hypertension. *J Perinatol.* 2010, 30, 420-424.
19. Liem N, Dung L. Thoracoscopic repair for congenital diaphragmatic hernia: lessons from 45 cases. *J Pediatr Surg.* 2006, 41, 1713-1715.
20. Said S, Moir C, Ishitani M, Zarroug A. Successful thoracoscopic staged repair of bilateral congenital diaphragmatic hernia. *J Pediatr Surg.* 2010, 45, 5-8.
21. Menendez C, Farinas M, Parente A, [et al.]. Long-term results of patients with congenital diaphragmatic hernia. *Cir Pediatr.* 2009, 22, 205-209.