

P R A C E K A Z U I S T Y N E  
*ginekologia*

# Polypectomy followed by adjuvant chemotherapy in a patient with sarcoma botryoides of the uterine cervix – case report and review of the literature

Polipektomia z uzupełniającą chemioterapią u chorej z mięsakiem groniastym szyjki macicy – opis przypadku i przegląd piśmiennictwa

Sobiczewski Piotr<sup>1</sup>, Dańska-Bidzińska Anna<sup>1</sup>, Miedzinska Magdalena<sup>1</sup>,  
Olszewski Wojciech<sup>2</sup>, Bidzinski Mariusz<sup>1</sup>

<sup>1</sup> Gynecologic Oncology Department, The Maria Skłodowska-Curie Memorial Cancer Center, Warsaw, Poland

<sup>2</sup> Pathology Department, The Maria Skłodowska-Curie Memorial Cancer Center, Warsaw, Poland

## Abstract

**Background:** Embryonal rhabdomyosarcoma in a form of a polyp of the uterine cervix occurs mainly in young women in their second decade of life. The characteristic microscopic features are: the submucosal cambium layer and the presence of rhabdomyoblasts in the stroma. So far the treatment has not been well defined and ranges from conservative to radical surgery.

**Case:** The presented case is a 22-year old woman with cervical polyp. Polypectomy with D&C was performed in 2005 and the microscopic examination revealed rhabdomyosarcoma botryoides. Detailed examination diagnosed stage Ia of the disease. The patient received 6 cycles of chemotherapy (Vincristine and Actinomycin).

**Conclusion:** Conservative treatment may be considered in young women with favorable prognostic factors who wish to preserve their fertility. Polypectomy followed by chemotherapy is a possible option for such patients.

Keywords: **rhabdomyosarcoma botryoides / cervical polyp /  
/ treatment / chemotherapy /**

## Corresponding author:

Piotr Sobiczewski, Gynecologic Oncology Department, The Maria Skłodowska-Curie Memorial Cancer Center, ul. Roentgena  
Poland, 02-781 Warsaw, Roentgena 5  
Phone +48 22 546 2578  
Fax +48 22 648 44 71  
e-mail: sobiczewskipiotr@acn.waw.pl  
sobiczewski@coi.waw.pl  
sobiczewskipiotr7@gmail.com

Otrzymano: 15.08.2011  
Zaakceptowano do druku: 20.10.2011

## Streszczenie

Mięsak groniasty może występować w postaci polipa szyjki macicy, głównie u młodych kobiet w drugiej dekadzie życia. Na charakterystyczny obraz mikroskopowy składają się zagęszczenia niezróżnicowanych komórek w warstwie podśluzówkowej i obecność rhabdomyoblastów w podścielisku. Leczenie chirurgiczne nie zostało jednoznacznie określone i mieści się w szerokim zakresie od chirurgii oszczędzającej do radykalnej.

**Opis przypadku:** Prezentowany przypadek dotyczy 22 letniej kobiety z polipem szyjki macicy. W 2005 roku wykonano usunięcie polipa oraz wyłyżeczkowanie kanału szyjki i jamy macicy a badanie mikroskopowe materiału wykazało mięsaka groniastego. Po dokładnej diagnostyce ustalono stopień zaawansowania nowotworu Ia. Pacjentka otrzymała 6 cykli chemioterapii wg schematu (VA)

**Wnioski:** U młodych kobiet pragnących zachować płodność, z korzystnymi czynnikami rokowniczymi można rozważyć leczenie oszczędzające. Jedną z możliwych opcji jest usunięcie polipa z uzupełniającą chemioterapią.

Słowa kluczowe: **mięsak groniasty / polip szyjki macicy / leczenie oszczędzające / chemioterapia /**

## Background

Rhabdomyosarcoma is a soft tissue tumor, localized in 20% in the genitourinary tract. In more than 50% of cases it occurs as embryonal subtype. Being a tumor of skeletal muscle, it is classified as heterologous sarcoma of the female genital tract [1]. The Intergroup Rhabdomyosarcoma Study (IRS) Group identified 3 major histologic subtypes of rhabdomyosarcoma: embryonal, alveolar and undifferentiated [2]. Sarcoma botryoides is a form of embryonal rhabdomyosarcoma with characteristic grape-like appearance.

Embryonal rhabdomyosarcoma arises from unsegmented and undifferentiated mesoderm. Microscopically, the tumor cells are small and spindle shaped. Some have a deeply acidophilic cytoplasm. A feature of diagnostic value is the presence of highly cellular areas, usually surrounding blood vessels, alternating with parvicellular regions that have abundant mucoid intercellular material. A highly characteristic feature of the polypoid (botryoid) tumors is the presence of a dense zone of undifferentiated tumor cells, directly beneath the epithelium, the formation known as Nicholson's cambium layer. Cross striations may or may not be present [3]. A prognostically favorable variant of embryonal rhabdomyosarcoma is represented by the spindle cell type.

In a female infant, in the genitourinary tract, vagina is the most common location. Cervical embryonal rhabdomyosarcoma is a rare entity and is seen in young women mainly in the second and the third decade of their life, macroscopically having an appearance of polypoid structures. Microscopically, both vaginal and cervical lesions share similar characteristic pathologic features: a submucosal cambium layer and the presence of rhabdomyoblasts in the stroma [1].

## Case report

A 22- year old woman, gravida 0, was referred to The Maria Skłodowska Curie Memorial Cancer Center, Department of Gynecological Oncology in October 2005. One month earlier the cervical polyp had been discovered during routine gynecological examination and polypectomy with fractional curettage (D&C) was performed.

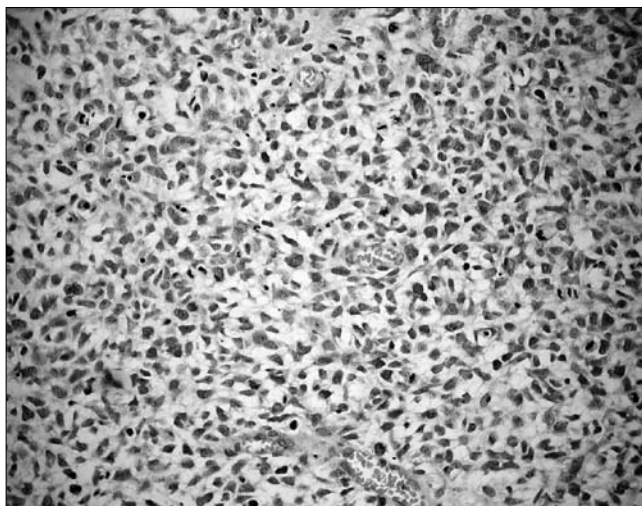


Figure 1. Small spindle cells with acidophilic cytoplasm (200x).

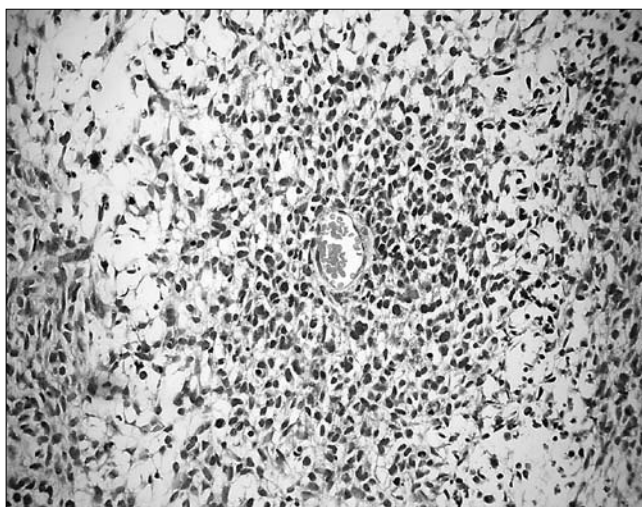


Figure 2. Characteristic feature of highly cellular area surrounding blood vessel (in the center of picture) alternating with parvicellular regions that have abundant mucoid intracellular material (left side of picture).

Polypectomy followed by adjuvant chemotherapy in a patient with sarcoma botryoides of the uterine cervix...

**Table I.** The review of patients treated by polypectomy.

Author	Patient age	Symptoms	IRS group	Surgery	Chemotherapy	Delayed therapy/therapy of relapse	Outcome
1. Hays et al. [9]	15	ns	I	polypectomy	VCN 2mg/kg <sup>2</sup> iv every week x12, ACD 0,015 mg/kg/d x5 repeat x4		A&W, 78 months
2. Hays et al. [9]	14	ns	I	polypectomy D&C	VCN 2mg/mg/m <sup>2</sup> iv every week x12, ACD 0,015 mg/kg/d x5 repeat x4	simple hysterectomy, oophorectomy, PND	A&W, 66 months
3. Hays et al. [9]	14	ns	I	polypectomy D&C	VCN 2mg/mg/m <sup>2</sup> iv every week x12, ACD 0,015 mg/kg/d x5 repeat x4		A&W, 66 months
4. Hays et al. [9]	14	ns	I	polypectomy D&C	pulse VAC for 24 months	hysterectomy	A&W, 33 months
5. Daya et al [6]	16	bleeding	ns	polypectomy	none		A&W, 60 months
6. Daya et al [6]	25	bleeding	ns	polypectomy	none		A&W, 60 months
7. Daya et al [6]	16	mass passed during menses	ns	polypectomy	none		A&W, 12 months
8. Daya et al [6]	15	bleeding	ns	polypectomy	none	VAC	A&W, 12 months
9. Daya et al [6]	16	recurrent endocervical polyp	ns	polypectomy	none	TAH, VAC	DOD, 21 months after TAH
10. Zanetta et al [8]	22	bleeding	Ia	polypectomy	Doxorubicine 25mg/m <sup>2</sup> /d, days 1,2,3; Ifosfamide 2gm <sup>2</sup> /d, days 1,2,3. every 3 weeks for 3 courses	Loop excision, local recidive	A&W, 38 months
11. Zanetta et al. [8]	25	bleeding	ns	polypectomy	Doxorubicine 25mg/m <sup>2</sup> /d, days 1,2,3; Ifosfamide 2gm <sup>2</sup> /d, days 1,2,3. every 3 weeks for 4 courses		A&W, 36 months
12. Zanetta et al. [8]	20	Bleeding	ns	polypectomy	Doxorubicine 25mg/m <sup>2</sup> /d, days 1,2,3; Ifosfamide 2gm <sup>2</sup> /d, days 1,2,3. every 3 weeks for 3 courses		A&W, 38 months
13. Current study	22	ns	Ia	Polypectomy D&C	Vincristine 1,5mg/m <sup>2</sup> , 1day, Actinomycin 0,015mg/kg 1-5 days for 6 cycles		A&W, 71 months

VAC – VCN+ACD+CPM, VCN – Vincristine, ACD – Dactinomycin, CPM – Cyclophosphamide, D&C – dilatation and curettage, A&W – alive and well

The microscopic examination revealed rhabdomyosarcoma botryoides. Immunohistochemical analysis were as follows: desmin (+/-), actin (-), MIB-1 (+++), vimentin (+), cytokeratin (-).

Microscopically, picture composed of small spindle cells with acidophilic cytoplasm was present with a characteristic feature of highly cellular area surrounding a blood vessel alternating with parvicellular regions that have abundant mucoid intracellular material. (Figure 1 and Figure 2).

The patient underwent a thorough clinical examination, chest X-ray, abdominal and transvaginal ultrasound and pelvic MRI. The results showed no evidence of metastatic or residual disease.

Diagnostic hysteroscopy was performed on the 10th day of the cycle and showed normal cervical canal and uterine cavity. According to the Intergroup Rhabdomyosarcoma Study (IRS) criteria, it was classified as group IA (4).

The patient was subsequently scheduled for adjuvant chemotherapy with Vincristine, 1,5mg/m<sup>2</sup> the first day, at a maximum dose of 2mg and Dactinomycin at a dose of 0,015mg/kg from the first until the fifth day, at a maximum dose of 0,5mg/day. Chemotherapy was given in 4-week intervals for 6 cycles with good tolerance without any significant toxicity. The menstrual periods were painful, but regular. The gynecological examination and transvaginal ultrasound were performed after the 3rd and the 6th cycle of chemotherapy. The treatment was completed without delays in April 2006.

**Table II.** The possible modifications of chemotherapy regimens.

Author	Regimen	Vincristine	Actinomycin D	Cyclophosphamide
Crist W et al. <i>J Clin Oncol</i> , 1995 [19]	VA	1,5mg/m <sup>2</sup> (max 2 mg) d.1	0,015mg/kg d.1-5	–
Bernal et al. <i>Gynecol Oncol</i> , 2004 [7]	VA	1,5mg/m <sup>2</sup> (max 2mg) d.1	0,015mg/kg (max 0,5mg/d) d.1-5	–
Gordon AN et al. <i>Gynecol Oncol</i> , 1990 [12]	VAC	2mg d.1	0,5mg/m <sup>2</sup> d.1-5	8mg/kg d.1-5
Lin J et al. <i>Gynecol Oncol</i> , 1995 [11]	VAC	2mg d.1	0,5mg/m <sup>2</sup> d.1	500mg/m <sup>2</sup> d.1
Zeisler H et al. <i>Gynecol Oncol</i> , 1998 [13]	VAC	1,5mg/m <sup>2</sup> d.1	0,3mg/m <sup>2</sup> d.1-5	150mg/m <sup>2</sup> d.1-5
Spunt SL et al. <i>Clin Cancer Res</i> , 2004 [16]	VAC	1,5mg/m <sup>2</sup> d.1,8,15	1,35mg/m <sup>2</sup> d.1	1,2-2,2g/m <sup>2</sup> d.1,2,3

d – day

In June 2006, the transvaginal ultrasound showed normal uterus and ovaries without any abnormalities. Hysteroscopy showed normal uterine cavity and cervical canal without any pathologic findings, endometrial and endocervical random biopsies were negative. The patient became pregnant and delivered on February 15, 2009. The patient remains without evidence of disease 71 months following the initial diagnosis of botryoid sarcoma.

## Discussion

Sarcoma botryoides in a form of a polyp of the uterine cervix is a rare entity and may occur in young women and adolescents.

In 1987 Brand et al., reported 4 cases of sarcoma botryoides of the uterine cervix and presented the review of literature with other 17 cases, which resulted in the total number of 21 cases reported until 1987 [5]. In that review, treatment ranged from polypectomy (2 patients) to radical surgery and exenteration with additional radio- and/or chemotherapy. One of the two patients after polypectomy survived 16 months without any additional treatment [5].

Radical surgery was traditionally the method of choice in the treatment of sarcoma botryoides. In the 1970s the standard management consisted of pelvic exenteration which enabled the recovery of about 50% of patients. By mid 1970s it was documented that pelvic exenteration may be abandoned and replaced by a less mutilating surgery and combined with chemotherapy.

Moreover, the majority of the patients with cervical lesions are young and therefore the possibility of fertility sparing treatment should be considered.

In 1988 Daya and Scully reported 13 cases of sarcoma botryoides in cervical polyps, thus comprising the largest series to date of original cases [6]. Five patients were treated with conservative surgery: 1 with cervicectomy, 3 patients with polypectomy and 1 with polypectomy and chemotherapy. All survived from 1 to 8 years and that study proved the prognosis was similar in cases treated conservatively and in a more radical manner.

Polypoid form of rhabdomyosarcoma has been suggested to have a more favorable prognosis. However, the potential invasiveness should be kept in mind as 1 patient in Daya and Scully series presented recurrent polyps and eventually died of the disease despite radical surgery and subsequent chemotherapy [6].

The case report published by Bernal et al., concerned a 19-year-old patient with a cervical polyp [7]. Endocervical curettage and evacuation of the polyp were performed and cervical conization was also decided due to the pathologic evaluation revealing embryonal rhabdomyosarcoma in both samples. Even though no residual tumor was present in cervical specimen, she was scheduled for chemotherapy and received 6 cycles of Vincristine and Dactinomycin [7].

Zanetta et al., reported 3 cases of rhabdomyosarcoma in cervical polyps in young women treated conservatively with polypectomy and local excision, followed by chemotherapy (Doxorubicin, Ifosfamide). In all three cases the follow up was up to 36 months. Local recurrence occurred in 1 patient after 9 months and was treated by loop excision. The two remaining patients were free of disease [8].

The appropriate therapy for sarcoma botryoides arising in the cervix has not been well-defined as it is a rare tumor and data are based on individual case reports. The majority of the patients are young, in their second decade of life, and in an attempt to maximize the reproductive potential a conservative surgery with preservation of fertility should be considered.

Since the report published in 1987 by Brand and al., the review of the literature has shown very limited number of cases with location in polyps treated conservatively with or without additional chemotherapy [9,10,11,12,13]. The cases of polypectomy, including current study, are presented in table I.

Among 13 patients, local recurrence occurred in 1 patient despite chemotherapy, 1 patient died (not treated with chemotherapy). The remaining 11 patients survived without recurrence, regardless of receiving or not chemotherapy.

Sarcoma botryoides is a highly malignant subgroup of rhabdomyosarcoma (RMS), but fortunately in most cases it is responsive to chemotherapy and radiation. Due to its rarity,

the best choice of adjuvant treatment, especially at the early stages of the disease, is still a matter of controversy and requires further investigation. Nowadays surgery followed by an adjuvant multidrug chemotherapy is the most frequent therapeutic option [14]. Radiation is actually indicated in patients with persistent or recurrent disease [15]. The employment of effective antineoplastic agents in adjuvant settings encourages a more conservative surgical approach. Because sarcoma botryoides of the cervix usually occurs as a localized disease it is possible not only to cure but also to preserve the fertility of patients [11, 12, 14]. Undoubtedly, multiagent treatment consisting of Vincristine, Dactinomycin and Cyclophosphamide (VAC) is the most popular adjuvant chemotherapy regimen in adolescents and young adult patients with cervical sarcoma botryoides. The recommended regimens and dosage may vary and are shown in table II.

The number of given cycles ranges from three to twelve [10, 13, 16]. Totally excised tumors of embryonal histology localized in the female genital tract have an excellent prognosis when treated with adjuvant multiagent chemotherapy, much superior than other subgroups of rhabdomyosarcomas [17]. Therefore, in patients with group I embryonal RMS, the "low-risk" patients, less aggressive schedule is usually chosen with fairly satisfactory results. It consists of Vincristine and Dactinomycin (VA) [7, 18, 19]. The aim of this regimen is to avoid disturbances in the endocrine system of young patients as much as possible. Cyclophosphamide is one of the cytostatics which inhibit hormonal ovarian function more frequently.

Ifosfamide belongs to the most active drugs in sarcomas. There are only few published cases of treating young women with sarcoma botryoides with chemotherapy based on Ifosfamide and Doxorubicin [8]. Regimens containing more cytostatics, as Ifosfamide, Dactinomycin and Vincristine (IVA), sometimes sequentially with Doxorubicin and Cisplatin or multidrug chemotherapy VAIA (Ifosfamide, Dactinomycin, Doxorubicin and Vincristine), widely used in "high-risk" children patients, have no role in the treatment of older patients [20, 21, 22, 23, 24].

As a result of the IRS study group, VA has been concluded to appear as effective as VAC in the group I disease and possibly to spare the adolescents complete alopecia and reduce toxicity [2]. Between 6 and 12 cycles are recommended in the literature.

#### Conclusion

Surgical procedures, even at early stages of the disease, range from polypectomy, cervicectomy (trachelectomy) up to radical hysterectomy. In young women wishing to preserve their fertility, the conservative treatment – polypectomy – may be considered as the results are similar to those of a more radical surgery.

Moreover, it seems that the extent of the disease is the most important prognostic factor.

Consequently, patients with favorable prognostic factors (disease classified as clinical group I with localized lesion, without a deep myometrial invasion, in the form of a single polyp and with embryonal histology), may be treated successfully with conservative surgery.

In fact, there is no evidence that chemotherapy is necessary at an early stage Ia of sarcoma botryoides after surgical excision. However, the prognosis which had been very bad before introduction of chemotherapy, has now improved so it may be an argument in favor of the adjuvant treatment.

The thorough evaluation of the extend of the disease should be performed, using imaging techniques (ultrasonography/MRI) and hysteroscopy with biopsy of the suspicious area.

The close follow-up is highly recommended as the risk of relapse is not negligible, and early detection is crucial for subsequent effective therapy.

#### References

1. Ioffe B O, Simsir A, Silverberg SG. Pathology. In: Practical Gynecologic Oncology. Eds. Berek J, Hacker N. 4th ed. Lippincott: *Williams & Wilkins*. 2005. 175-176.
2. Maurer H, Gehan E, Beltangady M, et al. The Intergroup Rhabdomyosarcoma Study-II. *Cancer*. 1993, 71, 1904-1922.
3. Crum C, Nuovo G. Cervix. In: Diagnostic Surgical Pathology, Ed. Sternberg S. New York: *Raven Press*. 1989, 1585-1586.
4. Hays D, Shimada H, Raney R, [et al.]. Sarcomas of the vagina and uterus: The Intergroup Rhabdomyosarcoma Study. *J Pediatr Surg*. 1985, 20, 718-724.
5. Brand E, Berek J, Nieberg R, Hacker N. Rhabdomyosarcoma of the uterine cervix, sarcoma botryoides. *Cancer*. 1987, 60, 1552-1560.
6. Daya D, Scully R. Sarcoma botryoides of the uterine cervix in young women: a clinicopathological study of 13 cases. *Gynecol Oncol*. 1988, 29, 290-304.
7. Bernal K, Fahmy L, Remmenga S, [et al.]. Embryonal rhabdomyosarcoma (sarcoma botryoides) of the cervix presenting as a cervical polyp treated with fertility – sparing surgery and adjuvant chemotherapy. *Gynecol Oncol*. 2004, 95, 243-246.
8. Zanetta I, Rota S, Lissoni A, [et al.]. Conservative treatment followed by chemotherapy with doxorubicin and ifosfamid for cervical sarcoma botryoides in young females. *Br J Cancer*. 1999, 80, 403-406.
9. Hays D, Shimada H, Raney R. Clinical staging and treatment results in rhabdomyosarcoma of the female genital tract among children and adolescents. *Cancer*. 1988, 61, 1893-1903.
10. Behtash N, Mousavi A, Tehrani A, [et al.]. Embryonal rhabdomyosarcoma of the uterine cervix : case report and review of the literature. *Gynecol Oncol*. 2003, 91, 452-455.
11. Lin J, Lam S, Cheung T. Sarcoma botryoides of the cervix treated with limited surgery and chemotherapy to preserve fertility. *Gynecol Oncol*. 1995, 58, 270-273.
12. Gordon A, Montag T. Sarcoma botryoides of the cervix: excision followed by adjuvant chemotherapy for preservation of reproductive function. *Gynecol Oncol*. 1990, 36, 119-124.
13. Zeisler H, Mayerhofer K, Joura E, [et al.]. Embryonal rhabdomyosarcoma of the uterine cervix: case report and review of the literature. *Gynecol Oncol*. 1998, 69, 78-83.
14. Arndt C, Donaldson S, Anderson J, [et al.]. What constitutes optimal therapy for patients with rhabdomyosarcoma of the female genital tract? *Cancer*. 2001, 12, 2454-2468.
15. Martelli H, Oberlin O, Rey A, [et al.]. Conservative treatment for girls with nonmetastatic rhabdomyosarcoma of the genital tract: A report from the Study Committee of the International Society of Pediatric Oncology. *J Clin Oncol*. 1999, 17, 2117-2122.
16. Spunt S, Smith L, Ruymann F, [et al.]. Cyclophosphamide Dose Intensification During Induction Therapy for Intermediate-Risk Pediatric Rhabdomyosarcoma Is Feasible but Does Not Improve Outcome: A Report from the Soft Tissue Sarcoma Committee of The Children's Oncology Group. *Clin Cancer Res*. 2004, 10, 6072-6079.
17. Mc Dowell H. Update on childhood rhabdomyosarcoma. *Arch Dis Child*. 2003, 88, 354-357.
18. Crist W, Anderson J, Meza J, [et al.]. Intergroup rhabdomyosarcoma study –IV: results for patients with nonmetastatic disease. *J Clin Oncol*. 2001, 19, 3091-3102.
19. Crist W, Gehan E, Ragab A, [et al.]. The Third Intergroup Rhabdomyosarcoma Study. *J Clin Oncol*. 1995, 13, 610-630.
20. Wolden S, Anderson J, Crist W, [et al.]. Indications for radiotherapy and chemotherapy after complete resection in rhabdomyosarcoma: A report from the Intergroup Rhabdomyosarcoma Studies I to III. *J Clin Oncol*. 1999, 17, 3468-3475.
21. Koscielnak E, Harms D, Henze G, [et al.]. Results of treatment for soft tissue sarcoma in childhood and adolescence: a final report of the German Cooperative Soft Tissue study CWS 86. *J Clin Oncol*. 1999, 17, 3706-3719.
22. Flamant F, Rodary C, Rey A, [et al.]. Treatment of non-metastatic rhabdomyosarcoma in childhood and adolescence. Results of the second study of the International Society of Paediatric Oncology: MMT84. *Eur J Cancer*. 1998, 34, 1050-1062.
23. Scaravilli G, Simeone S, Dell'Aversana Orabona G, [et al.]. Case report of a sarcoma botryoides of the uterine cervix in fertile age and literature review. *Arch Gynecol Obstet*. 2009, 280, 863-866.
24. Wierzchowska-Chmaj K, Wierzchowski M, Szymanowski K, [et al.]. Pleomorphic rhabdomyosarcoma of the uterine corpus-a case report. *Ginekol Pol*. 2010, 81, 541-543.