

Feasibility of using high-frequency skin ultrasound (HFSU) in vulvar skin assessment – initial report with the description of HFSU anatomy

Zastosowanie ultrasonografii wysokiej częstotliwości (HFSU) w obrazowaniu skóry sromu – doniesienie wstępne z opisem anatomii HFSU

Marian Stanisław Migda¹, Michał Migda², Bartosz Migda³, Rafał Zenon Słapa³, Robert Krzysztof Młosek³

¹ Civis Vita Centrum Medyczne, Toruń, Polska

² Oddział Kliniczny Położnictwa, Chorób Kobięcych i Ginekologii Onkologicznej, Wojewódzki Szpital Zespolony w Toruniu, Uniwersytet Mikołaja Kopernika w Toruniu, Polska

³ Zakład Diagnostyki Obrazowej, II Wydział Lekarski Warszawski Uniwersytet Medyczny, Warszawa, Polska

Abstract

Objectives: High-frequency skin ultrasound (HFSU) allows for an extremely detailed assessment of the skin layers (epidermis, dermis, and hypodermis), as well as skin appendages (hair follicles, glands, and vessels). The aim of the study was to evaluate vulvar structures using HFSU and its utility as a diagnostic tool.

Material and methods: The study group consisted of 50 women (22 pre- and 28 post-menopausal), aged 18-81 years, without clinical symptoms of vulvar pathology. The following regions were assessed: mons pubis, labia majora, labia minora, external urethra orifice, and posterior commissure. Statistical analysis of epidermis and dermis for mons pubis, labia majora and minora was performed.

Results: Comparison of the epidermis (EP) and dermis (DER) of mons pubis (MP), labia majora (VLM), labia minora (VLM) between the pre- and postmenopausal groups showed no statistically significant differences. Further comparison of EP and DER deemed the following results: for the premenopausal group - EP MP vs. EP VLM ($p=0.0884$) and DER MP vs. DER VLM ($p=0.8874$), for the postmenopausal group - EP MP vs. EP VLM ($p=0.5755$) and DER MP vs. DER VLM ($p=0.3606$), and without grouping - EP MP vs. EP VLM ($p=0.0988$) and DER MP vs. DER VLM ($p=0.5092$), and showed no statistical differences. As for rest of the measured parameters, the p -value was <0.05 .

Conclusions: HFSU allows for precise imaging and measurement of vulvar epidermis and dermis.

Key words: **ultrasonography / vulva / high-frequency ultrasound /**

Autor do korespondencji:

Michał Migda
Civis Vita Centrum Medyczne
ul. Warszawska 20, 87-100 Toruń, Polska
tel. 607398446
e-mail: mchmigda@gmail.com

Otrzymano: 13.10.2015
Zaakceptowano do druku: 11.11.2015

Marian Stanisław Migda et al. Feasibility of using high-frequency skin ultrasound (HFSU) in vulvar skin assessment – initial report with the description of HFSU anatomy.

Streszczenie

Cel: Ultrasonografia wysokiej częstotliwości (high frequency skin ultrasound - HFSU) pozwala na szczegółową ocenę poszczególnych warstw skóry: naskórka, skóry właściwej, tkanki podskórnej, oraz przydatków skóry: mieszków włosowe, gruczoły i naczynia krwionośne. Celem pracy była ocena struktur sromu przy pomocy HFSU i jej zastosowanie jako narzędzia diagnostycznego.

Metoda: Grupę badaną stanowiło 50 kobiet w wieku 18-81 lat, 22 kobiety przed- i 28 po menopauzie, bez widocznych klinicznie zmian patologicznych w obrębie skóry sromu. Oceniono wznórek tonowy, wargi sromowe większe, wargi sromowe mniejsze, łechtaczkę, okolice ujścia cewki moczowej oraz okolice spoidła tylnego. Analizie statystycznej poddano grubość naskórka i skóry właściwej warg sromowych większych, warg sromowych mniejszych oraz wznórek tonowego.

Wyniki: Porównanie grubości naskórka (EP) i skóry właściwej (DER) wznórką tonowego (MP), warg sromowych większych (VLM), warg sromowych mniejszych (VLm) w grupach kobiet przed- i po menopauzie nie wykazało istotnych statystycznie różnic. Porównanie grubości naskórka i skóry właściwej w grupie kobiet przed menopauzą, w grupie kobiet po menopauzie, oraz bez grupowania jedynie w przypadku porównań, odpowiednio dla kobiet przed menopauzą EP MP vs EP VLM ($p=0,0884$) i DER MP vs DER VLm ($p=0,8874$), kobiet po menopauzie EP MP vs EP VLM ($p=0,5755$) i DER MP vs DER VLm ($p=0,3606$), oraz bez grupowania EP MP vs EP VLM ($p=0,0988$) i DER MP vs DER VLm ($p=0,5092$) nie uzyskano istotnych różnic, w pozostałych przypadkach dla obu grup $p<0,05$.

Wnioski: HFSU pozwala na szczegółowe obrazowanie i pomiary grubości naskórka i skóry właściwej sromu.

Słowa kluczowe: **ultrasonografia / srom / ultrasonografia wysokich częstotliwości /**

Introduction

High-frequency skin ultrasound (HFSU) is an example of technological advances which are being increasingly used in diagnosing certain dermatological pathologies. The number of publications on its importance in esthetic medicine and cosmetology is steadily growing [1-6]. Ultrasound has been used in dermatology for over 30 years [7]. Alexander et al., were the first to apply this technique to non-invasive skin measurements in 1979 [8]. The following years gave rise to new areas of HFSU application, especially the diagnostic process of skin lesions and tumors [8-12]. In daily clinical practice, about 5% of all new gynecological consultations relate to vulvar pathology [13]. Nowadays, vulvar diagnosis is based on macroscopic evaluation, physical examination, vulvoscopy, microbiological specimen collection, and biopsy [14-15]. The treatment of vulvar pathologies is mostly based on a certain percent of subjectivism and personal experience. Ultrasound is not frequently used for general diagnostics, especially in the vulvar region, and transducers of 7,5MHz do not deliver sufficient images for vulvar skin assessment. Those images have low resolution and fail to visualize structures of <1mm [16].

Kleinermann et al., published a report on the correlation between ultrasound frequency and possible tissue penetration [7]. To the best of our knowledge, recent publications offer no data on HFSU utility in vulvar skin imaging using transducers of 20-100MHz [1, 17].

The aim of the study was to present the possibilities of imaging vulvar skin layers and skin appendages using HFSU.

Material and methods

The study sample included 50 women, aged 18-81 years, without clinical pathologies of the vulvar skin. The subjects were subdivided into the premenopausal (group 1, 22 women) and the postmenopausal (group 2, 28 women) groups, with mean ages of 35.7 years (18-64 years), and 59.1 years (47-81 years), respectively. One day before the examination all patients were instructed to remove their vulva hair by shaving. The examination was performed in gynecological position. EPISCAN (Longport International, UK) with 50MHz mechanical probe (focal length 7,75mm, stand-off 6mm) was used for the ultrasound. The same fixed settings of the ultrasound device parameters were used for all measurements: time-gain compensation 22%, position (Pos)

Table 1. Epidermal and dermal thickness measurement in pre- and post-menopausal women.

Variable	Before menopause				After menopause				p
	Mean	Min	Max	SD	Mean	Min	Max	SD	
Age	35.7	18.0	64.0	11.457	59.1	47.0	81.0	7.860	0.0000 ^b
EP VLM	0.21	0.04	3.40	0.47	0.15	0.03	4.09	0.29	0.8518 ^b
DER VLM	2.21	1.09	4.32	0.48	2.20	0.97	3.46	0.61	0.8769 ^a
EP VLm	0.08	0.06	0.32	0.03	0.08	0.06	0.16	0.02	0.3135 ^b
DER VLm	1.93	1.11	5.49	0.47	1.93	0.94	3.45	0.47	0.8735 ^b
EP MP	0.12	0.06	0.20	0.03	0.13	0.06	0.25	0.04	0.7515 ^b
DER MP	1.82	0.57	2.84	0.42	1.78	1.23	2.47	0.33	0.7170 ^b

Legend: ^a - t-Student test; ^b - U Mann-Whitney test; EP – epidermis, DER – dermis; VLM – labia majora; VLm – labia minora; MP – mons pubis

Marian Stanisław Migda et al. *Feasibility of using high-frequency skin ultrasound (HFSU) in vulvar skin assessment – initial report with the description of HFSU anatomy.***Table II.** Comparison of the thickness of the examined vulva structures in pre- and post-menopausal women.

Wilcoxon Test		AFTER MENOPAUSE					
P		EP VLM	DER VLM	EP VLm	DER VLm	EP MP	DER MP
Z							
BEFORE MENOPAUSE	EP VLM		0.0000	0.0000	0.0000	0.5755	0.0003
			6.04	5.16	5.99	0.56	3.66
	DER VLM	0.0000		0.0000	0.0161	0.0000	0.0097
		6.04		6.09	2.41	4.29	2.59
	EP VLm	0.0000	0.0000		0.0000	0.0000	0.0000
		10.53	11.98		6.09	4.20	4.29
	DER VLm	0.0000	0.0000	0.0000		0.0000	0.3606
		11.74	6.37	11.98		4.29	0.91
	EP MP	0.0884	0.0000	0.0000	0.0000		0.0000
		0.09	6.39	6.00	6.39		4.29
	DER MP	0.0000	0.0000	0.0000	0.8874	0.0000	
		6.39	4.74	6.39	0.14	5.99	

Legend: p, Z – p and Z values for Wilcoxon test; EP – epidermis, DER – dermis; VLM – labia majora; VLm – labia minora; MP – mons pubis

Table III. Comparison of the thickness of the examined vulvar structures without grouping.

Wilcoxon test	EP VLM	DER VLM	EP VLm	DER VLm	EP MP	DER MP
p						
Z						
EP VLM		0.0000	0.0000	0.0000	0.0998	0.0000
		13.21	11.71	13.16	1.65	11.71
DER VLM			0.0000	0.0000	0.0000	0.0000
			13.43	6.78	7.67	5.24
EP VLm				0.0000	0.0000	0.0000
				13.43	7.62	7.62
DER VLm					0.0000	0.5092
					7.67	0.66
EP MP						0.0000
						7.67
DER MP						

Legend: p, Z – p and Z values for Wilcoxon test; EP – epidermis, DER – dermis; VLM – labia majora; VLm – labia minora; MP – mons pubis

6,6mm, depth-4,0mm, and gain 47%. All scans were archived on a hard drive and analyzed by three independent researchers. While the examination was being performed, the transducer was perpendicular to the skin. The following structures were subject to an ultrasound evaluation based on the research protocol: labia majora (VLM), labia minora (VLm), mons pubis (MP), and

clitoris. Three scans were taken in all of these regions, the best one was evaluated by three independent blinded researchers. Secondly, 3 epidermis and dermis measurements were taken in every region and mean values were calculated. All patients signed an informed consent before the examination. Local Ethics Committee approved of the study (no. KB/220/2012).

Marian Stanisław Migda et al. Feasibility of using high-frequency skin ultrasound (HFSU) in vulvar skin assessment – initial report with the description of HFSU anatomy.

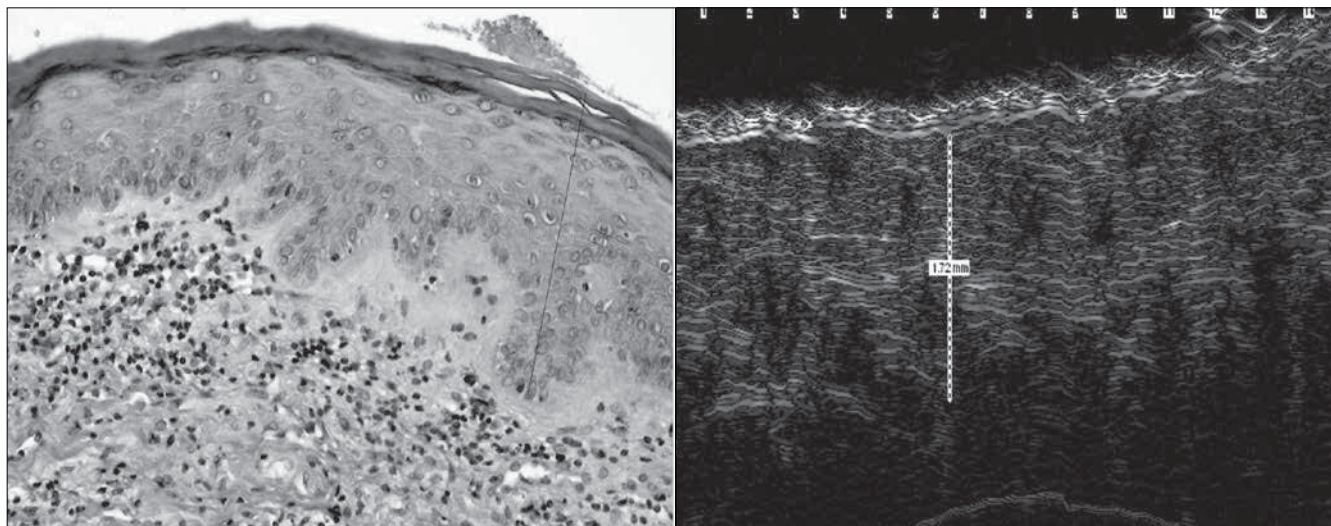


Figure 1 and 2. Comparison of histological and HFSU image of mons pubis skin measurements.

Statistical Analysis

Statistical analysis was performed using Statistica 10 (Statsoft Inc.). Distribution of the variables was assessed with the Shapiro-Wilk test. Comparison of unpaired quantitative variables was performed with Student t-test or U Mann-Whitney test, depending on their distribution. The assessment of paired variables was performed using Wilcoxon test. The p-value of >0.05 was considered as statistically significant.

Results

Data analysis was performed for each parameter which was included in the research protocol: epidermis (EP) and dermis (DER) thickness measurement in three regions (VLM – labia majora, VLM – labia minora, MP – mons pubis).

Mean VLM thickness of EP and DER in both groups of women before and after the menopause was 0.21mm, 2.21mm and 0.15mm, 2.20mm, respectively. Mean VLM thickness of EP and DER was equal in both groups and achieved 0.08mm and 1.93mm, respectively. Mean MP thickness of EP and DER in the examined groups was 0.12mm, 1.82mm and 0.13mm, 1.78mm, respectively. All of the above mentioned results were statistically insignificant. The p-value in all cases was >0.05 (Table I).

Tables II and III show the comparison of EP and DER thicknesses measured in different vulvar regions (MP, VLM, VLM), including the division into pre- and post-menopausal groups (Table II), and without grouping (Table III).

The obtained results, with the exception of two comparisons, i.e. the thickness differences of EP and DER, in all of the examined vulvar regions were statistically significant ($p < 0.05$) (Tables II and III).

Furthermore, the comparison of epidermal thickness of MP and VLM (EP MP – EP VLM), and dermal thickness of MP and VLM (DER MP – DER VLM) in both these groups (1 and 2), and women without grouping, revealed a lack of statistical significance ($p > 0.05$) (Tables II and III).

Ultrasound images of the vulvar structures were obtained by high frequency scanner (Episcan) with a mechanical probe 50MHz (Figures 1-9).

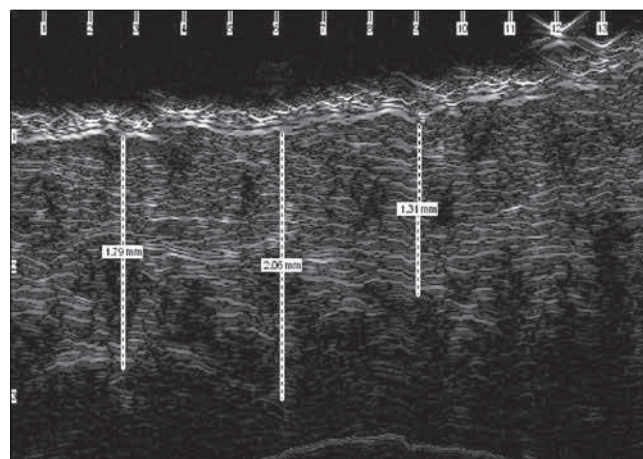


Figure 3. Dermis measurements of mons pubis using HFSU.

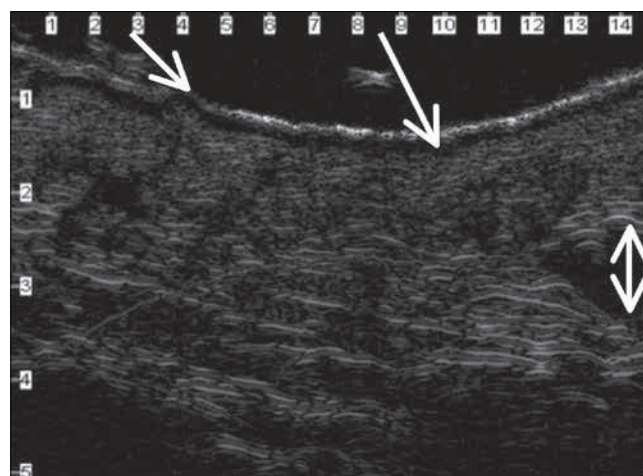


Figure 4. VLM in HFSU: hyperechoic EP(short arrow), subepidermal edema (long arrow), blood vessel (short double arrow).

Marian Stanisław Migda et al. Feasibility of using high-frequency skin ultrasound (HFSU) in vulvar skin assessment – initial report with the description of HFSU anatomy.

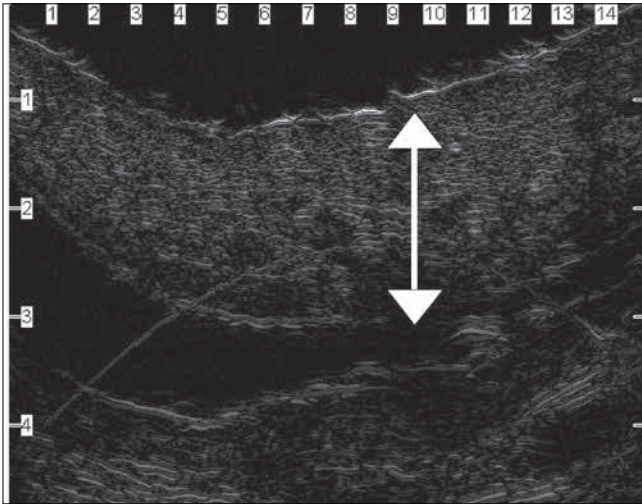


Figure 5. VLM in HFSU transvers view: hyperechogenic EP surrounding VLM fold (double arrow).

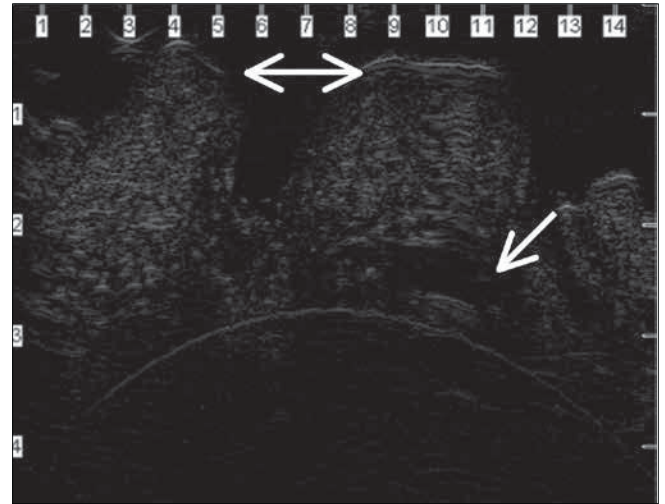


Figure 8. Multipara urethra orifice in HFSU: transverse view (double arrow), Skene's gland, (arrow).

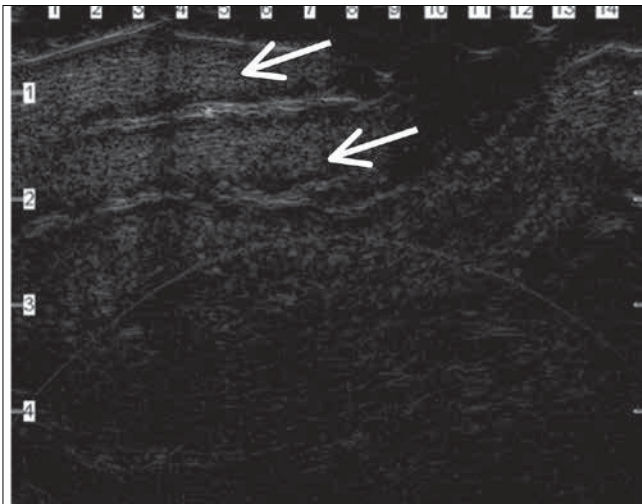


Figure 6. Clitoris in HFSU longitudinal view: two corpora cavernosa (arrows).

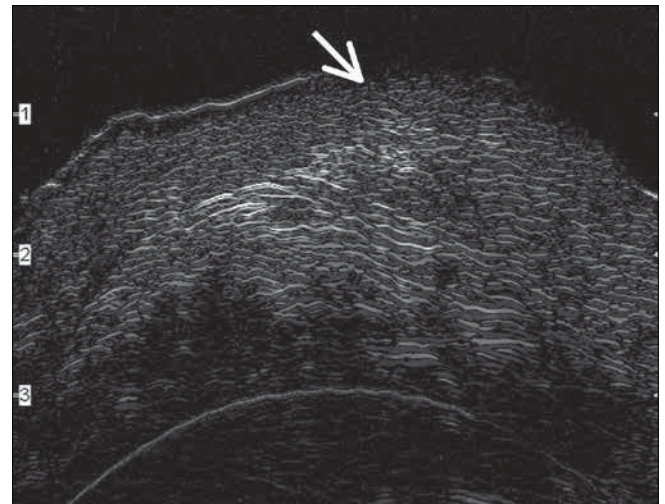


Figure 9. Hart's line in HFSU: connections between mucosa and stratified squamous epithelium non-keratinized (arrow).

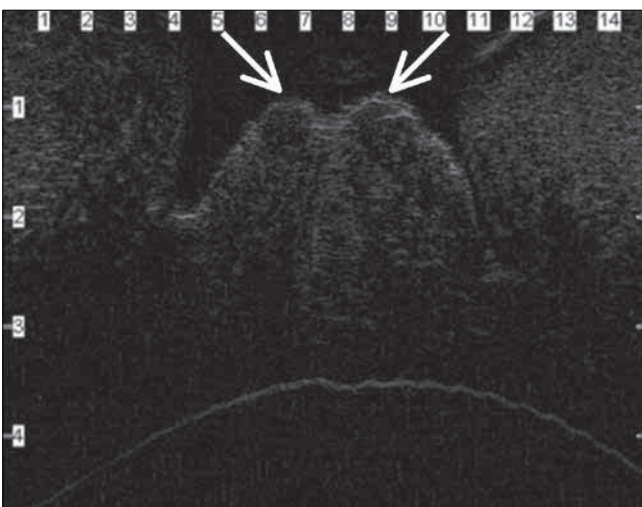


Figure 7. Nullipara urethra orifice in HFSU; transverse view (double arrow), VLM folds on both sides of urethra (arrows).

Discussion

HFSU improves clinical assessment in terms of detection, evaluation, and management of skin pathologies which are both, clinical or subclinical [18]. From the dermatological point of view, HFSU supplies important information regarding size, margins, echogenicity, homogeneity, posterior shadowing and infiltration depth. In case of skin pathologies, HFSU with color Doppler is considered a useful, safe, non-invasive, low-cost and repeatable procedure, which can reduce the number of invasive procedures such as biopsy [19].

Normal skin is a three-layer structure made of epidermis (0.06-0.6mm), dermis (1-4mm), built of connective tissue, nerves, blood vessels, skin appendages, and subcutaneous tissue (5-20mm), composed mostly of fat [14]p. According to Kleineremann, 50 MHz probes may visualize only the epidermis [7]. Based on the research of Mlosek et al., as well as our own findings, we confirm that 50 MHz mechanical probes produce images of both, epidermis and dermis [20].

Marian Stanisław Migda et al. Feasibility of using high-frequency skin ultrasound (HFSU) in vulvar skin assessment – initial report with the description of HFSU anatomy.

In the study group, we managed to visualize this layered skin structure, distinguishing most externally the highly hyperechogenic epidermis (top of the screen), followed by the dermis of more heterogenic structure, and hypoechogenic subcutaneous tissue at the bottom. All figures correlate strongly with microscopic skin specimens (Figures 1-3). All measurements of the vulvar region epidermis and dermis were within the normal ranges for all of the measured structures.

The most external layer visible on high frequency scans is entry echo, firstly observed by Altmeyer, which is created by reflections formed by the ultrasound gel and the surface of the epidermis. Just beneath the epidermis lies the dermis, which is a heterogenic layer with hypoechoic reflections of the collagen fibers and hypoechoic ones from the extracellular matrix between the fibers [21]. At the bottom of the scan is hypoechoic subcutaneous tissue, with thin linear hyperechoic reflexes [20].

In the study group, data analysis of EP thickness for MP, VLM, VLm in both groups showed no significant differences in mean values. However, a 40% thicker EP was observed in the premenopausal group as compared to the postmenopausal subjects. Unfortunately, a relatively small sample size did not allow for a definitive conclusion. Regardless, this observation has certain clinical implications, based on mean premenopausal age of 35 and postmenopausal age of 59 years. The possible cause of that difference might be the hormonal status, especially estrogens, progesterone, and androgens, whose levels change with age, and may lead to epidermal thinning [16, 22-23].

Additional analysis of the epidermal thickness of mons pubis and labia majora within the pre- and postmenopausal groups showed no differences. Epidermis is a very thin structure and precise measurement must be performed with great care. Mlosek et al., suggested to perform more measurements of that structure and use mean value to decrease the error (Figure 3) [16].

The next factor which can influence the error is vulvar hair shaving on the day before the examination. We expected a thicker epidermis in the group of pre-menopausal women and mechanical removal of that part of the epidermis may have negatively influenced the obtained thickness values. There was no difference in mons pubis and labia minora dermal thickness. The structure of mons pubis is mostly composed of fat tissue, with hair follicles, sweat glands, sebaceous glands, covered with keratinized stratified squamous epithelium. The labia minora are doubled vaginal folds, with connective tissue, sweat and sebaceous glands covered with this non-keratinized stratified squamous epithelium. HFSU images of these structures are very characteristic, but showed no differences in the investigated area.

HFSU is particularly useful to visualize hair follicles, sweat glands, and blood vessels, especially the veins. Those structures are mostly present on mons pubis and labia majora.

Rigal et al., were the first to publish the presence of the hypoechoic band beneath the epidermis, later called later the sub-epidermal low echogenic band (SLEB) or sub-epidermal non-echogenic band (SENEB) [24]. SLEB was observed in 48% of our patients, mostly in subjects who shaved off their vulvar hair (Figure 4) [14]. Precise imaging in HFSU is possible for VLM, clitoris and urethra, with distinguishing anatomical differences in nulliparas and multiparas, as well as visualization of Skene's gland (Figures 5-8).

Another sonographic feature seen in HFSU was Hart's line, which is the area of transition of the vulvar skin to smoother vestibular skin (Figure 9).

Conclusions

This preliminary report confirmed the utility of HFSU in vulvar skin imaging. High-frequency ultrasound expands the diagnostic process of the skin by enabling the measurement of epidermal and dermal thickness. As far as vulvar examinations are concerned, HFSU produces high-resolution scans, allowing to discern skin layers and appendages. This technique is an objective and non-invasive diagnostic tool in vulvar skin examination. Further research including pre- and postmenopausal physiology and skin pathologies is needed.

Oświadczenie autorów:

1. Marian Stanisław Migda – autor koncepcji i założeń pracy, przygotowanie manuskryptu i piśmiennictwa – autor zgłaszający i odpowiedzialny za manuskrypt.
2. Michał Migda – współautor tekstu pracy i protokołu, zebranie materiału, korekta i aktualizacja literatury.
3. Bartosz Migda – zebranie materiału, analiza statystyczna wyników, przygotowanie manuskryptu.
4. Rafał Zenon Ślapa – autor założeń pracy, analizy i interpretacji wyników, przygotowanie, korekta i akceptacja ostatecznego kształtu manuskryptu.
5. Robert Krzysztof Mlosek – ostateczna weryfikacja i akceptacja manuskryptu.

Źródło finansowania:

Praca nie była finansowana przez żadną instytucję naukowo-badawczą, stowarzyszenie ani inny podmiot, autorzy nie otrzymali żadnego grantu.

Konflikt interesów:

Autorzy nie zgłaszają konfliktu interesów oraz nie otrzymali żadnego wynagrodzenia związanego z powstawaniem pracy.

References

1. Alfageme F. Practical applications of skin ultrasound. *Piel.* 2012, 27, 204-209.
2. Vozmediano J, Hita J. Utility of diagnostic ultrasonography in dermatology. *Piel.* 2003, 18, 564-573.
3. Mlosek RK. Obrazowanie skóry i tkanki podskórnej za pomocą ultrasonografii klasycznej oraz ultrasonografii wysokiej częstotliwości i jej przydatność w kosmetologii. Praca habilitacyjna. 2012, 171-173.
4. Mandava A, Ravuri PR, Konathan R. High-resolution ultrasound imaging of cutaneous lesions. *Indian J Radiol Imaging.* 2013, 23 (3), 269-277.
5. Mlosek RK, Malinowska S, Sikora M, [et al.]. The use of high frequency ultrasound imaging in skin moisturization measurement. *Skin Res Technol.* 2013, 19 (2), 169-175.
6. Mlosek RK, Malinowska S. Application of high-frequency ultrasonography in closing small blood vessels. *J Ultrason.* 2014, 14, 320-327.
7. Kleinerman R, Whang TB, Bard RL, [et al.]. Ultrasound in dermatology: principles and applications. *J Am Acad Dermatol.* 2012, 67 (3), 478-487.
8. Alexander H, Miller DL. Determining skin thickness with pulsed ultrasound. *J Invest Dermatol.* 1979, 72 (1), 17-19.
9. Miyauchi S, Tada M, Miki Y. Echographic evaluation of nodular lesions of the skin. *J Dermatol.* 1983, 10 (3), 221-227.

Marian Stanisław Migda et al. *Feasibility of using high-frequency skin ultrasound (HFSU) in vulvar skin assessment – initial report with the description of HFSU anatomy.*

10. Stiller MJ, Gropper CA, Shupack JL, [et al.]. Diagnostic ultrasound in dermatology: current uses and future potential. *Cutis*. 1994, 53 (1), 44-48.
11. Bo S, Menato G, Gallo ML, [et al.]. Mild gestational hyperglycemia, the metabolic syndrome and adverse neonatal outcomes. *Acta Obstet Gynecol Scand*. 2004, 83 (4), 335-340.
12. Bozgeyik Z, Kocakoc E, Koc M, [et al.]. Giant fibroepithelial stromal polyp of the vulva: extended field-of-view ultrasound and computed tomographic findings. *Ultrasound Obstet Gynecol*. 2007, 30 (5), 791-792.
13. Edward J. Wilkinson and Stone Atlas of Vulvar Disease. 2012.
14. Cammarota T, Pinto F, Magliaro A, [et al.]. Current uses of diagnostic high-frequency US in dermatology. *Eur J Radiol*. 1998, 27, Suppl 2, 215-223.
15. Sadowska-Przytocka A, Danczak-Pazdrowska A, Fau- Szewczyk A, [et al.]. Treatment of genital lichen sclerosus in women--review. *Ginekol Pol*. 2012, 83, 458-461.
16. Mlosek RK, Malinowska S, Stepien A, [et al.]. Changes in the high frequency skin ultrasound image associated with aging. *Ultrasonografia*. 2011, 47, 22-27.
17. Schmid-Wendtner MH, Dill-Muller D. Ultrasound technology in dermatology. *Semin Cutan Med Surg*. 2008, 27 (1), 44-51.
18. Chami L, Lassau N, Chebil M, [et al.]. Imaging of melanoma: usefulness of ultrasonography before and after contrast injection for diagnosis and early evaluation of treatment. *Clin Cosmet Investig Dermatol*. 2011, 4, 1-6.
19. Badea R, Crisan M, Lupsor M, [et al.]. Diagnosis and characterization of cutaneous tumors using combined ultrasonographic procedures (conventional and high resolution ultrasonography). *Med Ultrason*. 2010, 12 (4), 317-322.
20. Mlosek RK, Malinowska S. Ultrasound image of the skin, apparatus and imaging basics. *J Ultrason*. 2013, 13 (53), 212-221.
21. Altmeyer P, el-Gammal S, Hoffmann K (Eds.), *Ultrasound in Dermatology*. Heidelberg: Springer-Verlag 1992.
22. Shuster S, Black MM, McVitie E. The influence of age and sex on skin thickness, skin collagen and density. *Br J Dermatol*. 1975, 93 (6), 639-643.
23. Eisenbeiss C, Welzel J, Schmeller W. The influence of female sex hormones on skin thickness: evaluation using 20 MHz sonography. *Br J Dermatol*. 1998, 139 (3), 462-467.
24. de Rigal J, Escoffier C, Querleux B, [et al.]. Assessment of aging of the human skin by in vivo ultrasonic imaging. *J Invest Dermatol*. 1989, 93 (5), 621-625.

K o m u n i k a t

Seksja Gestozy i Nadciśnienia w Ciąży
Polskiego Towarzystwa GinekologicznegoOddział Lubelski
Polskiego Towarzystwa GinekologicznegoOddział Lubelski
Polskiego Towarzystwa Medycyny PerinatalnejKatedra i Klinika Położnictwa i Perinatologii
Uniwersytetu Medycznego w Lublinie

z a p r a s z a j ą n a

XVI Sympozjum
Seksji Gestozy i Nadciśnienia w Ciąży
Polskiego Towarzystwa Ginekologicznego

Cięcie cesarskie
E P I D E M I A X X I W I E K U

27-29 maja 2016 roku
Kazimierz Dolny

Miejsce obrad:

Dom Pracy Twórczej Stowarzyszenia Dziennikarzy Polskich, 24-120
Kazimierz Dolny, ul. Małachowskiego 17

<http://www.domdziennikarza.com>

Na program Sympozjum składają się będą sesje wykładowe.
Wystąpią wybitni specjaliści z grona polskich i zagranicznych ekspertów.
Przedstawione wykłady wydane będą w formie monografii.

Szczegółowe informacje dotyczące Sympozjum
dostępne są na stronie internetowej:

www.gestoza.umlub.pl

Zgłoszenia udziału należy dokonywać drogą elektroniczną:

gestoza@umlub.pl

Zgłoszenie noclegów drogą telefoniczną w Domu Dziennikarza
tel. recepcja 81-8810-162