

# Non-invasive therapeutic use of High-Intensity Focused Ultrasound (HIFU) with 3 Tesla Magnetic Resonance Imaging in women with symptomatic uterine fibroids

Tomasz Łoziński<sup>1</sup>, Justyna Filipowska<sup>1</sup>, Grzegorz Gurynowicz<sup>2</sup>,  
Iwona Gabriel<sup>1</sup>, Artur Czekierdowski<sup>3</sup>

<sup>1</sup>Department of Obstetrics and Gynecology, Pro-Familia Hospital, Rzeszow, Poland

<sup>2</sup>Division of Perinatology and Women's Diseases, Poznan University of Medical Sciences, Poznan, Poland

<sup>3</sup>1st Department of Oncological Gynecology and Gynecology, Medical University of Lublin, Poland

## ABSTRACT

Benign uterine fibroids are common female genital tract tumors and if symptomatic often require extensive surgery. When tumors are multiple and large or unusually located, the operative treatment may lead to significant morbidity and compromise quality of life. Recovery period after surgical treatment may be complicated by patient's medical condition and wound healing problems. Currently used other non-surgical treatment modalities usually provide only a temporal symptoms relief and may not be efficient in all affected women. In the last decade, minimally invasive treatment of uterine fibroids called Magnetic Resonance guided High-Intensity Focused Ultrasound (MRI HIFU) was introduced. This technique uses thermal ablation simultaneously with MRI imaging of the mass and tissue temperature measurements during the procedure where a focused ultrasound beam is applied externally to destroy tumors located in the human body. Successful application of MRI HIFU has been recently described in patients with various malignancies, such as breast, prostate and hepatocellular cancers as well as soft tissue and bone tumors. This technique is innovative and has been proven to be safe and effective but there are several limitations for treatment. The article highlights the relative advantages and disadvantages of MRI guided HIFU in women with uterine fibroids. The authors also describe high-resolution MRI technique on 3T MRI, along with the approach to interpretation of HIFU results applied to uterine fibroids that has been experienced at one institution.

**Key words:** MRI-HIFU, fibroids, utility

Ginekologia Polska 2017; 88, 9: 497–503

## INTRODUCTION

Uterine fibroids, or leiomyomas, are the most frequently found solid benign tumors of the female genital tract. Approximately 25 percent of women of childbearing age who have fibroids experience various symptoms such as pelvic pain, heavy menstrual bleeding as well as pregnancy complications [1]. Selection of other treatment options in women with uterine myomas depends on several conditions, such as women's age, parity, future reproductive plans and a willingness to preserve fertility. Also, the severity of accompanying symptoms such as pain and/or heavy bleeding and as well as fibroids size, their number and location are considered important factors. Symptomatic fibroids

are the most common indication for hysterectomy in the US and Europe [2]. An alternative option is myomectomy, indicated in cases of women who wish to preserve their fertility. It is important to note that as many as 27% of patients undergoing myomectomy may have recurrent fibroids within 10 years after surgery [3]. Several treatment options are now available for women with symptomatic uterine fibroids, ranging from surgical treatment such as hysterectomy and myomectomy, to minimally invasive laparoscopic techniques, uterine arteries embolization (UAE) or medical therapy [4, 5]. In current clinical practice, uterus-conserving therapy is the standard of care for premenopausal patients with localized myomas. Laparotomy or laparoscopic opera-

### Corresponding author:

Tomasz Łoziński  
Department of Obstetrics and Gynecology  
Pro-Familia Hospital  
Witolda 6b, 35–302 Rzeszow, Poland  
e-mail: [tomasz.lozinski@pro-familia.pl](mailto:tomasz.lozinski@pro-familia.pl)

tions used to remove uterine fibroids are not major gynecological surgeries, but still are both invasive and not free of complications [3]. Because of this, optimizing treatment of women with symptomatic uterine fibroids remains a major topic of interest with minimally invasive or non-invasive methods that have become attractive alternative for surgery. In women who wish to preserve their uterus and fertility myomectomy may be beneficial, in such cases laparoscopy whenever feasible is favored over laparotomy. Laparoscopic myomectomy and the increasing use of robotic technology for endoscopic procedures could also improve patient outcomes, including decreased recovery time [6]. However, since UAE and MRI guided HIFU are newer techniques compared to surgical myomectomy, it is likely that the increased provider experience coupled with technical innovations could result in significant improvement as these technologies mature [5–7].

Ultrasonography is currently the most commonly used imaging modality in obstetrics and gynecology, however, the potential of focused ultrasound beam energy for therapeutic use in women is less well known. Imaging with magnetic resonance was first used as a therapeutic guidance in early 1990-ties for the treatment of brain tumors, especially to obtain maximal possible resection of low grade gliomas [8]. After more than three decades of research and technological development focused ultrasound beam energy has become available for a non-invasive ablative treatment of various benign and malignant lesions. Treatment of choice in selected benign tumors is attractive alternative, but the main potential of HIFU is related to non-invasive destruction of malignant masses [9]. The method can be used for a definitive treatment, i.e. tumor removal as well as for the debulking of a malignant lesion that would facilitate the use of other treatment modalities. MRI use may facilitate tumor margin assessment in such cases. Importantly, thermal ablation of tissue within human body can be easily monitored with temperature measurements available on MRI-based thermometry. An example of a malignant tumor that can be well visualized with high resolution contrast MRI and treated with HIFU is breast cancer [10, 11]. HIFU was introduced into clinical practice in the past decade, and currently is an approved method of choice for selected women with large uterine myomas. In case of uterine fibroids both real time-ultrasound imaging and MRI have been used. An apparent advantage of the 3T MRI lies in the precision of showing the extent of a mass to be treated and which is used to guide the high energy focused ultrasound beam directly to the target tissue [12]. By careful placement of energy focus HIFU creates discrete areas of tissue necrosis that do not require surgical removal. Because of this HIFU has become an alternative non-invasive method of uterine fibroids treatment. In order to summarize current status

of knowledge we performed PubMed database search for papers related to MRI guided HIFU treatment modality for uterine fibroids. The purpose of this paper is to present an update on the potential use of this treatment in women with symptomatic uterine fibroids and to share our own experience with this method applied in one institution. In this review the 3T MRI guided HIFU procedure will be described, including a description of important physiological and technical details, indications, contraindications, complications, and outcomes.

### **RATIONALE FOR MRI USE FOR GUIDED FOCUSED ULTRASOUND FIBROID ABLATION**

Magnetic resonance imaging guided high intensity focused ultrasound procedures provide a relatively safe and feasible alternative to surgical resection for the treatment of women with symptomatic uterine myomas [7, 12]. The potential of high focused ultrasound energy to interact with various tissues has been known for several years and the first MRI guided HIFU platform received United States FDA approval in 2004 [13]. This method is currently used more frequently than percutaneous microwave ablation. The results of both treatments are quite similar [14]. The therapeutic potential of HIFU is related to its ability to deliver high-energy doses that are localized deep within the human body without harming the surrounding tissue.

MRI guided HIFU uses constant magnetic resonance monitoring, heats the fibroid tissue in individual sonifications until the tissue is completely ablated [15]. Apart from this thermal destruction, many other and complex non-thermal effects of focused high-energy ultrasound beam directed to the tissue of internal organ are also important. Multiple acoustic and mechanical stimuli are related to microbubble generation and related phenomenon called cavitation, radiation pressure exerted by the mechanical force in the focal zones and finally acoustic streaming related to the induced by ultrasound beam fluid movements. In case of fibroids acoustic cavitation is less important as it only happens in microbubbles containing gas and these microbubbles are typically generated in fluid containing tissues by acoustic pressure waves. High energy of focused ultrasound beam may cause not only oscillation of the bubbles but also may release abruptly a stored energy that produces shock wave [16]. The effects of cavitation are much less predictable than high temperature use for heating of the tissue and as a final effect the destruction of affected region with internal hemorrhage may be observed. Combination of heating effects with cavitation may be used for the enhancement of the destruction effects [12–14].

The intensity of targeted tumor volumes sonication with ultrasound beam varies between 500 and 20 000 W/square cm applied over 1 to 60 seconds [16]. Since cooling of the

tissue is needed, shorter periods of sonication are preferred. The cooling period after each cycle of sonication should last until the temperature would return to the baseline, which will prevent a buildup of excessive heat in a surrounding, non-targeted tissue lying in the ultrasound beam path zone. The focal spot is visible on MRI thermometry which can measure actual target tissue temperature changes. MRI guidance enables precise and reproducible spatiotemporal control of ultrasound beam energy delivered to the tissue and when the goal is accomplished, the power level may be increased again to obtain irreversible tumor necrosis related to denaturation of proteins and disruption of fibroid microvasculature [9].

Treatment planning, monitoring tissue damage and final results evaluation in focused ultrasound tissue destruction area requires extremely accurate precision of imaging. MRI outperforms ultrasound and other imaging techniques when HIFU is considered. Contrast-enhanced T1-weighted and T2 weighted imaging is typically employed, but non-perfused volume is not directly correlated with the amount of non-viable tumor tissue. Because of this the protocols of MRI imaging for HIFU procedure are constantly upgraded. The study of high-intensity focused ultrasound tissue effects is facilitated with 3-Tesla (3T) MRI scanning [12]. One advantage of 3T MRI over most commonly used 1,5 T scanners is an improved signal-to-noise ratio (SNR) due to greater spin polarization, which may be used in imaging studies to improve spatial and/or temporal resolution. Another potential advantage is better contrast, including an improved contrast-to-noise ratio (CNR) with new or more physiologically specific sources of contrast [16].

Until today, there have been only a few reports about serious complications after HIFU. Recently, Kim al. [17] re-

ported three cases of complications after US-guided HIFU ablation for huge uterine fibroids, including two cases of rapid increase in size of the fibroids and one case of heavy vaginal bleeding. Upon completion of thermoablation, the control MRI scan should indicate the lack of contrast in the target tissue. The goal of HIFU treatment is to induce shrinking of a tissue mass, and because of this, a close to 100% destruction of the fibroid should not be expected and is not the purpose of this treatment [13].

## PHYSICAL BASIS OF HIFU

The explanation of the physical basis of MRI guided HIFU procedure is presented in Figure 1.

Pretreatment fibroid signal intensity (SI) and nonperfused volume (NPV) immediately after MRI guided HIFU procedure independently predict fibroid size and/or volume reduction during 12 month-follow up [16]. Published data indicate, that typical values of 11–13% reduction of an initial fibroid volume are most commonly expected [11, 13]. Moreover, most fibroids with estimated NPV less than 20% showed no further decrease in size after 12 months of follow up [18]. Since the complete remission of a fibroid is not an ultimate goal of the treatment, in many countries this option is performed in the diagnostic and interventional radiology units and is offered mainly for the decrease of the size and symptoms relief [16].

First MRI guided HIFU unit in Poland has been installed in Pro Familia Hospital, Rzeszow within the Department of Gynecology in December, 2014 [12]. The Sonalleve 3T MRI guided HIFU platform was manufactured by Phillips (The Netherlands) uses a focused transducer to bundle ultrasound energy into a small volume at the target locations inside the human body. Patients before therapy need some

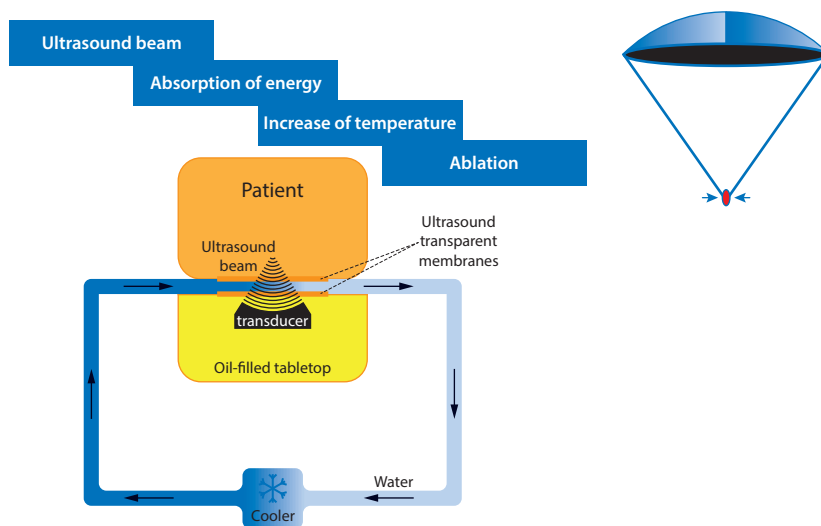
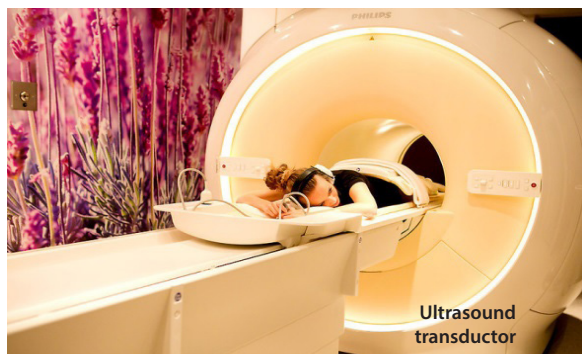

Figure 1. A diagram presenting physical basis of HIFU treatment

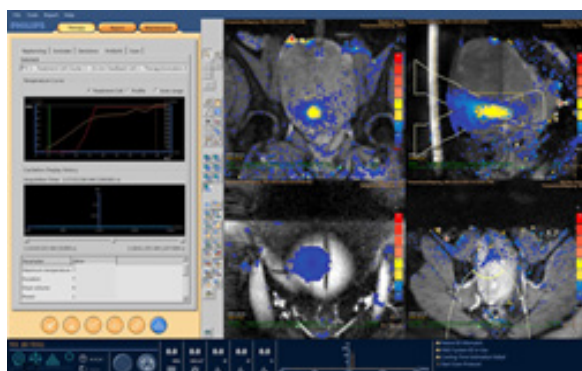


**Figure 2.** Patient positioning during treatment with 3T MRI guided HIFU Platform in Pro-Familia Hospital

preparation that includes bladder or rectum fluid filling in order to obtain optimal ultrasound beam window [18]. The Sonalleve 3T MRI system is designed for an intact skin. A typical placement of a patient for MRI guided HIFU procedure is shown on Figure 2.

During treatment, the ultrasound energy beam passes through the intact skin and soft tissue, causing localized high temperatures (60–100°C) only in the focus area [13]. The skin and intermediate tissue are left unharmed. Within a few seconds high-intensity focused ultrasound beam produces a well-defined region of coagulative necrosis. Simultaneously used three-dimensional 3T MR images show immediate anatomical site reference data for treatment planning. During ablation procedure real-time temperature sensitive images are acquired and provide real-time information on treatment progress. Constant monitoring of all critical anatomical structures is feasible [19]. Figure 3 presents a typical example of a real-time 3T MR mapping of temperature changes within and around ablated tissue.

The unit acquires T2 signal intensity (SI) measurements which will be next used as classification parameters for determining patient suitability for the procedure. A visual



**Figure 3.** An example of 3T MRI real-time mapping of tissue temperature with yellow color depicting hot areas and blue color designated for colder areas

inspection and SI values are used to classify fibroids into one of three types: type I (i.e. SI lower than that of skeletal muscles), type II (i.e. SI lower than that of myometrium but higher than that of skeletal muscles or type III (i.e. SI higher than that of the myometrium). The use of this classification suggested that low T2 SI values might be predictive of high nonperfused volume (NPV) ratio [9]. Several other technical details related to MRI guided HIFU technique are presented below.

### VOLUMETRIC HEATING

The focused ultrasound beam is rapidly transmitted over the tissue volume that was planned to be ablated. Ellipsoidal ablation volumes can be adjusted for the distances up to 16 mm wide and 40 mm long, leading to a macroscopic ablation of this tissue zone within seconds. Larger target volumes are usually covered with multiple heating episodes repeated over time. This is opposite to uterine artery embolization, where the effect is very fast and usually causes many suddenly appearing, unwanted side-effects [5, 9, 10].

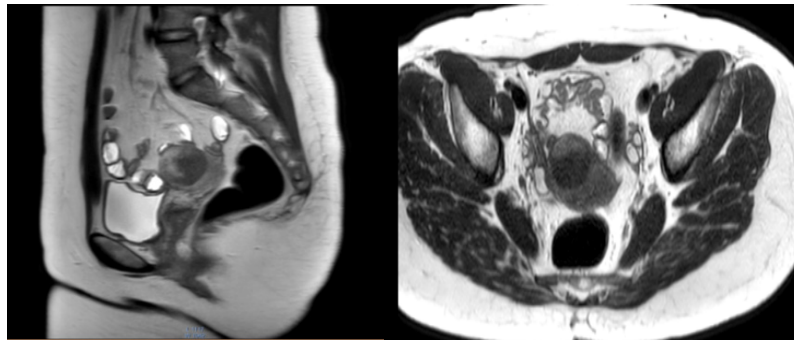
### REAL-TIME FEEDBACK

During treatment, the MRI scanner acquires temperature-sensitive images to monitor local heat distribution and to identify critical structures that must not be subjected to heat. The temperature information is used to automatically enhance HIFU delivery parameters, thus creating a feedback loop based on real-time temperature monitoring. This is an essential step extremely important to keep treatment times short while maintaining high-quality ablation of a target tissue [19].

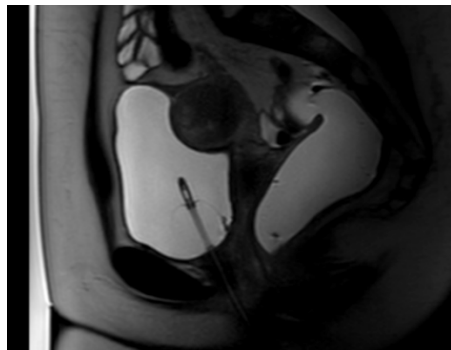
### HOMOGENEOUS HEATING

With a real-time feedback the 3T MRI guided HIFU system constantly compensates released energy for local variations in tissue properties, such as inhomogeneous absorption, attenuation, perfusion, and diffusion [13]. Otherwise, these variations can lead to local overheating or insufficient heating. While overheating could pose undesired effects and in addition would lead to increased treatment time, insufficient heating, e.g. near cooling vessels, could potentially leave tissue unablated. Examples of 3T MR images of fibroids before and after MRI guided HIFU procedure are shown on Figures 4–6. Examples of typical changes in uterine myoma after HIFU therapy are shown on Figure 7.

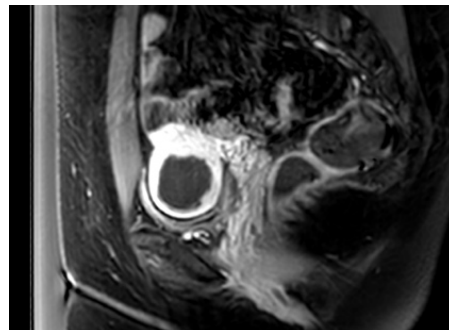
It is important to emphasize that not all women with symptomatic fibroids may be treated with MRI guided HIFU method. Patients who may benefit from this treatment modality have to be carefully selected [15, 16]. Currently used qualification criteria for the procedure in our hospital include the following indications:



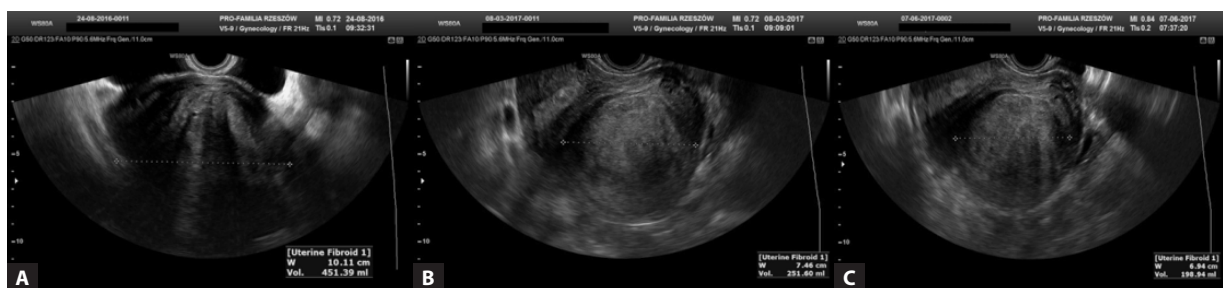
**Figure 4.** An example of 3T MRI image of a fibroid before treatment



**Figure 5.** Treatment with 3T MRI guided HIFU visualization of a catheter maneuvering in the urinary bladder



**Figure 6.** 3T MRI image of a fibroid following successful MRI guided HIFU treatment. A round shape black region corresponds to the area of tissue ablation in the fibroid



**Figure 7.** A typical sonographic appearance of a fibroid before 3T MRI guided HIFU therapy (A) and after 3 (B) and 6 months (C) of follow-up

- large and symptomatic fibroids,
- maximum size of the tumor < 130 mm,
- positive qualification for the MRI/US scan, i.e. the presence of a suitable therapeutic window for ultrasound beam.

Exclusion criteria include:

- size of a mass larger > 130 mm (relative, case-by-case decision),
- atypical localization of a fibroid(s),
- pregnancy,
- pelvic inflammatory disease (PID),
- contraindications to MRI exam,
- too close distance to the sacral bone < 20 mm.

### SIDE EFFECTS/COMPLICATIONS OF MRI GUIDED HIFU THERAPY

There are several rare, but important side effects and complications related to MRI guided HIFU treatment which include:

- pain,
- inflammation of subcutaneous fatty tissue and muscles of the abdominal wall,
- skin burns,
- deep vein thrombosis,
- paresthesia of the leg due to the nerve irritation or damage,
- bowel perforation (extremely rare).



It is important to present a detailed information on the whole procedure to the woman considered for a potential MRI guided HIFU treatment. When agreeing for this procedure, the patient should know and understand not only basic information but also the expected effectiveness, the possible side-effects and the length of the procedure. This has been recently reported to be as long as the median of 92 minutes with the range between 54 to 121 minutes [16]. Knowledge on all these issues seems to be crucial for further patient's satisfaction rate with the procedure itself. It is important to inform the patient that following MRI guided HIFU treatment occasionally some tissue components may be discharged vaginally, also an increased uterine bleeding may continue until approximately 3 months after the procedure.

Following 3 years of the 3T MRI guided HIFU procedure application our initial results indicate that in 56% cases the effect of therapy revealed more than 70% of fibroid tissue ablation, which is similar to the results reported by other centers [7, 14, 15, 17, 18]. The most common causes of the withdrawal from treatment attempts were largely related to bowel location in relation to the fibroid position. In such cases repositioning of the fibroid required some maneuvering and was not always effective. The same type of complication was observed by other authors [7, 15, 18]. In 2015 Pron [20] presented a meta-analysis of available studies on the use of MRI guided HIFU. The review included data on approximately 1600 women treated in 45 cohort studies, 19 case reports and two systematic reviews. Overall reported complications rate was 1.6%, whereas the eligibility for the procedure was ranging from 14% to 75%. According to this review, in clinical studies the higher retreatment rates were generally found and immediate acute interventions following the procedure were very rare. However, in most of these studies the follow-up was usually less than one year [20]. MRI guided HIFU should be performed only at hospitals or clinics possessing the requisite expertise and experience with this therapy. The experience should also include the ability to treat non-surgical and surgical side effects as well as typical complications. In addition, these centers should have an option to initiate appropriate post-interventional pain management [16].

The data on the long-term impact of HIFU therapy on fertility are still insufficient, but recent report by Zhou et al. [21] has shown promising results. These Authors investigated pregnancy outcomes following the HIFU treatment in one institution over 5 years. In total 78 patients had 80 pregnancies, in which 76 cases were natural pregnancies and four were obtained after IVF. The average time from treatment to pregnancy was  $5.6 \pm 2.7$  months. There were no significant complications in fetal development, uterine rupture, perinatal or postpartum complications. Pregnancies ended with 15 full term vaginal deliveries and 53 cesarean sec-

tions at term with 3 preterm cesarean sections. The Authors have concluded that HIFU can effectively treat women with uterine fibroids and can significantly reduce the time from treatment to pregnancy.

The cost-effectiveness of standard therapy in women with uterine fibroids depends on many factors that has to be taken into account. These costs include surgery, hospital admissions, outpatient visits, and medications and -what is often forgotten- medical treatment of women who became pregnant while having uterine fibroids. In addition to all these factors, there is a substantial cost of medical non-surgical treatment related to symptomatic uterine fibroids. It has been estimated that the total direct cost of uterine fibroids treatment in the United States between \$5.9–34.4 billion annually [22]. Recently, Cain-Nielsen et al. [23] presented updated cost-effectiveness analysis of three different treatment modalities used in women with symptomatic uterine fibroids. When incorporating productivity costs, MRI guided HIFU incurred a mean cost of US\$21, 232; myomectomy US\$22,599; and UAE US\$22,819. The difference in effectiveness between the three treatments was minimal, but when the productivity costs were incorporated into this analysis, the MRI guided HIFU strategy became a cost-effective alternative to myomectomy. The main advantage was the reduction in missed days of work from shorter postoperative recovery. UAE remained dominated with and without lost productivity costs [23]. The impact of various modern treatment modalities such as UAE and MRI HIFU on fertility outcomes remains understudied. Although the cost of MRI guided high energy focused ultrasound is high, it can be offset by the elimination of the need for an operating room, the absence of expensive hospitalization and anesthesia, and a reduced complication rate. Additional research is needed to effectively use these important outcomes in future analyses.

## SUMMARY

In summary, 3T MRI guided HIFU is a unique, noninvasive uterine-preserving new treatment modality and as of today is no longer considered investigational for symptomatic uterine fibroids. This method is an alternative to hysterectomy for women with symptoms producing fibroids and for those who had ineffective medical therapy. The goal of the therapy using focused ultrasound should be the achievement of the largest possible non-perfused volume (NPV) of a tumor. To adequately compare currently used non-invasive, minimally invasive and surgical methods used for the treatment of women with symptomatic uterine fibroids more prospective and well designed studies are needed. These studies should primarily assess rates of short-term and long-term complications, occurrence of serious side effects like e.g. thromboembolism as well as the need for

myomectomy and hysterectomy at a later stage of life of treated women.

**Clinical advantages:** It is a non-invasive treatment with a low risk of complications, with durable resolution of fibroid related symptoms. Easy planning and treatment in selected patients, no damage to surrounding tissue.

**Patient advantages:** Fast, non-invasive therapy, performed on an out-patient basis, procedure can be repeated if necessary.

**Disadvantages:** Costs of equipment and high drop-out rate. Not all women with symptomatic fibroids may be successfully treated with MRI guided HIFU and a drop-out rates may be quite high. To diminish this rate, a much better knowledge among gynecologists is needed before patients qualification for a possible MRI guided HIFU procedure.

## REFERENCES

- Pérez-López FR, Ornat L, Ceausu I, et al. EMAS. EMAS position statement: management of uterine fibroids. *Maturitas*. 2014; 79(1): 106–116, doi: [10.1016/j.maturitas.2014.06.002](https://doi.org/10.1016/j.maturitas.2014.06.002), indexed in Pubmed: [24975954](https://pubmed.ncbi.nlm.nih.gov/24975954/).
- Fonseca MCM, Castro R, Machado M, et al. Uterine artery embolization and surgical methods for the treatment of symptomatic uterine leiomyomas: a systemic review and meta-analysis followed by indirect treatment comparison. *Clin Ther*. 2017; 39(7): 1438–1455.e2, doi: [10.1016/j.clinthera.2017.05.346](https://doi.org/10.1016/j.clinthera.2017.05.346), indexed in Pubmed: [28641997](https://pubmed.ncbi.nlm.nih.gov/28641997/).
- Shin DG, Yoo HJ, Lee YAh, et al. Recurrence factors and reproductive outcomes of laparoscopic myomectomy and minilaparotomic myomectomy for uterine leiomyomas. *Obstet Gynecol Sci*. 2017; 60(2): 193–199, doi: [10.5468/ogs.2017.60.2.193](https://doi.org/10.5468/ogs.2017.60.2.193), indexed in Pubmed: [28344961](https://pubmed.ncbi.nlm.nih.gov/28344961/).
- Szamatowicz M, Kotarski J. [Selective progesterone receptor modulator (ulipristal acetate — a new option in the pharmacological treatment of uterine fibroids in women). *Ginekol Pol*. 2013; 84(3): 219–222, indexed in Pubmed: [23700851](https://pubmed.ncbi.nlm.nih.gov/23700851/).
- Brito Pires NM, Godoi ET, Oliveira DC, et al. Impact of pelvic magnetic resonance imaging findings in the indication of uterine artery embolization in the treatment of myoma. *Ginekol Pol*. 2017; 88(3): 129–133, doi: [10.5603/GPa.2017.0024](https://doi.org/10.5603/GPa.2017.0024), indexed in Pubmed: [28397200](https://pubmed.ncbi.nlm.nih.gov/28397200/).
- Kim S, Luu THa, Llarena N, et al. Role of robotic surgery in treating fibroids and benign uterine mass. *Best Pract Res Clin Obstet Gynaecol*. 2017 [Epub ahead of print], doi: [10.1016/j.bpobgyn.2017.04.004](https://doi.org/10.1016/j.bpobgyn.2017.04.004), indexed in Pubmed: [28551090](https://pubmed.ncbi.nlm.nih.gov/28551090/).
- Liu Y, Ran W, Shen Y, et al. High-intensity focused ultrasound and laparoscopic myomectomy in the treatment of uterine fibroids: a comparative study. *BJOG*. 2017; 124 Suppl 3: 36–39, doi: [10.1111/1471-0528.14745](https://doi.org/10.1111/1471-0528.14745), indexed in Pubmed: [28856854](https://pubmed.ncbi.nlm.nih.gov/28856854/).
- Carsin M, Rolland Y, Gandon Y, et al. Contribution of MRI to the diagnosis and post-therapeutic monitoring of brain stem tumours. *J Neuroradiol*. 1990; 17(1): 50–59, indexed in Pubmed: [2388094](https://pubmed.ncbi.nlm.nih.gov/2388094/).
- Schulman AA, Tay KJ, Robertson CN, et al. High-intensity focused ultrasound for focal therapy: reality or pitfall? *Curr Opin Urol*. 2017; 27(2): 138–148, doi: [10.1097/MOU.0000000000000372](https://doi.org/10.1097/MOU.0000000000000372), indexed in Pubmed: [27997415](https://pubmed.ncbi.nlm.nih.gov/27997415/).
- Mauri G, Sconfienza LM, Pescatori LC, et al. Technical success, technique efficacy and complications of minimally-invasive imaging-guided percutaneous ablation procedures of breast cancer: A systematic review and meta-analysis. *Eur Radiol*. 2017; 27(8): 3199–3210, doi: [10.1007/s00330-016-4668-9](https://doi.org/10.1007/s00330-016-4668-9), indexed in Pubmed: [28050693](https://pubmed.ncbi.nlm.nih.gov/28050693/).
- Knuttel FM, Huijssse SEM, Feenstra TL, et al. Early health technology assessment of magnetic resonance-guided high intensity focused ultrasound ablation for the treatment of early-stage breast cancer. *J Ther Ultrasound*. 2017; 5: 23, doi: [10.1186/s40349-017-0101-3](https://doi.org/10.1186/s40349-017-0101-3), indexed in Pubmed: [28781881](https://pubmed.ncbi.nlm.nih.gov/28781881/).
- Filipowska J, Łoziński T. Magnetic resonance-guided high-intensity focused ultrasound (MR-HIFU) in treatment of symptomatic uterine myomas. *Pol J Radiol*. 2014; 79: 439–443, doi: [10.12659/PJR.890606](https://doi.org/10.12659/PJR.890606), indexed in Pubmed: [25469176](https://pubmed.ncbi.nlm.nih.gov/25469176/).
- Ringold S. FDA approves ultrasound fibroid therapy. *JAMA*. 2004; 292(23): 2826, doi: [10.1001/jama.292.23.2826](https://doi.org/10.1001/jama.292.23.2826), indexed in Pubmed: [15598901](https://pubmed.ncbi.nlm.nih.gov/15598901/).
- Zhao WP, Han ZY, Zhang J, et al. A retrospective comparison of microwave ablation and high intensity focused ultrasound for treating symptomatic uterine fibroids. *Eur J Radiol*. 2015; 84(3): 413–417, doi: [10.1016/j.ejrad.2014.11.041](https://doi.org/10.1016/j.ejrad.2014.11.041), indexed in Pubmed: [25572326](https://pubmed.ncbi.nlm.nih.gov/25572326/).
- Kröncke T, David M, Matzko MF, et al. Consensus meetings regarding uterine artery embolization and focused ultrasound in fibroid treatment: an analysis. *Rofo*. 2017; 189(6): 508–510, doi: [10.1055/s-0043-108824](https://doi.org/10.1055/s-0043-108824), indexed in Pubmed: [28591884](https://pubmed.ncbi.nlm.nih.gov/28591884/).
- David M, Matzko M. MR-Guided focused ultrasound in fibroid treatment — results of the 3rd radiological-gynecological expert meeting. *Rofo*. 2017; 189(6): 515–518, doi: [10.1055/s-0043-108994](https://doi.org/10.1055/s-0043-108994), indexed in Pubmed: [28591886](https://pubmed.ncbi.nlm.nih.gov/28591886/).
- Kim HK, Kim D, Lee MK, et al. Three cases of complications after high-intensity focused ultrasound treatment in unmarried women. *Obstet Gynecol Sci*. 2015; 58(6): 542–546, doi: [10.5468/ogs.2015.58.6.542](https://doi.org/10.5468/ogs.2015.58.6.542), indexed in Pubmed: [26623424](https://pubmed.ncbi.nlm.nih.gov/26623424/).
- Kim YS, Lim HK, Rhim H. Magnetic resonance imaging-guided high-intensity focused ultrasound ablation of uterine fibroids: effect of bowel interposition on procedure feasibility and a unique bowel displacement technique. *PLoS One*. 2016; 11(5): e0155670, doi: [10.1371/journal.pone.0155670](https://doi.org/10.1371/journal.pone.0155670), indexed in Pubmed: [27186881](https://pubmed.ncbi.nlm.nih.gov/27186881/).
- Lam MK, de Greef M, Bouwman JG, et al. Multi-gradient echo MR thermometry for monitoring of the near-field area during MR-guided high intensity focused ultrasound heating. *Phys Med Biol*. 2015; 60(19): 7729–7745, doi: [10.1088/0031-9155/60/19/7729](https://doi.org/10.1088/0031-9155/60/19/7729), indexed in Pubmed: [26394264](https://pubmed.ncbi.nlm.nih.gov/26394264/).
- Pron G. Magnetic resonance-guided high-intensity focused ultrasound (MRgHIFU) treatment of symptomatic uterine fibroids: an evidence-based analysis. *Ont Health Technol Assess Ser*. 2015; 15(4): 1–86, indexed in Pubmed: [26357530](https://pubmed.ncbi.nlm.nih.gov/26357530/).
- Zou M, Chen L, Wu C, et al. Pregnancy outcomes in patients with uterine fibroids treated with ultrasound-guided high-intensity focused ultrasound. *BJOG*. 2017; 124 Suppl 3: 30–35, doi: [10.1111/1471-0528.14742](https://doi.org/10.1111/1471-0528.14742), indexed in Pubmed: [28856864](https://pubmed.ncbi.nlm.nih.gov/28856864/).
- Cardozo ER, Clark AD, Banks NK, et al. The estimated annual cost of uterine leiomyomata in the United States. *Am J Obstet Gynecol*. 2012; 206(3): 211.e1–211.e9, doi: [10.1016/j.ajog.2011.12.002](https://doi.org/10.1016/j.ajog.2011.12.002), indexed in Pubmed: [22244472](https://pubmed.ncbi.nlm.nih.gov/22244472/).
- Cain-Nielsen AH, Moriarty JP, Stewart EA, et al. Cost-effectiveness of uterine-preserving procedures for the treatment of uterine fibroid symptoms in the USA. *J Comp Eff Res*. 2014; 3(5): 503–514, doi: [10.2217/cer.14.32](https://doi.org/10.2217/cer.14.32), indexed in Pubmed: [24878319](https://pubmed.ncbi.nlm.nih.gov/24878319/).