

Eales' disease

Ioannis A. Mallias , Panagiota Petrakogianni

Laser Plus Eye, Nea Smyrni, Athens, Greece

ABSTRACT

This is a case report of a patient diagnosed with Eales' disease. Characteristics, etiology and symptoms will be described in this study. Moreover, we will present case of a 61-year-old woman and discuss the clinical features, treatment plan and its outcome in our patient.

KEY WORDS: Eales' disease; vitreous haemorrhage; floaters

Ophthalmol J 2019; Vol. 4, 28–30

INTRODUCTION

Eales' disease was first described by the British ophthalmologist in 1880 by Henry Eales, who thought that it is a non-inflammatory condition. The definition and etiology of Eales' disease are not adequately established [1]. In recent years, clinical and basic research, have provided significant clues to the understanding of the clinical features and etiology of Eales' disease [2]. It is an idiopathic peripheral retinal vasculopathy characterized by three overlapping stages of venous inflammation (vasculitis), occlusion and retinal features [2]. Other features of the disease are phlebitis, dilated aneurismal changes, shunt vessels and even macular edema [3]. Patients may present with decreased vision, photopsia and floaters unilaterally or bilaterally. Its etiology appears to be multifactorial [5]. It is claimed that hypertensive patients are prone to have this disease. The management depends on the stage of the disease and consists of medical treatment with oral corticosteroids in the active inflammatory stage and laser photocoagulation in the advanced retinal ischemia and neovascularization stages [5].

CASE REPORT

A 61-year-old woman complaining about floaters. Floaters caused by the mild vitreous haemorrhage. Her best corrected visual acuity (BCVA) was

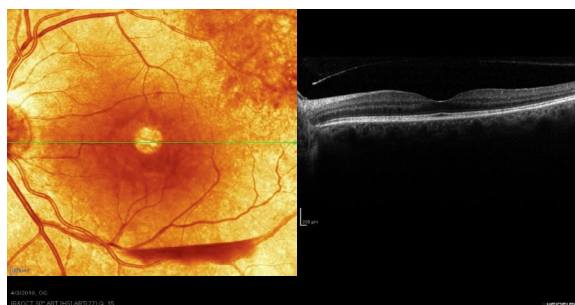


FIGURE 1. Left eye macula's image through the OCT imaging

20/20 in both eyes. The image we got through the OCT (Spectralis HRA+OCT, Heidelberg Engineering, Germany), revealed a preretinal haemorrhage in her left eye at her lower vascular arcade (Fig. 1).

The patient informed about her personal case history with hypertension and hereditary glaucoma coming from her father's side. Dr. Mallias decided that a multicolor imaging and a fluorescein angiography were essential in order to fully diagnose the case (Fig. 2).

The fluorescein angiography demonstrated abnormal staining in areas of vascular sheathing [6]. At the early stage of the examination, an area of hypo-fluorescence at the lower vascular arcade was found, which was attributed (Fig. 3) to a preretinal haemorrhage. Moreover, supertemporal to the macula an area of extended retinal ischemia was ob-

CORRESPONDING AUTHOR:

Ioannis Mallias, Laser Plus Eye, Kallipoleos 3, Nea Smyrni, Athens, Greece, e-mail: laser4myopia@yahoo.gr

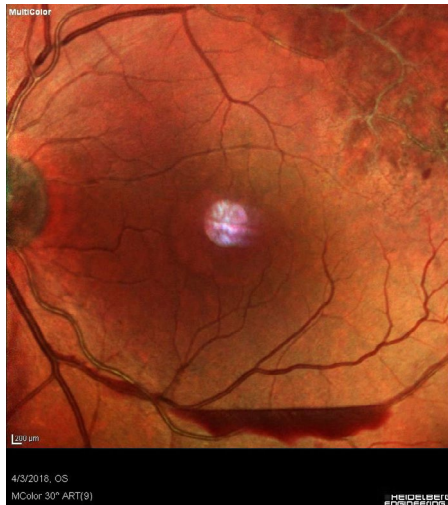


FIGURE 2. Left eye's image through the multicolor imaging

served, as well as the existence of multiple collateral vessels, in which small areas of focal hyper-fluores-

cence were found, being attributed to minor aneurisms. At the late stage of the examination, leakage of the fluorescence dye substance was observed which was attributed to retinal neovascularization. In addition, there was a leakage of the dye substance through the inner side of the veins of the retina. We performed a tuberculin test which turned out to be negative.

Argon laser photocoagulation was performed solely on the ischemic part of the retina. Three months later, we proceeded to a new fluorescein angiography where we observed that there was no retinal neovascularization. Furthermore, we noticed an improvement in the condition of the vessels and no vitreous haemorrhage occurred ever since.

DISCUSSION

The findings are compatible with Eales' disease, which is found at the late stage of retinal

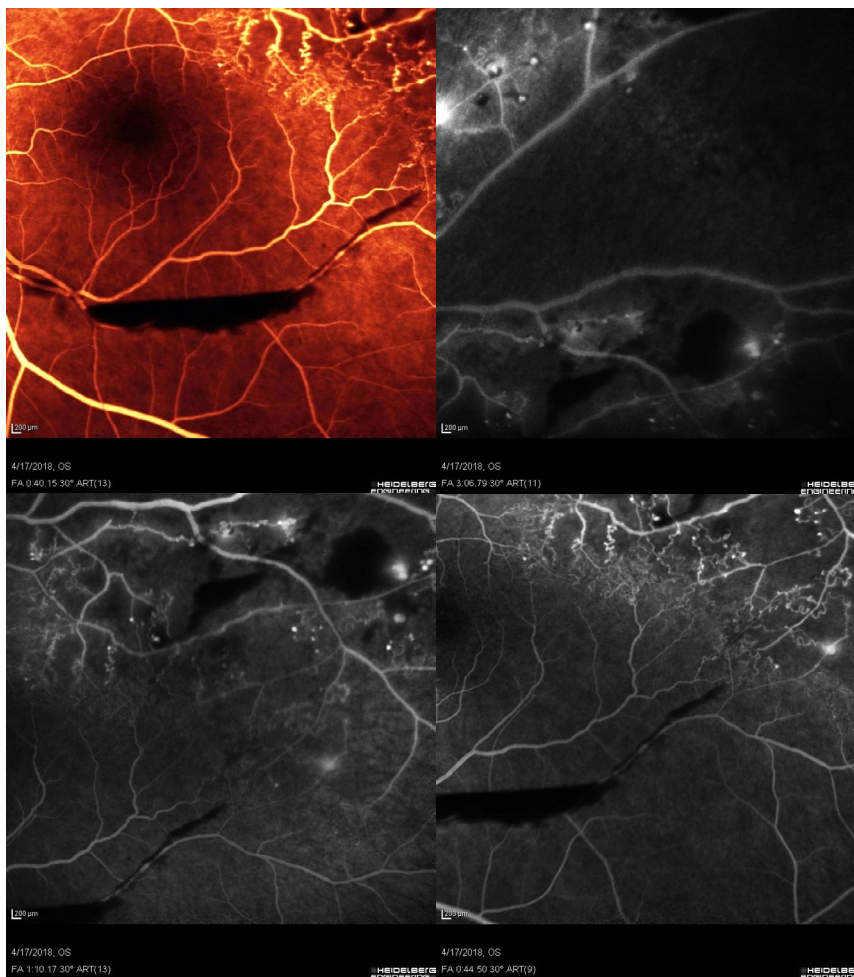

FIGURE 3. Left eye's image through the fluorescein angiography

ischemia accompanied by retinal neovascularization. The application of Argon Laser photocoagulation solely on the affected by ischemia area of the retina is recommended. With vascular non-perfusion and retinal neovascularization, intravitreal anti-VEGF therapy may be successful, however, its effects may cause vitreoretinal contraction [7]. In patients with exposure to tuberculosis, anti-tubercular therapy can be given for 9 months, but this is reserved for patients with massive infiltration, nodule formation, and venous obliteration. For non-resolving vitreous haemorrhage and/or retinal detachment (whether tractional, rhegmatogenous or combined), pars plana vitrectomy is necessary, with or without other vitreoretinal surgical procedures [8]. Endolaser treatment may be applied at the time of surgery. Vitrectomy for non-resolving vitreous haemorrhage should be performed no later than 6 months following onset of haemorrhage [9].

REFERENCES

1. Patnaik B, Nagpal P, Namperumalsamy P, et al. Eales disease – clinical features, pathophysiology, ethiopathogenesis. *Ophthalmol Clin North Am.* 1998; 11(4): 601–617, doi: [10.1016/s0896-1549\(05\)70081-x](https://doi.org/10.1016/s0896-1549(05)70081-x).
2. Biswas J, Ravi RK, Naryanasamy A, et al. Eales' disease – current concepts in diagnosis and management. *J Ophthalmic Inflamm Infect.* 2013; 3(1): 11, doi: [10.1186/1869-5760-3-11](https://doi.org/10.1186/1869-5760-3-11), indexed in Pubmed: [23514227](https://pubmed.ncbi.nlm.nih.gov/23514227/).
3. Nicolcescu A, Mocanu C, Dinu L, et al. Unilateral Eales' disease a case report. *Rom J Ophthalmol.* 2017; 61(2): 144–149, doi: [10.22336/rjo.2017.27](https://doi.org/10.22336/rjo.2017.27).
4. Gupta SR, Flaxel CJ. The use of a vascular endothelial growth factor inhibitor (ranibizumab) in macular edema due to eales disease. *Retin. Cases Brief Rep.* 2012; 6(1): 122–124, doi: [10.1097/ICB.0b013e31821608e8](https://doi.org/10.1097/ICB.0b013e31821608e8), indexed in Pubmed: [25390730](https://pubmed.ncbi.nlm.nih.gov/25390730/).
5. Belmokhtar A, Daoudi R. Eales disease: no typical clinical presentation. *Pan Afr Med J.* 2014; 17: 136.
6. Jacobiec FA, Albert DM. *Atlas of clinical ophthalmology.* Saunders, Philadelphia 1996.
7. Agrawal S, Agrawal J, Agrawal TP. Intravitreal triamcinolone acetonide in Eales disease. *Retina.* 2006; 26(2): 227–229, indexed in Pubmed: [16467685](https://pubmed.ncbi.nlm.nih.gov/16467685/).
8. Patwardhan S, Azad R, Shah B, et al. Role of intravitreal bevacizumab in Eales disease with dense vitreous hemorrhage: a prospective randomized control study. *Retina.* 2011; 31(5): 866–870, doi: [10.1097/iae.0b013e3181f2a27f](https://doi.org/10.1097/iae.0b013e3181f2a27f).
9. Paine SK, Sen A, Chowdhury IH, et al. Assessment of gelatinase and tumor necrosis factor- α level in the vitreous and serum of patients with Eales disease: role of inflammation-mediated angiogenesis in the pathogenesis of Eales disease. *Retina.* 2011; 31(7).
10. Das T, Pathengay A, Hussain N, et al. Eales' disease: diagnosis and management. *Eye (Lond).* 2010; 24(3): 472–82.
11. Roy FH, Randall J, Fraunfelder FT. *Current Ocular Therapy.* Elsevier/Saunders, Philadelphia 2008: 624–625.
12. Fraunfelder FT, Randall J, Roy FH. *Current Ocular Therapy.* Saunders Company, Philadelphia 2000: 609–611.