

# Partial transepithelial topography-guided PRK combined with corneal collagen crosslinking in patients with keratoconus

Ioannis A. Mallias, Panagiota Mylova, Aikaterini Mouzaka, Anastasia Tasiopoulou, Ronis Christidis

*Laser Plus Eye, Nea Smyrni, Athens, Greece*

## ABSTRACT

**INTRODUCTION.** The aim of this study is to identify the visual outcome and possible complications of partial transepithelial topography-guided PRK combined with collagen crosslinking in patients with keratoconus.

**MATERIALS AND METHODS.** Twenty eyes (20 patients) were treated with partial transepithelial topography-guided PRK combined with collagen crosslinking. Patients were evaluated preoperatively for best spectacle corrected visual acuity (BSCVA), clinical signs of keratoconus via slit lamp examination, and Scheimpflug-generated corneal topography. All eyes were treated with Amaris 750s Excimer Laser and KXL system.

**RESULTS.** Mean BCVA was improved from 20/100 to 20/25, postoperatively. Mean flat K was  $46.8 \pm 0.14$  D preoperatively and was reduced to  $45.2 \pm 0.7$  D postoperatively. Mean steep K was reduced from  $50.2 \pm 0.10$  D to  $47 \pm 0.6$  D. Total corneal astigmatism was  $4.5 \pm 0.14$  D and decreased to  $2.5 \pm 0.10$  D postoperatively. Average thinnest pachymetry was reduced from  $465 \pm 9.9$   $\mu\text{m}$  to  $416 \pm 11.3$   $\mu\text{m}$ . Total RMS (corneal aberrations) was  $15.5 \pm 7.4$   $\mu\text{m}$  and was significantly reduced to  $5.5 \pm 2$   $\mu\text{m}$ .

**CONCLUSIONS.** Partial transepithelial topography-guided PRK combined with collagen crosslinking can benefit patients fitting the criteria for such a procedure, by stabilising their cornea as well as improving their BSCVA.

**KEY WORDS:** PRK, PRK&CXL, keratoconus, crosslinking, CXL, topography guided

*Ophthalmol J 2016; Vol. 1, No. 4, 133–136*

## INTRODUCTION

Keratoconus is a corneal abnormality [1] where the central or paracentral cornea undergoes progressive thinning and steepening, causing irregular astigmatism. Its aetiology is unknown, but there are some systemic diseases associated with the appearance of keratoconus such as Down's syndrome, Marfan's syndrome, and Ehler's Danlos connective disorders. Keratoconus diagnosis can be achieved thorough slit lamp examination and observation of central or inferior corneal thinning, and also with corneal topography. Some early signs [2, 3] of keratoconus are asymmetric

refractive error with high or progressive astigmatism, keratometry showing high astigmatism and irregularity, scissoring of the red reflex on retinoscopy, and inferior steepening. The vast majority of keratoconus patients can be visually rehabilitated with glasses or rigid gas permeable lenses [4] (RGPs). In only a small percentage of keratoconus patients is a cornea transplant needed. The use of RGP contact lenses cannot stop the progression of the disease. However, some patients have contact lens intolerance [5] and their best spectacle corrected visual acuity with glasses is not sufficient for giving them a good quality of life.

### CORRESPONDING AUTHOR:

Ioannis A. Mallias, MD, PhD, Mediterraneo Hospital, Glyfada, 3 Kallipoleos Street, Nea Smyrni, 17123, Athens, Greece, tel.: 00302109320215, e-mail: johnmallias@yahoo.com

More than 10 years ago corneal collagen crosslinking (riboflavin and ultraviolet light) was proposed as a therapeutic approach [6] by Dr. Seiler and his team to improve the biochemical and biomechanical properties of the cornea. There is clinical evidence<sup>6</sup> that corneal crosslinking is a useful procedure that stops the progression of keratoconus. As a positive side effect some treated eyes presented a significant flattening [7] of the cornea (in rare cases the regression was more than 10 dioptres), which resulted in visual acuity improvement. In our study we analyse the one-year results of transepithelial topography-guided partial PRK combined with corneal collagen crosslinking (CXL) in order to identify the visual outcome and possible complications of this procedure.

## MATERIALS AND METHODS

Twenty patients (20 eyes) were included in the study. All participants were diagnosed with grade 3 keratoconus or above. Preoperatively patients received a complete ocular examination by Dr. Mallias, including best spectacle corrected visual acuity, subjective refraction, and slit lamp examination for clinical signs of keratoconus. They were also monitored with Scheimpflug-generated corneal topography (Pentacam HR, Oculus, Germany). Inclusion criteria were definite findings of consistent keratoconus, verified with consecutive topographies. Exclusion criteria were previous corneal surgery, history of chemical injury, delayed epithelial healing, systemic or other ocular diseases, pregnancy, lactation, and the use of oral oestrogen. All patients participating in this study had preoperative corneal thickness above 400  $\mu\text{m}$ . All surgeries were performed by Dr. Mallias, using an Excimer Laser Amaris 750s (Schwind, Germany) and KXL System (Avedro, USA). Patients were thoroughly screened 1, 6, and 12 months postoperatively. In every follow-up visit all patients underwent slit lamp examination, best spectacle corrected visual acuity (BSCVA) measurement, intraocular pressure measurement, and corneal topography with Pentacam HR. Patients using RGPs were asked to stop the usage of their contact lenses for at least three weeks before the operation and at least one month postoperatively. Prior to the operation, all surgical risks were explained to patients and informed consent was signed by all of them.

## SURGICAL TECHNIQUE

The first step of the procedure was a partial transepithelial topography-guided PRK performed by Amaris 750s and followed by CXL procedure. The maximum tissue ablation was limited to 50 microns of corneal stroma. Riboflavin (Vibex Rapid, 0.1% Riboflavin, Saline, HPMC, Avedro, USA) was instilled onto the cornea every two minutes for 10 minutes and then rinsed thoroughly. Then UVA was applied with the on-off module (UVA is on for one second and off for another second in order to avoid depletion of oxygen) for eight minutes, and the power was 30 mW/cm<sup>2</sup>.

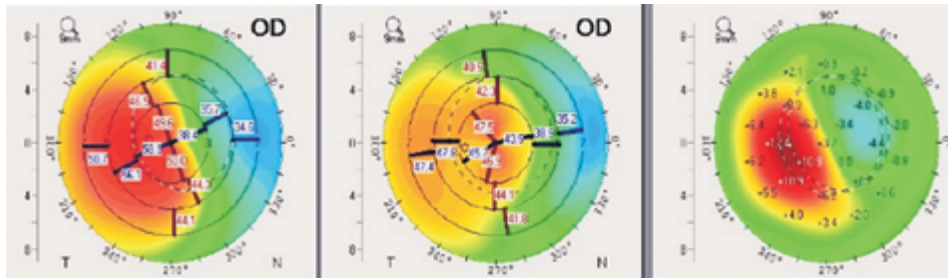
At the end of the operation a bandage soft contact lens was applied until re-epithelisation was achieved (approximately four days postop). Patients received ofloxacin four times daily, dexamethasone four times daily, and preservative-free artificial tears every two hours. After complete healing of the corneal epithelium, the bandage contact lens was removed and patients were given preservative-free artificial tears and Loteprednol drops three times daily slowly tapered over a period of one month.

## RESULTS

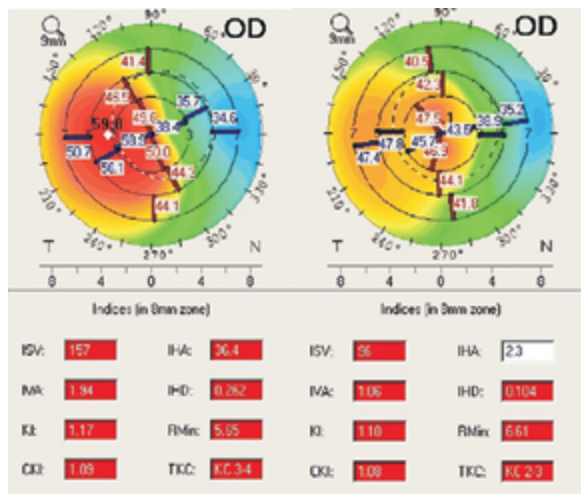
From the 20 patients (20 eyes) 13 were female and 7 were male. The mean age of the patients was  $26.4 \pm 4$  years. Their mean preoperative BSCVA was 20/100, and mean postoperative BSCVA at the end of the one-year follow-up period was 20/25. The preoperative mean flat K was  $46.8 \pm 0.14$  D, and it was reduced to  $45.2 \pm 0.7$  D. The preoperative mean steep K showed significant reduction from  $50.2 \pm 0.10$  D to  $47 \pm 0.6$  D. The total corneal astigmatism was  $4.5 \pm 0.14$  D preoperatively and  $2.5 \pm 0.10$  D postoperatively. The average thinnest pachymetry was reduced from  $465 \pm 9.9$   $\mu\text{m}$  to  $416 \pm 11.3$   $\mu\text{m}$  postoperatively. Total RMS (corneal aberrations) was  $15.5 \pm 7.4$   $\mu\text{m}$  and was significantly reduced to  $5.5 \pm 2$   $\mu\text{m}$ . We believe that this reduction is very important because it improves the image quality of the patient (Fig. 1).

There were no complications after the operation in any of the patients besides some mild haze, which was not visually significant and was managed with prolonged use of steroid drops (Fig. 2).

As can be seen in Image 1 and 2, the flattening of the cornea after transepithelial topography-guided partial PRK combined with corneal collagen crosslinking is obvious and the keratoconic indices are much lower.



**FIGURE 1.** Preoperative and postoperative topography of a patient who underwent topography-guided partial PRK combined with corneal collagen crosslinking, and a comparison of them



**FIGURE 2.** Same patient as in Figure 1 pre- and postoperative topometric indices showing great improvement of corneal irregularity

## DISCUSSION

As shown above, transepithelial topography-guided partial PRK combined with corneal collagen crosslinking can be a good option that offers cornea stabilisation as well as BSCVA improvement in patients who satisfy the criteria to proceed in such a surgery. Patients included in this study were classified as grade 3 keratoconus or above and their visual acuity was below 20/40. The reason is that if keratoconus is not that advanced or BSCVA is better, there is no need to proceed in a combined surgery since CXL standalone has shown corneal stabilisation and, as mentioned before, in some cases even corneal flattening. What should be mentioned is that the maximum ablation in this procedure is low, because its goal is not to eliminate refractive error but to “normalise” the cornea as much as possible. Also the on-off technique in corneal collagen crosslinking was employed to avoid the depletion of oxygen, which is needed for the creation of cross links in corneal collagen fibres.

There are other studies [8, 9] also dealing with excimer laser ablation combined with collagen crosslinking in keratoconic and ectatic eyes. In some studies the minimum corneal thickness was less than 400  $\mu\text{m}$ . We believe that if the preoperative central corneal thickness (CCT) is below 400  $\mu\text{m}$ , there is a possibility of toxicity in endothelial cells. Patients with advanced keratoconus and very thin corneas (CCT < 350  $\mu\text{m}$ ) are not good candidates for such the procedure described in this paper. We believe that these patients should proceed with a corneal transplant for better visual results. The main goal of such a combined procedure is to stabilise the cornea as well as to improve the BSCVA for patients who have contact lens intolerance due to allergic conjunctivitis [10], to avoid corneal transplant. Nevertheless, a study should be conducted to compare CXL standalone results with those undergoing a combined surgery, in order to determine whether or not CXL standalone can provide efficient corneal flattening.

As can be seen in Figure 3, in order to normalise the corneal surface, a mild ablation occurs on the cone and there is ablation of corneal tissue at the periphery of the cornea. Any ablation at the corneal periphery is a hyperopic ablation, and this explains our finding that there was a slight increase in myopia in all of these patients. This is the “price” that patients had to pay, in order to achieve regularisation of the anterior corneal surface and improvement of BSCVA.

We observed a significant reduction of RMS (corneal aberrations) calculated by Pentacam HR, postoperatively. Such a reduction as shown in the results above, indicates not only that BSCVA was improved, but aberrations naturally existing in keratoconic corneas were reduced, resulting in improvement in the quality of the image as well. To our knowledge, this is the first paper discussing RMS

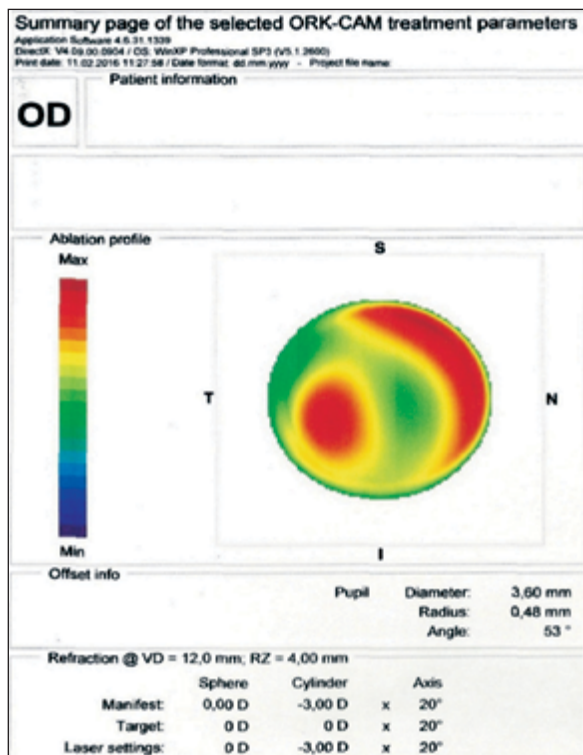


FIGURE 3. Ablation profile

(corneal aberrations) in keratoconus eyes before after excimer laser ablation combined with CXL.

We know that due to CXL there is apoptosis [11] of keratocytes from the anterior stroma. Because of the apoptosis, keratocytes do not produce the extracellular substance that is responsible for the development of corneal haze. This is the main reason we did not use mitomycin C in transepithelial topography-guided partial PRK combined with corneal collagen crosslinking cases, even if some similar studies [12] widely use it in order to avoid haze.

Another reason not to use mitomycin if it is not really necessary is the possible complications caused by its use [13]. What should be noted is that a large study should be conducted in order to investigate whether or not the use of Mitomycin reduces the possibility of haze appearance in such combined procedures with corneal crosslinking.

## REFERENCES

1. Rabinowitz YS. Keratoconus. *Surv Ophthalmol* 1998; 42: 297–319.
2. <http://eyewiki.aao.org/Keratoconus>.
3. <https://www.nkcf.org/keratoconus-symptoms-and-diagnosis/>.
4. Wu Y, Tan Q, Zhang W et al. Rigid gas-permeable contact lens related life quality in keratoconic patients with different grades of severity. *Clin Exp Optom* 2015; 98: 150–154. doi: 10.1111/cxo.12237.
5. Dana MR, Putz JL, Viana MA, Sugar J, McMahon TT. Contact lens failure in keratoconus management. *Ophthalmology* 1992; 99: 1187–1192.
6. Wollensak G, Spoerl E, Seiler T. Riboflavin/ultraviolet-a-induced collagen crosslinking for the treatment of keratoconus. *Am J Ophthalmol* 2003; 135: 620–627.
7. Koller T, Pajic B, Vinciguerra P, Seiler T. Flattening of the cornea after collagen crosslinking for keratoconus. *J Cataract Refract Surg* 2011; 37: 1488–1492. doi: 10.1016/j.jcrs.2011.03.041.
8. Kanellopoulos AJ, Asimellis G. Corneal refractive power and symmetry changes following normalization of ectasias treated with partial topography-guided PTK combined with higher-fluence CXL (the Athens Protocol). *J Refract Surg* 2014; 30: 342–346. doi: 10.3928/1081597X-20140416-03.
9. Kanellopoulos AJ, Asimellis G. Epithelial remodeling after partial topography-guided normalization and high-fluence short-duration crosslinking (Athens protocol): results up to 1 year. *J Cataract Refract Surg* 2014; 40: 1597–1602. doi: 10.1016/j.jcrs.2014.02.036.
10. Merdler I, Hassidim A, Sorkin N, Shapira S, Gronovich Y, Korach Z. Keratoconus and allergic diseases among Israeli adolescents between 2005 and 2013. *Cornea* 2015; 34: 525–529. doi: 10.1097/ICO.0000000000000416.
11. Song X, Stachon T, Wang J, Langenbucher A, Seitz B, Szentmáry N. Viability, apoptosis, proliferation, activation, and cytokine secretion of human keratoconus keratocytes after cross-linking. *Biomed Res Int* 2015; 2015: 254237. doi: 10.1155/2015/254237.
12. Kanellopoulos AJ. The management of cornea blindness from severe corneal scarring, with the Athens Protocol (transepithelial topography-guided PRK therapeutic remodeling, combined with same-day, collagen cross-linking). *Clin Ophthalmol* 2012; 6: 87–90. doi: 10.2147/OPHT.S27175.
13. <https://www.reviewofophthalmology.com/article/the-dangers-of-using-mitomycin-c>.