

Topography changes and endothelial cell loss after temporal 1.8 mm coaxial microincision cataract surgery (MICS)

Ioannis A. Mallias, Anastasia Tasiopoulou

Mediterraneo Hospital, Glyfada, Athens, Greece

ABSTRACT

INTRODUCTION. The purpose of this paper was to determine surgically-induced changes both in corneal topographic parameters and in endothelial cell loss after coaxial microincision cataract surgery (MICS) through temporal 1.8 mm incision.

MATERIALS AND METHODS. Evaluation was performed in forty eyes of thirty patients who underwent cataract surgery. Topographic parameters including corneal astigmatism, surface regularity index (SRI), and surface asymmetry index (SAI) were estimated preoperatively and at one week, four weeks, and eight weeks after surgery. A specular microscope was also used for the measurement of the corneal endothelial density (cells/mm²). The surgically-induced astigmatism (SIA) was calculated by means of vector analysis using Alpins' method.

RESULTS. Eight weeks after surgery the final mean value of SIA was 0.42 D and the differences in topographic parameters such as corneal astigmatism, SRI, and SAI were not statistically significant. Also, the decrease in endothelial cell density eight weeks after surgery was 6.02%.

CONCLUSIONS. The changes in SIA and topographic parameters after temporal coaxial 1.8 mm MICS are minimal throughout an eight-week follow up period.

KEY WORDS: corneal topography parameters, endothelial cell loss, coaxial microincision cataract surgery (MICS)

Ophthalmol J 2016; Vol. 1, No. 2, 41–45

INTRODUCTION

In recent years, the most popular surgical procedure for cataract extraction has been phacoemulsification. This procedure has, from its inception in the late 1960s, evolved in lock step with advances in technology.

The fundamental goal of phacoemulsification is to remove a cataract with minimum disturbance to the eye and to achieve fast recovery of visual function.

Surgically-induced astigmatism (SIA) is among the most important factors affecting visual rehabilitation after cataract surgery. Thus, many technological advances have evolved to minimise SIA, through modifications of parameters such as the incision size and wound shape as well as the location and angular position of the incision [1, 2].

Several studies have demonstrated that minimising the incision size may decrease SIA and improve wound strength and integrity [3, 4].

Currently, cataract extraction known as microincision cataract surgery (MICS) through sub-2.0 mm incision is widely performed. There are two types of MICS: bimanual and coaxial. Although the former induces slight SIA and corneal aberrations, it involves possible wound enlargement and difficulty in learning. Whereas, the latter is performed without wound enlargement, since the advent of a foldable hydrophilic intraocular lens (IOL) that can be implanted through an incision as small as 1.8 mm. Also, coaxial MICS is similar to conventional cataract procedure, and thus the learning curve is much easier [5].

CORRESPONDING AUTHOR:

Anastasia Tasiopoulou M.D., Mediterraneo Hospital, 101 Rodou Street, Petroupolis, 13231, Athens, Greece, tel.: 00306942687669, e-mail: an.tasiopoulou16@gmail.com

As far as the site of incision is concerned, some authors have reported that temporal clear corneal incisions cause relatively small changes to corneal astigmatism compared to superior and superolateral ones [6–9].

The aim of this study is to follow-up patients undergoing coaxial MICS through temporal 1.8 mm incision and to evaluate the early postoperative changes in corneal topography and endothelial cell count.

MATERIALS AND METHODS

Forty eyes of thirty different patients with age-related cataract, who underwent unilateral or bilateral phacoemulsification and monofocal IOL implantation were evaluated.

All clinical examinations and surgeries were conducted at the Ophthalmology Clinic of Mediteraneo Hospital (Athens, Greece) between December 3, 2010 and December 29, 2012.

Exclusion criteria included pathologies of the cornea, vitreous body, optic nerve, and macula; glaucoma; history of ocular operation and ocular injury; history of uveitis; contact lens wear; diabetes mellitus; patient refusal, difficulty in cooperation, or participation in another study. Moreover, patients with corneal astigmatism greater than 1.00 D were excluded from the study due to implantation of toric IOL and enlargement of the incision.

All patients underwent clinical examinations within three days before surgery as well as one, four, and eight weeks after surgery.

Clinical examinations performed preoperatively and at each postoperative follow-up included uncorrected visual acuity (UCVA) and best corrected visual acuity (BCVA), refraction, intraocular pressure, slit lamp biomicroscopy of anterior and posterior segment, corneal topography, and measurement of corneal endothelial cell density. Biometry and IOL calculation were also included in the preoperative evaluation. UCVA and BCVA were measured using the Snellen chart and converted to the logMAR scale. The refractive parameters were measured using an autorefractometer (KR-7100, Topcon), and then the manifest spherical equivalent was determined. All patients had corneal topography using the videokeratoscope Topographic Modelling System 2 (TMS-2). A specular microscope (EM -3000, Tomey) was used for the measurement of the corneal endothelial density (cells/mm²).

Statistical analysis was performed using Statistical Package for Social Science (SPSS) software. The Wilcoxon matched-pairs ranks test was used for statistical comparisons between preoperative and postoperative values. The surgically induced astigmatism (SIA) was cal-

culated by means of vector analysis using Alpins' method [10, 11].

SURGICAL TECHNIQUE

All operations were performed by the same surgeon (Dr Ioannis A. Mallias). Prior to the operation, informed consent was signed by all the patients after explanation of the nature and possible risks of the surgery, and the study was approved by the Hospital's Institutional Review Board.

The surgeries were performed under topical or peribulbar anaesthesia. The surgeon was always seated on the temporal side of the patients. For right eyes the incision was located at the 9-o'clock area and for left eyes at the 3-o'clock area. The 1.8-mm clear corneal incision was made using a 1.8-mm stainless keratome. The length of the incision was 1.5 mm from the margin of the cornea in order to make an almost square incision. A continuous curvilinear capsulorrhexis was performed under viscoelastic (Amvisc Plus Viscoelastic, Bausch and Lomb). After hydrodissection and hydrodelineation, phacoemulsification of the nucleus through stop and chop technique was conducted using a Stellaris Attune ultrasonic handpiece (Bausch and Lomb). Cortical remnants were removed by irrigation (I) and aspiration (A) through an I/A handpiece shaft tip with sleeve for 1.8-mm incision (Stellaris, MICS, Bausch and Lomb). Without enlarging the incision, a foldable intraocular lens (Akreos MI-60, Bausch and Lomb) was implanted in the capsular bag. At the conclusion of the surgery, the length of the wound was measured with an inner gauge (ASICO). Subsequently, the wound was closed by corneal stromal hydration. Postoperatively, patients received both antibiotic (ofloxacin 0.3%) and steroid drops (dexamethasone 0.1%) four times daily for one week. Steroid drops were gradually tapered over a period of four weeks. Also nepafenac three times daily for one month was included in the treatment.

RESULTS

The total of 30 patients (12 men and 18 women) who were assigned to this study were between 64 and 83 years of age (mean age: 73 years \pm 5.45). Twenty patients underwent unilateral cataract surgery and the rest of them had cataract surgery on both eyes consecutively. As well as their age, other patients' demographics and surgical data such as surgical time and total ultrasound (US) energy are shown in Table 1. All operations were uneventful and no suture was required in any case.

Preoperatively, the patients had a mean logMAR UCVA of 0.723 (range: 0.161–1.602), logMAR BCVA of 0.597 (range: 0.042–1.602) and corneal endothe-

lial density of 2504.7 ± 211 cells/mm². In the eight weeks after the cataract surgery the mean values of UCVA, BCVA, and corneal endothelial density were 0.206 (range: 0.042–1.00), 0.152 (range: 0–1.00), and 2353.9 ± 283.4 , respectively (Tab. 2). As seen in this table, both UCVA and BCVA were significantly improved in eight weeks' time after surgery. Compared with the preoperative value, the mean endothelial density decreased significantly at one week and then stabilised at four and eight weeks after surgery. The endothelial cell losses occurring one week, four weeks, and eight weeks after operation were 4.83%, 5.74%, and 6.02%, respectively (Fig. 1).

Table 1. Basic profile of the patients	
Age (years)	73 ± 5.45*
Eye (right/left)	17/23
Mean surgical time [minutes]	8.5 ± 1.7*
Mean total US energy [mJ]	29.5 ± 3*

*Mean value ± standard deviation (SD)

The values of topographic parameters including corneal astigmatism, surface regularity index (SRI), and surface asymmetry index (SAI) both preoperatively and postoperatively are shown in Table 3. The preoperative and eight-week

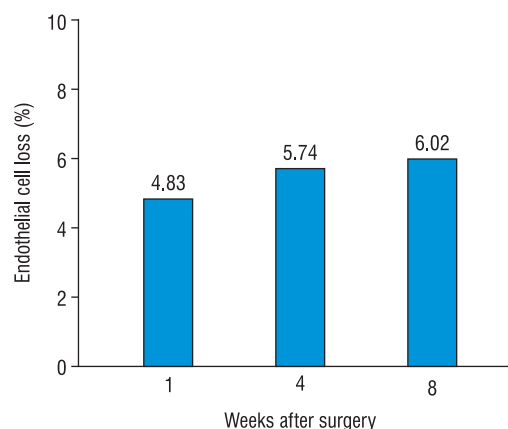


FIGURE 1. The endothelial cell losses occurring 1 week, 4 weeks, and 8 weeks after surgery. The mean endothelial density decreased significantly at 1 week and then stabilised at 4 and 8 weeks after surgery

Table 2. The mean UCVA, BCVA, and corneal endothelial density preoperatively and at 1, 4 and 8 weeks after surgery				
	Preoperatively	1 week postoperatively	4 weeks postoperatively	8 weeks postoperatively
logMAR UCVA (D)	0.723* Range:0.161–1.602	0.323* Range: 0.042–1.301 p < 0.01***	0.258* Range: 0.042–1.301 p < 0.01***	0.206* Range: 0.042–1.00 p < 0.01***
logMAR BCVA (D)	0.597* Range:0.042–1.602	0.254* Range:0–1.00 p < 0.01***	0.158* Range:0–1.00 p < 0.01***	0.152* Range:0–1.00 p < 0.01***
Corneal endothelial density [cells/mm ²]	2504.7 ± 211**	2383.7 ± 234.5** p < 0.01***	2360.9 ± 262** p < 0.01***	2353.9 ± 283.4** p < 0.01***

*Mean value, **Mean value ± SD, ***Wilcoxon matched-pairs ranks test between preoperative and postoperative values; statistically significant difference ($p < 0.05$)

logMAR — logarithm of the minimum angle of resolution (logMAR 0 = 20/20, logMAR 0.042 = 20/22, logMAR 0.161 = 20/29, logMAR 1.00 = 20/200, logMAR 1.301 = 20/400, logMAR 1.602 = 20/800); UCVA — uncorrected visual acuity; BCVA — best corrected visual acuity

Table 3. Mean value of topographic parameters preoperatively and at 1, 4, and 8 weeks postoperatively				
	Preoperatively	1 week postoperatively	4 weeks postoperatively	8 weeks postoperatively
Corneal Astigmatism (D)	0.72 ± 0.48*	0.79 ± 0.53* p > 0.05 (NS)**	0.74 ± 0.41* p > 0.05 (NS)**	0.71 ± 0.37* p > 0.05 (NS)**
SRI	0.78 ± 0.32*	0.89 ± 0.45* p > 0.05 (NS)**	0.83 ± 0.38* p > 0.05 (NS)**	0.72 ± 0.33* p > 0.05 (NS)**
SAI	0.30 ± 0.36*	0.45 ± 0.37* p > 0.05 (NS)**	0.42 ± 0.32* p > 0.05 (NS)**	0.37 ± 0.34* p > 0.05 (NS)**

* Mean value ± SD; ** Wilcoxon matched-pairs ranks test between preoperative and postoperative values; statistically significant difference ($p < 0.05$)

SRI — surface regularity index; SAI — surface asymmetry index; NS — not significant

Table 4. Mean value of SIA and SIA axis at 1, 4, and 8 weeks postoperatively			
	1 week postoperatively	4 weeks postoperatively	8 weeks postoperatively
SIA (D)	0.48 ± 0.21*	0.43 ± 0.24* p > 0.05 (NS)**	0.42 ± 0.20* p > 0.05 (NS)**
SIA axis	87.2 ± 30.9*	85.4 ± 29.5* p > 0.05 (NS)**	82.5 ± 27.4* p > 0.05 (NS)**

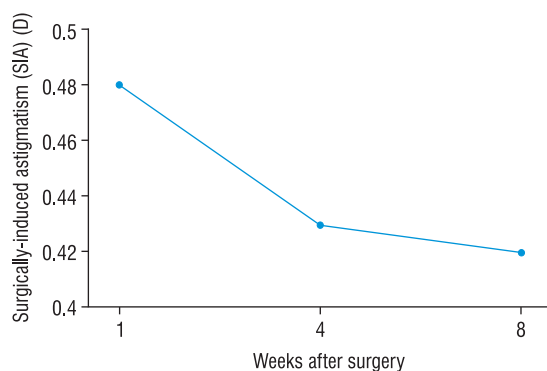


FIGURE 2. Comparison of the mean value of SIA at 1 week, 4 weeks, and 8 weeks after operation. The mean SIA at 1 week was 0.48 D and then it reduced at 4 and 8 weeks. However, the differences in the mean value of SIA throughout the whole follow-up period were not statistically significant. 8-week post-operative follow-up after temporal 1.8 mm coaxial MICS demonstrated minimal changes in topographic parameters (corneal astigmatism, SRI, and SAI), SIA of 0.42 D, and endothelial cell loss of 6.02%

postoperative corneal astigmatism were almost identical (Preoperative and eight-week-postoperative value: 0.72 ± 0.48 D and 0.71 ± 0.37 D, respectively). This was also indicated by corneal topography. Also, as seen in Table 3, there was no significant difference in mean values of SRI and SAI before the surgery and during the follow-up period (Preoperative mean value of SRI: 0.78 ± 0.32 and of SAI: 0.30 ± 0.36 , eight-week-postoperative mean value of SRI: 0.72 ± 0.33 and of SAI: 0.37 ± 0.34).

For mean surgically induced astigmatism (SIA) calculated using Alpins' method, the mean value at the first week was 0.48 ± 0.21 D (Tab. 4). Then it was reduced and stabilised after the fourth week (Fig. 2). It is worth mentioning that the differences in the mean value of SIA throughout the follow-up period were not statistically significant and the final SIA at eight weeks was < 0.50 D for all eyes. The mean SIA axis, which is also shown in Table 4, decreased gradually but not significantly during the follow-up period.

Evaluating the average corneal difference maps, the most pronounced changes in corneal shape one week after operation were a focal flattening of two clock hours

corresponding to the main incision (at the nine o'clock meridian on right eyes or at the three o'clock meridian on left ones), a slight peripheral flattening (< one clock hour) corresponding to the side port (at the two o'clock meridian on right eyes or at the 10 o'clock meridian on left ones) and a small steepening around the flattened areas. These corneal topographic changes were reduced gradually by four weeks after surgery and only a slight main incision-related flattening area was demonstrated by eight weeks.

DISCUSSION

The main objective of our study was to evaluate the induced astigmatism after coaxial MICS through a temporal 1.8-mm incision at one, four, and eight weeks after surgery. The mean SIA at the first week was 0.48 D reduced to 0.42 D eight weeks after surgery. This result is compatible with those reported by Hayashi et al. [12] after 2.0-mm coaxial MICS. In this study they found SIA of 0.56 D two months after surgery. Whereas, Alió et al. reported significantly lower SIA of 0.37 D three months after 1.5-mm biaxial MICS [13].

As far as corneal topography is concerned, eight weeks after surgery we found no statistically significant change in parameters such as corneal astigmatism, SRI, and SAI. This is also consistent with changes in corneal topographic maps, where there was a gradual reduction in incision-related flattening and, around the incision, steepening throughout the whole follow-up period. This rapid rate of recovery is due to the small size of the incision and its temporal location. The association of the temporal incision with lower SIA is highlighted by Barequet et al., who reported that 12-month SIA for temporal 3.5-mm incision was 0.71 D compared to 1.41 D for a nasal one [9]. The SIA found in our study is even lower than the one reported by Barequet et al. because the incision was both temporal and just 1.8 mm.

The advantage of temporal incision is also demonstrated by the comparison between the results of our study and the ones reported by Yao et al. [14]. They found mean SIA of 0.47 D in one month after 1.8-mm

coaxial MICS, while we found mean SIA of 0.43 D four weeks after surgery. The main reason for this slight difference is the temporal location of the incision in our study.

In addition, we reported that the endothelial cell density decreased by 6.02% eight weeks after surgery, and these results are compatible with those presented by Kahraman et al. They reported 6.2% endothelial cell loss after 2.0-mm and 1.4-mm MICS [15]. Whereas, Hayashi et al reported 8.88% endothelial cell loss eight weeks after 2.0-mm MICS [12]. Both of these studies demonstrated that, although the endothelial cell loss in the MICS group was lower than in the SICS group, the difference between the two groups was not significant [12, 15].

However, no other study has estimated the changes in topographic parameters (corneal astigmatism, SRI, and SAI) and corneal endothelial density along with SIA after temporal 1.8-mm coaxial MICS.

It is also worth mentioning that the postoperative inflammation in all our patients as well as the discomfort reported by them was minimal. This is due to the high wound integrity of 1.8-mm MICS, which results in a better self-sealing incision and thus in a lower possibility of postoperative endophthalmitis.

Furthermore, the lower SIA results in rapid stabilisation of refraction after surgery. So the doctor is enabled to prescribe spectacles for far and/or near vision in a short postoperative time.

In conclusion, temporal coaxial 1.8-mm MICS induces less change in corneal shape and ensures a higher wound integrity and thus a higher rate of postoperative safety. Surgeons who adopt temporal 1.8-mm MICS will not face much difficulty learning the technique and in the near future, newer technology will enable them to have better postoperative results.

REFERENCES

1. Nielsen PJ. Prospective evaluation of surgically induced astigmatism and astigmatic keratotomy effects of various self-sealing small incisions. *J Cataract Refract Surg* 1995; 21: 43–48.
2. Kohnen T, Dick B, Jacobi KW. Comparison of the induced astigmatism after temporal clear corneal tunnel incisions of different sizes. *J Cataract Refract Surg* 1995; 21: 417–424.
3. Wei YH, Chen WL, Su PY, Shen EP, Hu FR. The influence of corneal wound size on surgically induced corneal astigmatism after phacoemulsification. *J Formos Med Assoc* 2012; 111: 284–289.
4. Oshika T, Nagahara K, Yaguchi S et al. Three year prospective, randomized evaluation of intraocular lens implantation through 3.2 and 5.5 mm incisions. *J Cataract Refract Surg* 1998; 24: 509–514.
5. Hayashi K, Yoshida M, Hayashi H. Postoperative corneal shape changes: microincision versus small-incision coaxial cataract surgery. *J Cataract Refract Surg* 2009; 35: 233–239.
6. Tejedor J, Murube J. Choosing the location of corneal incision based on preexisting astigmatism in phacoemulsification. *Am J Ophthalmol* 2005; 139: 767–776.
7. Rainer G, Menapace R, Vass C et al. Corneal shape changes after temporal and superolateral 3.0 mm clear corneal incisions. *J Cataract Refract Surg* 1999; 25: 1121–1126.
8. Masket S, Tennen DG. Astigmatic stabilization of 3.0 mm temporal clear corneal cataract incisions. *J Cataract Refract Surg* 1996; 22: 1451–1455.
9. Barequet IS, Yu E, Vitale S, Cassard S, Azar DT, Stark WJ. Astigmatism outcomes of horizontal temporal versus nasal clear corneal incision cataract surgery. *J Cataract Refract Surg* 2004; 30: 418–423.
10. Alpíns NA. A new method of analyzing vectors for changes in astigmatism. *J Cataract Refract Surg* 1993; 19: 524–533.
11. Alpíns NA, Goggin M. Practical astigmatism analysis for refractive outcomes in cataract and refractive surgery. *Surv Ophthalmol* 2004; 49: 109–122.
12. Hayashi K, Yoshida M, Hayashi H. Postoperative corneal shape changes: Microincision versus small-incision coaxial cataract surgery. *J Cataract Refract Surg* 2009; 35: 233–239.
13. Alió J, Rodríguez-Prats JL, Galal A, Ramzy M. Outcomes of microincision cataract surgery versus coaxial phacoemulsification. *Ophthalmology* 2005; 112: 1997–2003.
14. Yao K, Wang W, Wu W, Tang XJ, Li ZC, Jin CF. Clinical evaluation on the coaxial 1.8 mm microincision cataract surgery. *Zhonghua Yan Ke Za Zhi* 2011; 47: 903–907.
15. Kahraman G, Amon M, Franz C, Prinz A, Abela-Formanek C. Intraindividual comparison of surgical trauma after bimanual microincision and conventional small-incision coaxial phacoemulsification. *J Cataract Refract Surg* 2007; 33: 618–622.

