

Sentinel lymph node biopsies in patients with malignant melanoma — qualifying principles and histopathological assessment (2017)

Anna Nasierowska-Guttmejer^{1,2}, Wojciech Biernat³, Piotr Wiśniewski⁴, Radziław Kordek⁵,
Wojciech M. Wysocki⁶, Arkadiusz Jeziorski⁷, Marcin Zdzienicki⁸, Piotr Rutkowski⁸

In 1999, the World Health Organisation (WHO) stated that sentinel lymph node biopsy should be the standard of management for those patients with melanomas without clinical signs of metastases to the regional lymph nodes. This procedure should include preoperative and intraoperative lymphoscintigraphy, combined with staining. Sentinel lymph node biopsies should be performed after excision biopsy of the melanoma and simultaneously with radical excision of the remaining scar after melanoma excision biopsy. Whenever sentinel lymph node(s) are found tumour occupied, metastases are most likely to be located in one or more lymph nodes that were first occupied along lymphatic drainage from the primary focal point of the cancer. Detecting even single melanoma cells in the sentinel lymph node is usually used to determine the stage of the disseminating cancer and radically changes prognoses and further therapeutic decisions. Guidelines on lymph nodes examined during melanoma have been established by the College of American Pathologists (CAP), the European Society of Pathology (ESP) and the Polish Society of Pathologists in 2013. If melanoma metastases are found in sentinel lymph node(s) then:

- the number of lymph nodes should be specified as well as the number of those with metastases;
- microscopic features of sentinel lymph node(s) metastases should be defined as follows: the largest metastasis/ /metastases size, their location (subcapsular, intraparenchymal, mixed or extended), signs of possible infiltration and crossing the node capsule, penetration into adipose tissue and vasculature involvement.

NOWOTWORY J Oncol 2017; 67, 1: 41–47

Key words: melanoma, sentinel lymph node, examination of sentinel lymph nodes

Epidemiology

In Poland, according to the 2013 data of the National Cancer Registry, 3027 new cases of skin melanoma were reported; 1414 males and 1613 females. The disease caused 1400 deaths; 739 males and 661 females [1]. In the USA, 73 870 new cases of this malignancy were diagnosed in 2015

and 9940 patients died [2]. In Poland, melanoma is a tumour whose incidence is very rapidly increasing.

Pathological-clinical factors

Skin melanoma is a malignant tumour arising from the uncontrolled proliferation of cells termed melanocytes,

¹Pathology Department, Central Teaching Hospital, Ministry of Internal Affairs in Warszawa, Poland

²Faculty of Medicine and Health Sciences, Jan Kochanowski University in Kielce, Poland

³Chair of Pathology, Medical University in Gdańsk, Poland

⁴Department of Pathology and Laboratory Diagnostics, Centre of Oncology — Maria Skłodowska-Curie Institute in Warszawa, Poland

⁵Medical University in Łódź, Poland

⁶Department of Surgical Oncology, Centre of Oncology — Maria Skłodowska-Curie Institute in Kraków, Poland

⁷Department of Surgical Oncology, Medical University in Łódź, 2nd Department of Surgical Oncology,

N. Copernicus Province Multidisciplinary Centre of Oncology and Traumatology in Łódź, Poland

⁸Department of Soft Tissue and Bone Tumours and Melanomas, Centre of Oncology — Maria Skłodowska-Curie Institute in Warszawa, Poland

located in the epidermis. The tumour most frequently develops from a primary transformation of those cells which settle the epidermis. At the preinvasive stage, melanocytes proliferate which is characteristic of the *in situ* phase of radial growth. At the invasive stage, they penetrate into the skin forming a vertical phase (nodule). Infiltration of the stroma is associated with the risk of dissemination via the lymphatic or blood vessels. Hyperplasia in the skin lymphatic vessels may cause satellite *foci* to develop (*in-transit* metastases), and their transfer to lymph nodes; metastatic lymphadenopathy. Important prognostic factors associated with primary tumour features (pT features) include [3, 4, 8]:

- infiltration thickness in mm (according to Breslov);
- ulceration of significant prognostic value in cases without metastases. The presence of ulceration in invasive melanomas elevates the pT progression stage from pT1'a' to the pT1'b' substage.

The number of mitotic figures counted only in the vertical plane, (the radial plane not being taken into account), in hot spots [3–6] is a prognostic factor but has no effect on the pT feature according to the TNM classification of 2017 [8].

The extent of invasion according to Clark's classification is however of lower prognostic importance [6–8]. Apart from the aforementioned prognostic parameters of primary melanoma and micrometastases, (in the current TNM classification revision of 2017 called 'clinically occult metastases'), to sentinel lymph nodes, particularly at the pT1 stage, then they are of prognostic value, especially in medium-thickness melanomas without clinically detectable metastases [8].

Clinical and pathological procedures

Total excision of a primary tumour, along with a margin of surrounding tissues is the optimal recommended surgical procedure making it possible to establish a pathological diagnosis of melanoma as well as assessing prognostic factors. The shave technique or punch biopsy of a tumour fragment are not recommended, as both methods preclude any assessment of tissues at the tumour margin or of detecting microsatellite *foci*. Pathological assessment of a full lesion cross-section is recommended. There are however no indications for examining frozen preparations, both from the primary lesion and the sentinel lymph node, because assessing such material by these means can reduce the sensitivity of the examination thereby rendering detection of single metastatic cells impossible [7, 10].

The clinical procedure used for invasive melanomas without clinically detectable metastases upon gross examination consists of excising the primary lesion with a margin of surrounding tissues together with a possibly following-on sentinel lymph node (SLN) biopsy. According to patholo-

gical indications, the examination should be performed following the standard procedure after fixing the tissue material in buffered 10% formalin solution, processing it to paraffin blocks and routinely staining the preparations with haematoxylin and eosin with possible application of immunophenotyping [4, 5, 11].

Patients are qualified for sentinel lymph node biopsy without clinical signs of metastases to regional lymph nodes and distant organs and by the following [10–13]:

- after an excision biopsy where diagnosis of skin melanoma is confirmed by histopathological examination, but not after extensive excision of the primary focus;
- with a Breslow infiltration thickness ≥ 1.0 mm;
- with (micro)ulceration on the melanoma surface regardless of infiltration thickness or mitotic index $\geq 1/\text{mm}^2$ [melanoma, with the primary focus being classified as in the pT1b-T4b category according to the TNM UICC/AJCC 2010 classification]. According to the data from the American Society of Surgical Oncology (SSO), American Society of Clinical Oncology (ASCO) [14, 15] and European Society for Medical Oncology (ESMO) [16], sentinel lymph node biopsy can be abandoned in pT1b melanomas of thickness up to 0.75 mm (however it should still be considered when finding an ulceration of the primary lesion) (Tab. I);
- without clinical signs of metastases to regional lymph nodes and distant organs.

Sentinel lymph node biopsy is currently an indispensable method for assessing clinically occult metastases (earlier termed micrometastases) in lymph nodes [13–18]. In 1999, the WHO stated that sentinel lymph node biopsy should be the standard management in those patients with skin melanomas without clinical signs of metastases to the regional lymph nodes. For these biopsies, preoperative lymphoscintigraphy and intraoperative lymphoscintigraphy combined with staining should be performed. Sentinel lymph node biopsy should be undertaken after excision biopsy of the melanoma, simultaneously with radical excision of the remaining scar after the melanoma excision biopsy. Available data do not suggest any adverse effects on the prognosis following sentinel lymph node biopsy performed six weeks after the primary focus excision. The method's accuracy relies on the collaboration between nuclear medicine specialists, surgeons and pathologists. Sentinel lymph node biopsy is a 'minimally invasive' diagnostic method in view of the low incidence of postoperative complications; both early and late.

The Multicenter Selective Lymphadenectomy Trial-1 (MSLT) demonstrated that sentinel lymph node biopsy in patients with melanomas made it possible to detect groups at high risk of malignancies disseminating, helped to correctly determine the disease progression stage, provided excellent local control and enabled patients to be

Table I. Adapted guidelines for sentinel lymph node biopsy according to the American Society of Clinical Oncology (ASCO) and Society of Surgical Oncology (SSO)

Thickness according to Breslow (mm)	Mitotic index		Ulceration		Additionally unfavourable factors*	
	< 1/mm ²	≥ 1/mm ²	No	Yes	No	Yes
≤ 0.5	No**	No**	No**	No**	No**	No**
0.51–0.75	No**	No**	No**	No**	No**	No**
0.76–1.0	To be considered	Recommended	To be considered	Recommended	To be considered	Recommended
> 1.0–4.0	Recommended	Recommended	Recommended	Recommended	Recommended	Recommended
> 4.0	Recommended	Recommended	Recommended	Recommended	Recommended	Recommended

*Unfavourable factors include positive margin, involvement of lymphatic vessels, infiltration grade IV according to Clark** excepting ulceration of the primary focus.

qualified for clinical trials according to uniform criteria [17]. Nevertheless, the MSLT-1 trial showed no improvement of survival time to disease recurrence and total survival time in all patients subjects that underwent sentinel lymph node biopsy, compared with the test group. Despite this, the patient subgroup with lymph nodes metastases, had a significantly higher incidence of 10-year survival in those patients who had immediate lymphadenectomy after finding a sentinel lymph node metastasis compared with patients being so treated at later stages due to clinically evident metastases being detected (62.1% vs 41.5%; $p = 0.006$) [17].

Upon finding melanoma metastases in sentinel lymph node(s) (in the case of $N > 0$) after histopathological examination, a sufficiently adequate group of regional lymph nodes should be totally excised (complementary lymphadenectomy) because in the remaining non-sentinel lymph nodes, melanoma metastases are found in about 20–30% patients [19].

Currently clinical trials are pending that are investigating whether the incidence of complementary lymphadenectomy can be limited in those patients having small and clinically occult metastases in sentinel lymph nodes of diameter below 0.1 mm or of a diameter up to 0.4 mm when found in the subcapsular location without having any contemporaneously adverse effects on melanoma recurrence [19].

Metastases to regional lymph nodes

It is commonly recognised that regional lymph nodes consist of one or two groups of lymph nodes situated at the lymphatic drainage regions closest to the primary lesion. This definition is applied to those lymph nodes that are inguinal-iliac, supraclavicular-axillary, cervical-supraclavicular, popliteal, antecubital, axillary-inguinal or bilateral axillary or inguinal.

Melanoma metastases to regional lymph nodes are assessed by histopathological examination according to the pN parameter grades, whilst metastases located in lymph nodes beyond the regional lymphatic drainage by the M1a parameter [7].

Melanoma metastases to lymph nodes are qualified as a pN being above 0 ($pN > 0$) in each case when cells are detected after staining with haematoxylin and eosin or if based on an immunohistochemical reaction. Table II defines microscopic categories of metastases found in lymph nodes according to the 8th edition of the pTNM AJCC/UICC classification from 2017 [8]; changes having been made to the 7th edition of the AJCC/UICC classification. The term ‘micrometastases’ has now replaced ‘clinically occult’ and instead of ‘gross metastases’, the term ‘clinically evident’ has been introduced.

The 8th revision of the TNM/AJCC classification of 2017, uses the pN parameter to describe melanoma metastases in lymph nodes regardless of their size and number of mali-

Table II. Microscopic classification of melanoma metastases in lymph nodes according to the 8th edition of the pTNM AJCC/UICC classification of 2017 [8]

Type of metastasis to lymph node	Definition
Clinically occult	Clinically and radiologically undetectable, but detected on histopathological examination after sentinel lymph node biopsy, in the preparation stained with haematoxylin and eosin or based on immunohistochemical reaction In the 7 th edition of the AJCC/UICC classification, these were described as micrometastases Their size does not affect assessment of the N parameter but is accounted for in Additional Factors Recommended for Clinical Care according to the 8 th edition of TNM/AJCC
Clinically evident	Is clinically detectable and consists of cells greater than 2 mm in size In the 7 th edition of the AJCC/UICC classification they were described as gross metastases

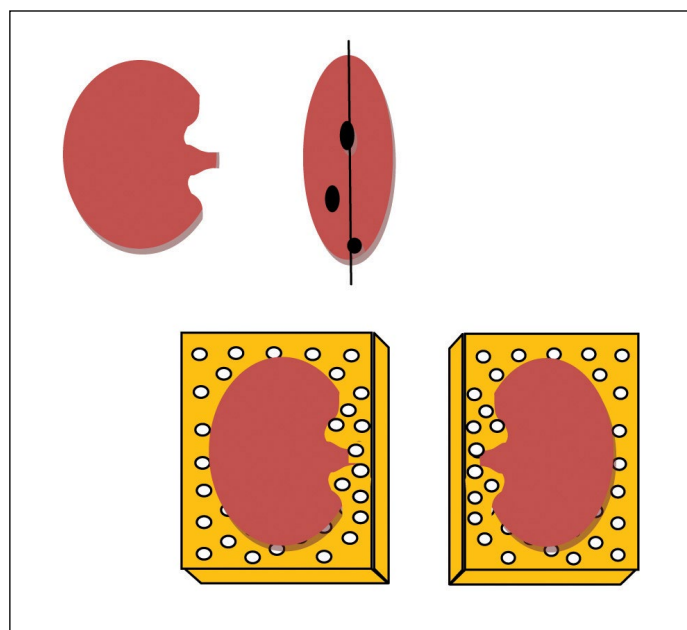


Figure 1. Mode of sentinel lymph node examination according to the British guidelines [22]

gnant cells, nor of microsatellite or satellite *foci* or *in-transit* metastases in the lymph node(s) in numbers greater than 0 ($pN > 0$). Patients with clinically occult metastases are classified as N1a, N2a, N3a, depending on the number of lymph nodes whenever microsatellite or satellite *foci* or *in-transit* metastases are not found, however if the afore mentioned satellite or *in-transit foci* are present but without metastases found in the lymph nodes, the N parameter is classified as N1c, N2c, N3c, respectively. In contrast, whenever there are clinically evident metastases in the lymph nodes but without microsatellite or satellite *foci* or *in-transit* metastases, the N parameter is then described as N1b, N2b, N3b, depending on the number of lymph nodes involved. The afore mentioned classification of the N parameter is significantly different between the 8th and 7th editions of the TNM AJCC/UICC classification (Tab. II) [7, 8].

Pathological examination procedure

For each cancer case the basic question is whether dissemination has occurred or if the cancer remains at the stage of local advancement. Metastases of melanoma can occur in the form of microsatellite or satellite *foci*, *in transit* metastases, metastases to lymph node(s) or distant metastases. If sentinel lymph node(s) are involved, metastases to one or more lymph nodes occupied as the first along the lymphatic drainage route are most likely. Detecting even single melanoma cells in the sentinel lymph node usually provides the first evidence as to dissemination stage and radically changes any prognoses and ensuing therapeutic decisions. Therefore, it is vital that a full sentinel lymph node

procedure/investigation is undertaken, in spite of the cost and extra effort required.

Examining SLNs requires a more detailed diagnostic procedure than that routinely used for assessing lymph node groups by the pathologist. Pathological examination of the sentinel lymph node in melanomas consist of three stages:

- histological examination of serially cut SLN cross-sections stained with haematoxylin and eosin;
- complementary application of immunohistochemical methods using a specific panel of antibodies;
- possible assessment of mRNA expression specific to a given malignancy, performed mainly for research purposes [10, 11].

This examination is based on commonly accepted standards. The diagnosis of SLN is included in the pathomorphological report. Guidelines concerning lymph nodes examined in the course of melanoma have been developed by the College of American Pathologists (CAP) [7], the European Society of Pathology (ESP) [11] and in the Polish principles of diagnostic-therapeutic management; recently issued by the Polish Society of Pathologists [10, 21].

The basic recommendations of the afore mentioned societies concern the mode for preparing tissue material, methods of its examination and its clinical interpretation. They can be summarised as in the sections below.

A. Preparation of SLN tissue material

Surgical procedure

Sentinel lymph nodes should be sent to the pathology laboratory either fixed in 10% buffered formalin or non-

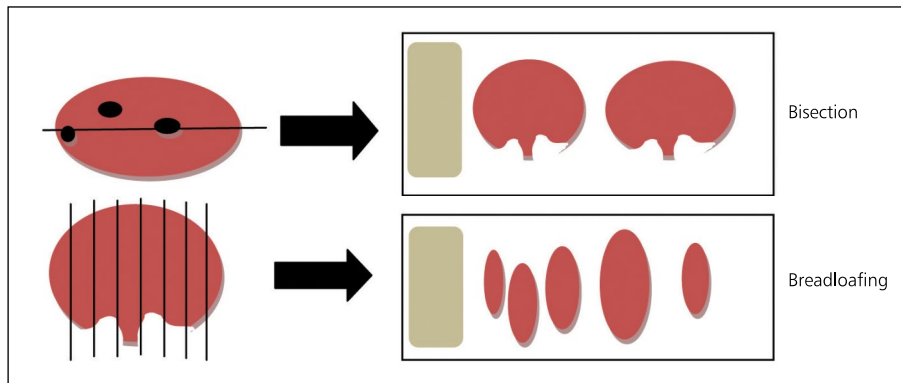


Figure 2. American recommendations concerning performing cross-sections through sentinel lymph node [4]

-fixed, upon which they are ready to undergo specialised PCR methods testing (polymerase chain reaction). It is recommended that the lymph node is denoted by means of threads or metal clips at the site where the greatest amount of the marker has accumulated. Intraoperative examination of a SLN is not indicated in melanoma. Preparing frozen tissue sections and cutting in a cryostat can however damage or destroy the malignant cells [5, 13]. It is therefore considered that the gold standard in melanoma is when examining sentinel lymph nodes that have been fixed in formalin and embedded in paraffin. Cytological examination is not recommended since macrophages filled with brown pigment cannot be unequivocally distinguished from melanocytes nor can the location of melanoma cells be found in the lymph node. Cytological material is also of no use in performing immunohistochemical tests for confirming or ruling out the diagnosis of a metastasis [22].

Gross examination when preparing sections

Each lymph node should be cut along its lengthwise axis. The recommended thickness of the lymph node cross-sections are 3 to 5 mm. The cross-section should contain adipose tissue adjacent to the lymph node. Each lymph node should be taken whole and placed into separate containers; two or more lymph nodes are not allowed to be together. If a single lymph node cannot be fitted into one container it should be divided into several separate containers and marked appropriately that this is so the case.

European guidelines recommend cutting a sentinel lymph node, according to Cochrane's original protocol, into two lobes cutting through the lymph node's hilum [23]. CAP guidelines recommend taking a small and whole lymph node (of diameter below 5 mm) or for larger ones they allow serial layer cutting into 2-mm slices perpendicular to the node lengthwise axis, termed 'breadloafing' [7]. Figure 1 depicts how cross-sections through the hilum of a sentinel lymph node are made and then placed into a container with

the cross-sectional surface facing down. Figure 2 shows both methods of taking sections according to CAP guidelines. The British proposal, accepted as the European Guidelines, recommends cutting six pairs of HE-stained tissue sections at 50 µm intervals. That method has now been accepted by EORTC.

B. Microscopic examination of SLN

These depend on determining the presence of, the size and location of metastases in the lymph node (Fig. 3). Melanoma cells lying singly or in small clusters are most frequently located in nodal sinuses under the capsule (58% cases). They are less frequently found in the lymph node parenchyma, in the fibrous capsule or in perinodal tissues (less than 5% cases). Melanoma metastases are found in about 20% of sentinel lymph nodes [24]. In 16% cases, they can be already detected by routine staining with haematoxylin and eosin, whilst in 4% they require detection and confirmation by immunohistochemical tests [24]. Out of the recommended tests of melanoma markers S100, HMB-45 (Fig. 4), MART-1 and tyrosinase, at least one of these should be carried out. The MITF antibody is not recommended because of its positive reaction with macrophages [25]. A differential diagnosis requires distinguishing melanocytes from macrophages, dendritic cells and naevus cells located subcapsularly. In cases of spindle cell melanoma, the S100 marker is recommended, since this rare melanoma type may not express HMB-45 nor MART-1 [10, 11, 21].

If melanoma metastases are found in sentinel lymph node(s), then the following should apply:

- the number of lymph nodes found and number of nodes with metastases should be reported;
- the following microscopic features of metastases in sentinel lymph node(s) should be determined:
 - the greatest dimensions of the metastasis/metastases,
 - their location (subcapsular, intramedullary, mixed or diffuse),

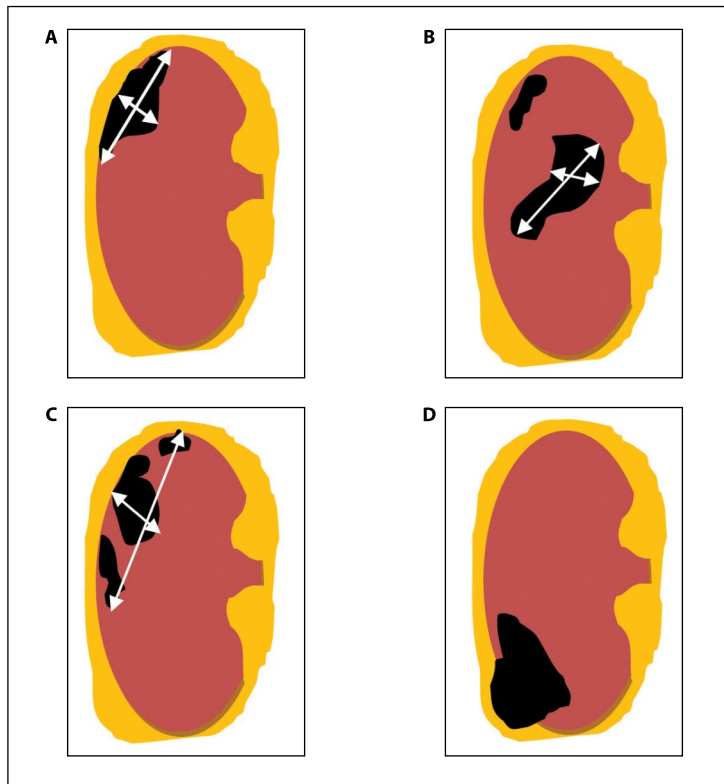


Figure 3. Location of melanoma metastases in sentinel lymph node: **A** — subcapsular, **B** — mixed, subcapsular and intramedullary, **C** — multifocal, **D** — extending to perinodal tissues acc. to [4]

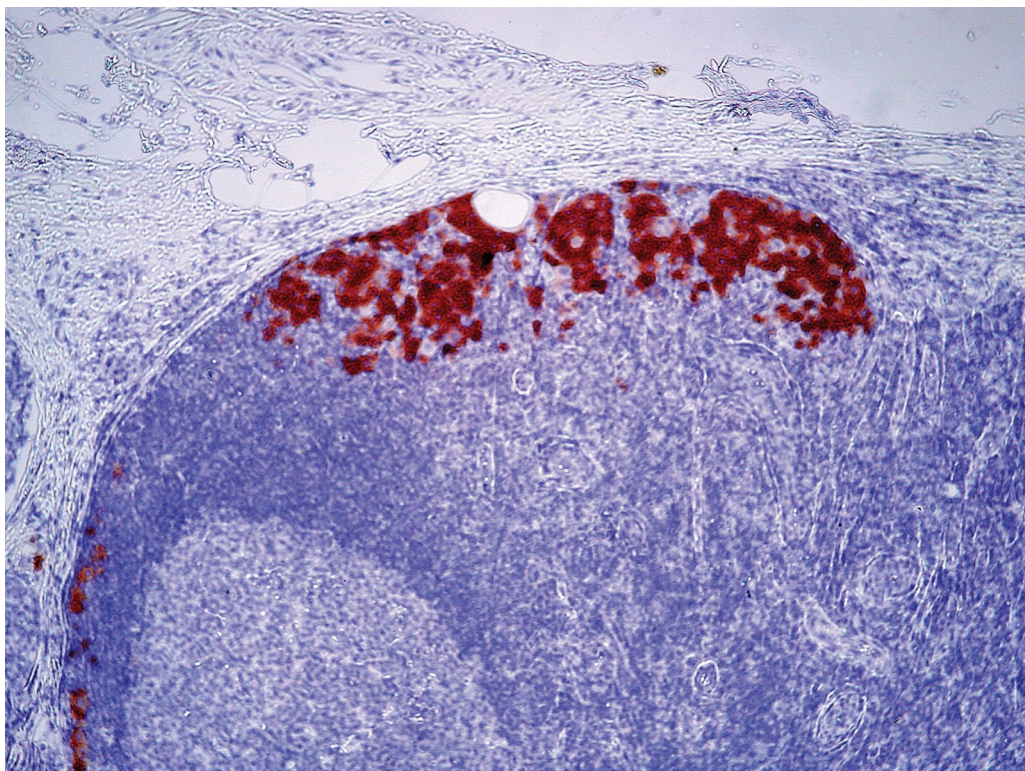


Figure 4. Location of melanoma metastases in subcapsular region. Immunohistochemical staining HMB45

- penetration into perinodal adipose tissue,
- penetration into adipose tissue,
- vasculature involvement.

In summary it should be said that due to a lack of consensus whenever sentinel lymph node are studied, the aforementioned guidelines constitute an optimal algorithm of management thereby making it possible that the highest sensitivity and specificity of an examination is maintained.

Conflict of interest: none declared

Prof Anna Nasierowska-Guttmejer, MD, PhD

Pathology Department, Central Teaching Hospital,
Ministry of Internal Affairs
Wołoska 137, 02–507 Warszawa, Poland
e-mail: anna-guttmejer@gmail.com

Received and accepted: 20 Mar 2017

References

1. Didkowska J, Wojciechowska U. *Nowotwory złośliwe w Polsce w 2013 roku; Cancer in Poland in 2013*. Warszawa: Krajowy Rejestr Nowotworów, 2015.
2. Han D, Thomas DC, Zager JS et al. Clinical utilities and biological characteristics of melanoma sentinel lymph nodes. *World J Clin Oncol* 2016; 7: 174–188.
3. Nasierowska-Guttmejer A, Rutkowski P. Czerniak. In: *Zalecenia do diagnostyki histopatologicznej nowotworów*. Centrum Onkologii — Instytut, Oddział Gliwice, Polskie Towarzystwo Patologów, 2013: 19–23.
4. Rutkowski P (ed.). *Złośliwe nowotwory skóry*. Gdańsk: Via Medica, 2014.
5. Prieto VG. Sentinel lymph nodes in cutaneous melanoma: handling, examination, and clinical repercussion. *Arch Pathol Lab Med* 2010; 134: 1764–1769.
6. Balch CM, Gershenwald JE, Soong SJ et al. Final version of 2009 AJCC melanoma staging and classification. *J Clin Oncol* 2009; 27: 6199–6206. http://www.cap.org/apps/docs/committees/cancer/cancer_protocols/2013/SkinMelanoma_13protocol_3300.pdf.
7. Gershenwald JE, Scoyler RA, Hess KR et al. Melanoma of the skin. In: Amin MB, Edge SE, Greene F et al. (eds.). *AJCC Cancer staging manual*. Chicago: Springer, 2017: 563–585.
8. Mitteldorf C, Bertsch HP, Jung K et al. Sentinel node biopsy improves prognostic stratification in patients with thin (pT1) melanomas and an additional risk factor. *Ann Surg Oncol* 2014; 21: 2252–2258.
10. Biernat W, Nasierowska-Guttmejer A. Diagnostyka patomorfologiczna węzła wartowniczego. In: *Węzeł chłonny wartowniczy*. Jezierski A (red.). Gdańsk: Via Medica, 2014: 27–36.
11. Biernat W. Diagnostyka histopatologiczna węzła wartowniczego. In: *Węzeł chłonny wartowniczy w chorobach nowotworowych*. Jezierski A, Piekarski J (red.). Warszawa: Fundacja PPCh, 2010: 23–28.
12. Batistatou A, Cook MG, Massi D et al. Histopathology report of cutaneous melanoma and sentinel lymph node in Europe: a web-based survey by the Dermatopathology Working Group of the European Society of Pathology. *Virchows Arch* 2009; 454: 505–511.
13. Rutkowski P, Wysocki PJ, Nasierowska-Guttmejer A et al. Cutaneous melanoma — diagnostic and therapeutic guidelines in 2016; Czerniak skóry — zasady postępowania diagnostyczno-terapeutycznego w 2016 roku. *Oncol Clin Pract; Onkol Prakt Klin* 2015; 11: 216–227.
14. Wong SL, Balch CM, Hurley P et al.; American Society of Clinical Oncology; Society of Surgical Oncology. Sentinel lymph node biopsy for melanoma: American Society of Clinical Oncology and Society of Surgical Oncology joint clinical practice guideline. *J Clin Oncol* 2012; 30: 2912–2918.
15. *NCCN Guidelines. Melanoma*. version 3.2016.
16. Dummer R, Hauschild A, Lindenblatt N et al. ESMO Guidelines Committee. Cutaneous melanoma: ESMO Clinical Practice Guidelines for diagnosis, treatment and follow-up. *Ann Oncol* 2015; 26 (Suppl 5): v126–132.
17. Morton DL, Thompson JF, Cochran AJ et al. Final trial report of sentinel-node biopsy versus nodal observation in melanoma. *N Engl J Med* 2014; 370: 599–609.
18. Rutkowski P, Szydłowski K, Nowecki ZI et al. The long-term results and prognostic significance of cutaneous melanoma surgery using sentinel node biopsy with triple technique. *World J Surg Oncol* 2015; 13: 299.
19. Nowecki ZI, Rutkowski P, Michej W. The survival benefit to patients with positive sentinel node melanoma after completion lymph node dissection may be limited to the subgroup with a primary lesion Breslow thickness greater than 1.0 and less than or equal to 4 mm (pT2–pT3). *Ann Surg Oncol* 2008; 15: 2223–2234.
20. van Akkooi AC, Nowecki ZI, Voit C et al. Sentinel node tumor burden according to the Rotterdam criteria is the most important prognostic factor for survival in melanoma patients: a multicenter study in 388 patients with positive sentinel nodes. *Ann Surg* 2008; 248: 949–955.
21. Nasierowska-Guttmejer A, Rutkowski P. Czerniak. In: *Zalecenia do diagnostyki histopatologicznej nowotworów*. Centrum Onkologii, Oddział Gliwice; Polskie Towarzystwo Patologów, 2013: 19–23.
22. Frishberg DP, Balch C, Balzer BL et al. Protocol for the examination of specimens from patients with melanoma of the skin. *Arch Pathol Lab Med* 2009; 133: 1560–1567.
23. Cook MG, Di Palma S. Pathology of sentinel lymph nodes for melanoma. *J Clin Pathol* 2008; 61: 897–902.
24. Migliano E, Bellei B, Govoni FA et al. SLN melanoma micrometastasis predictivity of nodal status: a long term retrospective study. *J Exp Clin Cancer Res* 2013; 32: 47.
25. Busam KJ. Microphthalmia transcription factor: expression is not restricted to melanocytes. *Adv Anat Pathol* 2002; 9: 140–141.
26. http://www.cap.org/apps/docs/committees/cancer/cancer_protocols/2013/SkinMelanoma_13protocol_3300.pdf.